

## Clinical outcomes of Fournier's gangrene from a tertiary hospital

Isaac José Felipe Corrêa Neto<sup>1</sup>, Otávio Nunes Sia<sup>2</sup>, Alexander Sá Rolim<sup>3</sup>, Rogério Freitas Lino Souza<sup>4</sup>,  
Hugo Henriques Watté<sup>5</sup>, Laércio Robles<sup>6</sup>

<sup>1</sup>Assistant Physician at the Service of Coloproctology at the Hospital Santa Marcelina (HSM) – São Paulo (SP), Brazil; Associate member of the Sociedade Brasileira de Coloproctologia (SBCP) – São Paulo (SP), Brazil. <sup>2</sup>Former Resident Physician at the Service of Coloproctology, HSM – São Paulo (SP), Brazil; Affiliate member of the SBCP – São Paulo (SP), Brazil. <sup>3</sup>Assistant Physician at the Service of Coloproctology at the HSM – São Paulo (SP), Brazil. <sup>4</sup>Assistant Physician at the Service of Coloproctology at the HSM – São Paulo (SP), Brazil. <sup>5</sup>Assistant Physician at the Service of Coloproctology at the HSM – São Paulo (SP), Brazil; Full member at the SBCP – São Paulo (SP), Brazil. <sup>6</sup>Physician, Head of the Department of Surgery and Coordinator of the Medical Residency Program in Coloproctology at the HSM – São Paulo (SP), Brazil.

Corrêa Neto IJF, Sia ON, Rolim AS, Souza RFL, Watté HH, Robles L. Clinical outcomes of Fournier's gangrene from a tertiary hospital. *J Coloproctol*, 2012;32(4): 407-410.

**ABSTRACT:** Fournier's gangrene is a progressive polymicrobial necrotizing fasciitis, caused by aerobic and anaerobic organisms. It causes an endarteritis obliterans leading to vessel thrombosis and subsequent cutaneous and subcutaneous necrosis of the perineal region. **Objective:** It was to describe the clinical outcomes of Fournier's gangrene treated at the Hospital Santa Marcelina, São Paulo (SP), Brazil. **Methods:** This was a retrospective study conducted at the Hospital Santa Marcelina, in São Paulo (SP), Brazil, with patients with necrotizing fasciitis from September 2008 to March 2011. **Results:** We included 13 patients, most were males, and the mean age was 51.8 years old. Five of them presented with systemic inflammatory response syndrome, only two had no comorbidities and 23% were obese. The most prevalent etiologic agent was *E. coli*, and the most common antibiotic regimen consisted of a combination of metronidazole with ciprofloxacin. The average number of surgical procedures performed by patient was 2.07, and 7 patients (53.8%) underwent colostomy formation. The mortality rate was 30.8%. **Conclusions:** Fournier's gangrene is a severe disease, with high mortality rates. The physician should suspect its diagnosis early and have an aggressive treatment approach to achieve better outcomes.

**Keywords:** Fournier gangrene; perineum; colostomy; bacterial infections; necrosis.

**RESUMO:** A gangrena de Fournier representa uma fascíte necrotizante e progressiva de origem polimicrobiana, causada por organismos aeróbios e anaeróbios. Tem como fisiopatologia a endarterite obliterante, que leva à trombose dos vasos cutâneos e subcutâneos e à consequente necrose da região perineal. **Objetivo:** Foi descrever os casos de gangrena de Fournier atendidos no Hospital Santa Marcelina, São Paulo (SP), Brasil. **Métodos:** Este estudo retrospectivo foi realizado no Hospital Santa Marcelina, em São Paulo (SP), com pacientes portadores de fascíte necrotizante no período de setembro de 2008 a março de 2011. **Resultados:** Este estudo incluiu 13 pacientes, a maioria do sexo masculino, com média de idade de 51,8 anos. Cinco apresentavam síndrome da resposta inflamatória sistêmica e somente dois não tinham comorbidades, sendo 23% deles obesos. O agente etiológico mais prevalente foi a *E.coli*, e o esquema de antibiótico mais utilizado foi a associação de metronidazol e ciprofloxacina. A média foi de 2,07 cirurgias por paciente, com realização de ostomia derivativa em 7 dos 13 pacientes (53,8%). A taxa de mortalidade foi de 30,8%. **Conclusão:** A gangrena de Fournier é uma doença grave, com alto índice de mortalidade. O médico assistente deve suspeitar precocemente essa afecção e realizar conduta terapêutica agressiva visando a melhores resultados.

**Palavras-chave:** gangrena de Fournier; períneo; colostomia; infecções bacterianas; necrose.

*Study carried out at the Coloproctology Medical Residency Program of the Department of General Surgery at the Hospital Santa Marcelina – São Paulo (SP), Brazil.*

*Financing source: none.*

*Conflict of interest: nothing to declare.*

*Submitted on: 01/06/2012*

*Approved on: 13/09/2012*

## INTRODUCTION

Fournier's gangrene (FG) was reported for the first time in 1764 by Baurienne<sup>1</sup> and initially described in 1883 by Fournier<sup>2</sup>. It is a progressive polymicrobial necrotizing fasciitis, caused by aerobic and anaerobic organisms<sup>3</sup> that act synergistically, affecting the perianal, perineal, genital and abdominal regions<sup>4</sup>.

Other terms have been used to describe this condition, such as idiopathic gangrene, spontaneous fulminant gangrene of the scrotum, streptococcal scrotal gangrene and gangrenous erysipelas of the scrotum, among other names.

This infectious process caused by endarteritis obliterans leads to thrombosis of cutaneous and subcutaneous vessels and consequent necrosis of the skin in the affected region.<sup>3,5</sup> Necrosis dissemination may reach 2 to 3 cm per hour<sup>6</sup>. In addition, tissue edema, hypoxia and difficult blood supply contribute to anaerobic bacteria development and proliferation<sup>7</sup>.

FG affects around 1:7,500<sup>8</sup>, mostly men, at mean age of 50 years old<sup>5,9</sup> and at the ratio of 10:1. Risk factors for FG include: diabetes mellitus, found in 40 to 60% of the patients<sup>10-12</sup>, alcohol abuse (25 to 50% of the cases), arterial hypertension, renal and hepatic failure, obesity, senility, smoking, immunodeficiency diseases and other conditions, such as infection by human immunodeficiency virus (HIV), radiotherapy and chemotherapy, leukemia, neoplasm and surgical procedures<sup>13-15</sup>.

Regarding its etiology, a careful investigation should be performed to determine the disease origin, which may be especially located in the urogenital tract, digestive tract or in skin infections. A recent study that analyzed 1,726 cases determined that skin infections may be the site of infection in 24% of the patients<sup>16</sup>.

The most commonly isolated microorganisms are species that usually colonize the urethra, rectum and skin of the affected region<sup>17</sup>, including aerobic gram-negative, *Escherichia coli* and *Pseudomonas aeruginosa*, aerobic gram-positive, *Staphylococcus aureus* and *Staphylococcus epidermidis*, *Clostridium difficile* and *Bacteroides fragilis* anaerobic bacilli and gram-positive spore-forming bacilli<sup>8,18,19</sup>.

Its clinical aspects involve an area of hyperemia, pain and swelling, that may affect the perianal, peri-

neal and scrotal region, indicating cellulitis. Tissue crepitus is found in 50 to 62% of the cases<sup>20</sup>. After 48 to 72 hours, necrotic areas appear in the infected tissue, making local gangrene evident after 4 to 5 days.

Most authors consider three principles when selecting the treatment option<sup>9,21,22</sup>: clinical stabilization, broad-spectrum antibiotics and surgical debridement with excision of affected tissues, as broad as necessary, complemented or not by urinary and fecal diversion.

## METHODS

This is a retrospective descriptive study that analyzed the electronic records of patients with necrotizing fasciitis from September 2008 to March 2011, at the Hospital Santa Marcelina, in São Paulo (SP), Brazil.

The following variables were collected: age and gender of patients, comorbidities, obesity, symptom duration, signs of systemic inflammatory response syndrome (SIRS), etiology, prior surgical procedures and how many, use of colostomy, etiological agent, antibiotic regimen, hospital length-of-stay and mortality rate.

This study was evaluated and approved by the Research Ethics Committee of the Hospital Santa Marcelina.

## RESULTS

Our study included 13 patients with FG admitted to the Hospital Santa Marcelina in the studied period, 77% (10) were males, mean age of 51.8 years old (24–67), and the most affected age group was that of patients in the 5<sup>th</sup> decade.

Most patients were admitted several days after disease onset, ranging from 1 to 15 days, mean period of 7.6 days, and 5 of them (38.5%) already presenting signs of systemic inflammatory response syndrome. Regarding the predisposing factors, only 2 patients (15%) did not present any comorbidity. Diabetes mellitus and arterial hypertension were present in 6 (46%) patients, and neurological sequelae and neoplasm in 15%. Morbid obesity was observed in 23% of the patients.

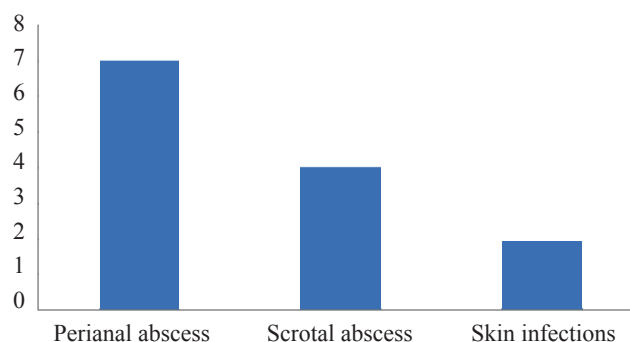
Regarding the probable initial infection origin, the most common was perianal abscess in 7, scrotal abscess in 4 and cutaneous infections in 2 patients (Figure).

The most prevalent etiological agent was *E. coli*, found in 57.1% of the cases, followed by *Enterococcus*, in 28.6%. The most frequent used antibiotic regimen was a combination of metronidazole with ciprofloxacin, and it was changed according to the clinical progress and culture results.

Average number of surgical procedures was 2.07 per patient (ranging from 1 to 7 surgeries), and diversion colostomy was performed in 7 patients (53.8%). The average hospital length-of-stay was 14.4 days (ranged from 4 to 39 days). Mortality rate was 30.8%, and the clinical features of these 4 patients can be seen in Table.

## DISCUSSION

Like most studies in the medical literature, we observed greater incidence of Fournier's gangrene in men<sup>4,23</sup>, with predominance of patients in the fifth decade of life. Diabetes was present in almost half of the cases, in agreement with other studies that report 40–60% incidence, and it was considered the main reason for poor response to treatment<sup>24</sup>.



**Figure.** Primary infection origin of Fournier's gangrene.

The main infection origin found in this study was: anorectal and genitourinary tracts, followed by cutaneous infections. Data obtained from this study agree with those presented in the literature, which shows involvement of anorectal tract in 30–70% of the cases, involvement of genitourinary tract in 13–70% and cutaneous infections in around 24%<sup>16,25,26</sup>.

FG is usually a result of polymicrobial infection, caused by aerobic and anaerobic organisms. *E. coli* is the most commonly isolated microorganism, also in agreement with our study.

The Fournier's gangrene severity index (FGSI)<sup>22</sup> analyzes the following parameters: temperature, heart ratio, respiratory rate, levels of sodium, potassium, creatinine, bicarbonate, hematocrit and leukocyte count. We did not use this index as an assessment parameter in this study, since this is from a retrospective report without a well-defined standardized protocol.

The treatment of FG involves hemodynamic support, rigorous intravenous hydration, broad-spectrum antibiotics, debridement of non-living tissues, with suspicion of necrosis with doubtful viability, primary site investigation and, when required, urinary or fecal diversion. Urethral stenosis or genitourinary source of infection are indications for cystostomy, while colostomy is indicated in case of infection involving the anal sphincter or in the presence of large perineal wound with persistent fecal contamination<sup>4,23,27</sup>. If necrotic areas still persist after 24 to 48 hours from the initial procedure, a new surgical debridement should be performed<sup>4</sup>.

FG may progress at the speed of 2 to 3 cm per hour<sup>6</sup>, therefore, a precise and quick diagnosis associated with an effective surgical treatment are very important and can determine the disease prognosis and mortality.

Initially considered as a process limited to men, idiopathic and fulminant in its original description, FG

**Table.** Clinical features associated with mortality.

	Age (years)	Gender	Comorbidities	Infection origin	Fecal diversion
Patient 1	58	Male	Hypertension, diabetes, smoking, alcoholism	Perianal abscess	Yes
Patient 2	24	Male	None	Cutaneous infection	No
Patient 3	53	Male	Spinal trauma, schizophrenia	Cutaneous infection	No
Patient 4	56	Male	Mesenchymal neoplasm recurrence	Perianal abscess	No

is today a well-known disease, but still presenting with high mortality rates<sup>5,13,17</sup>. In our analysis, the mortality rate was of 30.8%, according to the previous literature, in which can range from 3 to 67%<sup>4,24,25</sup>. Factors of even worse prognosis include: sepsis at hospital admission, late referral to medical support and diabetes.

## REFERENCES

1. Baurienne H. Sur une plaie contuse qui s'est terminée par le sphacèle de la scrotum. *J Med Chir Pharm* 1764;20:251-6.
2. Fournier JA. Gangrene foudroyante de la verge. *Med Pract* 1883;4:589-97.
3. Laucks SS 2nd. Fournier's gangrene. *Surg Clin North Am* 1994;74(6):1339-52.
4. Navarro-Vera JA. Gangrena de Fournier. *Rev Evid Invest Clin* 2010;3(1):51-7.
5. Yaghan RJ, Al-Jaberi TM, Bani-Hani I. Fournier's gangrene: changing face of the disease. *Dis Colon Rectum* 2000;43(9):1300-8.
6. Fajdic J, Bukovic D, Hrgovic Z, Habek M, Gugic D, Jonas D, et al. Management of Fournier's gangrene – report of 7 cases and review of the literature. *Eur J Med Res* 2007;12(4):169-72.
7. Burgl JCZ, Silva JG, Parra BJ. Gangrena de Fournier: presentación de caso. *Univ Med* 2007;48(4):487-92.
8. Nisbet AA, Thompson IM. Impact of diabetes mellitus on the presentation and outcomes of Fournier's gangrene. *Urology* 2002;60(5):775-9.
9. Schaeffer AJ. Infections of the urinary tract. In: Walsh PC, Retik AB, Vaughan ED Jr, Wein AJ, editors. *Campbell's Urology*. 8th ed. Philadelphia: WB Saunders Company; 2002. p. 515-602.
10. Norton KS, Johnson LW, Perry T, Perry KH, Schon JK, Zibary GB. Management of Fournier's gangrene: an eleven year retrospective analysis of early recognition, diagnosis, and treatment. *Am Surg* 2002;68(8):709-13.
11. Féres O, Andrade JI, Rocha JJR, Aprilli F. Fournier's gangrene: a new anatomic classification. In: Reis Neto JA, editor. *Proceedings of the 18th Biennial Congress of the International Society of University Colon and Rectal Surgeons*. Bologna: Monduzzi Editore; 2000. p. 103-7.
12. Thambi Dorai CR, Kandasami P. Fournier's gangrene: its aetiology and management. *Aust N Z J Surg* 1991;61(5):370-2.
13. Eke N. Fournier's gangrene: a review of 1726 cases. *Br J Surg* 2000;87(6):718-28.
14. Paty R, Smith AD. Gangrene and Fournier's gangrene. *Urol Clin North Am* 1992;19(1):149-62.
15. Chang JJ, Lee CC, Cheng SY. Fulminant gangrenous and crepitating scrotum. *Arch Dermatol* 2006;142(6):767-8.
16. Ahrenholz DH. Necrotizing soft-tissue infections. *Surg Clin North Am* 1988;68(1):199-214.
17. Smith GL, Bunker CB, Dinneen MD. Fournier's gangrene. *Br J Urol* 1998;81(3):347-55.
18. Yaghan RJ, Al-Jaberi TM, Bani-Hani I. Fournier's gangrene: changing face of the disease. *Dis Colon Rectum* 2000;43(9):1300-8.
19. Chinchilla RM, Morejona EI, Pietricicâ BN, Franco EP, Albasini JLA, López BM. Fournier's gangrene. Descriptive analysis of 20 cases and literature review. *Actas Urol Esp* 2009;33(8):873-80.
20. Almanza JM, Martín JAR, Latif J, Zuccollo S. Infecciones necrotizantes del perine: gangrena de Fournier. *Rev argent cir* 1993;64(3/4):122-8.
21. Cabral AA, Pineda GA, Domingues J, Cattaneo D, Gordillo L, De Barrio J, et al. Celulitis necrotizante del periné (Gangrena de Fournier). *Rev Argent Coloproct* 1997;8(1):60-3.
22. Laor E, Palmer LS, Tolia BM, Reid RE, Winter HI. Outcome prediction in patients with Fournier's gangrene. *J Urol* 1995;154(1):89-92.
23. Gamagami RA, Mostafavi M, Gamagami A, Lazorthes F. Fournier's gangrene: an unusual presentation for rectal carcinoma. *Am J Gastroenterol* 1998;93(4):657-8.
24. Mehl AA, Nogueira Filho DC, Mantovani LM, Grippa MM, Berger R, Krauss D, et al. Manejo da gangrena de Fournier: experiência de um hospital universitário de Curitiba. *Rev Col Bras Cir* 2010;37(6):435-41.
25. Irazu JC, de Miceu S, Salas J, Katz ON, Eche-guren ES, Blundo OA. Gangrena de Fournier: nuestra experiencia clinica, etiopatogenia y tratamiento. *Actas Urol Esp* 1999;23(9):778-83.
26. Czymek R, Hildebrand P, Kleemann M, Roblick U, Hoffmann M, Jungbluth T, et al. New insights into the epidemiology and etiology of Fournier's gangrene: a review of 33 patients. *Infection* 2009;37(4):306-12.
27. Barreda JT, Scheiding MM, Fernández CS, Campaña JMC, Aguilera JR, Miranda EF, et al. Fournier gangrene. A retrospective study of 41 cases. *Cir Esp* 2010;87(4):218-23.

## CONCLUSION

Fournier's gangrene is a severe disease with high mortality rates. The physician should suspect its diagnosis early and have an aggressive treatment approach to achieve better outcomes.

### Correspondence to:

Isaac José Felipe Corrêa Neto  
Hospital Santa Marcelina  
Rua Santa Marcelina, 177  
CEP: 08270-070 – São Paulo (SP), Brazil  
E-mail: isaacneto@hotmail.com