



Role of renin-angiotensin system in development of heart failure induced by myocardial infarction in rats

DANIEL C. TRINDADE^{1,3}, RAQUEL C. TRINDADE¹, MICHELLE P. MARASSI², ORNÉLIA P.P.R. MARTINS¹, RICARDO H. COSTA-E-SOUSA^{2,3}, ELISABETE C. MATTOS⁴, ALCIDES MARINHO-JR.^{1,3}, LUÍS C. REIS³ and EMERSON L. OLIVARES^{2,3}

¹Universidade de Barra Mansa, Rua Vereador Pinho de Carvalho, 267, 27330-550 Barra Mansa, RJ, Brasil

²Instituto de Biofísica Carlos Chagas Filho, CCS, UFRJ, Av. Brigadeiro Trompowsky, s/n Ilha do Fundão, 21949-900 Rio de Janeiro, RJ, Brasil

³Departamento de Ciências Fisiológicas, Instituto de Biologia, Universidade Federal Rural do Rio de Janeiro BR 465, Km 7, 23890-000 Seropédica, RJ, Brasil

⁴Ecodata Exames Médicos LTDA, 22020-120 Rio de Janeiro, RJ, Brasil

Manuscript received on December 27, 2005; accepted for publication on July 19, 2006; presented by LUCIA MENDONÇA PREVIATO

ABSTRACT

We investigated the morphologic and functional changes of infarcted rat hearts under a paradigm of angiotensin-converting enzyme inhibition. Myocardial infarction was induced by left coronary artery ligation and a control group (SHAM) underwent sham-operation. Infarcted rats received normal drinking water with (CAP group) or without (INF group) captopril. Functional assessment was performed by electro (ECG) and echocardiogram (ECHO) just before and 21 days after surgery. The ECG of INF and CAP showed similar values and resembled healed infarct after surgery. The most outstanding differences between INF and CAP were the prevention of the increase of P-wave and attenuation both in rightward deviation of the QRS axis and Q-wave amplitude in CAP compared with INF. The ECHO showed that captopril treatment improved the diastolic filling more than systolic performance. Cardiac dilatation and left congestive heart failure were observed only in INF. Both infarcted groups showed a scar tissue in the left ventricular wall, but the INF showed a higher scar area than CAP (49.7 ± 5.24 vs. 22.33 ± 6.19 respectively). These data suggest that the renin-angiotensin system induces morphologic and functional changes in post-infarcted rat hearts and which can be assessed by non-invasive exams.

Key words: myocardial infarction, electrocardiogram, echocardiogram, renin-angiotensin system, captopril.

INTRODUCTION

Myocardial infarction (MI) often evokes left ventricular dilatation associated with hypertrophy and fibroses of non-infarcted myocardium. Compensatory mechanisms, that help the compromised tissue in the early steps of the ischemic insult, are detrimental in the chronic stage of this disease (Francis 1985). Because one of these compensatory mechanisms, the circulating and local renin-angiotensin system, has long been considered

responsible for cardiac and vascular remodeling (Gody 1986, Sigurdsson et al. 1993, Gottlieb et al. 1993), inhibition of the angiotensin I-converting enzyme (iACE) have proven to be a beneficial therapy in improving cardiac function and increasing survival rate in experimental and clinical myocardial infarction (Pfeffer et al. 1985, Schoemaker et al. 1991, Kober et al. 1995). However, the window of time when best protection is achieved by iACE treatment is still controversial. Nelissen-Vrancken et al. (1998) reported that early (0-21 days after MI), but not late (21-35 days after MI) treatment with captopril

Correspondence to: Prof. Emerson Lopes Olivares
E-mail: elopes@ufrj.br

inhibited the normalization of maximum coronary flow without affecting the hypertrophic response. The authors suggested that this negative result could be attributed to the inhibition of endothelial proliferation and vascular growth after infarction. Schoemaker et al. (1991) also suggested a decrease in cardiac performance after early (0-3 weeks after MI) and an increase after late (3-5 weeks after MI) iACE. In the other hand, Kalkman et al. (1999), working with isolated rat heart, demonstrated that early iACE (1-3 weeks after MI) prevented the hypertrophy, but not adaptive vascular growth, increasing perfusion on viable myocardium. However, the same group did not demonstrate any improvement of cardiac function adopting this protocol (Schoemaker et al. 1991).

Despite of the beginning and period of treatment, the beneficial effects of the ACE inhibitors on cardiac function are still not clear. Although this pharmacological approach is effective in decreasing afterload in response to vasodilatation, many studies, as the Litwin et al. (1996), showed only a slight improvement in systolic function.

Our group already described significant changes in electro and echocardiogram (Santos and Masuda 1991, Olivares et al. 2004) of healed infarcted rat hearts. But, a serial functional assessment based on non-invasive exam as a tool to investigate the role of renin-angiotensin system in myocardial infarction is still poor in literature.

Thus, the aim of this study was to report the electro/echocardiographic and morphologic changes of healed infarcted rat hearts under a paradigm of iACE since early stage of myocardial infarction.

MATERIALS AND METHODS

This investigation conforms to the Guide for the Care and Use of Laboratory Animals published by the US National Institutes of Health (NIH Publication No. 85-23, revised 1996) and was approved by the institutional animal welfare committee.

ANIMALS AND GENERAL PROCEDURES

Wistar rats (200 to 250 g) were obtained from Universidade Federal do Rio de Janeiro (UFRuralRJ/Brazil). Animals were housed at controlled temperature (23°C) with daily exposure to a 12 h light-dark cycle and free access to water and standard rat chow.

MYOCARDIAL INFARCTION AND CAPTOPRIL-TREATMENT

Left ventricular myocardial infarction (MI) was induced following the procedure described by Johns and Olson (1954). Briefly, the rats were anesthetized with Halothane PA (Merck, Deutschland) and a 2 cm incision was made on the left side of the thorax, parallel to the sternum. The fifth and sixth ribs were separated, exposing the heart, and the left anterior descending coronary artery (LAD) was permanently occluded as it passes underneath the left atrial appendage by ligation with a 6-0 silk thread. The chest was then closed with continuous silk stitch and the rats allowed recovering.

The infarcted rats were randomized to receive captopril (Extracto Vital[®], 2 g/L in drinking water), as described by Pfeffer et al. (1987), soon after surgery and supplied continuously until the end of the experiment (28 days after surgery).

FUNCTIONAL STUDY

Electrocardiography

The electrocardiogram (ECG) was performed as described before (Olivares et al. 2004). Rats were anesthetized with Ketamine (50 mg/kg, Dopalen[®]) and Xilazine (5 mg/kg, Amasedan[®]) administered intraperitoneally and placed in the supine position for ECG recording (Cardimax FX-2111-Fukuda Denshi) in classic configuration: six limb leads (L1, L2, L3, aVR, aVL, aVF) and two chest leads (V_{ant} recorded half-way from the sternal manubrium and the xyphoid process and V_{lat} , recorded at the mid-axillary line, at the same height of the first chest lead). In order to obtain reproducible ECG recordings in the rat, the anesthetized animals were fixed on a board with their anterior paws in orthogonal direction with respect to the body and posterior limbs were kept free. Additionally, all animals were carefully examined at the time of *post mortem* study in order to detect alterations of the anatomical relations of the heart in the thoracic cage that might lead to misleading results in the evaluation of the ventricular depolarization axis. ECG was recorded for 3 minutes after which the anesthetized animals were subject to echocardiographic examination. During the 5-15 minutes that lasted the echocardiogram exam we continuously recorded an L2 lead ECG.

The ECG was calibrated for 50 mm/s with a sensitivity of the 2 cm = 1 mV. The parameters studied were as previously described (Olivares et al. 2004): heart rate, presence of a P wave larger than 0.1 mV in L1, L2 or L3, PR interval, QRS duration, QT interval, frontal QRS axis ($\hat{A}QRS$), QRS amplitude index (I-QRS, the sum of QRS complex voltage in L1, L2 and L3) and presence of Q wave in L1, L2, L3, aVF, V_{ant} and V_{lat} . In all infarcted animals (n = 15) the presence of an $\hat{A}QRS$ larger than 90° (right deviation) was used as evidence of an extensive infarction as demonstrated by *post mortem* pathological analysis that confirmed the presence of transmural scar tissue (Santos and Masuda 1991, Olivares et al. 2004).

Echocardiography

The echocardiogram (ECHO) was performed as described before (Olivares et al. 2004). In this study we used an echocardiographic color-system (Megas/ Esaote) equipped with a 10 MHz electronic-phased-array transducer. Under Ketamine and Xylazine anesthesia, the chests of the animals were shaved and they were maintained either in left lateral decubitus or supine position. All ECO analysis was performed blind by the same echocardiographer and included morphologic and functional parameters. Images were obtained from the left paraesternal and apical windows. Short-axis 2-dimensional views of the left ventricle (LV) were taken at the level of the papillary muscles to obtain the M-mode recordings. Anterior and posterior end-diastolic and end-systolic wall thickness, LV, left atrium and aorta internal dimensions (LA/Ao) ratio, and relative wall thickness (RWT, 2X posterior end-diastolic wall thickness/LV internal end-diastolic dimension, LVEDd) were measured following the American Society of Echocardiography (ASE) leading-edge method. The systolic function was expressed by the ejection fraction (EF%), calculated by Simpson's method after left ventricular (LV) volume calculation: systolic and diastolic LV long axis were measured on the long-axis view and systolic and diastolic LV short axis, traced at papillary muscles, were measured on transversal view. The pulsed-wave Doppler spectra of mitral inflow were recorded from the apical four-chamber view with the guidance of the color Doppler. All Doppler spectra (mitral flow velocity pattern: peak early dias-

tolic filling velocity, E velocity; peak filling velocity at atrial contraction, A velocity; and their ratio: E/A) were recorded and morphologic parameter values were measured during the echocardiographic exam.

Post-mortem STUDY

The rats were anesthetized with ether, killed by cervical dislocation 28 days post-surgery. The pleural effusion was collected by needle aspiration and its volume was measured by gravimetric method (Prunier et al. 2002). This procedure was performed blind by the same investigator and the data were showed as the number of animals with pleural effusion volume > 0.1 ml. Thereafter, the heart, lung and liver were removed and their weights measured and corrected by the body weight of the animal and expressed as heart, lung and liver index respectively.

Histopatology

After macroscopic analysis the heart was perfused with 4% paraformaldehyde in phosphate buffer. The percentage of scar tissue in LV was calculated as described by Spadaro et al. (1980). Briefly, the left ventricle was cut in four slices from apex to base. The slices had approximately the same thickness (1-2 mm) and were named slices A (at the apex), B, C and D, respectively. Histological analysis with tricromo gomory staining was performed in representative sections obtained from slice C, described as the most representative (Spadaro et al. 1980) and confirmed by previous study from our group (unpublished data) of the total infarcted length, using an Axiovert 100 microscope (Zeiss Inc – Germany). Sections stained with tricromo Gomory were recorded with a digital camera and stored for posterior analysis. The digital files were analyzed with the ImageJ software (version 1.27z, National Institute of Health, U.S.A.) which allowed us to measure the infarct size of the left ventricle. The length of the infarcted endocardium is measured, as well as the total perimeter of the endocardial surface. From the ratio of these values, the percentage value of infarcted endocardium is calculated. The same procedure is done for the epicardial surface, obtaining the value of the percentage of infarcted epicardium. From these two values the average percent infarct size was estimated.

EXPERIMENTAL PROTOCOL

Twenty-five normal rats underwent functional assessment (ECG and ECHO) just before the surgical procedures. Thereafter, one group was infarcted ($n = 15$) and other underwent sham-operation ($n = 10$). The sham group was subject to the same surgical procedure as the infarcted group but the LAD was not ligated.

The infarcted group ($n = 15$) was randomized to receive normal drinking water with (CAP group, $n = 9$) or without (INF group, $n = 6$) captopril as described before. The second functional assessment was performed 21 days after surgery and the *post-mortem* study in the end of the study (28 days after surgery) in all groups.

STATISTICAL ANALYSIS

All values are expressed as mean \pm SEM. Differences between electrocardiographic and echocardiographic measurements before and after surgery, and between groups at the same period of observation were evaluated by paired and unpaired Student *t* test respectively. Values were considered different when $P < 0.05$ after Bonferroni's correction. When frequency data were compared, the non-parametric Fischer exact test with the 0.05 level of probability was used.

RESULTS

FUNCTIONAL STUDY

Electrocardiography

The ECG data from SHAM, INF and CAP performed before surgery did not significantly differ between the three groups as showed in Table I. Otherwise, the INF showed significant differences after surgery that resembled a large myocardial infarction. The main changes were: the presence of P-wave > 0.1 mV in 50% of the animals, significant decrease of I-QRS, rightward of the frontal QRS axis ($\hat{A}QRS$), and presence of the Q-wave in L1 in all 6 animals compared with data obtained before surgery.

The ECG tracings from 9 captopril-treated animals (CAP) showed improvement in some parameters. The most outstanding one were: the prevention of P-wave > 0.1 mV in 100% of the animals and attenuation of rightward deviation of the QRS compared with non-treated infarcted rats. Although captopril treatment has

not been efficient to avoid the Q-wave in L1, the Q-wave amplitude was significantly decreased in CAP compared with INF (Table I). The other ECG parameters have not shown any differences between infarcted groups.

Echocardiography

Heart rate was constantly monitored during echocardiography and was not statistically different between all groups, ranging from 250 to 300 beats per minute under anesthesia in both periods of observation. The groups have shown similar echocardiographic values before surgery (Figure 1). However, the INF presented clear signs of severe heart failure 21 days after myocardial infarction. The LA/Ao ratio, LVEDd and E/A ratio (restrictive mitral flow) were increased, and the RWT (relative wall thickness) and EF% (ejection fraction) were decreased compared with the same group before surgery and SHAM 21 after surgery. No major changes were detected in other ECO parameters.

Despite of significant increase in LA/Ao ratio (Figure 1A) and LVDd (Figure 1B) showed by CAP, the PW (Figure 1C) and RWT (Figure 1D) did not change 21 days after infarction. Actually, the captopril-treated group exhibited an attenuation of the left atrial and ventricular dilatation compared with INF after infarction.

Regarding systolic function, the ejection fraction of the captopril-treated rats decreased significantly after infarction, but was still higher than infarcted rats without captopril-treatment (Figure 1E).

The data obtained from Doppler analysis was the most outstanding result found in CAP. This group showed a normal E/A velocity ratio (E/A ratio < 3.0) compared with INF, which exhibited a significantly increase in this parameter 21 days after surgery (Figure 1F).

Post-mortem study

The hearts from the all groups were carefully examined *post mortem* and none were found to present either tissue adherence or abnormal heart position in the thoracic cage that might otherwise lead to misleading interpretation of functional parameters, mainly in the $\hat{A}QRS$ axis.

Table II shows the macroscopic study undertaken in all groups. As expected in severe ventricular damage in this model, heart and lung indexes were increased and

TABLE I
Electrocardiographic parameters recorded from SHAM, INF and CAP just before and 21 days after surgery.
 Data are means \pm SEM. n = number of rats, I-QRS = QRS amplitude index, \hat{A} QRS = frontal QRS axis.
 *P < 0.05 and **P < 0.01 vs. before surgery. #P < 0.05 vs. INF after surgery.

GROUP	TIME	PARAMETERS					
		Heart rate (BPM)	P > 0.1 mV (n)	QRS-index (mV)	\hat{A} QRS (degrees)	Q-wave in L1 (n)	Q-amplitude (L1) (mV)
SHAM (n = 10)	before	277 \pm 8.49	0	0.99 \pm 0.03	69.82 \pm 3.47	0	0
	after	261 \pm 6.08	0	1.17 \pm 0.05	51.31 \pm 21.61	3	0.02 \pm 0.01
INF (n = 6)	before	287 \pm 8.66	0	1.08 \pm 0.1	69.90 \pm 4.40	0	0
	after	293 \pm 11.6	3*	0.57 \pm 0.06**	153.3 \pm 6.01**	6**	0.19 \pm 0.03**
CAP (n = 9)	before	258 \pm 10.3	0	1.11 \pm 0.06	67.75 \pm 2.10	0	0
	after	288 \pm 8.56	0	0.70 \pm 0.11**	124.5 \pm 7.89***#	9**	0.11 \pm 0.03***#

pleural effusion was observed in 100% of the infarcted non-treated rats (INF) during necropsy procedure. In contrast, the captopril-treated rats (CAP) exhibited a decrease in both heart and lung index compared with INF and pleural effusion was absent 28 days after captopril treatment. No changes were observed in liver index.

Histopathology

A gross examination showed a large transmural postinfarct scar in all hearts from INF 28 days after surgery. As showed in Table II and Figure 2, infarct size was decreased in captopril-treated group compared with INF. Figure 2 shows representative cross section of heart slices at papillary level obtained from SHAM, INF and CAP 28 days after surgery.

DISCUSSION

The local and/or circulating renin-angiotensin system (RAS) has long been considered responsible for cardiac remodeling and ventricular dysfunction. In the present report we evaluated the role of RAS on cardiac remodeling and function of rats with myocardial infarction through the early angiotensin converting enzyme (ACE) inhibition. The functional data presented here strengthen the evidences that RAS plays an important role on healing process. The ECG and ECHO parameters of captopril-treated animals improved significantly when compared to non-treated animals, suggesting a directly and/or indirectly involvement of the RAS in the

chain of events that ultimately led to the heart failure. According with functional data, the histological examination confirmed that the block of RAS was effective to decrease the scar tissue formation and left ventricular dilatation, the so-called "cardiac remodeling". Whereas some studies as like Lapointe et al. (2002) supported these findings, several ones showed no marked effects on fibrosis after early treatment with ACE inhibitors compared with non-treated animals (Nelissen-Vrancken et al 1998, Shao et al 1999, Zornoff et al 2000). We hypothesized that controversial results could be explained by differences in selected ACE inhibitor, i.e., pharmacological properties as tissue distribution (Keilani et al. 1995), which could be exploited to inhibit some local renin-angiotensin system while leaving others relatively intact, dose and route of drug administration and differences in infarct size induced by the surgery procedure. Although several works have assessed the effect of ACE inhibitors on infarcted rat hearts, these controversial data show that the real role of renin angiotensin system in heart function and cardiac remodeling in this model is far from clear. The congestive heart failure was also prevented as showed in *post-mortem* study: decrease of lung index and absence of pleural effusion in all captopril-treated rats compared with non-treated rats. Despite of the left atrial increase showed by rats from CAP group after surgery, it was still significantly lower than presented by the INF at the same time. Curiously, the P-wave > 0.1 mV in L1, a electrocardiographic parameter with high frequency of concurrency in

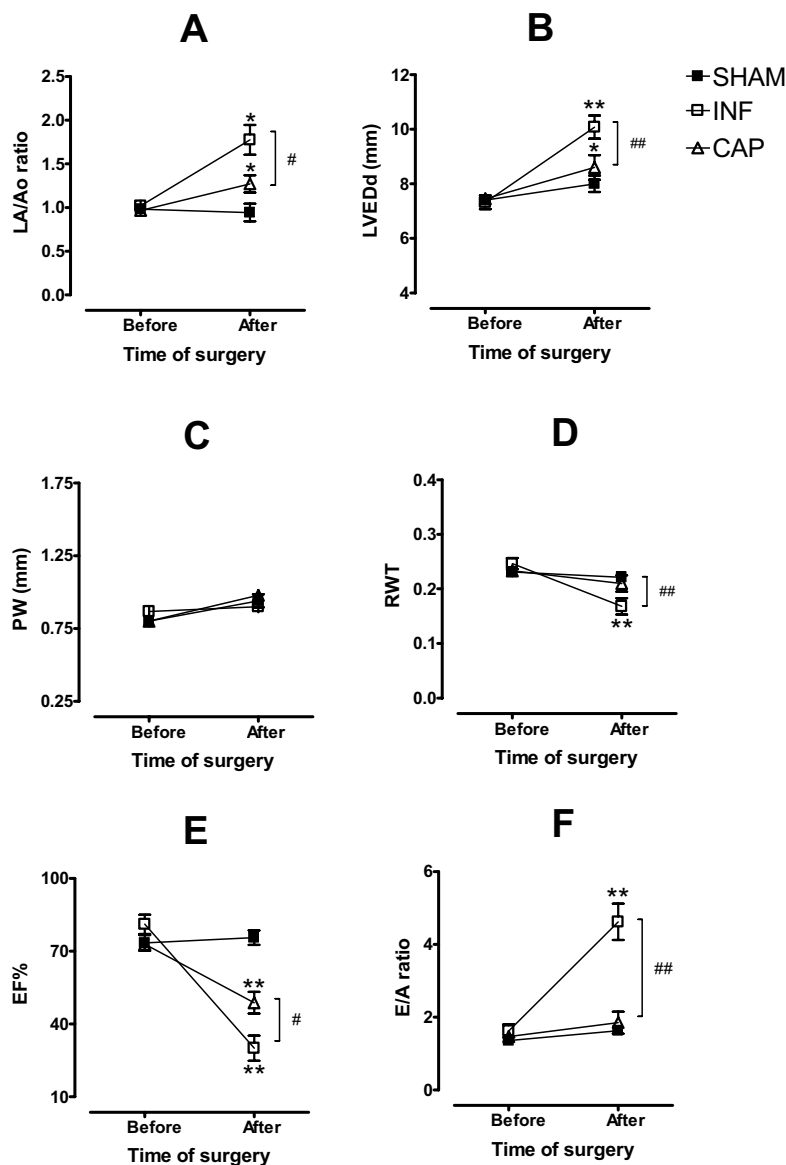


Fig. 1 – Echocardiographic parameters recorded from SHAM, INF and CAP just before and 21 days after surgery. Left atrium-to-aorta diameter (LA/Ao ratio) (A), left ventricular end-diastolic diameter (LVEDd, B), posterior wall thickness in diastole (PW, C), relative wall thickness (RWT, D), ejection fraction (EF%, E) and E/A velocity ratio (E/A ratio, F). Data are means \pm SEM. *P < 0.05 and **P < 0.01 vs. before and #P < 0.05 and ##P < 0.01 CAP vs. INF.

infarcted rats as described herein and in the other study (Santos and Masuda 1991), was not observed in 50% of the treated rats. In a previous study, using the same model of myocardial infarction in 84 rats, the $\hat{A}QRS$ was a sensible ECG parameter altered in the infarct group

(A. Miranda, unpublished data). All infarcted animals had angles greater than 92 degrees and this alteration was present since the first day post-infarction, remaining unaltered until the end of the experiment (28 days after surgery). In addition to $\hat{A}QRS$, the presence of Q wave

TABLE II
Post-mortem study performed in SHAM, INF and CAP 28 days after surgery. Data are means \pm SEM.
n = number of rats. **P < 0.01 vs. SHAM. ##P < 0.01 vs. INF.

GROUP	PARAMETERS					
	Body weight (g)	Cardiac index (mg/g)	Lung index (mg/g)	Liver index (mg/g)	Pleural effusion (n)	Infarct size (%)
SHAM (n=10)	233.20 \pm 4.25	3.17 \pm 0.04	6.90 \pm 0.33	38.60 \pm 1.53	0	0
INF (n=6)	226.0 \pm 3.05	4.69 \pm 0.15**	12.26 \pm 1.10**	40.36 \pm 1.27	6	49.70 \pm 5.24
CAP (n=9)	220.6 \pm 7.96	3.52 \pm 0.10##	7.70 \pm 0.19##	39.12 \pm 0.78	0	22.33 \pm 6.19##

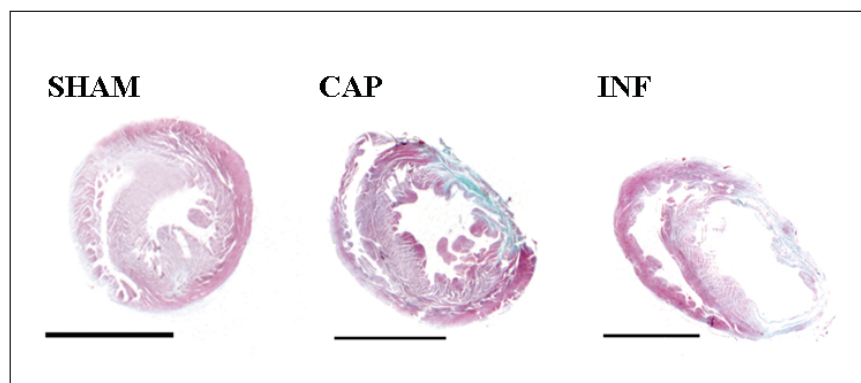


Fig. 2 – Representative cross section of heart slices at papillary level obtained from SHAM, CAP and INF 28 days after surgery. Note that captopril-treated rat showed a smaller scar tissue and left ventricular dilatation than non-treated rat. Bar = 0.5 cm. Tricromo gomori staining.

in L1 was another sensible ECG parameter. There was a correlation between Q-wave measured one day post-surgery and infarct size suggesting that ECG recorded at this time could estimate infarct size. For this reason, we excluded from the present study two animals (one from INF and one from CAP) which showed small (or not showed) Q-wave in L1 one day after infarction. We thought to minimize or abolish the most limitation of infarct model induced by coronary ligation, i.e., the large range of infarct size. Therefore, the fact those captopril-treated rats have presented smaller infarct size than non-treated rats could be attributed to effect of captopril and not to heterogeneity from the model. Regarding the main electrocardiographic signs of the large myocardial infarction in rats, the Q-wave in L1 and rightward deviation of the frontal QRS-axis (Santos and Masuda 1991, Olivares et al. 2004), the treatment with captopril atten-

uated both the amplitude of Q-wave in L1 and $\hat{A}QRS$, even with the presence of Q-wave in 100% of the treated rats. Whether these findings are explained by the small infarct size presented by this group, future studies need to be done. Anyway, the ECG was considered sensible to detect the real contribution of the RAS in development of the heart failure induced by myocardial infarction in rats.

The echodopplercardiography showed that the treatment with captopril starting at early phase of cardiac remodeling and given continuously until the end of experiments, did not fully restored the systolic functional competence of infarcted rat hearts, but normalized diastolic function as suggested by the normalization of the E/A velocity ratio (normal values: $1 < E/A \text{ ratio} < 3$, Olivares et al. 2004). These data are similar to those reported by Litwin et al. (1996). Therefore, data pre-

sented here suggest that RAS was more relevant in a chain of events that led to cardiac remodeling and consequently to diastolic dysfunction than affect directly the systolic performance. This late may result from diverse other mechanism as the loss of cardiac tissue and the increase of the neurohumoral drive involved in the cardiac dysfunction (Francis 1985).

These data suggest that the renin-angiotensin system induces morphologic and functional changes in post-infarcted rat hearts and which can be assessed by non-invasive exams.

ACKNOWLEDGMENTS

The authors are grateful to Prof. Sylvia E.C. Cabezas by the essential technical support and animal care. This study was partially supported by Conselho Nacional de Desenvolvimento Científico e Tecnológico (CNPq).

RESUMO

Nós investigamos as alterações funcionais e morfológicas em corações de ratos infartados, sob o paradigma de inibição da enzima conversora de angiotensina. O infarto do miocárdio foi produzido pela ligadura da artéria coronária esquerda e um grupo falso-operado serviu de controle para o experimento. Os ratos infartados receberam água normal com (grupo CAP) ou sem (grupo INF) captopril. A avaliação funcional foi feita através de eletro (ECG) e ecocardiografia (ECO) momentos antes e 21 dias depois da cirurgia. O ECG dos grupos INF e CAP foram similares e compatíveis com infarto cicatrizado após a cirurgia. As principais diferenças entre os grupos INF e CAP foram: a prevenção do aumento da onda P e a atenuação tanto do desvio do eixo de despolarização ventricular como da amplitude da onda Q no CAP comparado com o INF. O ECO revelou que o tratamento com captopril foi mais efetivo em melhorar o enchimento diastólico do que aumentar a função sistólica. A dilatação e a falência cardíaca congestiva foram observadas apenas no INF. Ambos os grupos infartados exibiram um tecido cicatricial no ventrículo esquerdo, mas no INF esta se mostrou maior do que no CAP (49.7 ± 5.24 vs. 22.33 ± 6.19 respectivamente). Estes dados sugerem que o sistema renina angiotensina produz alterações morfológicas e funcionais em corações de ratos infartados e que estas podem ser detectadas por exames não invasivos.

Palavras-chave: infarto do miocárdio, eletrocardiograma, ecocardiograma, sistema renina-angiotensina, captopril.

REFERENCES

- FRANCIS GS. 1985. Neurohumoral mechanism evolved in congestive heart failure. *Am J Cardiol* 55: 15–21.
- GODY RJ. 1986. Conceptual and therapeutic approaches to inhibition of the renin-angiotensin system in chronic heart failure. *J Cardiovasc Pharmacol* 8: 58–65.
- GOTTLIEB SS, DICKSTEIN K, FLECK E, KOSTIS J, LEVINE TB, LEJEMTEL T AND DEKCOK M. 1993. Hemodynamic and neurohormonal effects of the angiotensin II antagonist losartan in patients with congestive heart failure. *Circulation* 88: 1602–1609.
- JOHNS TNP AND OLSON JB. 1954. Experimental myocardial infarction: a method of coronary occlusion in small animals. *Ann Surg* 140: 675–682.
- KALKMAN EAJ, VAN HAREN P, SAXENA PR AND SCHOE-MAKER, RG. 1999. Early captopril prevents myocardial infarction-induced hypertrophy but not angiogenesis. *Eur J Pharmacol* 369: 339–348.
- KEILANI T, SCHLUETER W AND BATLE D. 1995. Selected aspects of ACE inhibitor therapy for patients with renal disease: impact on proteinuria, lipids and potassium. *J Clin Pharmacol* 35: 87–97.
- KOBER LARS ET AL. 1995. A clinical trial of the angiotensin-converting-enzyme inhibitor trandolapril in patients with left ventricular dysfunction after myocardial infarction. *N Engl J Med* 333: 1670–1676.
- LAPOINTE N, BLAIS-JR C, ADAM A, PARKER T, SIROIS MG, GOSSELIN H, CLEMENT R AND ROULEAU JL. 2002. Comparison of the effects of an angiotensin converting enzyme inhibitor and a vasopeptidase inhibitor after myocardial infarction in rat. *Am Coll cardiol* 39: 1692–1698.
- LITWIN SE, KATZ SE, MORGAN JP AND DOUGLAS PS. 1996. Long-term captopril treatment improves diastolic filling more than systolic performance in rats with large myocardial infarction. *J Am Coll Cardiol* 28: 773–781.
- NELISSEN-VRANCKEN HJMG, KUIZINGA MC, DAEMEN MJAP AND SMITS JFM. 1998. Early Captopril inhibits DNA synthesis in endothelial cells and normalization of maximal coronary flow in infarcted rat hearts. *Cardiovasc Res* 40: 156–164.
- OLIVARES EL ET AL. 2004. Bone marrow stromal cells improve cardiac performance in healed infarcted rat hearts. *Am J Physiol Heart Cir Physiol* 287: 464–470.
- PFEFFER JM, PFEFFER MA AND BRAUNWALD E. 1987. Hemodynamic benefit and prolonged survival with long-

- term captopril therapy in rats myocardial infarction and heart failure. *Circulation* 75: 1149–1155.
- PFEFFER MA, PFEFFER JM, STEUNBERG C AND FINN P. 1985. Survival after an experimental myocardial infarction: beneficial effects of long-term therapy with captopril. *Circulation* 72: 406–412.
- PRUNIER F, GAERTNER R, LOUEDEC L, MICHEL JB, MERCADIER JJ AND ESCOUBET B. 2002. Doppler echocardiographic estimation of left ventricular end-diastolic pressure after MI in rats. *Am J Physiol Heart Circ Physiol* 283: 346–352.
- SANTOS PEB AND MASUDA MO. 1991. The electrocardiogram of rats with an old extensive myocardial infarction. *Brazilian J Med Biol Res* 24: 1173–1177.
- SCHOEMAKER RG, DEBETS JJM, STRUYKER-BOUDIER HAJ AND SMITS JFM. 1991. Delayed but not immediate captopril therapy improves cardiac function in conscious rats, following myocardial infarction. *J Mol Cell Cardiol* 23: 187–197.
- SHAO Q, REN B, ZARAIN-HERZBERG A, GANGULY PK AND DHALLA NS. 1999. captopril treatment improves the sarcoplasmic reticular Ca²⁺ transport in heart failure due to myocardial infarction. *J Mol Cell Cardiol* 31: 1663–1672.
- SIGURDSSON A, HELD P AND SWEDBERG K. 1993. Short- and long-term neurohumoral activation following acute myocardial infarction. *Am Heart J* 126: 1068–1076.
- SPADARO J, FISHBEIN MC, HARE C, PFEFFER MA AND MAROKO PR. 1980. Characterization of myocardial infarcts in the rat. *Arch Pathol Lab Med* 104: 179–183.
- ZORNOFF LAM, MATSUBARA BB, MATSUBARA LS, PAIVA SAR AND SPADARO J. 2000. Early rather than delayed administration of lisinopril protects the heart after myocardial infarction in rats. *Basic Res Cardiol* 95: 208–214.