



Anatomy and morphometric aspects of the trachea of *Saimiri sciureus* Linnaeus, 1758: knowledge for emergency procedures

**LUANE L. PINHEIRO¹, ANA R. LIMA¹, JOSÉ A.P.C. MUNIZ², ALINE IMBELONI²,
EMERSON T. FIORETO³, RODRIGO F. FONTES³, ROSA CABRAL¹ and ÉRIKA BRANCO¹**

¹Laboratório de Pesquisa Morfológica Animal – LaPMA, Universidade Federal Rural da Amazônia,
Av. Perimetral, 2501, 66.077-530 Belém, PA, Brasil

²Centro Nacional de Primatas (CENP), Instituto Evandro Chagas (IEC),
BR 316, Km 7, n 44, 67030-000 Ananindeua, PA, Brasil

³Departamento de Morfologia, Centro de Biologia e Ciências da Saúde, Laboratório de Biologia Celular,
Universidade Federal de Sergipe (UFS), Rua Lagarto, 952, Centro, 49010390 Aracaju, SE, Brasil

Manuscript received on May 9, 2011; accepted for publication on June 22, 2011

ABSTRACT

The aim of this work is to study the morphological characteristics of the trachea of *Saimiri sciureus* through quantification and measurement of the cartilaginous rings, providing information to facilitate the election of more appropriate endotracheal tube, laryngeal mask or tracheostomy tube for anesthetic and emergency procedures, as it is a species of Neotropical primates most commonly used as biological models, and little is known about their morphology. Nine animals were investigated, being 4 adults and 5 young acquired from the Centro Nacional de Primatas (National Primate Center – CENP) - Ananindeua - PA, which died from natural causes and then fixed in aqueous buffered formalin 10%. *Saimiri sciureus* trachea comprises an average of 32.8 incomplete rings and an average length of 3.74 cm in young animals, while in adults it demonstrated an average of 30.25 rings and average length of 3.67 cm. The shape of the light and its proportion varied along the trachea. Endotracheal tube with a diameter the 2.0 – 2.5mm, laryngeal mask number 1.0 or tracheostomy tube neonatal Shiley number 3.0, can be placed in animals weighing 600g – 1.2 Kg. Given the great importance of the species studied, which is widely used as a biological model, the detailing on the morphology and morphometry of tracheal animal studies provides new approaches needed in respiratory emergency, as well as, facilitates the development of future anesthetic protocols.

Key words: emergency procedure, morphology, respiratory system, *Saimiri sciureus*, trachea.

INTRODUCTION

Cebidae constitute the majority of Neotropical primates. Among them, stands out the *Saimiriinae* subfamily, that includes the *Saimiri sciureus* Linnaeus, 1758, which is one of the Brazilian species most used as biological model (Vaughan

1985, Aurichio 1995). Known as Common Squirrel Monkey, it demonstrates a wide geographical distribution and lives in the tops of tall trees, 30 or 40m off the ground, often in troops of hundreds, of individuals. Considered frugivorous and insectivorous, they are slim and agile with a very thick tail. *S. sciureus*, differently to other Neotropical primates, present a well defined seasonality (Dukelow 1978).

Correspondence to: Érika Branco
E-mail: ebranco.ufra@gmail.com

Trachea is a tubular flexible organ, connective extends from the cricoid cartilage of the larynx to its bifurcation dorsally to the cranial region of the heart base, demonstrating a cervical portion and a thoracic portion. The entire trachea must be flexible to allow the movement of head, neck and larynx. This flexibility is possible due to the cartilages which forms individual rings connected by fibroelastic ligaments (Ettinger and Feldman 2004). In histologic terms, the trachea is composed of three layers: mucosa, submucosa and adventitia. The mucosa consists of respiratory epithelia, lamina propria and an elastic lamina. Respiratory epithelia, is a pseudo stratified cylindrical ciliated, and presents several cell types as caliciform cells (Ross et al. 1993).

Lackness of literature on the morphology and anatomy of *Saimiri sciureus* regarding to trachea macroscopic and morphometric aspects, lead us to its investigation. Moreover, these Neotropical primate is considered an important experimental model for biomedical research due to its phylogenetic similarities to human. Thus, this study was designed to facilitate the morphological knowledge of this species' trachea, in order to promote adequate anesthesia and mechanical ventilation, both in experimental procedures and approaches in an emergency.

MATERIALS AND METHODS

We investigated nine animals, four adults and five youngs, males and females, obtained from the Centro Nacional de Primatas (National Primate Center – CENP). The animals died from natural causes, and were fixed in aqueous solution of 10% buffered formaldehyde and storage in the same solution for seven days.

Following thoracotomy, trachea was removed (including the distal end of the larynx) and right and left main bronchi (up to the level of pulmonary hilum). Pieces were dissected by mesoscopic, with the aid of dissection material. Cartilage rings

were counted. A constant number of rings were considered to divide the trachea into 3 regions - cranial, middle and caudal, represented by a 3 parallel drawing lines perpendicular to the major tracheal axis. The third line was limited cranially to the carina, limiting the trachea from the main bronchi (Fig. 1).

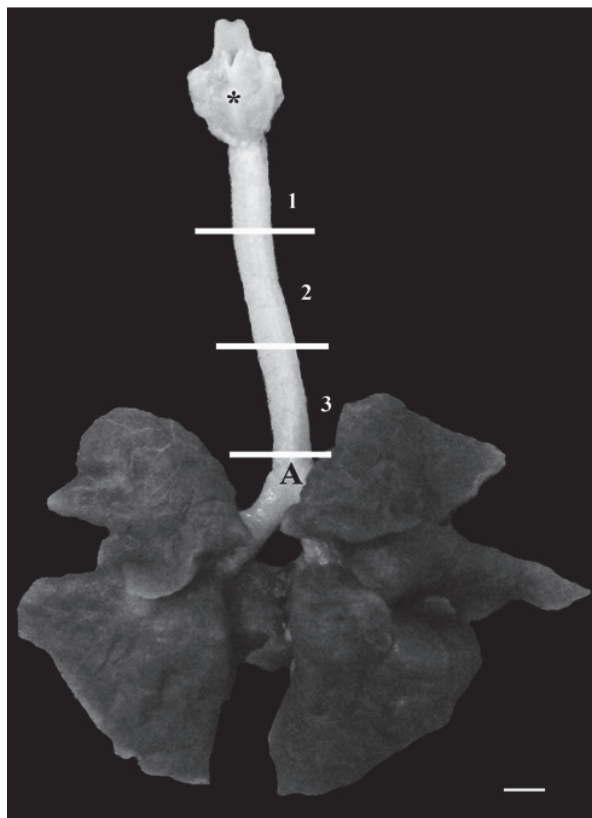


Fig. 1 - Trachea and lung of *S. sciureus* showing larynx (*), carina (A) and demarcation of the cranial portion (1), middle (2) and caudal (3) portions. Scale bar: 1cm.

Tracheal length was measured from the first to the last tracheal ring in cranio-caudal direction; trachea diameters were measured by two axis - height (dorsal-ventral) and width (lateral-lateral) of cranial, caudal and middle regions with the aid of a caliper rule. Following measurements, the tracheae were submitted to histological procedure, embedded in paraffin, and cuts of 5 μ m stained with hematoxylin-eosin.

RESULTS

Saimiri sciureus was observed as a tube of variable length in young and adults, being the trachea of young a little major due to the increase in number of rings. In these individuals, trachea is composed of an average of 32.8 incomplete rings and average length of 3.74 cm. In adults, the trachea showed an average of 30.25 also incomplete cartilaginous rings and average length of 3.67 cm (Table I).

TABLE I
Values for number of rings and length
of the trachea of *Saimiri sciureus*.

	Trachea			
	Number of Rings		Length (cm)	
	Young	Adult	Young	Adult
	36	28	3.50	3.30
	33	30	4.00	3.60
	35	31	3.60	3.90
	30	32	3.80	3.90
	30	-	3.80	-
Average	32.8	30.25	3.74	3.67
SD	6.96	2.18	0.03	0.06
SEM	3.11	1.09	0.01	0.03
CV (%)	21.2	7.23	0.80	1.63

SD: Average Standard deviation; SEM: Standard error of mean; CV%: Coefficient of Variance.

The shape of the light was diverse along the trachea and its proportion varied between youth and adults (Table II and Fig. 2). In young animals the initial segment of the trachea tended to be rounded, becoming oval in middle and caudal regions. In adults, the initial portion tended to be dorsal-ventrally flattened becoming oval with a decreasing diameter.

DISCUSSION

The literature is scarce in relation to morphological descriptions and morphometric aspects of the trachea in non human primates. In general, the trachea of *Saimiri sciureus* in structure resembles to the findings of higher primates or *Anthropoidea*.

Straus and Willian (1931) in their study of adult primates demonstrated an absolute number of cartilage rings what would depend, most probably, to the length of neck. The number of cartilage rings have been described in a range of variation according to sex and within the species: in *Tarsius* Storr, 1780, for example, Burmeister (1846) described 26 rings, while Woollard (1925) about 16; in *Daubentonia* Geoffroy, 1795, Owen (1866) counted 26 rings, as Peters (1852) and Zuckerkandl (1898), 22 rings; in *Lemur* Linnaeus, 1758, however, Peters (1852) described 26 rings and Patten (1899) 32 cartilaginous rings. In our study, *Saimiri sciureus* demonstrated an average of 30.25 rings in adult animals.

Tracheal cartilages do not form complete rings in humans and apes, and smiliar feature was observed in *S. sciureus*, in which they appeared to be incomplete on its dorsal surface, demonstrating a "C" shape. Free borders of these half-rings were united by a membrane of connective tissue and smooth muscle fibers (Straus and Willian 1931).

In some cases the ends of the cartilages were superimposed. However, it was quite evident that the rings were incomplete (Straus and Willian 1931). The overlap is presumably a result of changes after death, a hypothesis reinforced by the observations of Beattie (1927) on the trachea of *Callithrix jacchus* Linnaeus, 1758, when comparing samples fixed in formalin to the living animal that demonstrated a distinct and clear space between the dorsal borders of the rings. This overlap, however, was not observed in our study.

In *Galago* Geoffroy, 1796, and *Nycticebus* Geoffroy, 1812, free borders of the rings have a

TABLE II
Mean values and standard deviation for width (w) and height (h) (cm) in three parts of the trachea of *Saimiri sciureus*.

Trachea												
Region	Cranial				Middle				Caudal			
	Young		Adult		Young		Adult		Young		Adult	
	w	h	w	h	w	h	w	H	w	h	w	h
Average	0.40	0.40	0.45	0.40	0.38	0.40	0.40	0.42	0.36	0.37	0.37	0.40
Minimum	0.30	0.30	0.40	0.30	0.30	0.30	0.30	0.40	0.30	0.30	0.30	0.40
Maximum	0.50	0.50	0.50	0.50	0.40	0.50	0.50	0.50	0.40	0.40	0.40	0.40
CV %	0.07	0.07	0.04	0.08	0.04	0.07	0.08	0.05	0.05	0.04	0.05	0
SEM	0.03	0.03	0.02	0.04	0.01	0.03	0.04	0.02	0.02	0.01	0.02	0

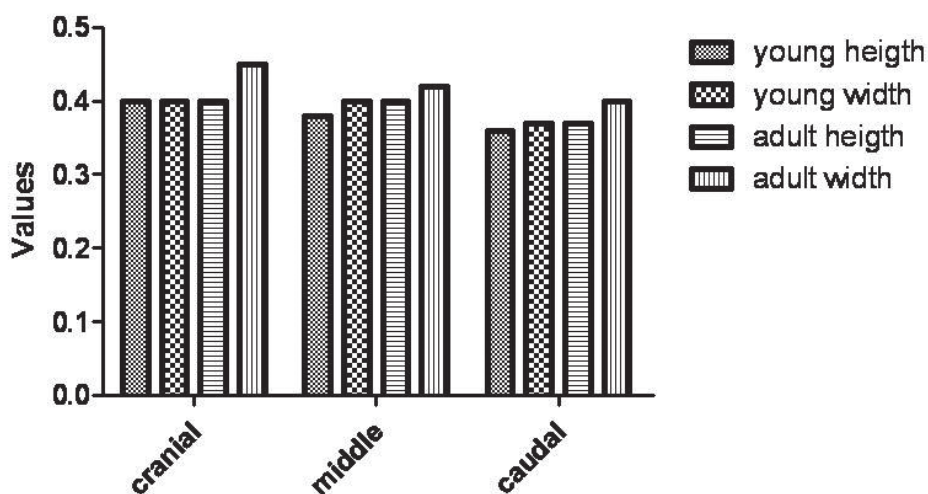


Fig. 2 - Mean values for height and width (cm) corresponding to the diameter of the trachea in three parts of young and adult animals, the cranial, middle and caudal.

tendency to become slightly enlarged or spatula-shaped (Straus and Willian 1931). This condition was not noticeable in *S. sciureus*.

Along *S. sciureus* trachea, the diameter varied in lateral direction, tending to be more oval in the caudal portion resembling to the shape of the light of the trachea in humans, usually circular or oval according to Gamsu and Webb (1982).

Histologically, the epithelium of *S. sciureus* trachea resembled to that of domestic animals, a pseudostratified cylindrical ciliated epithelia with numerous goblet cells producing mucus (Getty 1986) and the human (Ross et al. 1993).

Maintenance of a patient airway may be realized by of an endotracheal tube, laryngeal mask or tracheostomy tube. Intubation of non human primates makes this technically difficult, but becomes relatively easy if we use a small curved blade design to visualized the larynx (Tranquilli et al. 2007). Tubes with a diameter the 2.0 – 2.5mm (Portex®) can be placed in animals weighing 600g – 1.2 Kg.

However, Vilani et al. (2000) say that the laryngeal mask was correctly inserted in the first trial, and its use was an excellent alternative for the patient's adequate ventilation. In addition,

the waken-up occurred quickly after ceasing the administration of the inhalatory anesthetic. For the species studied in given laryngeal mask number 1.0 (NovaMasc[®]). In situations where it is not possible in orotracheal intubation or placement of the laryngeal mask, the alternative to keep the ventilation is the placement of the tracheostomy tube (Fraga et al. 2009). This species should be used neonatal Shiley tracheostomy tube number 3.0 (Mallinckrodt[®]).

ACKNOWLEDGMENTS

We would like to thank the Centro Nacional de Primatas (National Primate Center – CENP) - Ananindeua - PA for donating the animals and the technical support during laboratory investigation. We also thank the Research Fellowship Program - REUNI/UFRA for financial support.

RESUMO

Estudou-se as características morfológicas da traqueia do *Saimiri sciureus* através da quantificação e mensuração dos anéis cartilagosos, a fim de fornecer informações que facilitem a eleição mais adequada de sonda endotraqueal, máscara laríngea ou cânula de traqueostomia para procedimentos anestésicos e de emergência, visto que é uma das espécies de primatas neotropicais mais comumente utilizadas como modelos biológicos e pouco se sabe sobre sua morfologia. Foram utilizados nove animais, sendo quatro adultos e cinco jovens, oriundos do Centro Nacional de Primatas (CENP) - Ananindeua - PA, os quais vieram a óbito por causas naturais e, posteriormente, foram fixados em solução aquosa de formol tamponado a 10%. A traqueia do *Saimiri sciureus* é composta por uma média de 32,8 anéis incompletos nos animais jovens e comprimento médio de 3,74cm, já os adultos apresentam uma média de 30,25 anéis e comprimento médio de 3,67cm. A forma da luz e suas proporções variaram ao longo da traqueia. Sonda endotraqueal com diâmetro de 2,0 – 2,5mm, máscara laríngea número 1,0 ou cânula de traqueostomia neonatal Shiley número 3,0, podem ser colocados em animais pesando 600g - 1,2 K. Dada a grande importância da espécie estudada, que é amplamente utilizada como modelo

biológico, o detalhamento sobre o estudo da morfologia e morfometria traqueal animal, fornece novas abordagens necessárias em emergência respiratória, bem como facilita o desenvolvimento de futuros protocolos anestésicos.

Palavras-chave: procedimentos emergenciais, morfologia, sistema respiratório, *Saimiri sciureus*, traqueia.

REFERENCES

- AURICHIO P. 1995. Primatas do Brasil. São Paulo: Terra Brasilis, 168 p.
- BEATTIE J. 1927. The anatomy of the common marmoset (*Hapale jacchus* Kuhl). Proc Zool Soc Lond 3: 593-718.
- BURMEISTER H. 1846. Beitrage zur naheren Kenntnis der Gattung *Tarsius*. Berlin: G Reimer, 140 p.
- DUKELOW WR. 1978. Reproduction in the squirrel monkey (*Saimiri sciureus*). Rec Adv Primatol 2: 195-200.
- ETTINGER SJ AND FELDMAN E. 2004. Tratado de medicina interna veterinária. 5ª ed., Rio de Janeiro: Guanabara Koogan, 2156 p.
- FRAGA JC, SOUZA JCK AND KRUEL J. 2009. Pediatric tracheostomy. J Pediatr 85: 97-103.
- GAMSU G AND WEBB WR. 1982. Computed tomography of the trachea: normal and abnormal. AJR 139: 321-326.
- GETTY R. 1986. Sisson & Grossman, Anatomia dos animais domésticos. 5ª ed., Rio de Janeiro: Guanabara Koogan, 2000 p.
- OWEN R. 1866. On the aye-aye (*Chiromys madagascarensis*). Trans Zool Soc Lond 5: 33-101.
- PATTEN CJ. 1899. The form and position of the thoracic viscera of the ruffed lemur (*Lemur varius*). Trans Roy Acad Med Ireland 20: 441-473.
- PETERS WCH. 1852. Naturwissenschaftliche Reise nach Mossambique. Zoologie I. Berlin: Saugethiere, 202 p.
- ROSS MH, REITH EJ AND ROMRELL LJ. 1993. Histologia Texto e Atlas. 2ª ed., São Paulo: Panamericana, 779 p.
- TRANQUILLI WJ, THURMON JC AND GRIMM KA. 2007. Lumb & Jones Veterinary Anesthesia and Analgesia. 4ª ed., Iowa: Blackwell Publishing, 1096 p.
- STRAUS JR AND WILLIAN L. 1931. The Form of the Tracheal Cartilages of Primates, with Remarks on the Supposed Taxonomic Importance. J Mammal 12: 281-285.
- VAUGHAN TA. 1985. Order primates. In: VAUGHAN TA (Ed.), J Mammal. Northern Arizona University, Flagstaff, USA, p. 138-143.
- VILANI RGD'OC, VILANI PD'OC, PACHALY JR, MANGINI PR, MACHADO GV AND SUSKO I. 2000. Inhalatory anesthesia with laryngeal mask in a chimpanzee (*Pan troglodytes*). Arch Vet Sci 5: 17-21.
- WOOLLARD HH. 1925. The anatomy of *Tarsius spectrum*. Proc Zool Soc Lond 70: 1071-1184.
- ZUCKERKANDL E. 1898. Zur Anatomie von *Chiromys madagascarensis*. Denkschr d k Akad Wiss Wien Math-Nat 68: 89-200.