



## Intestinal and liver morphometry of the Yellow Tail Tetra (*Astyanax altiparanae*) fed with oregano oil

POLLYANNA M.F. FERREIRA, DÉBORA W. CALDAS, ANA LÚCIA SALARO, SIRLENE S.R.  
SARTORI, JERUSA M. OLIVEIRA, ALEX J.S. CARDOSO and JENER A.S. ZUANON

Departamento de Biologia Animal, Universidade Federal de Viçosa/UFV, Av. PH Rolfs, s/n, 36570-900 Viçosa, MG, Brasil

*Manuscript received on April 6, 2015; accepted for publication on August 20, 2015*

### ABSTRACT

This study aimed to evaluate the effect of oregano oil on the intestinal and liver morphometry of yellow tail tetra, *Astyanax altiparanae*. Fish ( $1.46 \pm 0.09$  g) were kept in a 60-L aquaria, at a stocking density of 0.5 fish L<sup>-1</sup>. Six diets containing varying amounts of oregano oil were evaluated (0.0; 0.5; 1.0; 1.5; 2.0 and 2.5 g of oregano oil kg<sup>-1</sup>). At the end of 90 days, the fish were euthanised. Four intestines and four livers were collected per treatment, which were fixed in Bouin and embedded in resin. For height and width folds, the absorption surface area and thickness of the muscular layer a positive linear effect of oregano oil was observed. A decrescent linear effect on the total number of goblet cells was also observed. For the cytoplasmic percentage of hepatocytes and liver glycogen, a positive linear effect of oregano oil was observed. There was a decreasing linear effect on the percentage of nuclei in the hepatocytes and capillaries. Thus, the oregano essential oil promotes increased absorption areas, modulates the amount of goblet cells involved in protecting the intestinal mucosa and promotes cytoplasmic increase with greater deposition of liver glycogen in yellow tail tetra.

**Key words:** carvacrol, growth promoter, intestinal histology, liver histology, *Origanum vulgare*, thymol.

### INTRODUCTION

Knowledge of gut histology and the digestion and absorption processes of nutrients is essential for understanding fish physiology and nutrition. This knowledge can contribute to the formulation of fish diets and the feeding management for these animals, resulting in increased productivity and reduced production costs (Castro et al. 2002, Faccioli et al. 2014). In addition, the nutrients of diet can directly affect the function and morphology of the liver as an important organ in energy metabolism, emulsification of lipids, and participate in the body's detoxification (Bombardelli et al. 2009).

In order to increase weight gain, improve feed efficiency and reduce mortality of animals, growth promoters have begun to be used in diets (Andreotti and Nicodemo 2004). Essential oils stand out among the growth promoters because they are natural products with good availability, they have fewer side effects, lower levels of toxicity, and better biodegradability. These characteristics make them safe in terms of animal and human health, in addition to being safer for the environment (Kalemba and Kunicka 2003). Possible ways that essential oils affect the body of animals include: 1) controlling pathogens due to the oil's antimicrobial activity (Rao et al. 2006, Sahu et al. 2007, Aly and Mohamed 2010); 2) the antioxidant activity

Correspondence to: Jener Alexandre Sampaio Zuanon  
E-mail: [jenerzuanon@gmail.com](mailto:jenerzuanon@gmail.com)

related to the presence of phenolic compounds, flavonoids and terpenoids (Zheng et al. 2009); 3) improving digestion by stimulating the secretion of digestive enzymes (Lee et al. 2004); and 4) improving absorption capacity of nutrients due to their beneficial effects on the height villus and depth crypt of the intestinal epithelium (Petrolli et al. 2012, Zanini et al. 2012).

One of the essential oils that has a great potential for use as a growth promoter in animal diets is oregano oil (Fukayama et al. 2005), due to its antibacterial (Burt and Reinders 2003, Souza et al. 2006, Oliveira et al. 2009), antifungal (Sartoratto et al. 2004, Cleff et al. 2010), antioxidant (Zheng et al. 2009), anti-inflammatory (Ocaña-Fuentes et al. 2010), anthelmintic (Force et al. 2000) and pro-digestive (Basmacıoğlu Malayoğlu et al. 2010, Hashemipour et al. 2013) properties. The oregano essential oil contains over 34 active compounds, and their properties are attributed to the presence of the main components: carvacrol, thymol, and their precursors  $\gamma$ -terpinene and  $p$ -cymene (Bampidis et al. 2005).

Among the many species of fish, tetras have received significant market interest because they can be used as live bait for sport fishing, like fried snacks, and still have the potential to be canned. The yellow tail tetra (*Astyanax altiparanae*) has a wide distribution in South America (Martinez et al. 2012) and therefore can be raised without the risk of introducing exotic species into the natural environment. This species has a great aquaculture potential due to its high reproductive rate, short production cycle (Porto-Foresti et al. 2005) and omnivorous (Adrian et al. 2001), while having a good acceptance of processed diets. Thus, the present study aimed to evaluate the effects of oregano oil on the intestinal and liver morphometry of yellow tail tetra (*Astyanax altiparanae*).

#### MATERIALS AND METHODS

The Ethics Committee in Animal Use of the Animal Science Department at the University Federal

de Viçosa approved this research project under number 31/2012 on September 4, 2012.

#### ANIMALS AND EXPERIMENTAL CONDITIONS

The experiment was conducted using a completely randomised design with six treatments and four replicates. The treatments consisted of six isonitrogenous (350 g crude protein/kg) and isocaloric (4272 kcal gross energy/kg) diets containing 0.0, 0.5, 1.0, 1.5, 2.0 and 2.5 g/kg of oregano oil.

We used the commercial oregano essential oil (LASZLO® – Brazil), extracted from *Origanum vulgare*. The oregano oil was mixed with soybean oil and then mixed with the other ingredients. The mixture was pelleted, kiln dried with forced ventilation (30°C for 48 h), crushed, sieved and stored in a freezer at -20°C.

Juvenile yellow tail tetra (*Astyanax altiparanae*), weighing an average of  $1.46 \pm 0.09$  g, were kept in 60-L aquaria, equipped with aeration, biological filters, temperature control via heaters and thermostats ( $27 \pm 0.5^\circ\text{C}$ ), at a stocking density of 0.5 fish  $\text{L}^{-1}$  of water. Fish were fed to satiation three times daily for 90 days. At the end of the experiment, the fish were euthanised using excess anaesthetic (clove oil 400 mg  $\text{L}^{-1}$ ) for the collection of samples.

#### HISTOMORPHOMETRY

The histomorphometry was performed by collecting samples from the liver and anterior gut of four fish per treatment. The samples were held in Bouin's fixative solution for 12 hours. The liver and anterior intestine were dehydrated in an ascending series of alcohols, before being embedded in resin. Sections of the tissues were cut on microtomes in a semi-serial fashion, obtaining sections with a thickness 3  $\mu\text{m}$ . Two histological glass slides were prepared from each tissue, with 10 cuts in each.

For the morphometric analysis of the intestine, the sections were stained with toluidine blue. For the histochemical detection of glycoconjugates, the

gut sections were stained with periodic acid-Schiff (PAS) combined with alcian blue (AB), pH 2.5, before being counter-stained with haematoxylin. For the morphometric analysis, the liver sections were stained with haematoxylin and eosin. For the presence of glycogen, the periodic acid-Schiff (PAS) histochemical method was used.

The histological glass slides were photo documented with the Olympus BX53 light microscope with an attached Olympus DP73 camera. In addition, the software Image Pro-Plus® was used. Five pictures per glass slide were obtained from the intestine (20 pictures per treatment) in a 4x objective for morphometry of the folds. For the morphometry of the muscular layer, other five pictures were obtained per glass slide, using a 20x lens. To count the goblet cells, five pictures per glass slide of mucous secretions were obtained using a 20x lens and PAS-AB staining.

In the morphometric analysis of the gut sections, the following variables were measured: folds height (FH) from its base to the apex, measuring three folds of each photo; folds width (FW) using the same three folds at two points, one near the apex and the other near the base; and muscle layer thickness (MLT) from the inner to the outer muscular layer. The absorption surface area (ASA) was calculated according to Kisielinski et al. (2002) formula, adapted as follows:  $ASA = (\text{width of the folds} \times \text{height of the folds}) / (\text{width of the folds} / 2)^2$ .

For the histochemical detection of glycoconjugates in the intestine, the number of goblet cells producing neutral mucin (magenta), the number of cells producing acidic mucin (blue) and the number of cells producing both types of mucins (purple) were counted throughout the area photos. We also calculated the total number of goblet cells from the sum of these different types of cells.

For the liver morphometric analysis, images were superimposed with a grid, that included 255 numbered points (intersections of lines) on the nuclei, cytoplasm and blood capillaries. Based on the

number of matching points, the core percentages of the cytoplasm and blood capillaries were calculated. We measured the diameter of 10 nuclei of each picture, totalling 100 nuclei per treatment. To determine the glycogen density in the cytoplasm of hepatocytes, a scale was established ranging from 1 (low glycogen) to 5 (very high glycogen), based on the staining of glycogen granules. Three independent evaluators issued the scores, and an average of the three scores was used for our analysis.

#### STATISTICAL ANALYSIS

The evaluation of the effects of oregano oil on the morphometric variables was performed using an analysis of variance and a polynomial regression at 5% probability. The Lilliefors test was used to check the assumption of normality of the errors. A Bartlett test was used to assess the homogeneity of variances of the errors among the treatments. To choose the regression model, the significance of the regression coefficient was considered, as well as the behaviour of the variables studied and the magnitude of the coefficient of determination, calculated using the sum of squares regression/square sum treatments.

#### RESULTS

In *Astyanax altiparanae*, the wall of the anterior intestine consisted of four coats: mucosa, submucosa, muscle and serosa. In the inner lining, there were folds formed by the projections of the mucosa and submucosa tunics (Fig. 1a). The mucous tunic of this organ is covered by simple columnar epithelial tissue with brush border and goblet cells. Next to the intestine, there was a significant amount of vascularised pancreatic tissue, indicating that these fish have hepatopancreas beyond the diffuse pancreas (Fig. 2c). For the fold height (FH), fold width (FW), absorption surface area (ASA) and the muscle layer thickness (MLT), there was a linear effect for the oregano oil (Table I, Fig. 2).

**TABLE I**  
**Effects of oregano oil in the diet on the intestinal morphology of yellow tail tetra (*Astyanax altiparanae*).**

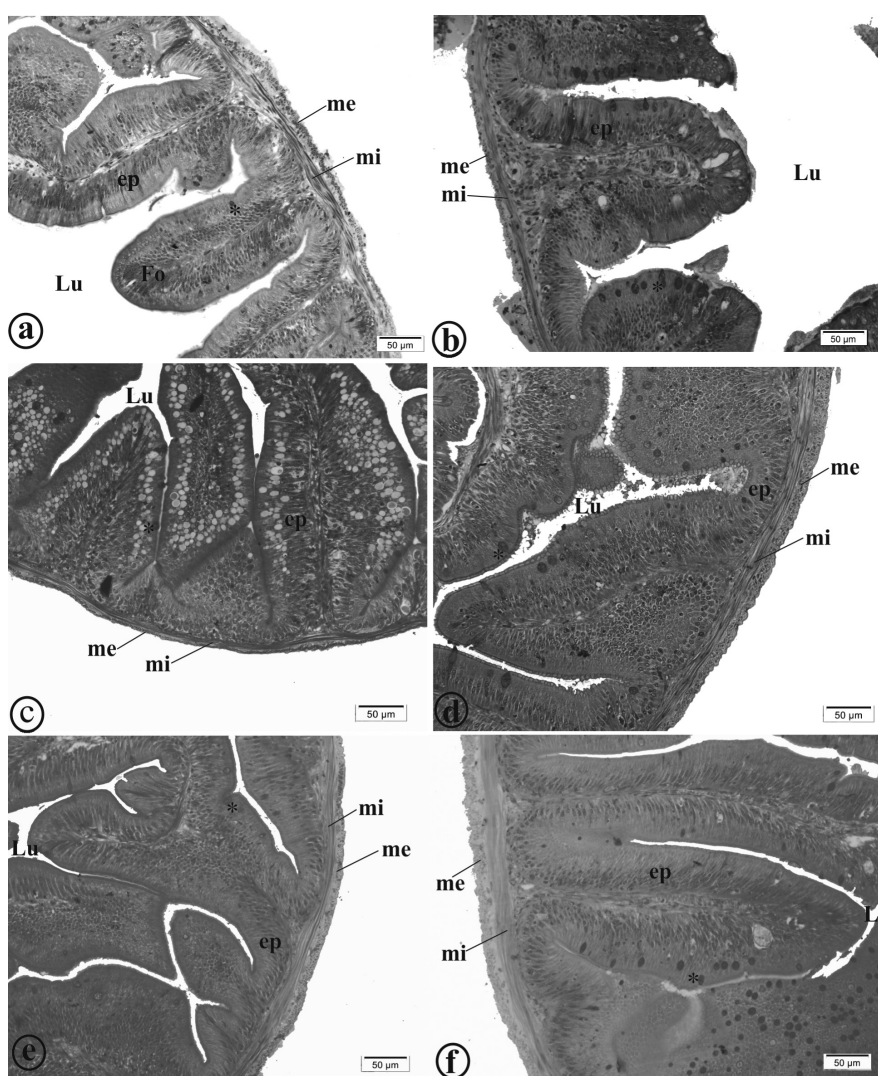
Variables	Oregano oil levels in the experimental diets (g/kg)						CV (%)
	0.0	0.5	1.0	1.5	2.0	2.5	
Fold height (FH) ( $\mu\text{m}$ ) <sup>1</sup>	263.38	288.90	526.79	716.89	544.90	751.62	68.80
Fold width (FW) ( $\mu\text{m}$ ) <sup>2</sup>	107.18	92.79	117.47	138.82	135.74	127.62	33.81
Absorption surface area (ASA) ( $\mu\text{m}^2$ ) <sup>3</sup>	10.15	12.99	18.33	19.78	16.64	23.80	55.68
Muscle layer thickness (MLT) ( $\mu\text{m}$ ) <sup>4</sup>	20.61	23.26	24.89	25.16	30.65	38.25	38.55

<sup>1</sup> FH =  $194.25x + 272.61$ ,  $R^2 = 77.79\%$  ( $p = 0.01$ ).

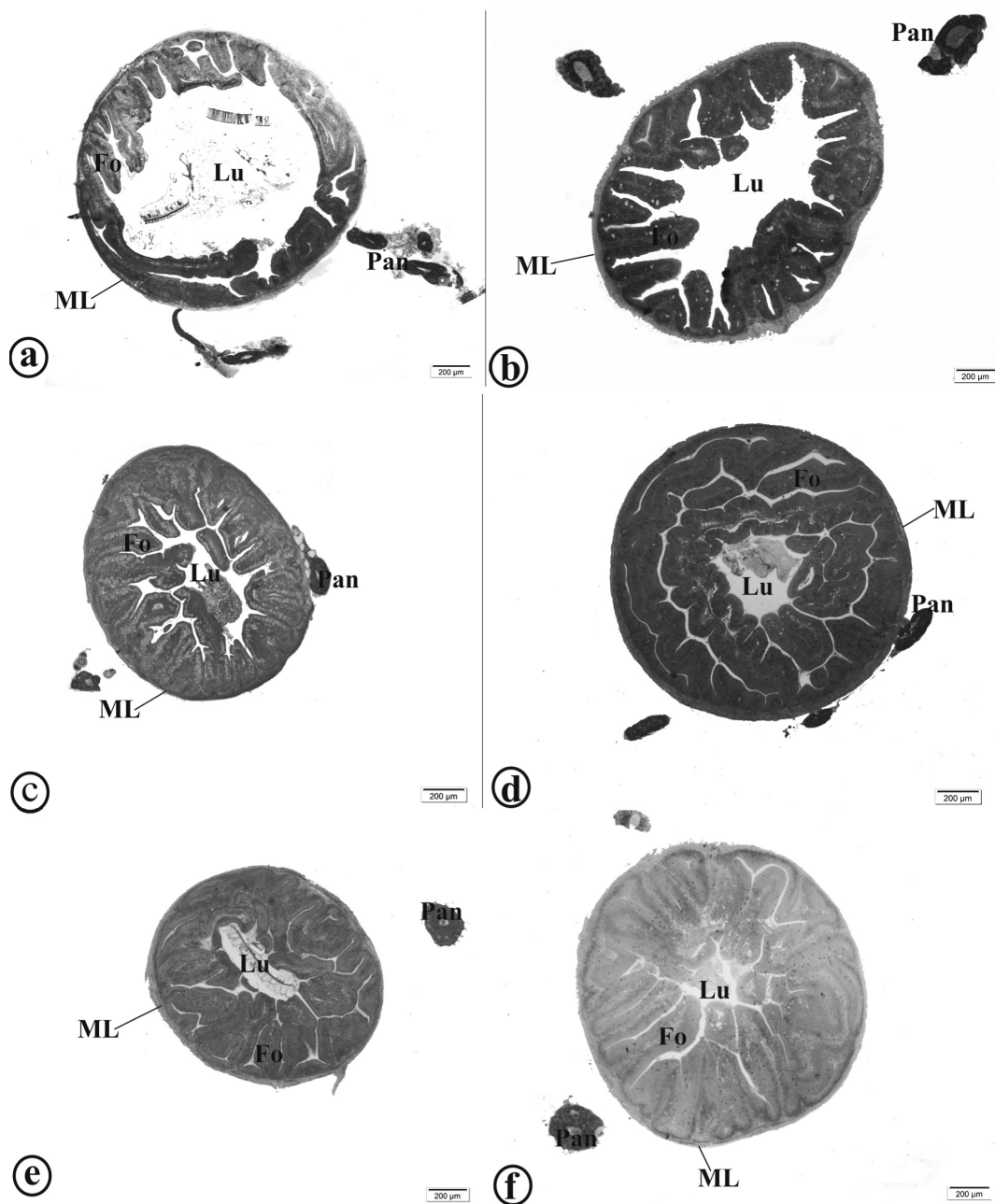
<sup>2</sup> FW =  $14.424x + 101.91$ ,  $R^2 = 57.94\%$  ( $p = 0.01$ ).

<sup>3</sup> ASA =  $4.6099x + 11.188$ ,  $R^2 = 78.2\%$  ( $p = 0.01$ ).

<sup>4</sup> MLT =  $6.3237x + 19.231$ ,  $R^2 = 86.39\%$  ( $p = 0.01$ ).



**Figure 1** - Photomicrographs of structural organization of gut of yellow tail tetra (*Astyanax altiparanae*). **a:** Animals fed  $0.0 \text{ g kg}^{-1}$ ; **b:** Animals fed  $0.5 \text{ g kg}^{-1}$ ; **c:** Animals fed  $1.0 \text{ g kg}^{-1}$ ; **d:** Animals fed  $1.5 \text{ g kg}^{-1}$ ; **e:** Animals fed  $2.0 \text{ g kg}^{-1}$ ; **f:** Animals fed  $2.5 \text{ g kg}^{-1}$ . ep = epithelium; mi = internal muscle; me = external muscle; \* = goblet cell; Lu = lumen; Fo = fold. Staining: toluidine blue. Scale bar =  $50 \mu\text{m}$ . (See the colors in the online version).



**Figure 2** - Intestinal morphology of yellow tail tetra (*Astyanax altiparanae*). **a**: Animals fed 0.0 g kg<sup>-1</sup>; **b**: Animals fed 0.5 g kg<sup>-1</sup>; **c**: Animals fed 1.0 g kg<sup>-1</sup>; **d**: Animals fed 1.5 g kg<sup>-1</sup>; **e**: Animals fed 2.0 g kg<sup>-1</sup>; **f**: Animals fed 2.5 g kg<sup>-1</sup>. ML = muscular layer; Pan = pancreatic tissue, Lu = lumen; Fo = fold. Staining: toluidine blue. Scale bar = 200 μm. (See the colors in the online version).

For the total number of goblet cells, a quadratic effect of the oregano oil was observed, with an estimated value to minimise this variable equal to 1.39 g kg<sup>-1</sup> of oregano oil. There was no significant effect of oregano oil on the number of goblet cells

producing neutral, acid and mixed mucins (Table II, Fig. 3).

The liver histological analysis revealed hepatocytes with large and rounded nuclei, predominantly located in the central region with prominent

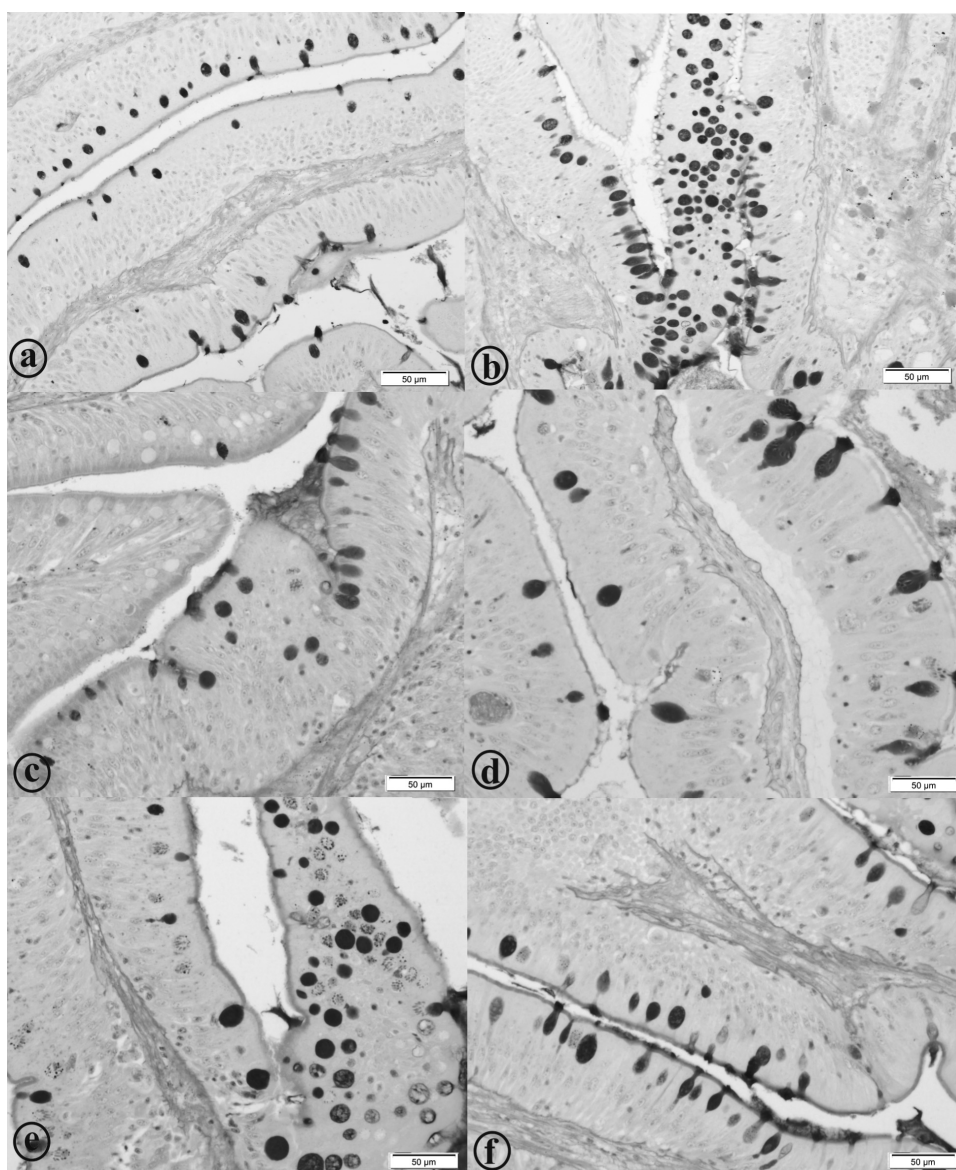
TABLE II

Oregano oil effects on the number of goblet cells of the intestinal mucosa of the yellow tail tetra (*Astyanax altiparanae*).

Variables	Oregano oil levels in the experimental diets (g/kg)						CV (%)
	0.0	0.5	1.0	1.5	2.0	2.5	
Total number of goblet cells (GC) <sup>1</sup>	32.10	38.05	20.70	20.30	30.00	31.25	49.18
Goblet cells secreting mixed mucin (MM) <sup>ns</sup>	25.10	39.85	12.50	14.05	22.90	21.80	75.00
Goblet cells secreting neutral mucin (NM) <sup>ns</sup>	2.90	3.25	5.10	3.45	3.65	6.75	168.18
Goblet cells secreting acidic mucin (AM) <sup>ns</sup>	4.10	3.85	3.10	2.80	3.45	2.70	85.25

<sup>1</sup> CG= 6.05x<sup>2</sup> - 16.771x + 35.832, R<sup>2</sup> = 40.23% (p = 0.01).

<sup>ns</sup> not significant by analysis of variance at 5% probability.



**Figure 3** - Goblet cells of the intestinal mucosa of the yellow tail tetra (*Astyanax altiparanae*). **a**: Animals fed 0.0 g kg<sup>-1</sup>; **b**: Animals fed 0.5 g kg<sup>-1</sup>; **c**: Animals fed 1.0 g kg<sup>-1</sup>; **d**: Animals fed 1.5 g kg<sup>-1</sup>; **e**: Animals fed 2.0 g kg<sup>-1</sup>; **f**: Animals fed 2.5 g kg<sup>-1</sup>. Staining: PAS-AB. Scale bar = 50 µm. (See the colors in the online version).

nucleoli. Among the hepatocytes, sinusoidal capillaries with erythrocytes were observed (Fig. 4). In the liver parenchyma, exocrine pancreatic tissue was also observed. The exocrine pancreas consists of acinar serous cells that are rich in zymogen granules in the cytoplasm (Fig. 4g). These cells are typically basophilic when staining near the bottom, and eosinophilic closer to the apex of the cell. There were no melanomacrophage centres in *A. altiparanae*'s liver.

For the percentage of nuclei and blood capillaries, there was a decreasing linear effect of the oregano oil. For the cytoplasmic percentage of hepatocytes and liver glycogen density, there was an increasing linear effect of oregano oil (Table III, Fig. 4 and Fig. 5). There was no significant effect of oregano oil on the diameter of the nucleus.

#### DISCUSSION

The increased height, width and absorption surface area of the folds may be related to the antimicrobial activity of oregano oil (Burt and Reinders 2003, Sartoratto et al. 2004, Souza et al. 2006, Oliveira et al. 2009, Cleff et al. 2010), causing a reduction of unwanted bacteria (Kirkpinar et al. 2011, Giannenas et al. 2012) and a consequent reduction of mucosal damage. Thus, the reduction in energy expenditure for cell replacement in the intestinal mucosa may have allowed its greater development.

The increased surface area of the pleats promoted by the oregano oil can improve the digestive and absorptive processes, resulting in more efficient use of nutrients, and ensuring improved productive performance of the animals, as noted by Zheng et al. (2009), Ahmadifar et al. (2011), and Ferreira et al. (2014).

The increased thickness of the muscular layer may contribute to increased motility, and consequently, to the elimination of intestinal parasites. Bona et al. (2012), evaluating a plant compound containing the essential oils of oregano, rosemary, cinnamon and red pepper, observed an increase in villus height in the duodenum and jejunum of broilers, and a reduction of the number of *Clostridium perfringens* colonies in the cecum of birds, when compared to the control group.

The mucosa exhibited epithelium interspersed with goblet cells that were PAS-positive (neutral mucin), AB-positive pH 2.5 (acid mucins) and PAS/AB-positive (mixed mucins), with a predominance of cells with mixed secretions (AB/PAS-positive). This indicated the presence of neutral and acidic glycoproteins. In general, the mucus secreted by the goblet cells promotes protection and lubrication necessary to facilitate the passage of food (Carraón et al. 2006). Furthermore, the mucus contains immunoglobulin A (IgA) and peptides with antimicrobial activity, which may facilitate the elimination of pathogens (Hasnain et al. 2013). The

TABLE III  
Oregano oil effects on liver morphometry of yellow tail tetra (*Astyanax altiparanae*).

Variables	Oregano oil levels in the experimental diets (g/kg)						CV (%)
	0.0	0.5	1.0	1.5	2.0	2.5	
Nuclei (%) (NU) <sup>1</sup>	11.06	14.11	8.23	11.06	8.52	10.16	34.96
Cytoplasm (%) (CT) <sup>2</sup>	80.44	76.38	81.14	80.34	85.90	83.03	7.79
Capillaries (%) (CP) <sup>3</sup>	8.43	9.75	10.63	8.04	5.58	6.82	50.83
Diameter nuclei (µm) (DN) <sup>ns</sup>	3.17	3.02	3.27	3.06	3.14	3.17	10.20
Glycogen (Glyc) <sup>4</sup>	2.92	2.42	2.78	3.70	3.44	3.78	31.27

<sup>1</sup> NU = - 1.0248x + 11.8934, R<sup>2</sup> = 19.40% (p = 0.01).

<sup>2</sup> CT = 2.3247x + 78.2995, R<sup>2</sup> = 47.30% (p = 0.01).

<sup>3</sup> CP = - 1.3247x + 9.8647, R<sup>2</sup> = 44.70% (p = 0.01).

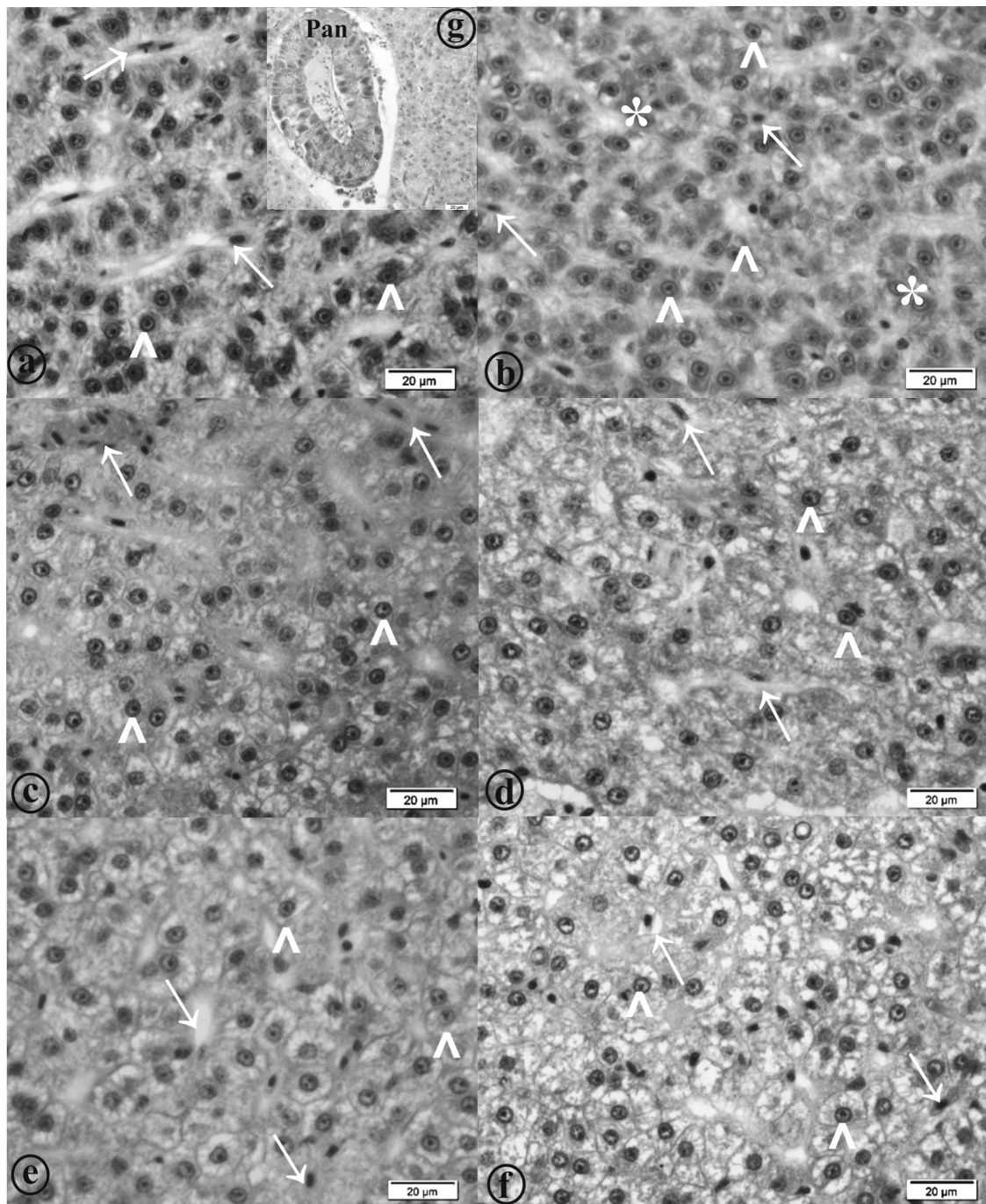
<sup>4</sup> Glyc = 0.4751x + 2.5774, R<sup>2</sup> = 65.44% (p = 0.01).

<sup>ns</sup> not significant by analysis of variance at 5% probability.



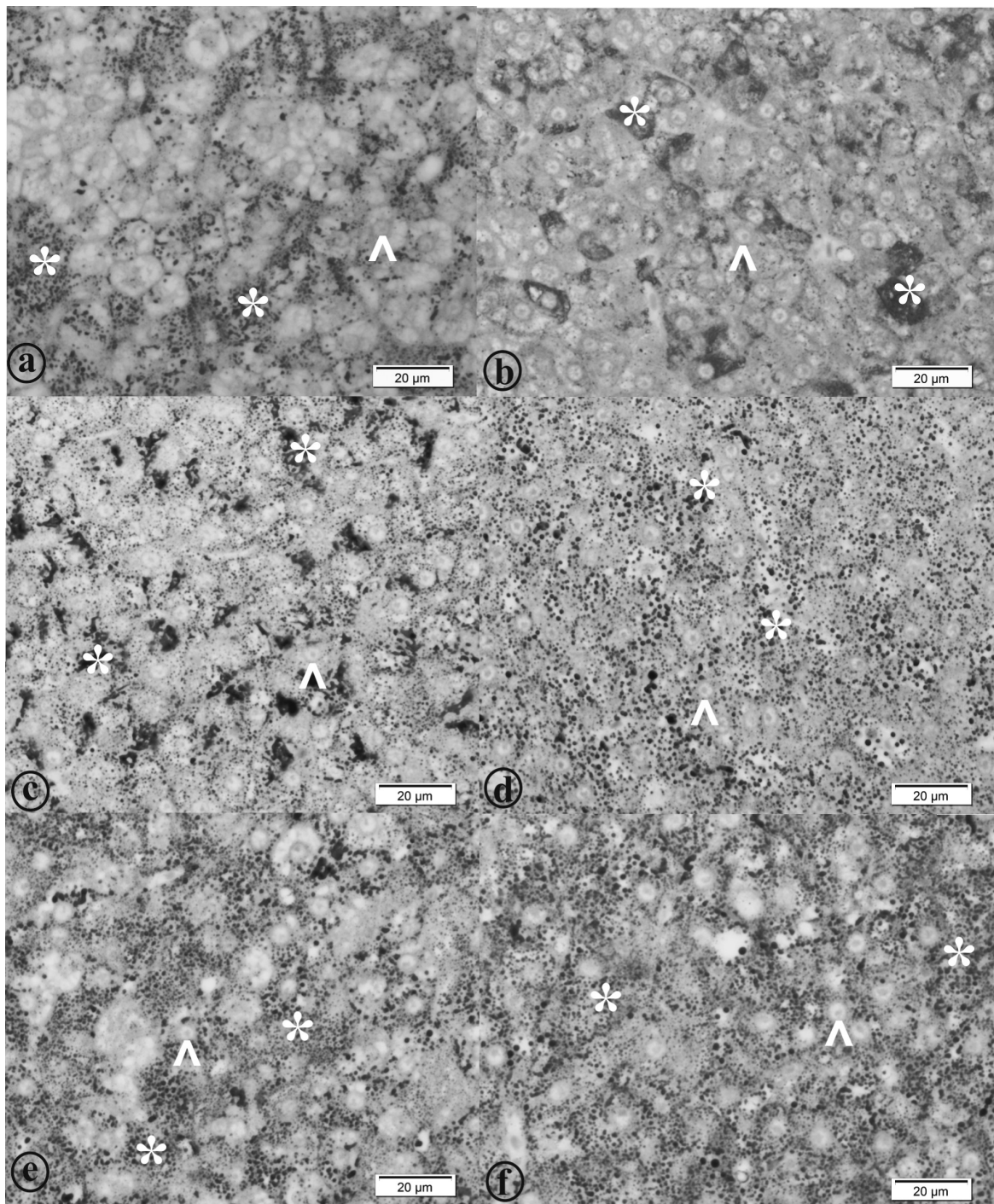
acids glycoconjugates are more resistant to the action of bacterial glycosidases (Makela et al. 1971) and therefore, contribute to increased protection of

the intestinal mucosa, since the neutral mucins can provide the co-factors necessary for the enzymatic breakdown of food nutrients (Anderson 1986).



**Figure 4** - Liver morphometry of yellow tail tetra (*Astyanax altiparanae*). **a-g**: Animals fed 0.0 g kg<sup>-1</sup>; **b**: Animals fed 0.5 g kg<sup>-1</sup>; **c**: Animals fed 1.0 g kg<sup>-1</sup>; **d**: Animals fed 1.5 g kg<sup>-1</sup>; **e**: Animals fed 2.0 g kg<sup>-1</sup>; **f**: Animals fed 2.5 g kg<sup>-1</sup>. Arrow = capillaries; headed arrow = hepatocytes; Pan = hepatopancreas. Staining: haematoxylin and eosin. Scale bar = 20 µm. (See the colors in the online version).





**Figure 5** - Liver morphometry of yellow tail tetra (*Astyanax altiparanae*). **a**: Animals fed 0.0 g kg<sup>-1</sup>; **b**: Animals fed 0.5 g kg<sup>-1</sup>; **c**: Animals fed 1.0 g kg<sup>-1</sup>; **d**: Animals fed 1.5 g kg<sup>-1</sup>; **e**: Animals fed 2.0 g kg<sup>-1</sup>; **f**: Animals fed 2.5 g kg<sup>-1</sup>. Headed arrow = hepatocytes; \* glycogen granules. Staining: PAS. Scale bar = 20 µm. (See the colors in the online version).

The reduction in the total number of goblet cells may indicate that oregano was effective in controlling microorganisms and intestinal para-

sites, since goblet cell hyperplasia can occur with intestinal infections by bacteria, virus and parasites (Kim and Khan 2013). However, further studies

are needed to evaluate the effect of oregano oil on the goblet cells of fish intestines when dealing with microbial and parasitic challenges.

The increase in the percentage of hepatocyte cytoplasm may be associated with hepatic glycogen accumulation, considering that the flavonoids present in oregano oil (naringin and naringerin) have hypoglycaemic activity (Ong and Khoo 2000, Perez-Gutiérrez et al. 2000, Hilaly and Lyoussi 2002). One of the mechanisms flavonoid action is the binding to insulin receptors (Agullo et al. 1997), promoting glucose utilisation in the peripheral tissues and the liver. This supports the increased synthesis of glycogen by hepatocytes. Fernandes et al. (2009) observed an increase in liver glycogen levels in diabetic rats receiving naringerin in the diet. Oliveira et al. (2010) observed that tilapia fed with passion fruit (*Passiflora edulis*) extract showed increased cytoplasmic area and decrease nuclei amounts. These authors attribute the increased glycogen accumulation to the presence of flavonoids (vitexin) in passion fruit extract.

The results of this study demonstrate that oregano essential oil promotes increased absorption surface area and modulates the number of goblet cells involved in protecting the intestinal mucosa. Furthermore, oregano essential oil promotes cytoplasmic increases with greater deposition of liver glycogen in yellow tail tetra, *Astyanax altiparanae*.

#### ACKNOWLEDGMENTS

The authors would like to thank the Fundação de Amparo à Pesquisa do Estado de Minas Gerais (FAPEMIG, Brazil), for funding this project and for granting the first author's scholarship. In addition, the authors are also very grateful the Guabi Nutrição Animal, Brazil, for its support in successfully performing these experiments.

#### RESUMO

O objetivo do presente estudo foi avaliar o efeito do óleo de orégano sobre a morfometria intestinal e hepática do

lambari-do-rabo-amarelo, *Astyanax altiparanae*. Os peixes ( $1,46 \pm 0,09$  g) foram distribuídos em aquários contendo 60 L, na densidade de 0.5 peixes L<sup>-1</sup>. Foram avaliadas seis dietas práticas contendo quantidades variadas de óleo de orégano (0,0; 0,5; 1,0; 1,5; 2,0 e 2,5 g de óleo de orégano kg<sup>-1</sup>). Ao final de 90 dias, os peixes foram eutanasiados. Foi realizada a coleta de 4 intestinos e 4 fígados por tratamento, que foram fixados em Bouin e incluídos em resina. Foi observado efeito linear crescente do óleo de orégano sobre a altura das vilosidades, largura das vilosidades, área de superfície de absorção e espessura da camada muscular. Também foi observado efeito linear decrescente sobre o número total de células caliciformes. Houve efeito linear crescente da porcentagem citoplasmática e glicogênio hepático. Para a porcentagem de núcleos dos hepatócitos e capilares houve efeito linear decrescente. Dessa forma, o óleo essencial de orégano promove o aumento da área de absorção e modula a quantidade de células caliciformes envolvidas na proteção da mucosa intestinal e promove o aumento citoplasmático, com maior deposição de glicogênio hepático no lambari-do-rabo-amarelo.

**Palavras-chave:** carvacrol, promotor de crescimento, histologia intestinal, histologia hepática, *Origanum vulgare*, timol.

#### REFERENCES

- ADRIAN IF, SILVA HBR AND PERETTI D. 2001. Dieta de *Astyanax bimaculatus* (Linnaeus, 1758) (Characiformes, Characidae), da área de influência do reservatório de Corumbá, Estado de Goiás, Brasil. *Acta Sci* 23: 435-440.
- AGULLO G, GAMET-PAYRASTRE L, MANET S, VIALA C, REMESY C, CHAP H AND PAYRASTRE B. 1997. Relationship between flavonoids structure and inhibition of phosphatidylinositol-3-kinase: A comparison with tyrosine kinase and protein kinase on inhibition. *Biochem Pharmacol* 53: 1649-1657.
- AHMADIFAR E, FALAHATKAR B AND AKRAMI R. 2011. Effects of dietary thymol-carvacrol on growth performance, hematological parameters and tissue composition of juvenile rainbow trout, *Oncorhynchus mykiss*. *J Appl Ichthyol* 1: 1-4.
- ALY SM AND MOHAMED MF. 2010. Echinacea purpurea and Allium sativum as immunostimulants in fish culture using Nile tilapia (*Oreochromis niloticus*). *J Anim Physiol Anim Nutr* 94: e31-39.
- ANDERSON TA. 1986. Histological and cytological structure of the gastrointestinal tract of the luderick, *Girella*

- tricuspidata* (Pisces, Kyphosidae), in relation to diet. *J Morphol* 190: 109-119.
- ANDREOTTI R AND NICODEMO MLF. 2004. Uso de Antimicrobianos na Produção de Bovinos e Desenvolvimento de Resistência, 1ª ed., Campo Grande: Embrapa Gado de Corte, 50 p.
- BAMPIDIS VA, CHRISTODOULOU V, FLOROU-PANERI P, CHRISTAKI E, SPAIS AB AND CHATZOPOULOU PS. 2005. Effect of dietary oregano leaves supplementation on performance and carcass characteristics of growing lambs. *Anim Feed Sci Technol* 121: 285-295.
- BASMACIOĞLU MALAYOĞLU H, BAYSAL S, MISIRLIOĞLU Z, POLAT M, YILMAZ H AND TURAN N. 2010. Effects of oregano essential oil with or without feed enzymes on growth performance, digestive enzyme, nutrient digestibility, lipid metabolism and immune response of broilers fed on wheat-soybean meal diets. *Br Poult Sci* 52: 67-80.
- BOMBARDELLI RA, HAYASHI C, NATALI MRM, SANCHES EA AND PIANA PA. 2009. Desempenho reprodutivo e zootécnico e deposição de lipídios nos hepatócitos de fêmeas de tilápia-do-nilo alimentadas com rações de diversos níveis energéticos. *R Bras Zootec* 38(8): 1391-1399.
- BONA TDMM, PICKLER L, MIGLINO LB, KURITZA LN, VASCONCELOS SP AND SANTIN E. 2012. Óleo essencial de orégano, alecrim, canela e extrato de pimenta no controle de *Salmonella*, *Eimeria* e *Clostridium* em frangos de corte. *Pesq Vet Bras* 32(5): 411-418.
- BURT SA AND REINDERS RD. 2003. Antibacterial activity of selected plant essential oils against *Escherichia coli* O157:H7. *Lett Appl Microbiol* 36: 162-167.
- CARRASSÓN M, GRAU A, DOPAZO LR AND CRESPO S. 2006. A histological, histochemical and ultrastructural study of the digestive tract of *Dentex dentex* (Pisces, Sparidae). *Histol Histopathol* 21: 579-593.
- CASTRO EF, FONSECA CC AND MENIN E. 2002. Identificação de células endócrinas no aparelho digestório de *Prochilodus marginatus* Walbaum, 1792 (Pisces, Teleostei, Characiformes, Prochilodontidae). *Arq Ciênc Vet Zool UNIPAR* 5(1): 71-78.
- CLEFF MB, MEINERS AR, XAVIER M, SCHUCH LF, MEIRELES MCA, RODRIGUES MRA AND MELLO JRB. 2010. *In vitro* activity of *Origanum vulgare* essential oil against candida species. *Braz J Microbiol* 41: 116-123.
- FACCIOLI CK, CHEDIDA RA, AMARALA AC, VICENTINIA IBF AND VICENTINI CA. 2014. Morphology and histochemistry of the digestive tract in carnivorous freshwater *Hemisorubim platyrhynchos* (Siluriformes: Pimelodidae). *Micron* 64: 10-19.
- FERNANDES AAH, NOVELLI ELB, JUNIOR AF AND GALHARDI CM. 2009. Effect of Naringerin on Biochemical Parameters in the Streptozotocin-Induced Diabetic Rats. *Braz Arch Biol Technol* 52(1): 51-59.
- FERREIRA PMF, NASCIMENTO LS, DIAS DC, MOREIRA DMV, SALARO AL, FREITAS MBD, CARNEIRO APS AND ZUANON JAS. 2014. Essential Oregano Oil as a Growth Promoter for the Yellowtail Tetra, *Astyanax altiparanae*. *J World Aquacult Soc* 45(1): 28-34.
- FORCE M, SPARKS WS AND RONZIO RA. 2000. Inhibition of enteric parasites by emulsified oil of oregano in vivo. *Phytother Res* 14(3): 213-214.
- FUKAYAMA EH, BERTECHINI AG, GERALDO A, KATO RK AND MURGAS LDS. 2005. Extrato de orégano como aditivo em rações para frangos de corte. *R Bras Zootec* 34(6): 2316-2326.
- GIANNENAS I, TRIANTAFILLOU EL, STAVRAKAKIS S, MARGARONI M, MAVRIDIS S, STEINER T AND KARAGOUNI E. 2012. Assessment of dietary supplementation with carvacrol or thymol containing feed additives on performance, intestinal microbiota and antioxidant status of rainbow trout (*Oncorhynchus mykiss*). *Aquacult* 350-353: 26-32.
- HASHEMIPOUR H, KERMANSHAHI H, GOLIAN A AND VELDKAMP T. 2013. Effect of thymol and carvacrol feed supplementation on performance, antioxidant enzyme activities, fatty acid composition, digestive enzyme activities, and immune response in broiler chickens. *Poult Sci* 92: 2059-2069.
- HASNAIN SZ, GALLAGHER AL, GRENCIS RK AND THORNTON DJ. 2013. A new role for mucins in immunity: Insights from gastrointestinal nematode infection. *Int J Biochem Cell Biol* 45: 364-374.
- HILALY JE AND LYOUSSI B. 2002. Hypoglycemic effect of the lyophilised aqueous extract of *Ajuga iva* in normal and streptozotocin diabetic rats. *J Ethnopharmacol* 80: 109-113.
- KALEMBA D AND KUNICKA A. 2003. Antibacterial and antifungal properties of essential oils. *Curr Med Chem* 10(10): 813-829.
- KIM JJ AND KHAN WI. 2013. Goblet Cells and Mucins: Role in Innate Defense in Enteric Infections. *Pathogens* 2: 55-70.
- KIRKPINAR F, BORA ÜNLÜ H AND GÜVEN ÖZDEMİR. 2011. Effects of oregano and garlic essential oils on performance, carcass, organ and blood characteristics and intestinal microflora of broilers. *Livest Sci* 137: 219-225.
- KISIELINSKI K, WILLIS S, PRESCHER A, KLOSTERHALFEN B AND SCHUMPELICK V. 2002. A simple new method to calculate small intestine absorptive surface in the rat. *Clin Exp Med* 2: 131-135.
- LEE KW, EVERTS H AND BEYNEEN AC. 2004. Essential oils in broilers nutrition. *Int J Poult Sci* 3(12):738-752.
- MAKELA V, KORHONEN LK AND LILIUS G. 1971. Carbohydrate-rich compounds in the colonic mucosa of man. 1. Histochemical characteristics of normal and adenomatous colonic mucosa. *Cancer* 27: 120-127.

- MARTINEZ ERM, ALVES AL, SILVEIRA SM, FORESTI F AND OLIVEIRA C. 2012. Cytogenetic analysis in the incertae sedis species *Astyanax altiparanae* Garutti and Britzki, 2000 and *Hypheosbrycon eques* Steindachner, 1882 (Characiformes, Characidae) from the upper Paraná river basin. *Comp Cytogen* 6(1): 41-51.
- OCAÑA-FUENTES A, ARRANZ-GUTIÉRREZ E, SEÑORANS FJ AND REGLERO G. 2010. Supercritical fluid extraction of oregano (*Origanum vulgare*) essentials oils: Anti-inflammatory properties based on cytokine response on THP-1 macrophages. *Food Chem Toxicol* 48: 1568-1575.
- OLIVEIRA JLTM, DINIZ MFM, LIMA EO, SOUZA EL, TRAJANO VN AND SANTOS BHC. 2009. Effectiveness of *Origanum vulgare* L. and *Origanum majorana* L. Essential oils in Inhibiting the Growth of Bacterial Strains Isolated from the Patients with Conjunctivitis. *Braz Arch Biol Technol* 52(1): 45-50.
- OLIVEIRA RHF, PEREIRA-DA-SILVA EM, BUENO RS AND BARONE AAC. 2010. O extrato de maracujá sobre a morfometria de hepatócitos da tilápia do Nilo. *Cienc Rural* 40(12): 2562-2567.
- ONG KC AND KHOO HE. 2000. Effects of myricetin on glycemia and glycygen metabolism in diabetic rats. *Life Sci* 67: 1675-1705.
- PEREZ-GUTIÉRREZ RM, CERVANTES CH, ZAVALA SMA, SANCHEZ AJ, PEREZ GS AND PEREZ GC. 2000. Isolation and hypoglycemic activity of 5, 7, 3'-tryhydroxy-3,6,4'-trimetoxiflavona from *Brickellia veronicaefolia*. *Phyto-medicine* 7: 25-29.
- PETROLI TG, ALBINO LFT, ROSTAGNO HS, GOMES PC, TAVERNARI FC AND BALBINO EM. 2012. Herbal extracts in diets for broilers. *R Bras Zootec* 41(7): 1683-1690.
- PORTO-FORESTI F, CASTILHO-ALMEIDA RB AND FORESTI F. 2005. Biologia e criação do lambari-do-rabo-amarelo (*Astyanax altiparanae*). In: Baldissero B and Gomes LC (Eds), *Espécies nativas para piscicultura no Brasil*, Santa Maria: Editora UFSM, Santa Maria, RS, p. 105-120.
- RAO YV, DAS BK, JYOTYRMAYEE P AND CHAKRABARTI R. 2006. Effect of *Achyranthes aspera* on the immunity and survival of *Labeo rohita* infected with *Aeromonas hydrophila*. *Fish Shellfish Immunol* 20: 263-273.
- SAHU BS, DAS BK, MISHRA BK, PRADHAN J AND SARANGI N. 2007. Effect of *Allium sativum* on the immunity and survival of *Labeo rohita* infected with *Aeromonas hydrophila*. *J Appl Ichthyol* 23: 80-86.
- SARTORATTO A, MACHADO ALM, DELARMELENA C, FIGUEIRA GM, DUARTE MCT AND REHDER VLG. 2004. Composition and antimicrobial activity of essential oils from aromatic plants used in Brazil. *Braz J Microbiol* 35: 275-280.
- SOUZA EL, STAMFORD TLM AND LIMA EO. 2006. Sensitivity of spoiling and pathogen food-related bacteria to *Origanum vulgare* l. (Lamiaceae) essential oil. *Braz J Microbiol* 37: 527-532.
- ZANINI SF, SILVA MA, PESSOTTI BMSS, COLNAGO GL, NUNES LC AND RODRIGUES MRA. 2012. Suplementação de vitamina E e/ou de óleo essencial de aroeira na dieta de frangos de corte sobre o desempenho e morfometria intestinal. *Arch Vet Sci* 17(1): 76-81.
- ZHENG ZI, TAN JYW, LIU HY, ZHOU XH, XIANG X AND WANG KY. 2009. Evaluation of oregano essential oil (*Origanum heracleoticum* L.) on growth, antioxidant effect and resistance against *Aeromonas hydrophila* in channel catfish (*Ictalurus punctatus*). *Aquacult* 292: 214-218.