

Application of genetic testing to define the surgical approach in a sporadic case of multiple endocrine neoplasia type 1

Aplicação de teste genético para definição da conduta cirúrgica num caso esporádico de neoplasia endócrina múltipla do tipo 1

Cesar Luiz Boguszewski¹, Leila Caroline Bianchet¹, Salmo Raskin², Luiz M. Nomura³, Luis Alencar Borba⁴, Teresa Cristina Santos Cavalcanti⁵

SUMMARY

We report the use of a genetic test for therapeutic decision making in a case of primary hyperparathyroidism associated with Cushing's disease (CD). A 20-year-old woman was evaluated for gradual weight gain, asthenia, muscle pain, and hypertension. Biochemical and radiologic tests confirmed CD and she underwent transsphenoidal surgery. Immunohistochemistry of the microadenoma was positive for adrenocorticotrophic hormone (ACTH). On follow-up, hypercalcemia with high parathyroid hormone (PTH) levels was detected, associated with nephrolithiasis and low bone mineral density in the spine and hip. Parathyroid scintigraphy showed tracer uptake in the inferior region of the left thyroid lobe, and cervical ultrasound showed a heterogeneous nodule in the same area, suggestive of a parathyroid adenoma (PA). Genetic testing detected mutation in the *MEN 1* gene and total parathyroidectomy with the implantation of a fragment of one gland in the forearm was performed. Pathology showed a PA and 3 normal parathyroid glands, without hyperplasia, despite the diagnosis of MEN 1. This case illustrates the role of genetic testing in defining the therapeutic approach for sporadic MEN 1. *Arq Bras Endocrinol Metab.* 2010;54(8):705-10

SUMÁRIO

Relatamos o uso de teste genético para decisão terapêutica em um caso de hiperparatiroidismo primário associado com doença de Cushing (DC). Uma jovem de 20 anos foi avaliada por ganho de peso gradual, astenia, mialgias e hipertensão. Os exames complementares confirmaram DC e ela foi submetida à cirurgia transesfenoidal. A análise imuno-histoquímica do microadenoma foi positiva para hormônio adrenocorticotrófico (ACTH). No seguimento, a paciente apresentou hipercalcemia com níveis elevados de hormônio de paratireoide (PTH), nefrolitíase e densidade mineral óssea baixa em coluna e fêmur. A cintilografia de paratireoide mostrou captação do traçador em região inferior do lobo esquerdo da tireoide e a ecografia cervical revelou nódulo heterogêneo na mesma área, sugestivo de adenoma da paratireoide (AP). O teste genético detectou mutação no gene *MEN 1* e ela foi submetida à paratireoidectomia total com implante de fragmento de uma das glândulas no antebraço. A patologia confirmou AP e as outras três glândulas normais, sem hiperplasia, apesar do diagnóstico de MEN 1. Esse caso ilustra a importância do teste genético para definir a abordagem terapêutica em um caso esporádico de MEN 1.

Arq Bras Endocrinol Metab. 2010;54(8):705-10

INTRODUCTION

Multiple endocrine neoplasia type 1 (MEN 1) is an autosomal dominant disorder character-

ized by the occurrence of tumors of the parathyroid, enteropancreatic neuroendocrine tissues, and anterior pituitary. It is a rare disease with an estimated

¹ Endocrine Division (SEMPR), Department of Internal Medicine, Hospital das Clínicas, Universidade Federal do Paraná (UFPR), Curitiba, PR, Brazil
² Genetika Laboratory, Curitiba, PR, Brazil
³ Oncology Division, Nossa Senhora das Graças Hospital, Curitiba, PR, Brazil
⁴ Department of Neurosurgery, UFPR, Curitiba, PR, Brazil
⁵ Department of Pathology, UFPR, Curitiba, PR, Brazil

Correspondence to:

Cesar Luiz Boguszewski
 Departamento de Clínica Médica, SEMPR, Universidade Federal do Paraná
 Av. Agostinho Leão Junior, 285
 80030-110 – Curitiba, PR, Brazil
 cesarluiz@hc.ufpr.br

Received on Jul/31/2010
 Accepted on Oct/27/2010

prevalence of 0.01-2.5 cases per 1,000 individuals (1-3). The presentation of MEN 1 occurs within the context of previously identified kindred, in a newly ascertained individual with advanced disease who might be the proband of new kindred, or an example of a *de novo* mutation. In the latter case, it might be challenged to establish the diagnosis. The familial forms are the most common and require a first degree relative that presents the tumor in at least one of the three most frequently affected tissues. The sporadic forms account for 8%-14% of the affected patients and it is usually diagnosed in advanced stages. Comparing tumors in the same tissues, they usually appear one to two decades earlier in the familial forms compared to the sporadic ones (1-3).

The *MEN 1* gene was identified in 1997 and consists of 10 exons encoding a 610-amino acid protein known as menin (4). Menin is predominantly a nuclear protein that has roles in transcriptional regulation, genome stability, cell division, and proliferation (5). *MEN 1* mutations are scattered in and around the open reading frame of menin and may include nonsense, missense and donor-splice mutations, as well as small deletions and small insertions. These mutations usually predict protein absence or truncation (the “first hit”), which in combination with a somatic or postnatal loss of the other copy of *MEN 1* (the second hit, frequently involving the loss of a large segment or all of chromosome 11) in one cell, initiate neoplastic clonal expansion from that cell (1).

Pituitary adenoma occurs in about one third of MEN 1 cases, whereas the frequency of MEN 1 in cases of apparently sporadic pituitary tumor is usually below 5% (1,6,7). Cushing’s syndrome in MEN 1 can be caused by a pituitary adenoma, an ectopic tumor or rarely by an adrenal adenoma (1,6-9). Cushing’s disease due to ACTH oversecretion accounts for only 5% of the pituitary tumors involved in MEN 1 (6). On the other hand, hyperparathyroidism (HPT) is the most common hormonal manifestation of MEN 1 (1,2), although only 1%-5% of the cases of primary HPT are related to the syndrome (10). In comparison with sporadic cases, HPT in MEN 1 has an earlier age of presentation and a different pathology, characterized by a multiglandular disease (1-3). Enteropancreatic neuroendocrine tumors such as gastrinomas, insulinomas and glucagonomas, occur

in about 60% of the patients; they are usually multiple, can secrete various hormones and can be malignant, although a proportion of these tumors are silent and do not produce symptoms (1-3).

Genetic testing has been advocated to identify *MEN 1* carriers of the MEN 1 families for earlier detection of tumors. Analysis of the *MEN 1* gene has also been recommended for therapeutic decision making such as in cases of apparently sporadic tumors (1). The aim of the present Case Report was to demonstrate the importance of genetic testing for therapeutic decision making in a sporadic case of MEN 1, manifested by Cushing’s disease and subsequent primary HPT.

SUBJECT AND METHODS

Case report

A 20-year-old female patient was initially evaluated in May, 2008 due to a progressive weight gain of 20 kg (representing 37% of her previous body weight) during the two previous years, especially in the last 9 months. In addition, she had complaints of asthenia, localized muscle pain in the lower limbs, and referred previous detection of high blood pressure. She had been taking oral hormonal contraceptives for two years. The positive findings in her physical examination were a mild hypertension (130/90 mmHg), body mass index (BMI) of 30.8 kg/m² and a centripetal body fat distribution. Moon face, red-purple striae and “buffalo hump” were not observed. Laboratorial investigation tests revealed urinary free cortisol of 489.6 µg/24 hours (reference range 42-473 µg), serum cortisol level of 21.2 µg/dL (585 nmol/L) after 1 mg-dexamethasone (normal suppression below 5 µg/dL or 140 nmol/L), and serum ACTH level of 43.8 pg/mL (9.6 pmol/L) (reference range 10-52 pg/mL or 2-11 pmol/L). Pituitary magnetic resonance imaging (MRI) identified a hypodense lesion with 8 mm in the larger diameter associated with a pituitary stalk deviation, compatible with pituitary microadenoma. She underwent a transsphenoidal surgery for resection of the lesion in June, 2008, and the pathologic and immunohistochemical analysis of the tumor – which was positive only for ACTH and negative for all the other pituitary hormones – confirmed the diagnosis of corticotropinoma. The patient developed adrenal insuff-

iciency two weeks after surgery, with serum cortisol levels $< 1 \mu\text{g/dL}$ ($< 27.6 \text{ nmol/L}$), and prednisone was initiated. Glucocorticoid replacement therapy was gradually withdrawn, her symptoms improved, she lost 13 kg and her serum and urinary cortisol levels normalized.

Two months after the transsphenoidal surgery, a blood test showed calcium levels of 11 mg/dL (2.85 mmol/L). Subsequent evaluation confirmed hypercalcemia in association with high serum levels of PTH (367.5 ng/L ; reference range $1\text{-}84 \text{ ng/L}$). Phosphatemia and calciuria were normal, and 25OH-vitamin D levels were low (11.3 ng/mL or 28.2 nmol/L). Parathyroid scintigraphy showed tracer uptake in the topography of the inferior region of the left thyroid lobe, and a cervical ultrasound showed a solid, irregular, and heterogeneous nodule of $21 \times 9 \times 10 \text{ mm}$ in the same area, suggestive of a parathyroid adenoma. Other relevant findings were a bilateral nephrolithiasis in the abdominal ultrasonography and a low bone mineral density at the lumbar spine (0.759 g/cm^2 ; Z-score = -2.4 SD), femoral neck (0.564 g/cm^2 ; Z-score = -2.6 SD), and total femur (0.716 g/cm^2 ; Z-score = -1.9 SD).

When the primary HPT was confirmed, just after the diagnosis and treatment for Cushing's disease, the existence of a MEN 1 was strongly considered, but in a sporadic form, since her family history was negative for typical MEN 1 manifestations. In this case, as the disease is multiglandular, parathy-

roidectomy with the implantation of a fragment of one gland in the forearm would be indicated. On the other hand, if the diagnosis of MEN was not confirmed, adenomectomy would probably be the best choice (11,12). At this time, mutational analysis was performed by sequencing the entire coding region of the *MEN 1* gene (Genetika Laboratory, Curitiba, Brazil). A frameshift c1561dupC mutation at the exon 10 of the *MEN 1* gene was found, predicting a truncated form of menin which was identified (Figure 1). On July, 2009, with the diagnosis of sporadic MEN 1, the patient was submitted to total parathyroidectomy with immediate implantation of a small fragment of one parathyroid gland in the nondominant forearm. Pathology confirmed the presence of a parathyroid adenoma, while the remaining three parathyroid glands were histologically normal, with no evidence of hyperplasia or neoplasia (Figure 2). One year after surgery, she has maintained normal calciuria and serum levels of calcium (last result = 9.5 mg/dL or 2.46 mmol/L) and PTH (last result = 56.6 ng/L) within the normal range on treatment with 1.500 mg of calcium per day and 10.000 IU of vitamin D per week. The only complication encountered during follow-up was the cardiologic diagnosis of Wolff-Parkinson-White syndrome, for which a catheter ablation was performed. Thus far, there has been no clinical, biochemical or radiologic evidence of any enteropancreatic neuroendocrine tumor.

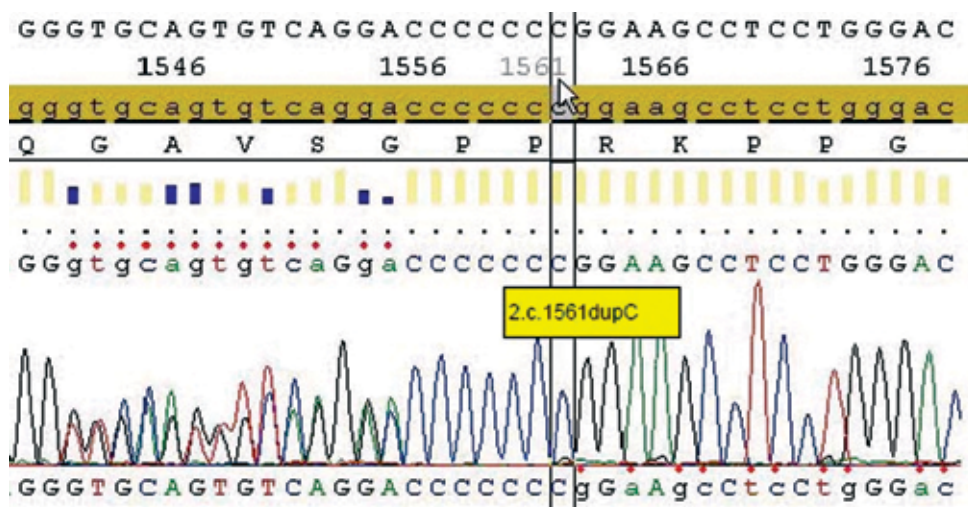


Figure 1. Electropherogram showing the c1561dupC mutation characterized by the insertion of an additional cytosine at position 1561 of the *MEN 1* gene predicting a truncated form of menin. The c.1561dupC mutation at exon 10 results in a frameshift, and is predicted to create a novel stop codon (TGA instead of normal AGG; p.Arg521fsX15) 15 codons after the codon the mutation occurs in.

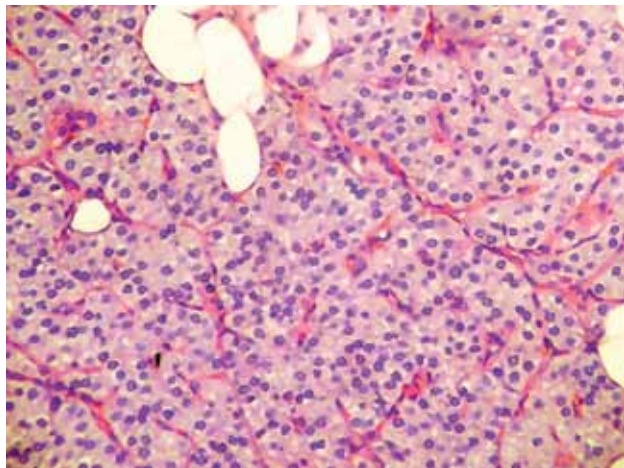


Figure 2. Histopathology slide demonstrating parathyroid gland with sheet-like arrangement of monotonous parathyroid cells (hematoxylin and eosin 20X).

DISCUSSION

Early identification of the manifestations, improvements in diagnostic techniques and therapeutic approaches has had a favorable impact on the morbidity and mortality associated with MEN syndromes. In the classical MEN 2A – which is clinically characterized by the presence of medullary thyroid carcinoma (MTC), bilateral pheochromocytoma and primary HPT; in MEN 2B, where MTC is associated with pheochromocytoma and mucosal neuroma; and in familial MTC, genetic testing detects nearly 100% of *RET* proto-oncogene mutation carriers and is now considered the standard of care for all first degree relatives of patients with newly diagnosed MTC. Each variant of MEN 2 results from a different *RET* mutation, with a good genotype-phenotype correlation, allowing the design of good guidelines for timing of prophylactic thyroidectomy and extent of surgery based on risk levels (13).

Unlike the situation in MEN 2, there is no mutation-guided intervention and no clear genotype-phenotype relations for MEN 1, where more than 20 different combinations of endocrine and nonendocrine tumors have been reported (1,2). Although screening for endocrine tumor manifestations in definite or probable *MEN 1* mutation carriers seems likely to help improve management, this has not been proven. Nevertheless, genetic testing in MEN 1 is recommended, among other clinical situations, in sporadic cases with two or more MEN 1-related tumors (1,2). However, patients with certain spo-

radic tumor combinations, such as parathyroid and somatotroph or corticotroph, as in this reported young female patient, may have unexpectedly low frequency of *MEN 1* mutation (14). The reasons for that include two kinds of tumors with high natural incidence in older subjects developed by chance, another familial tumor syndrome with low penetrance, as previously observed in familial acromegaly with primary hyperparathyroidism by mutation of another gene, or a somatic mutation during early embryonic stages (14). Taken together, the data demonstrate that despite the high clinical suspicion of MEN 1 in our patient, the coincident presentation of Cushing's disease and primary hyperparathyroidism could not be completely ruled out, especially with a parathyroid scintigraphy showing a pattern compatible with only one hyperfunctioning gland.

The likelihood of *MEN 1* mutation is higher with younger onset age for the tumor or with tumor multiplicity in that organ. The frequency of *MEN 1* germline mutation with a tumor, presumed to be sporadic based on family evaluations, is speculated as follows: parathyroid adenoma (1%), gastrinoma (5%), prolactinoma (1%), foregut carcinoid (2%), lipoma (0.1%), and angiofibroma (1%) (1). These estimates show the importance of establishing the genetic diagnosis of our patient before the decision for the surgical approach for her primary HPT: a negative test would indicate more conservative management with resection of the parathyroid adenoma, while the positive test for MEN 1 would favor a complete removal of the parathyroid glands (11,12). The latter approach was chosen with the finding of a c1561dupC mutation at the exon 10 of the *MEN 1* gene in our patient. In this heterozygous frameshift mutation, an additional cytosine occurs at position 1561, resulting in a stop codon. Lemos and Thakker (15) reported on 1,336 mutations described in the first decade following the identification of the *MEN 1* gene, which are scattered in and around its open reading frame. *MEN 1* mutations include nonsense, missense, donor-splice, small deletions and small insertions, and more than 70% of them are predicted to generate truncated forms of menin (1,2,15).

From a practical point of view, MEN 1 is defined in a patient with two of the three main MEN 1-related endocrine tumors (parathyroid adenomas, entero-pancreatic endocrine tumors, and pituitary tumor). Familial MEN 1 is similarly defined as at least

one MEN 1 case plus at least 1 first degree relative with one of the three main MEN 1-related endocrine tumors (1). However, the expression of one or more of the less common tumors of MEN 1 can occur by chance, unlike syndromic variants that occur repeatedly in MEN 2, especially in sporadic cases (13). This was the situation of our patient, whose initial manifestation was Cushing's Disease at 20 years of age. Anterior pituitary adenoma is the first clinical finding of MEN 1 in up to 25% of sporadic cases, but only less than 5% of these tumors are corticotropinomas (1,2,6). In fact, Cushing's disease is a rare disease even in the general population, with an incidence of 5-10 cases per million, per year. In 1993, Gaitan and cols. (16) reported on a similar case of a woman with Cushing's disease and primary HPT, who had a daughter with Cushing's disease and another daughter and two other relatives with primary HPT. In contrast, our patient had a negative family history for any tumor related to MEN. Prolactinomas represent 25% of the pituitary adenomas in MEN 1, followed by nonfunctioning adenomas in 10% and somatotropinomas in 5% of the cases (1,2,6). As corticotropinomas are very rare, schedules to screen for tumor expression in the carriers of *MEN 1* mutation include annual determination of prolactin and IGF-1 levels and an MRI every 3-5 years, beginning at 5 years of age, but they do not usually recommend for a biochemical evaluation of Cushing's syndrome (1).

The diagnosis of primary HPT in our case was initially suspected by the detection of asymptomatic hypercalcemia. This emphasizes the importance of measuring serum calcium in patients with pituitary tumors, especially those at younger ages and who have prolactinomas, as a simple test for detection of MEN 1 (7). For carriers of *MEN 1* mutation, determination of serum calcium and PTH is advised to start at 8 years of age (1). Primary HPT is the most common endocrinopathy in MEN 1, reaching nearly 100% of penetrance by the age of 50 years (1-3). In contrast, MEN 1 represents less than 5% of all cases of primary HPT (10). In MEN 1, HPT is most frequently asymptomatic, but when symptoms are present, they are similar to those observed in other forms of HPT (1-3). Compared to sporadic parathyroid adenomas, HPT in MEN 1 starts at an earlier age (25 *versus* 55 years), lack gender preference (1:1 *versus* 3:1 female/male ratio), and differs in pathology, with the presence

of multiglandular disease, which justifies a most aggressive surgical approach (1-3,11-12). However, despite the diagnosis of MEN 1, the pathologic study in our case did not reveal a multiglandular disease. It is believed that the development of multiglandular parathyroid disease in MEN 1 is a question of time, and the age of our patient may explain the absence of hyperplasia in the other three parathyroid glands (17). Our patient presented no specific symptoms of HPT, but subsequent investigation demonstrated bilateral nephrolithiasis and low bone mineral density at the lumbar spine and femoral neck. In Brazil, a recent study of 36 cases from 8 unrelated MEN 1 families with uncontrolled HPT found that bone mineral and urolithiasis-related renal complications in this population was early-onset, frequent, extensive, severe and progressive, which are in agreement with our findings (18). Moreover, the hypercortisolism in our patient was also a contributor to the impairment of her bone mass.

Our patient has no clinical, biochemical or radiological evidence of any enteropancreatic neuroendocrine tumor so far. The prevalence of these tumors in MEN 1-affected individuals varies in different clinical series from 30%-75% and approaches 80% in necropsy series (1-3). Biochemical screening for these tumors includes fasting glucose, gastrin, insulin, proinsulin, glucagon, and chromogranin A. In suspected cases, additional tests and more detailed investigation may be indicated. Search for insulinoma in carriers is recommended to start at 5 years of age, whereas for gastrinoma, foregut carcinoid and other enteropancreatic tumors the age to begin testing is 20 years of age, with annual evaluation of the biochemical screening (1).

More recently, our patient had the cardiologic diagnosis of Wolff-Parkinson-White syndrome, which is the most common cause of ventricular pre-excitation. In this condition, all or part of the ventricle is excited earlier than would normally be expected due to defects in the conduction pathway, often leading to ventricular fibrillation and sudden cardiac death (19). It was recently discovered that many of the underlying mutations responsible for the familial form of Wolff-Parkinson-White syndrome are located in the gene encoding for the regulatory gamma(2)-subunit (*PRKAG2*) of the AMP-activated protein kinase (20). The cellular mechanisms for the observed arrhythmias are currently being studied and may involve glycogen storage with associated hy-

pertrophy as well as alterations in the properties of cardiac ion channels, such as voltage-gated sodium channel (19,20). To our knowledge, there have been no reports on this cardiac abnormality in patients with MEN 1, indicating the fortuitous nature of such association.

In summary, this report illustrates the importance of genetic testing in a case of sporadic MEN 1 to define the best therapeutic approach for HPT and to optimize patient follow-up.

Disclosure: no potential conflict of interest relevant to this article was reported.

REFERENCES

1. Brandi ML, Gagel RF, Angeli A, Bilezikian JP, Beck-Peccoz P, Bordi C, et al. Guidelines for diagnosis and therapy of MEN type 1 and type 2. *J Clin Endocrinol Metab.* 2001;86:5658-71.
2. Hoff AO, Hauache OM. Multiple endocrine neoplasia type 1 (MEN 1): clinical, biochemical and molecular diagnosis and treatment of the associated disturbances. *Arq Bras Endocrinol Metab.* 2005;49:735-46.
3. Burgess J. How should the patient with multiple endocrine neoplasia type 1 (MEN 1) be followed? *Clin Endocrinol (Oxf).* 2010;72:13-6.
4. Chandrasekharappa SC, Guru SC, Manickam P, Olufemi SE, Collins FS, Emmert-Buck MR, et al. Positional cloning of the gene for multiple endocrine neoplasia-type 1. *Science.* 1997;276(5311):404-7.
5. Hendy GN, Kaji H, Canaff L. Cellular functions of menin. *Adv Exp Med Biol.* 2009;668:37-50.
6. Vergès B, Boureille F, Goudet P, Murat A, Beckers A, Sassolas G, et al. Pituitary disease in MEN type 1 (MEN1): data from the France-Belgium MEN1 multicenter study. *J Clin Endocrinol Metab.* 2002;87:457-65.
7. Corbetta S, Pizzocaro A, Peracchi M, Beck-Peccoz P, Faglia G, Spada A. Multiple endocrine neoplasia type 1 in patients with recognized pituitary tumours of different types. *Clin Endocrinol (Oxf).* 1997;47:507-12.
8. Rix M, Hertel NT, Nielsen FC, Jacobsen BB, Hoejberg AS, Brixen K, et al. Cushing's disease in childhood as the first manifestation of multiple endocrine neoplasia syndrome type 1. *Eur J Endocrinol.* 2004;151:709-15.
9. Alzahrani AS, Al-Khalidi N, Shi Y, Al-Rijjal RA, Zou M, Baitei EY, et al. Diagnosis by serendipity: Cushing syndrome attributable to cortisol-producing adrenal adenoma as the initial manifestation of multiple endocrine neoplasia type 1 due to a rare splicing site MEN1 gene mutation. *Endocr Pract.* 2008;14:595-602.
10. Skandarajah A, Barlier A, Morlet-Barlat N, Sebag F, Enjalbert A, Conte-Devolx B, et al. Should routine analysis of the MEN1 gene be performed in all patients with primary hyperparathyroidism under 40 years of age? *World J Surg.* 2010;34:1294-8.
11. Lew JI, Solorzano CC. Surgical management of primary hyperparathyroidism: state of the art. *Surg Clin North Am.* 2009;89:1205-25.
12. Waldmann J, López CL, Langer P, Rothmund M, Bartsch DK. Surgery for multiple endocrine neoplasia type 1-associated primary hyperparathyroidism. *Br J Surg.* 2010;97(10):1528-34.
13. Raue F, Frank-Raue K. Genotype-phenotype relationship in multiple endocrine neoplasia type 2. Implications for clinical management. *Hormones (Athens).* 2009;8:23-8.
14. Hai N, Aoki N, Shimatsu A, Mori T, Kosugi S. Clinical features of multiple endocrine neoplasia type 1 (MEN1) phenocopy without germline MEN1 gene mutations: analysis of 20 Japanese sporadic cases without MEN1. *Clin Endocrinol (Oxf).* 2000;52:509-18.
15. Lemos MC, Thakker RV. Multiple endocrine neoplasia type 1 (MEN1): analysis of 1336 mutations reported in the first decade following identification of the gene. *Hum Mutat.* 2008;29:22-32.
16. Gaitan D, Loosen PT, Orth DN. Two patients with Cushing's disease in a kindred with multiple endocrine neoplasia type 1. *J Clin Endocrinol Metab.* 1993;76:1580-2.
17. Doherty GM, Lairmore TC, DeBenedetti MK. Multiple endocrine neoplasia type 1 parathyroid adenoma development over time. *World J Surg.* 2004;28:1139-42.
18. Lourenço DM Jr, Coutinho FL, Toledo RA, Montenegro FL, Correia-Deur JE, Toledo SP. Early-onset, progressive, frequent, extensive and severe bone mineral and renal complications in multiple endocrine neoplasia type 1-associated primary hyperparathyroidism. *J Bone Miner Res.* 2010;25(11):2382-91.
19. Light PE. Familial Wolff-Parkinson-White Syndrome: a disease of glycogen storage or ion channel dysfunction? *J Cardiovasc Electrophysiol.* 2006;17(Suppl 1):S158-61.
20. Nagata D, Hirata Y. The role of AMP-activated protein kinase in the cardiovascular system. *Hypertens Res.* 2010;33:22-8.