

# Treatment of mild to moderate Graves' ophthalmopathy with sodium diclofenac: a pilot study

*Tratamento da oftalmopatia de Graves leve a moderada com diclofenato de sódio: um estudo piloto*

Walter Bloise<sup>1</sup>, Lidia Yuri Mimura<sup>1</sup>, Janete Moura<sup>1</sup>, Wilian Nicolau<sup>1</sup>

<sup>1</sup> Graves' Ophthalmopathy Section, Thyroid Unit, Hospital das Clínicas, Faculdade de Medicina, Universidade de São Paulo (FMUSP), São Paulo, SP, Brazil

## ABSTRACT

**Objective:** To report the use of sodium diclofenac, an antagonist of *PPAR*-gamma and cyclooxygenase-2 (COX-2) inhibitor in the treatment of mild to moderate Graves' ophthalmopathy. **Subjects and methods:** Thirteen patients with clinical activity score (CAS) 2 to 7 were treated during a period ranging from 3 to 12 months (mean  $7.8 \pm 3.4$ ) with oral sodium diclofenac, 50 mg every 12 hours. **Results:** Extra-ocular muscle restriction and CAS improved significantly,  $p = 0.003$  and  $p = 0.004$ , respectively. Ocular pain and diplopia disappeared, except for one patient who reported improvement of these symptoms. No recurrence was found after interruption of treatment. **Conclusions:** Treatment of moderate Graves' ophthalmopathy with oral sodium diclofenac is a good, safe and less expensive therapeutic option. Like others new treatment trials, findings must be confirmed in a greater number of patients in a controlled study. *Arq Bras Endocrinol Metab.* 2011;55(9):692-5

## Keywords

Moderate Graves' ophthalmopathy; treatment; sodium diclofenac; *PPAR*-gamma; cyclooxygenase-2

## RESUMO

**Objetivo:** Relatar o uso do diclofenato de sódio, um antagonista do *PPAR*-gama e inibidor da ciclooxigenase-2 (COX-2) no tratamento da leve a moderada oftalmopatia de Graves. **Sujeitos e métodos:** Treze pacientes com CAS (*clinical activity score*) 2 a 7 foram tratados durante um período de 3 a 12 meses (média  $7,6 \pm 3,4$ ) com diclofenaco de sódio por via oral na dose de 50 mg a cada 12 horas. **Resultados:** A restrição da musculatura extraocular e o índice CAS melhoraram de modo significativo, respectivamente  $p = 0,003$  e  $p = 0,004$ . A dor ocular e a diplopia desapareceram, com exceção de um paciente que referiu melhora desses sintomas. Não houve recidiva após a interrupção do tratamento. **Conclusões:** O tratamento da oftalmopatia de Graves de média gravidade com diclofenaco de sódio por via oral é uma opção boa, segura e de baixo custo. Como outros novos tratamentos, ele deverá ser confirmado em um maior número de pacientes em estudos controlados. *Arq Bras Endocrinol Metab.* 2011;55(9):692-5

## Descritores

Oftalmopatia de Graves moderada; tratamento; diclofenaco de sódio; *PPAR*-gama; ciclooxigenase-2

## Correspondence to:

Walter Bloise  
Alameda Franca, 84, ap. 122  
01422-000 – São Paulo, SP, Brazil  
wbloise@uol.com.br

Received on 24/Mar/2011  
Accepted on 24/Nov/2011

## INTRODUCTION

Graves' ophthalmopathy is an autoimmune condition in which intense orbital inflammation affects mainly the extra-ocular muscles and fibro-adipose tissue. The progression of the disease depends upon interactions between B and T lymphocytes and orbital fibroblasts (1). The increased knowledge on the pathogenesis of Graves' ophthalmopathy introduced new immuno-

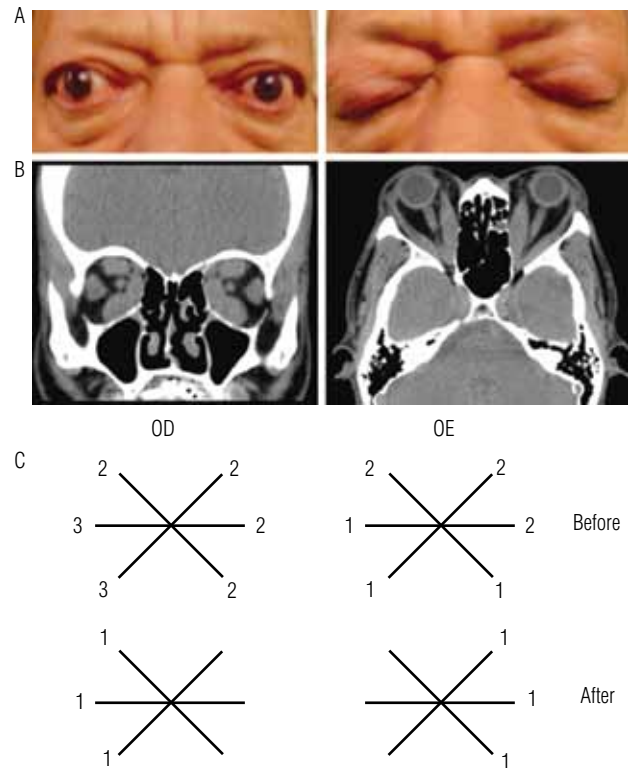
therapeutic strategies directed to dampen one specific component of this immunological process. In general, these strategies are targeted to immunocompetent cells or cytokines involved in the orbital inflammation (1-3). One important player in this complex process is *PPAR*-gamma. In a previous study, we found a significant increase in the expression of *PPAR*-gamma in the orbital fibro-adipose tissue of patients with Graves' ophthalm-

omopathy in the active stage, and a link with the peculiar increase of ocular adipose tissue (4). Otherwise, the gene of proinflammatory cyclooxygenase-2 (COX-2), another partner of the disease, was found overexpressed in severe and active phase of Graves' ophthalmopathy (5,6). According to these data, the use of a PPAR-gamma and COX-2 antagonist could theoretically be useful in the treatment of the orbital disease.

The aim of this prospective pilot study is to report the results of the use of sodium diclofenac, a nonsteroid anti-inflammatory drug (NSAID) that is a PPAR-gamma antagonist and COX-2 inhibitor, in the treatment of selected patients with Graves' ophthalmopathy (7,8).

## PATIENTS AND METHODS

Thirteen patients without ocular treatment at least 3 months before the study were selected by showing clinical activity score (CAS) 2 to 7. Five patients with CAS 2 who sought treatment were included because of a complaint of distressing ocular pain, diplopia or severe conjunctival hyperemia. They were evaluated monthly on the first 3 months, and afterwards, every 2 months. Patients with optic neuropathy or renal disease were excluded. The duration of Graves' ophthalmopathy ranged from 4 to 60 months (mean  $32.1 \pm 16.9$  months), age ranged from 24 to 66 years old (mean  $42.7 \pm 14.8$  years), and 7 patients were females. Seven patients were hyperthyroid, under treatment with methimazole; and three of them were hypothyroid, receiving L-thyroxine. Three of them were euthyroid. Antibodies to the TSH receptor were positive in 10 patients. All patients had variable degrees of spindle shaped extra-ocular muscle thickness, as shown by orbital computed tomography scan. The same examiner evaluated the restriction of extra-ocular muscle by means of scores 0 to 4, where zero represented absence of restriction, and 4, inability to drive the eye to the points shown in figure 1. Proptosis was measured by Hertel exophthalmometer, and diplopia was also investigated. Figure 1 shows one of the patients of the study and the representation of his extra-ocular muscle evaluation. Oral sodium diclofenac was administered every 12 hours in a maximum period of 12 months, or interrupted after signs or symptoms disappeared. The administration period ranged from 3 to 12 months (mean  $7.8 \pm 3.4$  months). Local eye adjuvant therapy to all patients consisted of ointments and lubricating drops. Oral omeprazole was also prescribed in the case of gastric pain.



**Figure 1.** (A) Characteristic Graves' ophthalmopathy; (B) Computed tomography scans of the orbits; (C) Schematic representation of extra-ocular muscle restriction.

Blood counts and renal and liver function were assessed during the treatment.

Paired t test was used in the statistical comparison of proptosis and the sum of extra-ocular muscle restriction scores of the right and left eye of each patient, before and after the treatment. Wilcoxon non-parametric test was used to compare the changes in CAS index.

Informed consent was obtained from all patients.

## RESULTS

Table 1 summarizes the evolution of the symptoms and signs of the disease before and after the treatment.

Ocular pain and diplopia disappeared, except in one patient who still showed some discomfort. The improvements in extra-ocular muscle function and CAS were statistically significant,  $p = 0.003$  and  $p = 0.004$ , respectively. Proptosis was unaltered.

No renal or liver injury was found. Two patients complained of gastric pain, which was relieved by oral omeprazole.

No recurrence was found after treatment was interrupted.

**Table 1.** Result of treatment of mild to moderate Graves' ophthalmopathy with 50 mg of oral sodium diclofenac every 12 hours

	Ocular pain (n = 6)	Diplopia (n = 5)	Muscle restriction <sup>a</sup> (scores 0-4) (n = 11)	Proptosis <sup>b</sup> (mm) Right n = 13	Proptosis <sup>b</sup> (mm) Left n = 13	CAS <sup>c</sup> n = 13
Before treatment	6	5	5.23 ± 4.34	26.04 ± 4.20	23.38 ± 3.57	3.61 ± 1.44
After treatment	1	1	3.38 ± 4.53	25.08 ± 3.60	23.00 ± 3.67	2.30 ± 1.03
p			= 0.003	ns	ns	= 0.004

a) Mean of the sum of muscle restriction scores of right and left eye (see text); b) Mean; c) Mean of clinical activity score (CAS).

## DISCUSSION

Conventional management of severe Graves' ophthalmopathy is usually based on nonspecific immunosuppression with high doses of corticosteroids or orbital decompression (9). The novel strategies of treatment comprises B lymphocyte depletion (10,11) or anticytokines (12,13). In general, they are expensive, administered parenterally and, sometimes, not deprived of adverse effects (14). *PPAR*-gamma is a substantial component of the orbital inflammatory process, as observed earlier. Another evidence of the *PPAR*-gamma contribution in the pathogenicity of Graves' ophthalmopathy was obtained after the report on adverse effects of insulin-sensitizing *PPAR*-gamma agonists, the thiazolidinediones, on the natural course of the ocular disease (15,16). These findings strengthen the previous suggestion that take into account *PPAR*-gamma as one inducer of the characteristic orbital adipose tissue accumulation of the thyroid eye disease. (4). According to these data, therapeutic efforts to antagonize *PPAR*-gamma should theoretically be useful in the management of ophthalmopathy. Sodium diclofenac, besides antagonizing *PPAR*-gamma, has a potent inhibiting action upon COX-2, another player of the autoimmune orbital process. This enzyme converts arachidonic acid to prostaglandin, a relevant factor on inflammation and adipogenesis, and a natural ligand of *PPAR*-gamma (17). Graves' ophthalmopathy of mild to moderate intensity but with troublesome symptoms, is usually managed with orbital radiotherapy or corticosteroids in variables doses. This type of treatment is usually associated with many and, sometimes undesirable, side effects. The favorable results achieved with sodium diclofenac on the distressing diplopia and ocular pain were noteworthy in this preliminary survey. In addition, impaired extra-ocular muscle function and clinical activity score of the disease improved significantly. It is relevant that gastric pain was the only side effect reported by two patients. Treatment of Graves' ophthalmopathy

has a long story, with many different drugs and strategies tested. Few of them resisted the test of daily clinical practice. Treatment with indomethacin, another nonsteroidal anti-inflammatory drug, which is a non-selective inhibitor of Cox 1 and 2, is an example. It was used many years ago as a rectal suppository in a non-controlled therapeutic trial in seven patients with modest results, but it was further disregarded (18).

In conclusion, oral sodium diclofenac in the treatment of mild to moderate Graves' ophthalmopathy resulted in almost complete relief of diplopia and pain, and significant improvement of the extra-ocular muscle restriction and CAS.

The results of this pilot study, if confirmed in a controlled trial with a greater number of patients, could be a good option in the treatment of selected patients with ocular complications caused by Graves' disease, because of the feasibility, low cost and almost absence of side effects of this treatment.

Acknowledgements: the abstract of this study was reported as an oral communication on the 80<sup>th</sup> Annual Meeting of American Thyroid Association, in 2009.

Disclosure: no potential conflict of interest relevant to this article was reported.

## REFERENCES

1. Bahn RS. Graves' ophthalmopathy, mechanism of disease. Review. N Engl J Med. 2010;362:726-38.
2. Paul Banga J, Nielsen CH, Gilbert JA, El Fassi D, Hegedus L. Application of new therapies in Graves' disease and thyroid-associated ophthalmopathy, animal models and translation to human clinical trials. Thyroid. 2008;18:973-81.
3. Bartalena L, Lai A, Sassi L, Lombardi V, Dalle Mulle I, Lipanoto I, et al. Novel treatment modalities for Graves' orbitopathy. Pediatric Endocrinol Rev Suppl. 2007;2:210-6.
4. Mimura LY, Villares SMF, Monteiro MLR, Guazzelli IC, Bloise W. Peroxisome proliferator-activated receptor-gamma gene expression in orbital adipose/connective tissues is increased during the active stage of Graves' ophthalmopathy. Thyroid. 2003;13:845-50.
5. Konuk EBY, Konuk O, Misirliouglu M, Menevse A, Unal M. Expression of cyclooxygenase-2 in orbital fibroadipose connective

- tissues of Graves' ophthalmopathy patients. *Eur J Endocrinol*. 2006;155:681-5.
6. Vondriichova T, Capretz A, Parikh H, Frenander C, Asman P, Sberg M, et al. Cox-2 and SCD, markers of inflammation and adipogenesis, are related to disease activity in Graves' ophthalmopathy. *Thyroid*. 2007;17:511-7.
  7. Adamson DJA, Frew D, Tatoud R, Wolf R, Palmer CAN. Diclofenac antagonizes peroxisome proliferator-activated receptor-gamma signaling. *Mol Pharmacol*. 2002;61:7-12.
  8. Gan TJ. Diclofenac: an update on its mechanism of action and safety profile. *Curr Med Res Opin*. 2010;26:1715-31.
  9. Bartalena L, Baldeschi L, Dickinson AJ, Eckstein A, Kendall-Taylor P, Marcocci C, et al. Consensus statement of the European group on Graves' orbitopathy (EUGOGO) on management of Graves' orbitopathy. *Thyroid*. 2008;18:333-46.
  10. El Fassi D, Nielsen CH, Hasselbach HC, Hegedus L. Treatment-resistant severe, active Graves' ophthalmopathy successfully treated with B lymphocyte depletion. *Thyroid*. 2006;16:709-10.
  11. Salvi M, Vannucchi G, Campi I, Curro N, Dazzi D, Simonetta S, et al. Treatment of Graves' disease and associated ophthalmopathy with the anti-CD20 monoclonal antibody rituximab. An open study. *Eur J Endocrinol*. 2007;156:33-40.
  12. Paridaens D, van den Bosch WA, van den Loos TL, Krenning EP, van Hagen PM. The effect of etanercept on Graves' ophthalmopathy: a pilot study. *Eye*. 2005;19:1286-9.
  13. Durrani OM, Reuser TQ, Murray PI. Infliximab: a novel treatment for sight-threatening thyroid associated ophthalmopathy. *Orbit*. 2005;24:117-9.
  14. Simsek J, Erdem H, Pay S, Sobaci G, Dinc A. Optic neuritis occurring with anti-tumor necrosis factor- (alpha) therapy. *Am Rheum Dis*. 2007;66:255-8.
  15. Starkey K, Heufelder A, Baker G, Joba W, Evans M, Davies S, et al. Peroxisome proliferator-activated receptor-gamma in thyroid eye disease: contraindication for thiazolidinedione use? *J Clin Endocrinol Metab*. 2003;88:55-9.
  16. Lee S, Tsirbas A, Goldberg RA, McCann JD. Thiazolidinedione induced thyroid associated orbitopathy. *BMC Ophthalmol*. 2007;7:8.
  17. Forman BM, Tontonoz P, Chen J, Brun RP, Spiegelman BM, Evans RM. 15-Deoxy-delta 12, 14-prostaglandin J2 is a ligand for the adipocyte determination factor PPAR gamma. *Cell*. 1995;83:803-12.
  18. Amemiya T. Long-term indomethacin treatment of ophthalmopathies after Basedow disease in general practice. *Klin Monbl Augenheilkd*. 1982;181:286-9.