

Evaluation of percutaneous ethanol injections in benign thyroid nodules

Avaliação do tratamento com injeção percutânea com etanol em nódulos benignos de tireoide

Camila Luhm Silva Perez¹, Tayane Muniz Fighera¹, Fabiola Miasaki¹, Cleo Otaviano Mesa Junior¹, Gilberto Jorge da Paz Filho¹, Hans Graf¹, Gisah Amaral de Carvalho¹

¹ Department of Endocrinology and Metabolism, Hospital de Clínicas, Federal University of Paraná (UFPR), Curitiba, PR, Brazil

ABSTRACT

Objective: The objective of this study was to evaluate the efficacy and safety of percutaneous ethanol injection (PEI) in the treatment of benign thyroid nodules. **Subjects and methods:** We evaluated 120 patients with benign thyroid nodules. Patients underwent evaluation of serum TSH and free T4, cervical ultrasound, and thyroid scintigraphy (in those with suppressed TSH levels). The application of sterile ethanol 99% was guided by ultrasound, with the injected volume amounting to one-third of the nodule volume. Response was considered complete (reduction of 90%); partial (reduction between 50 and 90%); or none (reduction of < 50%). Autonomous nodules were evaluated for normalization of TSH levels. **Results:** Among the nodules studied, 30.8% were solid, 56.7% were mixed, 12.5% were cystic, and 21.6% were hyperfunctioning. The initial volume of the treated nodules ranged from 0.9 to 74.8 mL (mean 13.1 ± 12.4 mL). We performed 1-8 sessions of PEI, applying an average of 6.2 mL of ethanol for patient. After 2 years of follow-up, 17% of patients achieved a complete response (94% reduction); 53%, a partial response (70% reduction); and 30%, no response. A reduction in the volume of autonomous nodules was noted in 70% of cases, and 54% had a normalized value of TSH. The main side effect is local pain, lasting less than 24 hours in most cases. **Conclusion:** This study showed that PEI is a safe and effective procedure for treatment of benign, solid or mixed thyroid nodules. Most cases resulted in significant reduction in nodule volume, with normalization of thyroid function. *Arq Bras Endocrinol Metab.* 2014;58(9):912-7

Keywords

Nodule, thyroid, goiter; percutaneous ethanol injection; sclerotherapy

RESUMO

Objetivo: O objetivo deste estudo foi avaliar a eficácia e segurança da injeção percutânea de etanol (IPE) no tratamento de nódulos tireoidianos benignos. **Sujeitos e métodos:** Foram avaliados 120 pacientes com nódulos benignos de tireoide. Todos realizaram dosagens de TSH, T4 livre, ecografia cervical (US) e cintilografia de tireoide (em pacientes com TSH suprimido). A aplicação de etanol estéril a 99% foi guiada por US e o volume de etanol injetado correspondeu a um terço do volume nodular calculado. A resposta foi considerada completa (redução de 90%); parcial (redução entre 50 e 90%) ou ausência de resposta (redução menor que 50%). Nos nódulos autônomos, foi avaliada a normalização do TSH. **Resultados:** Entre os nódulos estudados, 30,8% eram sólidos, 56,7% eram mistos, 12,5% eram císticos e 21,6%, nódulos hiperfuncionantes. O volume inicial dos nódulos tratados variou de 0,9 a 74,8 mL (média $13,1 \pm 12,4$ mL). Foram realizadas de 1 a 8 sessões de IPE (média 2,8), com aplicação média de 6,2 mL de etanol por paciente. Após dois anos de seguimento, 17% dos pacientes obtiveram resposta completa (redução de 94%), 53% obtiveram resposta parcial (redução de 70%) e 30% não responderam. Houve redução de volume nos nódulos autônomos em 70% dos casos, e 54% normalizaram o valor do TSH. Os efeitos colaterais registrados foram decorrentes apenas do desconforto no local de aplicação. **Conclusão:** Este trabalho mostrou que a IPE é um procedimento seguro e eficaz para tratamento de nódulos benignos, sólidos ou mistos de tireoide. Na maioria dos casos, ocasiona redução do volume nodular, com melhora dos sintomas compressivos e normalização da função tireoidiana. *Arq Bras Endocrinol Metab.* 2014;58(9):912-7

Descritores

Nódulo; tireoide; bócio; injeção percutânea de etanol; escleroterapia

Correspondence to:
Tayane Muniz Fighera
Hospital das Clínicas,
Universidade Federal do Paraná,
Departamento de Endocrinologia e
Metabolismo
Av. Agostinho Leão Junior, 285
80030-110 – Curitiba, PR, Brazil
tayfighera@yahoo.com.br

Received on May/4/2014
Accepted on Aug/10/2014

DOI: 10.1590/0004-2730000003444

INTRODUCTION

Thyroid nodules are often found in clinical practice. Epidemiological studies conducted in regions rich in iodine have shown that 4 to 7% of women and 1% of men have a palpable nodule (1-4). However, ultrasound studies show a prevalence much higher (reaching 68%), with a greater incidence in women and elderly people (1,5).

In the evaluation of thyroid nodules, in addition to the clinical and ultrasound findings, fine-needle aspiration (FNA) cytology is important for characterizing and defining treatment. In nodules with cytology suspicious or positive for malignancy, surgical resection is the appropriate treatment. The best treatment for benign nodules, however, remains uncertain, especially if they cause cosmetic problems or compressive symptoms (6).

The treatment of thyroid nodules by simple aspiration, thyroid hormone suppression, or sclerosing treatment with chemical agents, such as tetracycline, has shown unsatisfactory results (7,8). Ethanol has been used as a primary sclerosing agent (9) and can be considered a therapeutic option after excluding malignancy (6). Percutaneous ethanol injection (PEI) is currently the first choice treatment of cystic nodules relapsed after diagnostic evacuation. Its use for solid nodules is under debate and, generally, proposed only in case of poor surgical risk or in patients refusing surgical or radioiodine therapy. Despite some controversial results, PEI seems as effective as radioiodine in inducing partial or complete remission of autonomous nodules, with greater reduction in size and a low risk of recurrence and hypothyroidism (10). PEI is also an alternative for patients with nodular lesions with surgical contraindication or high surgical risk (9).

SUBJECTS AND METHODS

One hundred and twenty patients (mean age, 48.2 years, 94.2% female) with uninodular and multinodular goiter were selected between May 1998 and March 2010. All patients were ambulatory and followed at the Department of Endocrinology of the Hospital de Clinicas in Curitiba, Brazil. No patient had been previously treated with radioiodine, surgery, suppressive levothyroxine, or PEI. Before the first session, levels of thyroid-stimulating hormone (TSH) were measured by chemiluminescence (ARCHITECT; Abbott Laboratories, Lake Forest, IL) (benchmark, 0.35-4.94 mU/L) and free T4 chemiluminescence (ARCHITECT Free T4; Abbott

Laboratories) (benchmark, 0.7-1.48 ng/dL). Patients who had suppressed TSH levels underwent thyroid scintigraphy (Pho/Dot Scanner; Nuclear-Chicago, Des Plaines, IL, USA), including those with toxic nodules. Patients also underwent thyroid ultrasound (SSD-500V, Hitachi Aloka Medical, Ltd, Tokyo, Japan) using a 7.5-MHz transducer. For measurement of the nodule, it was assumed that the nodule had an ellipsoid shape; thus, the following equation was used: volume = diameter of the nodule laterolateral \times anteroposterior \times longitudinal diameter \times 0.52. Patients with solid and/or mixed nodules were included in the study, and malignancy was excluded in all patients by ultrasound-guided FNA biopsy of the dominant and/or suspected nodules.

For treatment, we used sterile ethanol 99% (Indústria Farmacêutica Rioquímica Ltda., São José do Rio Preto, Brazil). The PEI procedure was performed by two experienced operators in ultrasound and FNA, with one holding the transducer and the other performing the ethanol injection. Patients were informed about the procedure and positioned in dorsal decubitus with slight hyperextension of the neck. The insertion of the needle and ethanol injection was performed with the same ultrasound equipment used for the FNA, without anesthesia or sedation. A 23-gauge needle was inserted into the nodule, and sterile ethanol 99% was injected slowly. The ethanol volume applied amounted to one-third the size of the nodule. The distribution of ethanol was monitored in real time by the ultrasound equipment. In nodules with a cystic component, aspiration of the liquid contents was performed. The injection was stopped when ethanol completely filled the nodule or when the patient complained of severe neck pain. By the end of the procedure, each patient received a prescription of nonsteroidal anti-inflammatory for use in case of persistent pain.

Treatment efficacy was evaluated for nodule volume reduction and normalization of TSH levels (in autonomous nodules). Response was considered complete when the nodule volume decreased \geq 90%; partial, if decreased between 50% and 90%; and none, if $<$ 50%.

The tolerability of the treatment was assessed immediately after treatment and again during outpatient follow-up. Patients were asked about the presence or absence of cervical pain. Pain was classified as mild (limited to procedure), moderate (less than 24 hours) and severe (over 24 hours). Thyroid function was monitored in those with hyperthyroidism.

For statistical analysis, clinical, laboratory, and ultrasound data were entered in Microsoft Excel software

(Microsoft, Redmond, WA) and exported to SPSS version 17.0 software (IBM Corporation, Chicago, IL). Categorical variables were described by absolute frequency and relative frequency percentage and compared by χ^2 test or χ^2 test with Yates correction. For small samples, we used the Fisher exact test. *P* values < 0.05 was considered significant.

The research was approved by the Ethics Committee on Human Research of the Hospital de Clinicas, Federal University of Paraná. Patients were informed about the procedure and signed a consent form.

RESULTS

Before treatment, 94 (78%) patients had normal thyroid function, whereas 26 (22%) had hyperthyroidism. Patients with suppressed TSH levels underwent thyroid scintigraphy, which in all cases revealed an autonomous nodule.

Fifty-eight percent of patients had a single nodule; 42% of the patients had a multinodular goiter, and in these patients, treatment was only performed in the dominant nodule. Thirty-one percent of the nodules were solid, 57% were mixed, and 12% were cystic. Further, women comprised 94% of the study sample. Mean age was 48.5 ± 13.2 years.

Patients underwent a mean of 2.8 (range, 1-8) sessions each. The average volume of ethanol 99% applied was 6.2 mL for patient. Each patient had only one nodule treated (the dominant one in cases of multinodular goiter). The average volume of the nodules selected for initial treatment was 13.1 ± 12.4 mL. The final volume was 4.7 ± 5.6 mL, with a mean reduction of $60.4\% \pm 28.3\%$ ($P < 0.001$).

In a follow-up ranging from 6 months to 11 years, 17% of patients achieved a complete response (volume reduction of 94%); 53%, a partial response (70% reduction); and 30%, no response (Figure 1). There was a reduction in the volume of autonomous nodules in 70% of cases. Analyzing the 26 patients with hyperfunctioning nodule, 54% achieved normalization of TSH (considering our reference values) (Figure 2A and 2B). No patient developed hypothyroidism after the procedure. Solid nodules were less likely to completely respond compared to mixed and cystic nodules (7.1% vs. 45%), with a relative risk of 1.67 (95% confidence interval, 0.92-3.05; $P = 0.056$) (Tabela 1). Hyperfunctioning nodules also showed a lower response rate (11.1%) than nonfunctioning nodules (40.4%), with a relative risk of 1.49 (95% confidence interval, 1.07-2.08; $P = 0.09$).

There was no difference in the probability of response in the other parameters studied (i.e., sex, type of goiter [uninodular or multinodular], age, initial volume of the treated nodule [> 5 mL]) (Tabela 2). Among the patients analyzed, 25% did not report any pain, 17% reported mild pain, 32% reported moderate pain and 26% reported severe pain. When questioned only 1.7% of patients do not repeat the procedure because of pain. Other reported symptoms were pain radiating to the jaw, swelling and local hematoma, occurring in < 1% of cases. No patient required glucocorticoids.

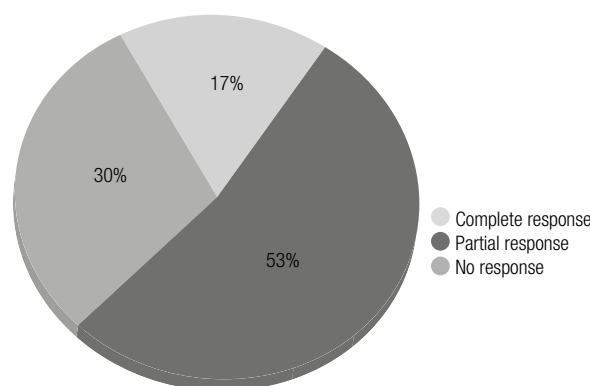


Figure 1. Response to sclerotherapy (n = 120).

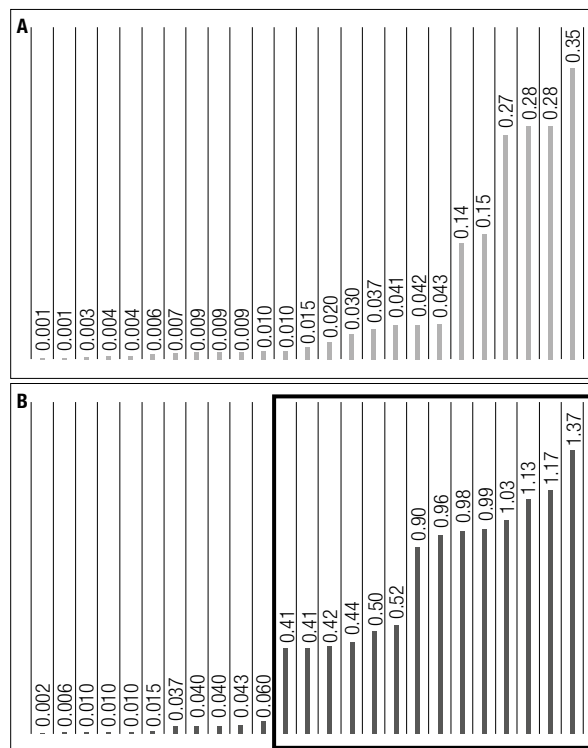


Figure 2. TSH levels (mIU/L) in patients with autonomous thyroid nodules. (A) TSH levels before treatment; (B) TSH levels after treatment. Inside the box are highlighted patients who normalized TSH levels with percutaneous ethanol injection.

Table 1. Changes in nodule volume with percutaneous ethanol injection treatment according to the nodule type

	Pre-treatment volume (mL)	Post-treatment volume (mL)	Reduction (%)
Solid	10.9 ± 10.7	5.4 ± 6.8	52.9
Mixed	14.5 ± 13.3	4.8 ± 5.1	63.0
Cystic	12.2 ± 12.3	2.6 ± 4.2	66.7

Table 2. Responses rates to percutaneous ethanol injection according patients and nodules characteristics

	Partial response		P value	Complete response		P value
	< 49 years	≥ 50 years		< 49 years	≥ 50 years	
Age	75.0%	65.6%	0.263	48.1%	24.1%	0.060
Gender	Female	Male	0.119	Female	Male	0.407
	71.7%	42.9%		37.3%	20.0%	
Type of goiter	Uninodular	Multinodular	0.225	Uninodular	Multinodular	0.617
	65.7%	76.0%		33.3%	40.0%	
Type of nodule	Solid	Cystic	0.901	Solid	Cystic	0.056
	64.9%	66.7%		7.1%	44.4%	
Initial volume	≥ 5 mL	< 5 mL	0.929	≥ 5 mL	< 5 mL	0.822
	69.8%	70.6%		36.6%	33.3%	

DISCUSSION

Currently, PEI is the first-line therapy in benign recurrent thyroid cysts. It has also been considered as an alternative therapy to surgery and radioiodine treatment in hyperfunctioning thyroid nodules. However, cost, efficacy and side effects disfavour PEI as opposed to radioactive iodine therapy. In solid nonfunctioning nodules, PEI appears to be effective in reducing volume and compressive symptoms, but there are no long-term follow-up studies assessing whether those results are sustained, and whether PEI improves quality of life. This study showed that PEI is an effective, simple, and safe method for treating benign nodules, reaching a mean volume reduction of 60% and controlling thyroid function in more than one-half of toxic nodule cases, in a follow-up for up to 11 years.

Sclerosing properties of ethanol have been known for many years, and PEI has been used to treat various benign and malignant lesions, including thyroid and parathyroid nodules; metastases from thyroid carcinoma; hepatic and intra-abdominal tumors (8,11-14). The mechanism of action of ethanol is related to cellular dehydration, coagulation necrosis, thrombosis, and vascular occlusion (15). In thyroid cysts, the application of ethanol leads to obstruction of vessels walls and prevention of recurrent bleeding and is proven to be more effective than single aspiration (11,16,17). Taking into account the changes caused by ethanol in

thyroid tissue as well as fibrosis, hemorrhagic necrosis, and inflammation, reduced volume of nodules persists for some time after ethanol application, which justifies holding sessions every few months (18). Because the PEI technique uses ultrasound guidance, the nodule suffers the action of ethanol, but not the adjacent thyroid tissue, which explains the low rate of early and late clinical complications (15).

The treatment of patients in the present study with sclerotherapy showed complete response in 17% of cases, with volume reduction ≥ 90%, whereas 53% had a partial response with volume reduction between 50 and 70%. Approximately one-third of our patients did not respond to treatment, with volume reduction < 50%. Lima and cols. (4) selected 42 patients with nodular goiter or nodular hyperplasia and evaluated them after at least two sessions of PEI. Thyroid nodules were multiple (solid or cystic) in 52.4% of their patients, and single (solid, cystic, or mixed) in 47.6%. The mean reduction of nodules after injection of ethanol was 58.2% for single nodules and 60.8% for cystic nodules. In multiple nodules, the authors evaluated the reduction of all thyroid lobes and found a 52.4% reduction. The only side effects reported were discomfort at the application site. Bianchini and cols. (19) evaluated 50 patients (26 with solid nodules, 17 with cystic nodules, and 7 with autonomous nodules). After 1 year of treatment, solid nodules showed a 74% reduction in the initial volume, whereas cystic nodules decreased by 92% with no recur-

rences. In patients with autonomous nodules, euthyroidism occurred in five cases, whereas two maintained a subnormal TSH level.

In the present study, a reduction in the volume of autonomous nodules was seen in 70% of cases, and 53% of patients had normalized TSH values. In a multicenter study presented by Lippi and cols. (20), 429 patients with autonomous nodules underwent sclerotherapy. These patients underwent 2 to 12 sessions of PEI (mean, 4 sessions) with 2 to 50 mL ethanol administered in each patient (mean, 17 ± 9 mL). Euthyroidism was achieved in 66.5% of patients with toxic adenomas and in 83.4% with pretoxic adenomas after 12 months of follow-up. In all cases, there was a reduction in the volume of nodes, and those with a better response had an initial volume of < 15 mL. No patient had a recurrence or hypothyroidism at follow-up. Monzani and cols. (21) studied 77 patients with toxic nodules and observed a complete response (euthyroidism) in 60 (77.9%). Treatment failure occurred in 10 (13%) patients, all with an initial volume > 10 mL. Efficacy was similar in patients with uninodular and multinodular goiter. Recurrence of hyperthyroidism was not observed in any patient at the 5-year follow-up, and evolution to hypothyroidism occurred in only one case.

In the present sample, the ethanol dose calculated was 30% of nodular volume measured before the beginning of the session. Each patient had a mean of 2.8 PEI sessions, which agrees with the literature (4,22).

The main adverse effect associated with the procedure was pain at the injection site due to overflow of small amounts of ethanol in the subcutaneous tissue. Pain was discrete and transient in most cases. No cases of transient recurrent nerve palsy were reported in the medical charts. PEI is a safe procedure without serious complications, and immediate pain is the most common complication. Other complications can occur and are described in the literature as unilateral vocal paralysis (0.7%) (23), hematoma at the injection site (0.2-23%) (4,23), dysphonia (2.6-4.7%) (4,24), transitory hypotension (0.2%) (23), transitory thyrotoxicosis (3.2%) (8), and fibrosis complicating subsequent surgery (1.6%) (8). The main limitation of this study is the retrospective evaluation of data. Data were collected from medical records, which may reduce their reliability.

In conclusion, PEI appears to be an effective alternative method for the treatment of benign thyroid nodules. Ethanol treatment caused significant nodule

reduction and normalization of thyroid function in most cases of hyperfunctioning nodules. Response was less likely to occur in solid non-functioning nodules. The reported complications were transitory and self-limited. Large prospective studies need to evaluate whether response is sustained, particularly for solid non-functioning nodules.

Disclosure: no potential conflict of interest relevant to this article was reported.

REFERENCES

- Rosário PW, Ward LS, Carvalho GA, Graf H, Maciel RMB, Maciel LMZ, et al. Nódulo tireoidiano e câncer diferenciado de tireoide: atualização do consenso brasileiro. *Arq Bras Endocrinol Metab.* 2013;57:240-64.
- Vander JB, Gaston EA, Dawber TR. The significance of nontoxic thyroid nodules. Final report of a 15-year study of the incidence of thyroid malignancy. *Ann Intern Med.* 1968;69:537-40.
- Tunbridge WM, Evered DC, Hall R, Appleton D, Brewis M, Clark F, et al. The spectrum of thyroid disease in a community: the Whickham survey. *Clin Endocrinol (Oxf).* 1977;7:481-93.
- Lima MA, Fagundes TA, Raffaelli CM, Ferreira BP, Rezende EM, Fonseca ECR, et al. Alcoolização de nódulo tireoidiano em região endêmica de bócio colóide. *Arq Bras Endocrinol Metab.* 2007;51:1007-12.
- Cooper DS, Doherty GM, Haugen BR, Kloos RT, Lee SL, Mandel SJ, et al.; American Thyroid Association Guidelines Taskforce. Management guidelines for patients with thyroid nodules and differentiated thyroid cancer. *Thyroid.* 2006;16(2):109-42.
- Hegedüs L. Clinical practice. The thyroid nodule. *N Engl J Med.* 2004;351:1764-71.
- Hegedüs L, Hansen JM, Karstrup S, Torp-Pedersen S, Juul N. Tetracycline for sclerosis of thyroid cysts. A randomized study. *Arch Intern Med.* 1988;148:1116-8.
- Bennedbaek FN, Karstrup S, Hegedüs L. Percutaneous ethanol injection therapy in the treatment of thyroid and parathyroid diseases. *Eur J Endocrinol.* 1997;136:240-50.
- Camargo RYA, Tomimori EK. Injeção percutânea de etanol dirigida pelo ultra-som no tratamento dos nódulos tireóideos. *Arq Bras Endocrinol Metab.* 1998;42:292-5.
- Ferrari C, Reschini E, Paracchi A. Treatment of the autonomous thyroid nodule: a review. *Eur J Endocrinol.* 1996;135:383-90.
- Guglielmi R, Pacella CM, Bianchini A, Bizzarri G, Rinaldi R, Graziano FM, et al. Percutaneous ethanol injection treatment in benign thyroid lesions: role and efficacy. *Thyroid.* 2004;14:125-31.
- Livraghi T, Festi D, Monti F, Salmi A, Vettori C. US-guided percutaneous alcohol injection of small hepatic and abdominal tumors. *Radiology.* 1986;161:309-12.
- Livraghi T, Giorgio A, Marin G, Salmi A, de Sio I, Bolondi L, et al. Hepatocellular carcinoma and cirrhosis in 746 patients: long-term results of percutaneous ethanol injection. *Radiology.* 1995;197:101-8.
- Solbiati L, Giangrande A, De Pra L, Bellotti E, Cantù P, Ravetto C. Percutaneous ethanol injection of parathyroid tumors under US guidance: treatment for secondary hyperparathyroidism. *Radiology.* 1985;155:607-10.
- Crescenzi A, Papini E, Pacella CM, Rinaldi R, Panunzi C, Petrucci L, et al. Morphological changes in a hyperfunctioning thyroid adenoma after percutaneous ethanol injection: histological, en-

- zymatic and sub-microscopical alterations. *J Endocrinol Invest.* 1996;19:371-6.
16. Verde G, Papini E, Pacella CM, Gallotti C, Delpiano S, Strada S, et al. Ultrasound guided percutaneous ethanol injection in the treatment of cystic thyroid nodules. *Clin Endocrinol (Oxf).* 1994;41:719-24.
 17. Bennedbaek FN, Hegedüs L. Treatment of recurrent thyroid cysts with ethanol: a random double-blind controlled trial. *J Clin Endocrinol Metab.* 2003;88:5773-7.
 18. Pomorski L, Bartos M. Histologic changes in thyroid nodules after percutaneous ethanol injection in patients subsequently operated on due to new focal thyroid lesions. *APMIS.* 2002;110:172-6.
 19. Bianchini EX, Ikejiri ES, Mamone MCC, Mamone MC, Piva ER, Maciel RMB, et al. Injeção percutânea de etanol no tratamento de nódulos tireoidianos sólidos, císticos e autônomos. *Arq Bras Endocrinol Metab.* 2003;47:543-51.
 20. Lippi F, Ferrari C, Manetti L, Rago T, Santini F, Monzani F, et al. Treatment of solitary autonomous thyroid nodules by percutaneous ethanol injection: results of an Italian multicenter study. *J Clin Endocrinol Metab.* 1996;81:3261-4.
 21. Monzani F, Caraccio N, Goletti O, Lippolis PV, Casolaro A, Del Guerra P, et al. Five-year follow-up of percutaneous ethanol injection for the treatment of hyperfunctioning thyroid nodules: a study of 117 patients. *Clin Endocrinol.* 1997;46:9-15.
 22. Del Prete S, Caraglia M, Russo D, Vitale G, Giuberti G, Marra M, et al. Percutaneous ethanol injection efficacy in the treatment of large symptomatic thyroid cystic nodules: ten-year follow-up of a large series. *Thyroid.* 2002;12:815-21.
 23. Lee SJ, Ahn IM. Effectiveness of percutaneous ethanol injection therapy in benign nodular and cystic thyroid disease: long-term follow-up experience. *Endocr J.* 2005;52:455-62.
 24. Alcântara-Jones DM, Araújo LM, Almeida Ade M, Jones Dde A, Cardoso LJ, Passos MC. Efeito da injeção percutânea de etanol na redução de nódulos tireoideanos. *Arq Bras Endocrinol Metab.* 2006;50:97-104.