
Paracoccidioidomycosis chorioretinitis in a patient with Aids

Paracoccidioidomicose causadora de coriorretinite num paciente com Aids

Cláudio Lottemberg¹

Renato A. Neves¹

Rubens Belfort Jr.^{1,2}

Márcia S. Lowen¹

Arnaldo Colombo¹

José R. Rehder¹

Miguel Burnier Jr.^{1,2}

Paracoccidioidomycosis is a deep mycosis caused by a dimorphous fungus (*P. braziliensis*) of intense occurrence in many countries of the world. The infection is supposed to be acquired by inhalation, with a primary localization in the lungs followed by hematogenic spread. It has been described in several parts of the eye such as the eyelids, the conjunctiva and the choroid^(1,2), where it causes a diffuse granulomatous response and secondary retinal involvement in non immunosuppressed hosts⁽¹⁾.

We report herein a patient with Aids that in spite of an absence of visual symptoms and a normal ophthalmologic examination was found

to have *P. braziliensis* present in the choroid upon histologic examination.

CASE REPORT

An hemophiliac, 32 year old black Brazilian male was admitted in May 1989 to the São Paulo Hospital Emergency Room with a septic arthritis, chronic diarrhea and weight loss of 15 kg in the last 6 months. Serology for HIV was tested and was positive. An ocular examination was normal. Two days later the patient died due to acute disseminated Paracoccidioidomycosis and respiratory failure.

A complete autopsy was performed. Several organs were involved

Key words: Paracoccidioidomycosis, chorioretinitis, Aids.

(1) Escola Paulista de Medicina, Hospital São Paulo — São Paulo, Brasil.

(2) National Eye Institute, National Institutes of Health, Bethesda, Maryland, USA.

Endereço para correspondência:

Prof. Dr. Rubens Belfort Jr. — Caixa Postal 4086
— 01051 — São Paulo — SP — Brasil.

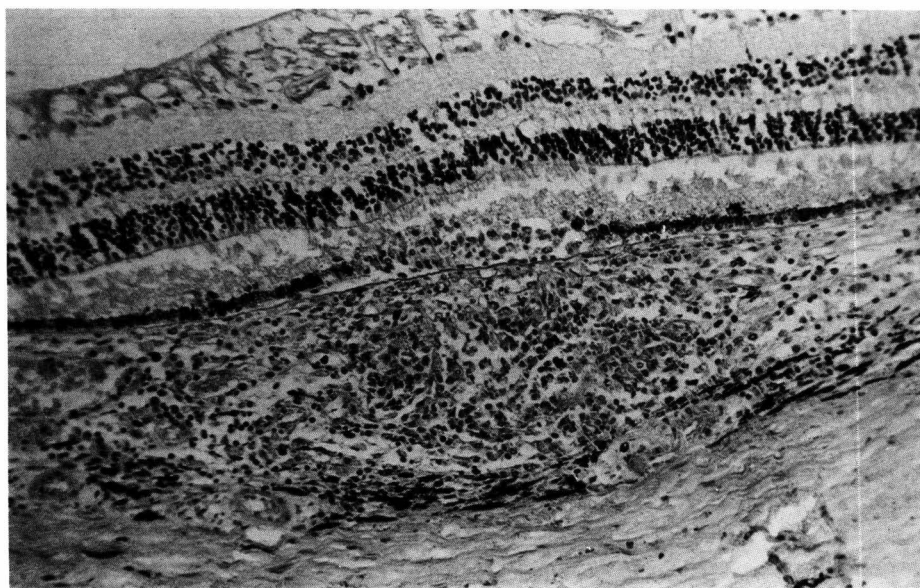


Fig. 1 — Histopathologic section of the right eye disclosed an area of granulomatous inflammation of the choroid with histiocytes and lymphocytes. Within the inflammatory response there are many microorganisms characteristics of *Paracoccidioides brasiliensis* (H&E, 200 x).

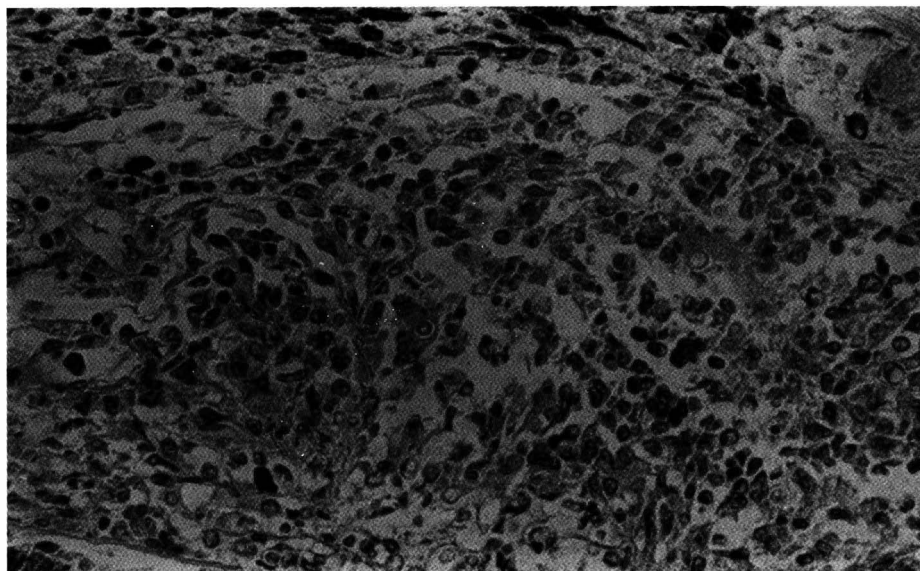


Fig. 2 – High power showing retinal pigment epithelium hyperplasia and many *P. braziliensis* within the granulomatous choroidal reaction (H&E, 400 x).

in the mycotic infection, including the lungs, the central nervous system, the liver and the adrenal glands. Both eyes were enucleated post-mortem and histopathologically studied. The left eye showed no abnormalities both grossly and microscopically. Upon histologic examination the right eye disclosed a granulomatous inflammation of the choroid with retinal pigment epithelium hyperplasia (Fig. 1). Within the area of the granulomatous inflammation there were several round and oval microorganisms, with a birefringent capsule, characteristic of *P. braziliensis* (Fig. 2). The inflammatory infiltrate also involved the retina, with rupture of Bruch's membrane and disorganization of the photoreceptors. The sensory retina overlying the inflammatory reaction was essentially unremarkable. The vitreous and the other tissues of the eye were normal.

DISCUSSION

A single focus of inflammation was found only after inspecting several histopathologic sections, emphasizing the importance of systematic mi-

croscopic examination of eyes of patients with Aids, even in the absence of clinical or gross findings.

Several recent reports^(3,4,5) have emphasized the need to consider Paracoccidioidomycosis in HIV infected persons in countries where this disease is endemic⁽⁶⁾. This agent should therefore be included among the opportunistic mycotic ocular infections in Aids patients.

REFERENCES

1. BONOMO, P.P.; BELFORT, R. Jr; TSUNECHIRO, J.Y.; GIANNOTTI, O.F. – Choroidal granuloma caused by *Paracoccidioides brasiliensis*. *Mycopathologia* 1982; 77: 37-41.
2. BELFORT, R. Jr; FISHMAN, O.; CAMARGO, Z.P.; ALMADA, A.T. – Paracoccidioidomycosis with palpebral and conjunctival involvement. *Mycopathologia* 1975; 56:21-24.
3. BERNARD, G.; BUENO, J.P.; YAMASHIRO-KANASHIRO, E.H.; et al. – Paracoccidioidomycosis in a patient with HIV infection: immunological study. *Trans R Soc Trop Med Hyg* 1990; 84: 151-152.
4. PEDRO, R.J.; AOKI, F.H.; BOCCATO, R.S. et al. Paracoccidioidomycose e infecção pelo vírus da imunodeficiência humana. *Rev Inst Med Trop São Paulo* 1989; 31: 119-125.
5. BAKOS, L.; KRONFELD, M.; HAMPE, S.; CASTRO I.; ZAMPESE, M. – Disseminated paracoccidioidomycosis with skin lesions in a patient with acquired immunodeficiency syndrome. *J Am Acad Dermatol* 1989; 20: 854-855.
6. PINHEIRO, S.R.A.A.; OREFICE, F.; MASSON, E.M. – Blastomicose Sul-Americana: descrição de um caso com lesões cutâneas, nasais e envolvimento do trato uveal posterior. *Arq. Bras. Oftal.* 1987; 50: 66-69.

CONSELHO BRASILEIRO DE OFTALMOLOGIA
CGC 48.939.250/0001-18