

Color vision loss in patients treated with chloroquine

Perdas na visão de cores em pacientes tratados com cloroquina

Dora F. Ventura¹
Luiz Carlos L. Silveira²
Mauro Nishi^{3,4}
Marcelo F. Costa¹
Mirella Gualtieri¹
Ruth M. A. dos Santos²
Carolina T. Pinto²
Ana Laura A. de Moura²
Anderson R. Rodrigues²
Claudio Sakurada³
Maria de Fátima L. C. Sauma⁵
John M. de Souza¹

ABSTRACT

Patients that make use of chloroquine or hydroxychloroquine, drugs which are frequently administered for treatment of rheumatoid arthritis, lupus erythematosus or malaria, may suffer alterations in color vision and in contrast sensitivity. The present work evaluates the visual function of these patients in a joint study of the University of São Paulo (USP), in São Paulo, and of the Federal University of Pará (UFPA), in Belém. Thirty two chloroquine user patients without alterations in the eye fundus exam were evaluated in São Paulo (n=10; aged 38 to 71 years; mean=55,8 years) and in Belém (n=22; aged 20 to 67; mean=40 years). The prescribed accumulated chloroquine dose was 45 to 430 g (mean=213 g; sd= 152 g) for the São Paulo group, and 36 to 540 g (mean=174 g; sd=183 g) for the Belém group. Tests were performed monocularly with corrected eye refractive state. Color discrimination was evaluated using the Cambridge Colour Test (CCT): the color discrimination threshold was measured first in the protan, deutan and tritan axes and, in succession, three MacAdam's ellipses were determined. The patient's color vision was also evaluated with color arrangement tests: the Farnsworth-Munsell 100 Hue (FM100), the Farnsworth-Munsell D15, and the Lanthony Desaturated (D15d) tests. We also measured the contrast sensitivity for black-and-white sine wave grating of twenty two patients. The results were compared with controls without ophthalmologic or neuro-ophthalmologic pathologies. Twenty four patients presented acquired dyschromatopsia. There were cases of selective loss (11 patients) and of diffuse loss (13 patients). Although losses were present in the FM100 there was no correlation between the FM100 error score and the ellipse area measured by the CCT. Moreover, three patients that scored normal in the FM100, failed to reach normal threshold in the CCT. The Lanthony test was less sensitive than the other two tests, since it failed to indicate loss in about half the patients, and the D15 was the least sensitive test, having failed to indicate loss in 9 out of 10 patients. Contrast sensitivity was within normal values for patients submitted to this test. The extent of losses in color discrimination was positively correlated with the accumulated dose. The CCT is recommended for follow up since it provides quantitative data that can be directly interpreted in CIE (Commission Internationale d'Éclairage) color space.

Keywords: Chloroquine; Retinopathy; Color vision; Contrast sensitivity; Neurotoxicology, Neurobehavioral test battery; Dyschromatopsia

¹ Departamento de Psicologia Experimental, Instituto de Psicologia e Núcleo de Neurociências e Comportamento, Universidade de São Paulo, São Paulo, Brasil; ² Departamento de Fisiologia, Centro de Ciências Biológicas, Universidade Federal do Pará, Belém, Brasil; ³ Hospital Universitário, Universidade de São Paulo, São Paulo, Brasil; ⁴ Departamento de Oftalmologia, Escola Paulista de Medicina, Universidade Federal de São Paulo, São Paulo, Brasil; ⁵ Departamento de Medicina Integrada II, Centro de Ciências da Saúde, Universidade Federal do Pará, Belém, Brasil.

Correspondence concerning this article should be addressed to Dora Fix Ventura - Av. Prof. Mello Moraes, 1721 CEP 05508-900, São Paulo, SP, Brasil (email: dventura@usp.br); phone: 11-3091-4444 x223 / Fax: 11-3091-4357.

INTRODUCTION

The neurotoxic effect of some therapeutic drugs is well established⁽¹⁻²⁾. Treatment with 4-aminoquinoline derivatives - chloroquine or hydroxychloroquine- prescribed for rheumatoid arthritis, lupus erythematosus or

malaria, may be accompanied by ocular toxicity that produces a loss of paracentral visual fields, which may develop, in later stages, an annular scotoma. These visual field abnormalities are related with some characteristic ophthalmic findings that include loss of the foveal reflex, with irregular and increased pigmentation in the macula. A ring of depigmentation surrounded by mild increased pigmentation eventually develops, resembling a bull's eye or target. The electroretinogram may show an enlarged a wave or a reduced b wave, and the electro-oculogram may be depressed. These findings may even be present before ophthalmoscopic changes appear and may be accompanied by alterations in color vision⁽³⁾.

The first report of probable ocular toxicity was by Cambiaggi in 1957⁽⁴⁾, when he reported on an unusual retinopathy seen in a patient with systemic lupus erythematosus who was taking chloroquine. However, he did not associate this retinopathy with the use of chloroquine. In 1959, Hobbs and colleagues⁽⁵⁾ made the first association of retinopathy with the use of chloroquine. In the early 1960s there were many reports of chloroquine retinopathy, with most patients taking daily doses averaging 500 mg and total doses sometimes exceeding 1000 g. Initial review of these data⁽⁶⁻⁹⁾ suggested that retinopathy was rare if the total dose of chloroquine was less than 100 g.

These symptoms are probably due to retinal degeneration, reported in 0.5 to 3.5% of patients treated with hydroxichloroquine⁽¹⁰⁻¹¹⁾ and in 10-25% of patients treated with chloroquine⁽¹²⁾.

The retinal degeneration that occurs in chloroquine retinopathy is a cone-rod dysfunction ophthalmoscopically detected in its advanced stages as a bull's eye lesion, usually affecting both eyes, although it may be found unilaterally⁽¹³⁾.

As a rule, long term use of chloroquine increases the risk and severity of retinopathy in a cumulative fashion, related to the total amount of drug taken. However, there are cases of retinopathy with minimal doses^(9,14-15) as well as lack of toxicity in massive doses⁽¹⁶⁾. A recent report associating early susceptibility with mutations in the ABCR (*ABCR4*) gene led to the suggestion of a relationship between retinal toxicity by 4-aminoquinoline derivatives and Stargardt's disease⁽¹⁷⁾. Detection of such susceptibility should constitute a recommendation for careful monitoring of visual function and retinal integrity during drug treatment.

In an effort to achieve early diagnosis of retinal damage, the present work evaluates visual impairment in non-retinopathic users of chloroquine or hydroxichloroquine, with sensitive quantitative methods of assessment of color discrimination and contrast sensitivity. In a joint study of the University of São Paulo (USP), in São Paulo, and of the Federal University of Pará (UFPA), in Belém, we evaluated patient's color discrimination thresholds using the Cambridge Color Test (CCT)⁽¹⁸⁻²¹⁾, color discrimination performance in arrangement tests using the Farnsworth-Munsell 100 Hue (FM100), the Farnsworth-Munsell D15, and the Lanthony desaturated tests⁽¹⁻²²⁾; and patient's contrast sensitivity for black-and-white sine wave grating.

METHODS

Subjects

We studied patients that make use of chloroquine for the treatment of rheumatic diseases but, at the same time, had no ophthalmoscopic signs of retinopathy. Patients were referred by rheumatologists in both centers. All patients were submitted to an ophthalmological examination that included evaluation of corrected visual acuity, biomicroscopy, tonometry and indirect ophthalmoscopy. Patients with any finding that would be related to chloroquine retinopathy or other ophthalmological pathology were excluded from the present study. Informed consent was obtained from all subjects, in accordance with the Declaration of Helsinki determinations.

Patients were tested in São Paulo (n=10; aged 38 to 71 years; mean=55.8 years) and Belém (n=22; aged 20 to 67; mean=40 years). The prescribed accumulated chloroquine dose was 45 a 430 g (mean=213 g; sd=152 g) for the São Paulo group and 36 to 540 g (mean= 174 g; sd=183 g) for the Belém group.

Equipment

The São Paulo group used commercial version of all tests. The Cambridge Colour Test, CCT v2.0, with VSG 5 card and Sony FD Trinitron colour monitor, was purchased from Cambridge Research Instruments, England. The arrangement tests were the Farnsworth Munsell 100 Hue and D15 tests (Gretag Macbeth, N.Y.) and the Lanthony Desaturated test (D15-d Luneau Ophtalmologie, Chartres, France). The Belém group used a self-built system. The software was written using C++ programming language, OFS/Motif 1.1, AIX-Windows R4, and IBM-GL graphic library, all for AIX 3.2.x environment. The software was developed for IBM POWERStation RISC 6000. The stimuli were displayed in IBM 6091 19i colour monitors, 1280 x 1024 pixels, 81.32 kHz horizontal refresh rate, 77 Hz vertical frame rate. They were generated by using IBM GT4-3D graphic adapters, 24 bits / 8 bits per gun. A dithering routine was used to obtain 10 bits grey level resolution. The software was developed by C. R. Botelho-de-Souza (luminance contrast sensitivity test), A. M. Braga (FM100) and author ARR (CCT, FM100).

Procedure

All tests were performed with All tests were performed with spectacles to correct any refractive error.

Cambridge Colour Test

Testing was performed monocularly in a darkened room and with the subject positioned at 3 m from the stimulus monitor. The subject was instructed to indicate the position of a Landolt C opening by pressing the corresponding button in a response box (São Paulo) or the respective keyboard arrows (Belém). The short protocol, the Trivector, was determined first, for screening purposes. Subjects that exceed the values

of $100 \times 10^{-3} u'v'$ units in either the deutan or protan axis or $150 \times 10^{-3} u'v'$ units in the tritan axis were excluded.

The Trivector was followed by a longer procedure, the MacAdam Ellipses protocol. Eight-vector or twenty-vector ellipses were determined in the São Paulo and Belém laboratories, respectively, for all subjects that passed the Trivector protocol. The $u'v'$ coordinates for the center of the three ellipses lied along the protan-deutan axis (Tritanopic set) and were: Field 1: 0.197, 0.469 for Ellipse 1; Field 2: 0.158, 0.473 for

Ellipse 2; Field 3: 0.242, 0.463 for Ellipse 3. These CIE (Commission Internationale d'Éclairage) chromaticities constituted the background colour against which hues corresponding to equally spaced vectors were tested⁽²¹⁾ (Figures 1 and 2).

The CCT used the staircase psychophysical method to measure threshold discrimination, presenting two staircases in random alternation. In each staircase testing began with a saturated hue and proceeded to a less saturated hue every time the subject answered correctly, with a maximum excursion of $0.110 u'v'$ units and a minimum excursion of $0.002 u'v'$ units in this space. Reversibly, incorrect responses or no responses are followed by presentation of hues with higher saturation value. Step size is halved or doubled, following respectively correct or incorrect responses. After a criterion of 6 incorrect responses or 6 reversals, the series is terminated and a threshold is computed. In succession, testing on a new pair of hues is begun. The results are expressed in $u'v'$ coordinates in CIE colour space.

Arrangement Tests

The arrangement tests were used by the São Paulo group in their original formats, according with the test's instructions, with the specified illumination provided by a fluorescent lamp (Sylvania mod. Octron 6500K FO 32W) in an otherwise darkened room. This procedure was followed in the application of the FM100, D15 and Lanthony Desaturated tests.

The Belém group used a locally made computerized version of the FM100. The general procedure is the same as in the commercial version, but all measurements were repeated four times and the results were presented as mean and standard deviation for each data point.

Contrast Sensitivity

The contrast sensitivity was evaluated only in the Belém group of patients. Achromatic contrast sensitivity was measured monocularly, both eyes being alternately tested, at eleven spatial frequencies, ranging from 0.2 to 30 cycles / degree. The stimuli consisted of stationary, black-and-white, vertical sine-wave gratings, with a mean luminance of 188 cd/m^2 , placed at 3 m, subtending 6.5×5 degrees. Each measurement was repeated six times and the mean value was taken as representative of contrast sensitivity.

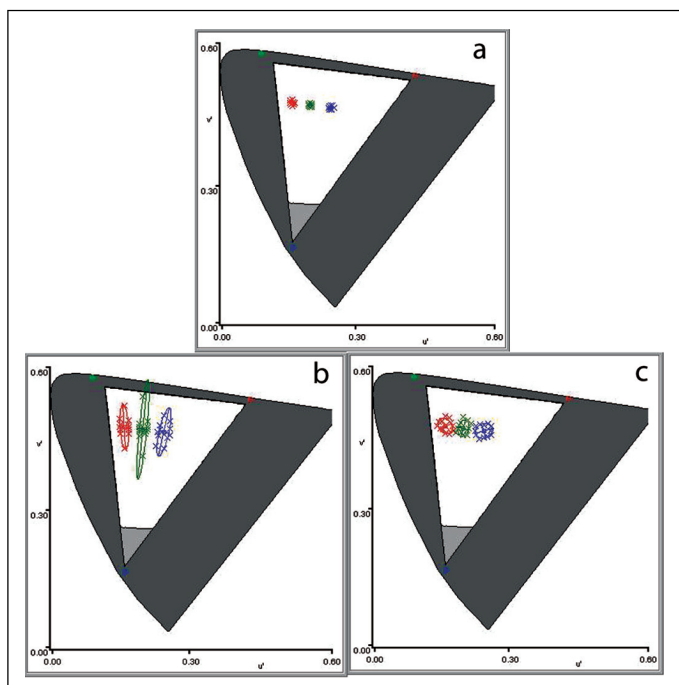


Figure 1 – MacAdam's ellipses measured by the Cambridge Colour Test. Results for a control subject (a), a chloroquine treated patient showing tritan loss (b), and a chloroquine treated patient with diffuse loss (c)

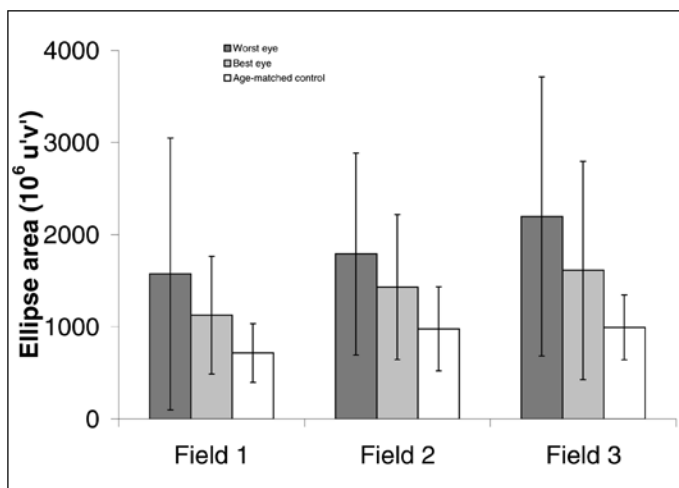


Figure 2 – Average ellipse area for the three fields tested for the worst eye and best eye of chloroquine treated patients and for age-matched controls

RESULTS

All patients presented normal ophthalmological exams with corrected visual acuity of 20/20. No patient was excluded from the present study. In São Paulo, all patients were evaluated in every test. In Belém, all patients were tested in the FM100, but only 5 patients were tested in the CCT.

Nine of the 10 patients tested in São Paulo and 15 of the 22 tested in Belém, presented acquired dyschromatopsia revealed by the CCT and/or by the arrangement tests – the FM 100 and Lanthony. The D15 test was not sensitive enough to

reveal losses in these patients. Since previous work on norms for the CCT (Ventura et al., in press) showed no statistical difference between the ellipse parameters obtained in the São Paulo and Belém setups in normal subjects, all results were grouped. The same was true for the data from the FM 100.

The MacAdam's Ellipses Test

Figure 1 shows the CIE 1976 u'v' color space representation containing MacAdam's ellipses around three chromaticities for two chloroquine treated patients and for an age-matched control subject. The central point in each ellipse represents the background chromaticity and each data point (crosses) is a color discrimination threshold, between the background color and one of the tested colors. The tested colors ranged from red to violet. The resulting ellipse is represented by the interpolated line. The shape of the ellipses obtained reveals the type of colour vision loss. Horizontal ellipses tilted towards the red or green vertices of the color triangle in the diagram correspond to protan or deutan losses, respectively, while ellipses pointing to the blue extremity correspond to tritan losses. A diffuse loss increases the ellipse in all directions.

MacAdam's ellipses obtained in patients treated with chloroquine were enlarged in comparison with those measured in age-matched controls (Figures 1 and 2). The pathologic changes were either tritanopic (6/10 in São Paulo and 2/5 in Belém) or diffuse (3/10 in São Paulo and 3/5 in Belém) and the average ellipse areas were asymmetric for fellow eyes. Total ellipse area from the worst eyes, regardless of shape, showed a statistically significant difference between chloroquine treated patients and controls for Fields 2 and 3 ($p = 0.041$ and $p = 0.046$, respectively) but not for Field 1 ($p = 0.14$). No significant difference was observed when the best eyes from the chloroquine treated group were compared to the control.

The large variability in these data is related to the fact that the patients had different levels of accumulated dose of chloroquine. In fact, accumulated dose of chloroquine was highly positively correlated with ellipse area, especially in Field 3, which is closer to the blue end of the colour space (Figure 3).

Arrangement Tests

Typical results for the FM100 Test are shown in Figure 4 for a control subject and for two chloroquine treated patients, one with diffuse loss, the other with a light tritan loss. The numbers in the periphery of the graph correspond to the Munsell colors that are ordered in the test. The radial plot shows the magnitude of each error that was made when arranging the colours sequentially. Error magnitude indicates the distance between each colour and the next one. A test result with no errors is represented by a radial plot that constitutes a perfect circle. Errors made by subjects with protan, deutan and tritan deficiencies fall along the respective confusion lines.

The average error score for the FM100 test was higher in the chloroquine treated patients than in the age-matched controls and it was different between the two eyes (Figure 5a).

The FM100 error score was worse even after the first few doses of chloroquine for both the best and worst eyes in all patients (Figure 5b and 5c). The best eye results were statistically different from the controls ($p = 0.013$). Twenty four patients showed pathologic changes in the FM100, either tritanopic (5/22 in Belém) or diffuse (9/10 in São Paulo and 10/22 in Belém). However, three patients from the Belém group that scored within the normal range in the FM100, showed tritanopic (2 patients) or diffuse (1 patient) losses in the CCT.

In an attempt to compare the FM100 results with those from the CCT, the ellipse area was plotted against the FM100 error score. The result showed no statistically significant correlation.

The Lanthony test revealed losses in three out of seven patients, while the D15 showed loss in only one of these patients.

Contrast sensitivity

Contrast sensitivity was unaffected by the chloroquine treatment in the patients in which this visual function was evaluated. However, since the group tested in Belém received a lower accumulated dose of chloroquine, a loss in contrast sensitivity is not excluded for higher accumulated doses.

Comparison between test results

The results obtained with the CCT showed that, among chloroquine treated patients, there were cases of selective tritanopic colour vision loss (6/10 in São Paulo and 5/22 in Belém) and of diffuse loss (3/10 in São Paulo and 10/22 in Belém). Although losses were also present in the FM100, there was no statistically significant correlation between the FM100 error score and the ellipse area measured by the CCT. The Lanthony desaturated test was more sensitive and closer to the CCT than the FM100 in the indication of losses. The D15 was not sensitive enough to show these losses. Contrast sensitivity was within normal values for all patients. The extent of the losses in colour discrimination was positively correlated with the accumulated dose.

DISCUSSION

Patients without chloroquine retinopathy presented functional alterations in color discrimination but did not show changes in contrast sensitivity. Colour vision loss due to chloroquine toxicity in these patients increased with accumulated dose values and was present at even the lowest dose (45 g of chloroquine) for at least one patient tested. Colour discrimination was worse in the patients than in the age-matched controls in three of the four tests used – CCT, FM100 and Lanthony desaturated tests. Both the CCT and FM100 were sensitive enough to detect these losses. The Lanthony test was less sensitive than the other two tests, since it failed to indicate loss in about half the patients, and the D15 was the

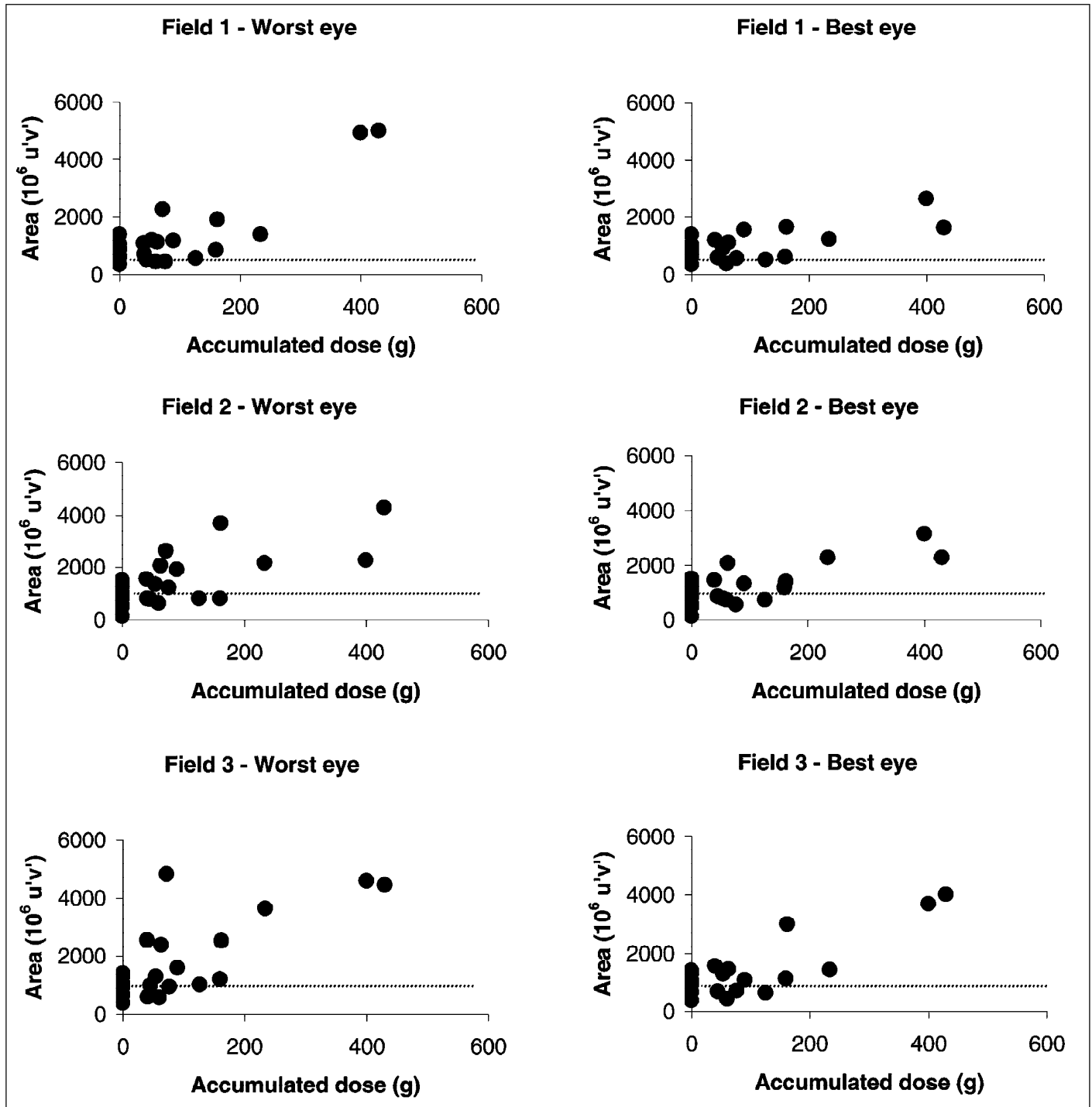


Figure 3 – Relationship between accumulated prescribed dose of chloroquine in grams and ellipse area at the three fields measured, for the worst and best eyes. Each data point is the result of one patient. Age-matched control results are plotted at the zero dose level point. The dashed horizontal line represents the median ellipse area of the control group

least sensitive test, having failed to indicate loss in 9 out of 10 patients. Further work with a larger number of patients is in progress to strengthen and broaden these comparisons.

The finding that in some patients functional changes are associated with very small doses of chloroquine suggests

that these cases correspond to the early susceptibility described by several authors^(9,14-15) and it would be important to find out if these patients have mutations in the ABCR (*ABCR4*) gene, which has been suggested as a link between retinal toxicity by chloroquine and Stargardt's disease⁽¹⁷⁾.

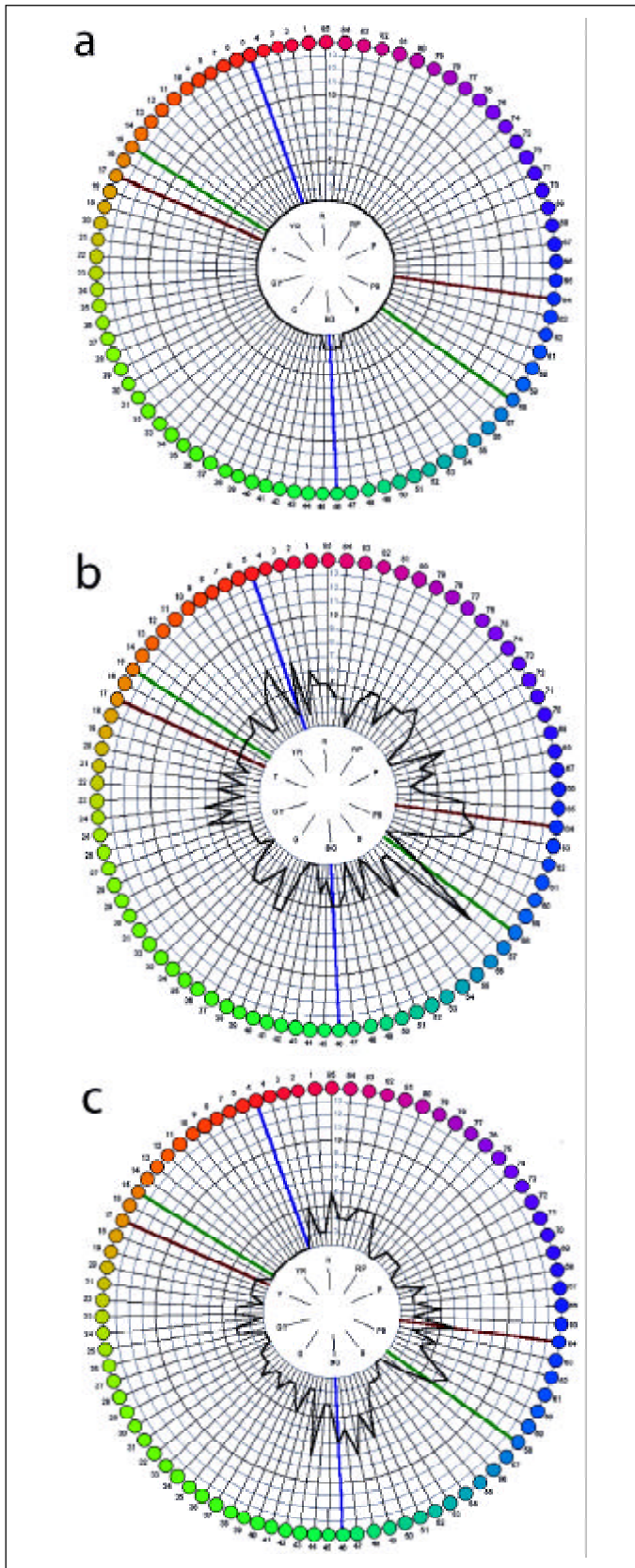


Figure 4 – FM 100 results for an age-matched control subject (a) and two chloroquine treated patients, one showing diffuse (b) and the other tritanopic losses (c)

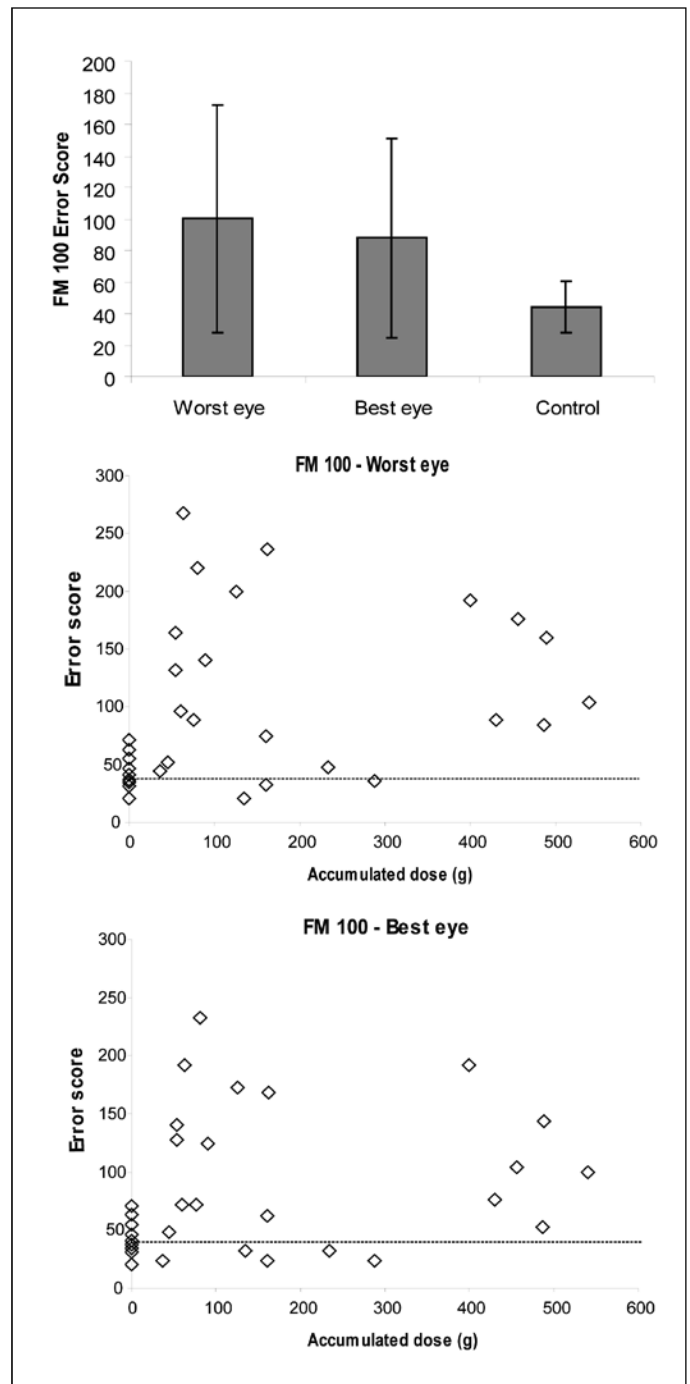


Figure 5 – (a) Average FM 100 error score for the worst eye and the best eyes and for the age-matched controls. (b and c) Relationship between FM 100 error score and accumulated dose for the worst and best eyes, respectively. Each data point is the result of one patient. Age-matched control results are plotted at the zero dose level point. The dashed horizontal line represents the median error score for the control group

The present results support the recommendation made by other authors to monitor visual function during treatment with chloroquine. Among the tests used here, the CCT is the most highly recommended for both diagnosis and follow up because it is sensitive, uses a very rigorous psychophysical

procedure and provides quantitative data that can be directly interpreted in CIE colour space, while the FM100 is a test that is influenced by training and by other subjective factors.

RESUMO

Pacientes que fazem uso de cloroquina ou hidróxi-cloroquina, drogas que são freqüentemente administradas para o tratamento de artrite reumatóide, lúpus eritematoso ou malária, podem sofrer alterações na visão de cores e na sensibilidade de contraste. O presente estudo avaliou a função visual destes pacientes em um estudo conjunto da Universidade de São Paulo (USP), em São Paulo, e da Universidade Federal do Pará (UFPA), em Belém. Trinta e dois pacientes usuários de cloroquina sem alterações no exame de fundo de olho foram avaliados em São Paulo (n=10, 38 a 71 anos, média=55,8 anos) e em Belém (n=22, 20 a 67 anos, média=40 anos). A dose acumulada de cloroquina prescrita foi de 45 a 430 g (média=213 g; dp=152 g) para o grupo de São Paulo, e de 36 a 540 g (média=174 g; dp=183 g) para o grupo de Belém. Os testes foram realizados monocularmente com o estado refracional corrigido. A discriminação de cor foi avaliada utilizando o Teste de Cor de Cambridge (CCT): o limiar de discriminação de cor foi mensurado primeiro nos eixos protano, deutano e tritano, e em seqüência, três elipses de MacAdam foram determinadas. A visão de cores dos pacientes também foi avaliada com testes de arranjo de cores: o teste de 100 matizes de Farnsworth-Munsell (FM100), o D15 de Farnsworth-Munsell, e o teste Lanthony Dessaturado (D15d). A sensibilidade de contraste foi também medida com grades senoidais preto-e-brancas em 22 pacientes. Os resultados foram comparados com controles sem patologias oftalmológicas ou neuro-oftalmológicas. 24 pacientes apresentaram discromatopsia adquirida, com perdas seletivas (11 pessoas) ou difusas (13 pessoas). Embora as perdas estivessem presentes no FM100, não houve correlação entre o escore de erro do FM100 e a área elíptica medida pelo CCT. Além disso, três pacientes que tiveram escores normais no FM100 falharam para alcançar limiares normais no CCT. O teste de Lanthony foi menos sensível do que os outros dois testes, tal que falhou em indicar perda em cerca de metade dos pacientes afetados, e o D15 foi o teste menos sensível, deixando de indicar déficits em 9 de 10 pacientes. A sensibilidade de contraste esteve dentro dos valores normais para pacientes submetidos a este teste. A extensão das perdas na discriminação de cores foi positivamente correlacionada com a dose acumulada. O CCT é recomendado para o acompanhamento destes pacientes, pois forneceu dados quantitativos que podem ser diretamente interpretados no espaço cromático da CIE (Commission Internationale d'Éclairage).

Descritores: Cloroquina; Retinopatia; Visão de cores; Sensibilidade de contraste; Neurotoxicologia; Bateria de testes neurocomportamentais; Discromatopsia

ACKNOWLEDGEMENTS

This work was supported by FAPESP # 0030/00-98, FINEP #66.95.0407.00, CNPq #523303/95-5 and CAPES-PROCAD grants to D.F.V.; FINEP-PNOPG #090/00-99, FINEP/CNPq-PRONEX, CNPq-PNOPG #550663/2001-0, and CNPq #521640/96-2, CAPES-RENOR, IBM and UFPA-PROINT #372/2001 grants to L.C.L.S. D.F.V., L.C.L.S., and J.M.S. are CNPq research fellows. M.F.C. and A.R.R. have graduate fellowships from CAPES, whilst M.G., R.M.A.S., C.T.P. and A.L.A.M. have undergraduate fellowship from CNPq. We thank Claudiel Luiz dos Santos and Jocely Costa Barata for administrative assistance.

REFERENCES

- Birch J. Diagnosis of Defective Color Vision. New York: Oxford University Press, 1993.
- Pokorny J, Smith VC, Verriest G, Pinckers AJLG. Congenital and Acquired Color Vision Defects. New York: Grune & Stratton, 1979.
- Easterbrook M. Detection and prevention of maculopathy associated with antimalarial agents. *Int Ophthalmol Clin* 1999;39:49-57.
- Cambiaggi A. Unusual ocular lesions in a case of systemic lupus erythematosus. *Arch Ophthalmol* 1957;57:451.
- Hobbs HE, Sorsby A, Freedman A. Retinopathy following chloroquine therapy. *Lancet* 1959;2:478.
- Hobbs HE, Eadie SP, Somerville F. Ocular lesions after treatment with chloroquine. *Brit J Ophthalmol* 1961;45:284.
- Hendkind P, Rothfield NF. Ocular abnormalities in patients treated with synthetic antimalarial drugs. *N Engl J Med* 1963;269:433.
- Arden GB, Kolb H. Antimalarial therapy and early retinal changes in patients with rheumatoid arthritis. *Brit Med J* 1966;5482:270.
- Nylander U. Ocular damage in chloroquine therapy. *Acta Ophthalmol Scand* 1966;44:335-48.
- Levy GD, Munz SJ, Paschal J, et al. Incidence of hydroxychloroquine retinopathy in 1,207 patients in a large multicenter outpatient practice. *Arthritis Rheum* 1997;40:1482-6.
- Mavrikakis M, Papazoglou S, Sfrikakis PP, et al. Retinal toxicity in long term hydroxychloroquine treatment. *Ann Rheum Dis* 1996;55:187-9.
- Finbloom DS, Silver K, Newsome DA, Gunkel R. Comparison of hydroxychloroquine and chloroquine use and the development of retinal toxicity. *J Rheumatol* 1985;12:692-4.
- Nomura R, Kondo M, Tanikawa A, Yamamoto N. Unilateral cone dysfunction with bull's eye maculopathy. *Ophthalmology* 2001;108(1):49-53.
- Voipio H. Incidence of chloroquine retinopathy. *Acta Ophthalmol Scand* 1966;44:349-54.
- Silman A, Shipley M. Ophthalmological monitoring for hydroxychloroquine toxicity: a scientific review of available data. *Brit J Rheumatol* 1997;36:599-601.
- Johnson MW, Vine AK. Hydroxychloroquine therapy in massive total doses without retinal toxicity. *Am J Ophthalmol* 1987;104:139-44.
- Shroyer NF, Richard AL, Lupski JR. Analysis of the ABCR (ABCA4) gene in 4-Aminoquinoline retinopathy: is retinal toxicity by chloroquine and hydroxychloroquine related to Stargardt disease? *Am J Ophthalmol* 2001; 131(6):761-6.
- Mollon JD, Reffin JP. A computer-controlled colour vision test that combines the principles of Chibret and Stilling. *J Physiol* 1989;41(4):5.
- Mollon JD, Reffin J P. Handbook of the Cambridge Colour Test. London: Cambridge Research Systems (www.crsLtd.com), 2000.
- Reffin JP, Astell S, Mollon JD. Trials of a computer-controlled colour vision test that preserves the advantages of pseudoisochromatic plates. In: Drum B, Moreland JD, Serra A, editors, *Colour Vision Deficiencies X*. Dordrecht: Kluwer, 1991: p.69-76.
- Regan BC, Reffin JP, Mollon JD. Luminance noise and the rapid determination of discrimination ellipses in colour deficiency. *Vision Res*, 1994;34: 1279-99.
- Committee on Vision. Procedures for Testing Color Vision. Washington, DC: National Academy Press, 1981.