

# Retinal nerve fiber layer loss documented by Stratus OCT™ in patients with pituitary adenoma: case report

*Perda da camada de fibras nervosas retiniana documentada por meio do Stratus OCT™ em pacientes com adenoma hipofisário: relato de caso*

Bruno Campelo Leal<sup>1</sup>  
Frederico Castelo Moura<sup>2</sup>  
Mário Luiz Ribeiro Monteiro<sup>3</sup>

## ABSTRACT

**Purpose:** To report abnormalities of retinal nerve fiber layer (RNFL) thickness using optical coherence tomography (Stratus OCT™) in patients with pituitary adenoma. **Methods:** Two patients with long-standing bitemporal visual field defects and optic nerve band atrophy were submitted to optical coherence tomography examination (Stratus OCT™). **Results:** Both patients with band atrophy revealed diffuse loss of the retinal nerve fiber layer on Stratus OCT™, with severe reduction in the nasal and temporal areas of the optic disc. Retinal nerve fiber layer loss correlated well with visual field loss and with previous histological studies of band atrophy of the optic nerve. **Conclusions:** Stratus optical coherence tomography can provide useful information in the diagnosis of band atrophy from chiasmal lesions such as pituitary adenomas.

**Keywords:** Pituitary neoplasms; Retinal ganglion cells/cytology; Tomography, optical coherence; Optic chiasm/abnormalities; Nerve fibers/pathology; Vision disorders; Case reports [publication type]

## INTRODUCTION

Pituitary adenomas are among the most important causes of lesions in optic pathways and produce bitemporal visual field loss due to chiasmal compression. Abnormalities in the retinal nerve fiber layer (RNFL) in long-standing lesions are also characteristic<sup>(1)</sup>. In such cases, the crossed nerve fibers are lost with preservation of the uncrossed nerve fibers. Therefore, RNFL loss occurs predominantly in the nasal and temporal side of the optic disc, a pattern identified on ophthalmoscopy as band atrophy (BA) that is important in diagnosis and in estimating the chances of visual improvement after optic pathway decompression<sup>(2-4)</sup>.

Optical coherence tomography (OCT) is an *in vivo* technique for acquisition of cross-sectional images of retinal structures from which estimates of the thickness of retinal layers can be made. Recent studies showed that OCT-1 was able to distinguish mean values of RNFL of eyes with BA from those of normal controls in two series of patients<sup>(5-6)</sup>. However, due to large variation of normal values, very often it is difficult to define RNFL as abnormal in an individual patient. The newer version of OCT (Stratus OCT™) has incorporated advances in image acquisition and provides a classification (within normal limits, borderline, or outside normal limits) for each studied parameter based on comparison with an internal normative database. We had the opportunity of documenting the usefulness of such program in two patients with pituitary adenomas that demonstrated good correlation with the expected pattern of RNFL loss.

Department of Ophthalmology, Faculdade de Medicina da Universidade de São Paulo - USP - São Paulo (SP) - Brasil.

<sup>1</sup> Postgraduate student of Department of Ophthalmology, Faculdade de Medicina da Universidade de São Paulo - USP - São Paulo (SP) - Brasil.

<sup>2</sup> Associate Professor of Department of Ophthalmology, Faculdade de Medicina da USP - São Paulo (SP) - Brasil.

<sup>3</sup> Associate Professor of Department of Ophthalmology, Faculdade de Medicina da USP - São Paulo (SP) - Brasil.

**Endereço para correspondência:** Mário Luiz Ribeiro Monteiro, Av. Angélica, 1757 - Conj. 61 - São Paulo (SP) CEP 01227-200  
E-mail: mlrmonteiro@terra.com.br

Recebido para publicação em 03.05.2005

Versão revisada recebida em 13.11.2005

Aprovação em 23.11.2005

Os autores não têm interesse comercial no equipamento utilizado neste estudo.

**Nota Editorial:** Depois de concluída a análise do artigo sob sigilo editorial e com a anuência do Dr. Eric Pinheiro de Andrade sobre a divulgação de seu nome como revisor, agradecemos sua participação neste processo.

CASE REPORTS

Case 1

A 49-year-old man complained of visual loss 20 years previously when a large pituitary adenoma was diagnosed. Surgical removal and postoperative use of bromocriptine resulted in visual improvement, however, a severe temporal visual loss remained in both eyes. Ophthalmic examination revealed a visual acuity of 20/20 in each eye. Fundus examination showed diffuse band atrophy of the optic disc in each eye and visual field testing revealed severe bitemporal hemianopia (Figure 1). Stratus OCT™ showed diffuse reduction of RNFL in both eyes including the nasal and temporal portions of the disc (Figure 1).

Case 2

A 36-year-old woman presented headache and visual loss 10 years previously and was diagnosed as having a large pituitary

adenoma that was surgically removed. On examination her best corrected visual acuity was 20/20 in the right eye (OD) and 20/25 in the left eye (OS). She had bitemporal hemianopic scotomas with I/4e target and complete temporal hemianopia with I/2e target in both eyes (Figure 2). Fundus examination revealed band atrophy of the optic disc in both eyes. Stratus OCT™ examination showed diffuse reduction of RNFL in both eyes, including the nasal and temporal portions of the disc (Figure 2).

DISCUSSION

In both cases Stratus OCT™ demonstrated RNFL loss involving predominantly the nasal and temporal portions of the disc, with relative preservation of the superior and inferior quadrants. Such findings are in agreement with Mikelberg and Yidegilgne's<sup>(3)</sup> histological analysis of a patient with band

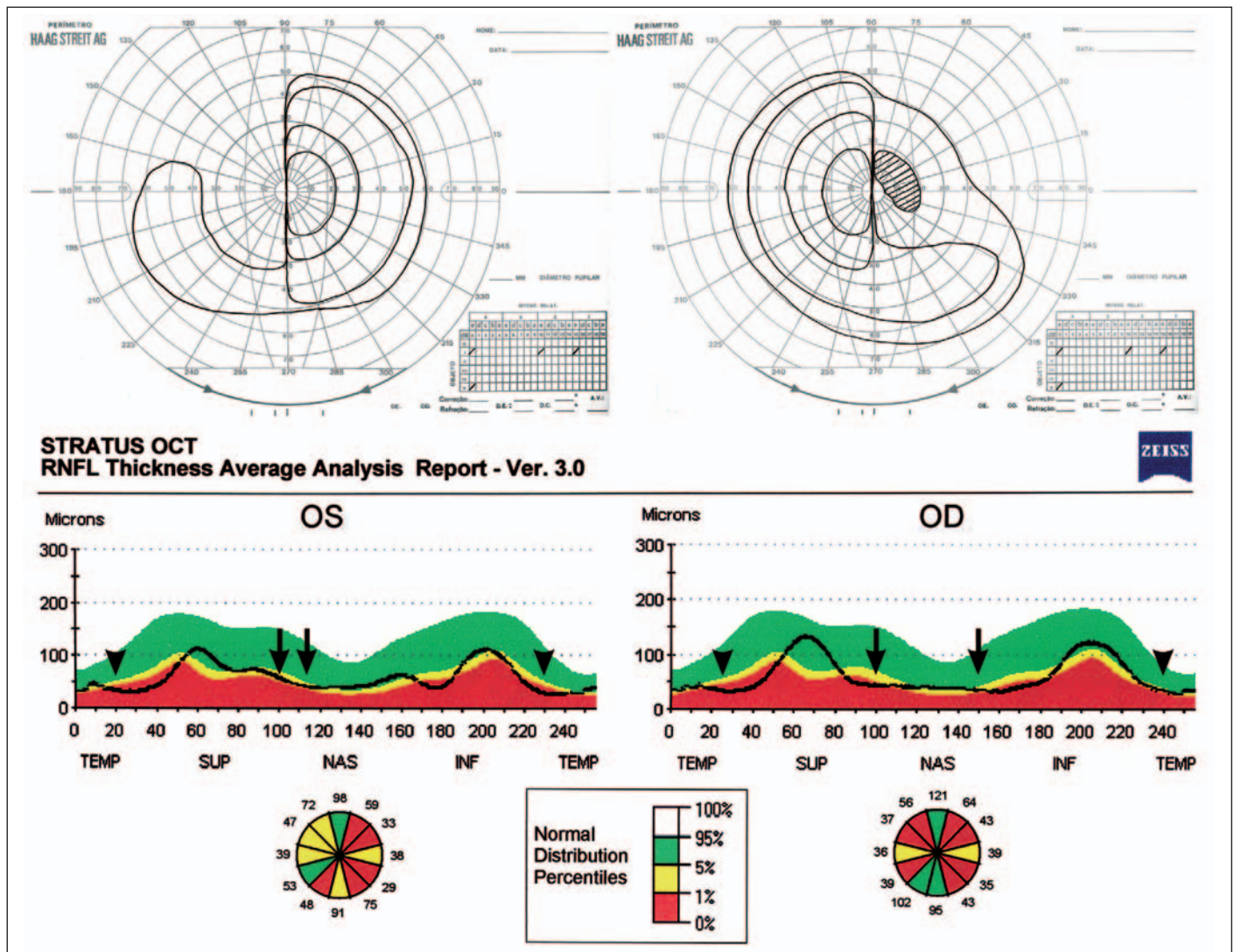


Figure 1 - Case 1: Goldmann visual fields showing bitemporal severe loss. Stratus OCT™ showing diffuse retinal nerve fiber layer loss in both eyes especially involving the nasal (arrows) and temporal (arrowheads) aspects of the optic nerve

atrophy and seems to confirm a better potential of OCT when compared to the scanning laser polarimetry (SLP) in evaluating RNFL in the nasal and temporal areas of the disc<sup>(4-6)</sup>. In a previous study using an early commercial version of OCT (OCT-1), we have documented that RNFL measurements in patients with BA were significantly different from normal ones in each quadrant as well as in each of twelve, 30-degree segments of the disc<sup>(5)</sup>, a finding confirmed by the study of Kanamori et al.<sup>(6)</sup>. Large normal range and absence of a normative database in OCT-1, however, many times makes it difficult to define as abnormal an individual case. In this paper we have documented good correlation of the normative database of Stratus OCT™ and the expected RNFL loss. Further studies with a larger number of patients, however, are necessary in order to better understand the real value of such normative database in diagnosis and management of diseases of the anterior visual pathways.

**RESUMO**

**Objetivo:** Relatar alterações na camada de fibras nervosas retiniana (CFNR) com o uso da tomografia de coerência óptica (Stratus OCT™) em pacientes com adenoma hipofisário. **Métodos:** Dois pacientes com defeito perimétrico bitemporal de longa duração e atrofia em banda do nervo óptico foram examinados com tomografia de coerência óptica (Stratus OCT™). **Resultados:** Ambos pacientes demonstraram perda difusa da camada de fibras nervosas retiniana com redução acentuada nas regiões nasal e temporal do disco óptico. A perda da camada de fibras nervosas retiniana se correlacionou com o defeito de campo visual e com os estudos histológicos de atrofia em banda do nervo óptico. **Conclusões:** A tomografia de coerência óptica (Stratus OCT™) pode apresentar grande utilidade no diagnóstico da atrofia em banda decorrente de lesões quiasmáticas tais como os adenomas pituitários.

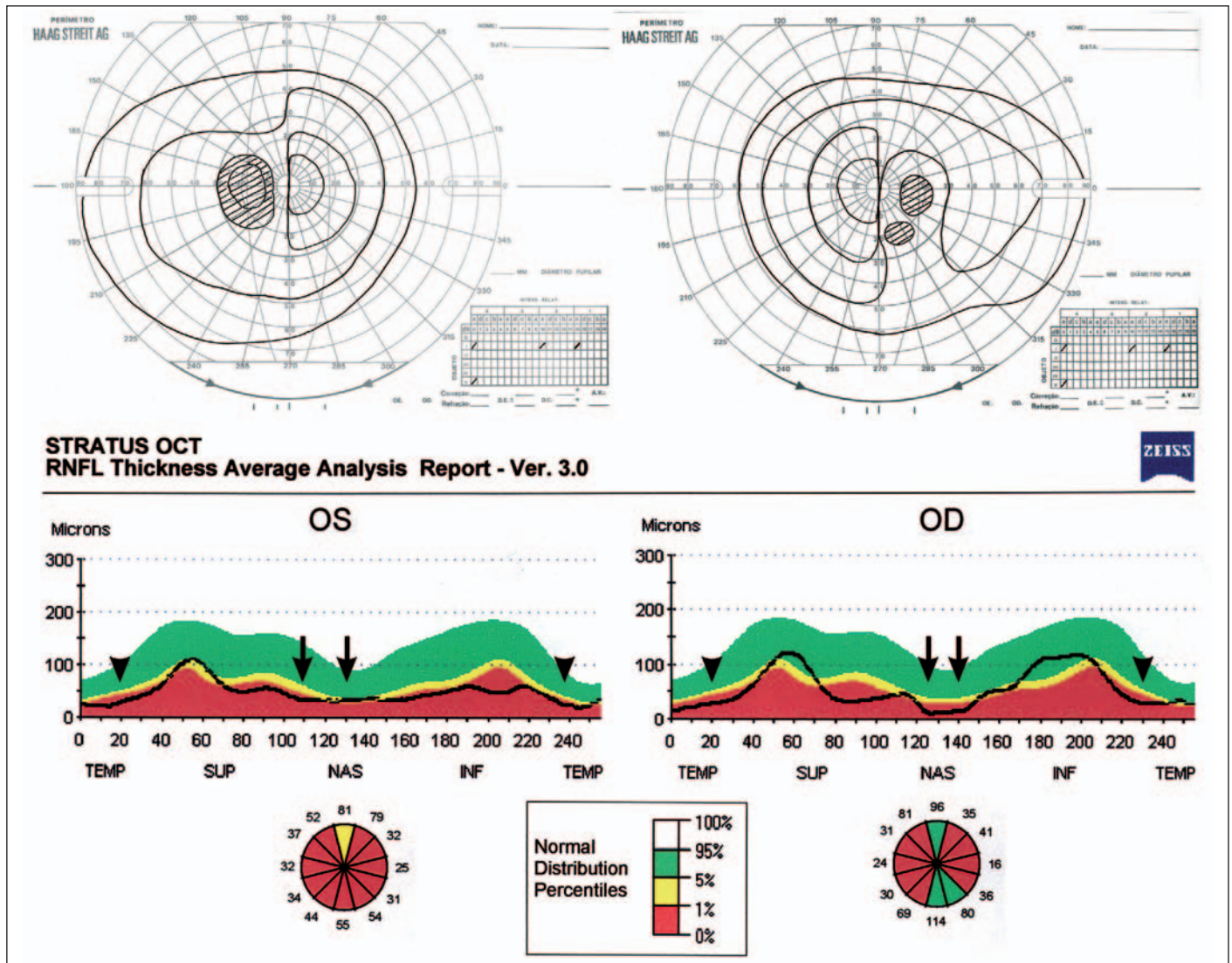


Figure 2 - Case 2: Goldmann visual fields showing bitemporal hemianopic scotomas. Stratus OCT™ showing diffuse reduction of RNFL in both eyes, including the nasal (arrows) and temporal (arrowheads) portions of the disc

**Descritores:** Neoplasias hipofisárias; Células do glângio retiniano/citologia; Tomografia de coerência óptica; Quiasma óptico/abnormalidades; Fibras nervosas/patologia; Transtornos da visão; Relato de casos [tipo de publicação]

---

#### REFERENCES

---

1. Tanito M, Itai N, Goto T, Ohira A, Chihara E. Abnormalities of scanning laser polarimetry associated with pituitary adenoma. *Am J Ophthalmol.* 2003;135(4):565-7.

2. Unsöld R, Hoyt WF. Band atrophy of the optic nerve. The histology of temporal hemianopia. *Arch Ophthalmol.* 1980;98(9):1637-8.
3. Mikelberg FS, Yidegiligne HM. Axonal loss in band atrophy of the optic nerve in craniopharyngioma: a quantitative analysis. *Can J Ophthalmol.* 1993;28(2): 69-71.
4. Monteiro MLR, Medeiros FA, Ostroski MR. Quantitative analysis of axonal loss in band atrophy of the optic nerve using scanning laser polarimetry. *Br J Ophthalmol.* 2003;87(1):32-7.
5. Monteiro ML, Leal BC, Rosa AA, Bronstein MD. Optical coherence analysis of axonal loss in band atrophy of the optic nerve. *Br J Ophthalmol.* 2004;88(7): 896-9.
6. Kanamori A, Nakamura M, Matsui N, Nagai A, Nakanishi Y, Kusuhara S, et al. Optical coherence tomography detects characteristic retinal nerve fiber layer thickness corresponding to band atrophy of the optic discs. *Ophthalmology.* 2004;111(12):2278-83.

## XXIX Simpósio de Oftalmologia da UNIFESP

### Instituto da Visão

**3 a 5 de Agosto de 2006**

**LOCAL:**

**GRAN MELIÁ MOFARREJ  
Al. Santos, 1437 • São Paulo (SP)**

**TEMA: NOVAS TECNOLOGIAS**

**CURSOS E SIMPÓSIOS:**

- Atualização Clínica e Cirúrgica nas diversas áreas da Oftalmologia
- Programas de imersão no Pré-Congresso
- Atualização em Clínica Médica para oftalmologistas
- Atualização em Medicina Celular e Células-tronco aplicadas à Oftalmologia
- Cirurgias ao vivo
- Wet Labs
- Investimentos e Finanças pessoais

**MAIORES INFORMAÇÕES PELO SITE**

**[www.oftalmo.epm.br/simasp](http://www.oftalmo.epm.br/simasp)**