

# Treatment outcomes in VI nerve palsy corrected by Carlson & Jampolsky technique

## *Resultados do tratamento da paralisia de VI nervo operada pela técnica de Carlson-Jampolsky*

Fábio Ejzenbaum<sup>1</sup>  
Janine Radd Ferreira Pinto<sup>2</sup>  
Carlos Ramos Souza-Dias<sup>3</sup>  
Mauro Goldchmit<sup>4</sup>

### ABSTRACT

**Purpose:** To study the results of Carlson & Jampolsky technique in 31 patients with VI nerve palsy. **Methods:** We had 23 unilateral and 8 bilateral cases. The mean unilateral preoperative esotropia was  $56.8 \text{ PD} \pm 24 \text{ PD}$  (30 PD to 100 PD) and they had a mean postoperative follow-up of  $14 \pm 17.9$  months (3 to 72). The mean bilateral preoperative esotropia deviation angle in primary position was  $74.5 \text{ PD} \pm 20.7 \text{ PD}$  (45 PD to 100 PD) and the mean postoperative follow-up was  $14.7 \pm 15.7$  months (4 to 47). **Results:** In the unilateral group, 18 patients had good results and reoperation was not necessary. Out of 5 patients who were reoperated (2 undercorrections and 3 overcorrections), 2 had to use prismatic glasses. Among the bilateral patients, 2 cases were reoperated (1 undercorrection and 1 overcorrection), and the undercorrected patient remained with esotropia (ET13 PD), and also had to use prismatic glasses. **Conclusions:** Carlson & Jampolsky technique was useful to treat patients with VI nerve palsy. We had low reoperation rates and, among the 7 patients who needed a second intervention, only 3 did not achieve good results.

**Keywords:** Ophthalmoplegia; Strabismus; Esotropia/surgery; Ophthalmologic surgical procedures/methods; Abducens nerve/surgery; Oculomotor muscles; Postoperative complications

Study carried out at the Department of Ophthalmology, Faculdade de Ciências Médicas da Santa Casa de Misericórdia de São Paulo - São Paulo (SP) - Brazil.

<sup>1</sup> PhD in Ophthalmology from the Universidade Federal de São Paulo - UNIFESP - São Paulo (SP), Brazil. Voluntary assistant physician at the Service of Strabismus, Department of Ophthalmology, Faculdade de Ciências Médicas da Santa Casa de Misericórdia São Paulo - São Paulo (SP) - Brazil.

<sup>2</sup> Resident (year 2) at the Department of Ophthalmology, Faculdade de Ciências Médicas da Santa Casa de Misericórdia de São Paulo - São Paulo (SP) - Brazil.

<sup>3</sup> Full Professor at the Department of Ophthalmology, Faculdade de Ciências Médicas da Santa Casa de Misericórdia de São Paulo - São Paulo (SP) - Brazil. Post-doctorate degree from the Universidade Federal de São Paulo - UNIFESP - São Paulo (SP) - Brazil.

<sup>4</sup> PhD and Master's degree in Ophthalmology from the Universidade Federal de São Paulo - UNIFESP - São Paulo (SP), Brazil. Head of the Service of Strabismus, Department of Ophthalmology, Faculdade de Ciências Médicas da Santa Casa de Misericórdia de São Paulo - São Paulo (SP) - Brazil.

**Correspondence to:** Fábio Ejzenbaum. Rua Albuquerque Lins, 1144 - Apto. 82 - São Paulo (SP) CEP 01230-001  
E-mail: fabio\_e@terra.com.br

Recebido para publicação em 20.02.2007  
Aprovação em 09.08.2007

### INTRODUCTION

Transposition of the vertical rectus muscle for treatment of paralytic strabismus was first proposed by \*Hummelsheim in 1907<sup>(1)</sup>. The lateral halves of the superior and inferior rectus muscles are transposed toward the lateral rectus insertion and reinserted close to its ends, a method aiming to improve eye abduction. Many modifications have been suggested since then. Jensen<sup>(2)</sup>, in 1964, proposed a method in which he splits the superior and inferior rectus muscles fibers into medial and lateral halves and then unites them with the upper and lower halves of the also split lateral rectus muscle in the region of the equator, intended to avoid anterior segment ischemia. Carlson & Jampolsky<sup>(3)</sup> described an adjustable transposition, associated to medial rectus muscle (MR) adjustable recession in case of contracture.

\*Hummelsheim (1907) apud<sup>(1)</sup>

In this study, we assessed the charts of 31 patients with sixth nerve palsy, who were operated on using the Carlson & Jampolsky technique (C&J), in terms of functional results and reoperation rate.

## METHODS

The records of 31 patients with VI nerve palsy were retrospectively examined - in that, 8 were bilateral and 23 were unilateral cases. All patients were submitted to the C&J technique (Figure 1), which consists of superior and inferior rectus muscle hemitransposition associated to medial rectus adjustable recession in the cases in which this muscle is found contracted. The operation technique is described below (Figure 1)<sup>(4)</sup>.

This operation was performed in both eyes in bilateral cases.

The mean age of unilateral patients was  $39.7 \pm 16.4$  years (7 to 70), and of the squint was  $28.4 \pm 40$  months (1.5 to 180). The mean preoperative esotropia (ET) deviation angle in primary position was  $56.8 \text{ PD} \pm 24 \text{ PD}$  (30 PD to 100 PD). The mean postoperative follow-up was  $14 \pm 17.9$  months (3 to 72). All patients had medial rectus recession. Ten patients had medial rectus adjustment after the surgery, 6 for overcorrection and 4 for undercorrection.

The mean age of bilateral patients was  $25 \pm 16.7$  years (13 to 52), and of the squint was  $26.8 \pm 30.5$  months (3 to 90). The mean preoperative ET deviation angle in primary position was  $74.5 \text{ PD} \pm 20.7 \text{ PD}$  (45 PD to 100 PD). The mean postoperative follow-up was  $14.7 \pm 15.7$  months (4 to 47). Six patients had medial rectus recession, and only one had adjustment for undercorrection after the surgery.

The abduction deficit was recorded as follows<sup>(5-6)</sup>: zero (normal); -1 (to 75% full rotation); -2 (to 50% full rotation); -3 (to 25% full rotation); -4 (to midline); and -5 (inability to abduct to the midline). All patients were classified as having -5 or -4 active abduction deficit (mean of  $4.5 \pm 0.7$ ). The passive duction test showed relative restriction in 16 patients (2 bilateral) and absolute restriction in 15 patients. Forced generation test revealed small force in 7 patients (1 bilateral) and absence of muscle force in 24 patients.

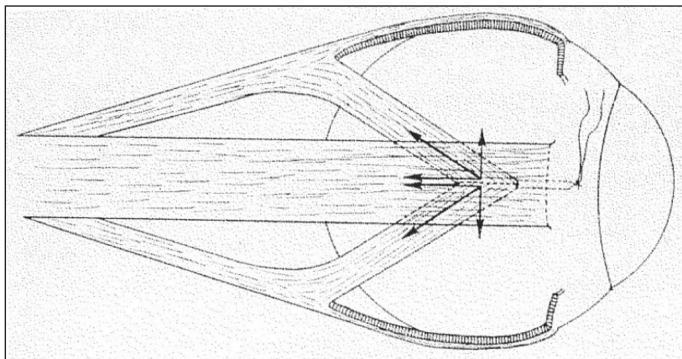


Figure 1 - Schematic drawing of Carlson & Jampolsky hemitransposition technique<sup>(4)</sup>

We considered as good results patients who achieved single binocular vision in the primary position at distance fixation, without or with a small head turn ( $<5^\circ$ ).

## RESULTS

The unilateral group had a mean deviation correction of  $55 \text{ PD} \pm 26 \text{ PD}$  (25 to 115).

The postoperative abduction deficit varied from -2 to -3 (mean of  $-1.4 \pm 0.8$ ) and adduction varied from 0 to -3 (mean of  $-1 \pm 0.8$ ) with an adduction deficit of -3 in only one patient, who had an overcorrection of esotropia of 15 PD.

Five patients had bad results and underwent re-recession or advancement of the medial rectus, 2 for undercorrection (residual esotropia of 10 PD and 20 PD) and 3 for overcorrection (2 patients with consecutive exotropias (XT) of 20 PD, one with 12 PD). Two of them did not have a good final motor alignment (1 ended up with ET 12 PD and the other with XT 15 PD). Those patients feel comfortable with prismatic glasses.

Among the 18 patients who had to be reoperated, 9 (50%) had small head turn for achieving fusion in primary position (all with residual esotropia, with an average of  $7 \pm 3 \text{ PD}$ , and one had a 5 PD hypertropia).

The bilateral group had a mean deviation correction of  $76.2 \text{ PD} \pm 20 \text{ PD}$  (45 to 105).

The postoperative abduction deficit varied from -2 to -4 (mean of  $-3.5 \pm 0.6$ ) and adduction varied from 0 to -2 (mean of  $-1.1 \pm 0.85$ ).

Bad results were found in two patients: one undercorrected ET20 PD who had a MR re-recession and one overcorrection (XT15 PD) who had a MR advancement as a second surgical procedure. Only the undercorrected patient did not achieve a good final result (ET13 PD), but he was comfortable with prismatic glasses. The other had only XT4 PD and a small compensatory head turn.

Among the 6 patients who did not require reoperation, only one (15%) had a small head turn for achieving fusion in primary position (residual esotropia of 10 PD).

## DISCUSSION

In this study, the success rate with the Carlson & Jampolsky surgery was 77% (patients who did not need reoperation), and similar results were obtained in the unilateral (78%) and bilateral cases (75%).

In a multicentric study on the sixth nerve palsy<sup>(7)</sup>, 11 patients were treated with transposition surgery or botulin toxin plus transposition surgery. They did not report which transposition was used. They had good results in the cases treated with toxin plus surgery, but the transposition success rate of patients who did not receive botulin toxin was 0%, probably because their criteria were more limited than ours

(no esotropia and no head turn in primary position), which is difficult to achieve in VI nerve palsy, and probably the cases who did not receive toxin botulin had an important medial rectus contracture. For complete chronic VI nerve palsies, other authors<sup>(8)</sup> reported on 20 out of 26 patients (77%) with at least 60" of stereopsis on the Titmus test postoperatively, after a Jensen procedure. Nevertheless, 58% of their patients had no face turn postoperatively, a result higher than ours (13 patients or 47%). Another study<sup>(9)</sup> observed that out of 10 patients with VI nerve palsy who underwent C&J operation, 8 ended with no horizontal deviation in primary position. Others authors<sup>(10)</sup> reported 11 cases who had C&J surgery and only 2 patients did not obtain good results (XT10 PD, XT16 PD).

The increased lateral rotation achieved with this kind of operation is due to relaxation of the antagonist medial rectus muscle, combined with the passive abduction force provided by the "tonic" primary position innervation of the transposed vertical muscles<sup>(11)</sup>, which, according to Scott<sup>(12)</sup>, moves about 10 -15 g toward abduction. This force is insufficient to provide full abduction, thus, probably those 4 patients, who were classified as having a lateral rectus paralysis, in fact had had preoperatively a partial recovery of lateral rectus force and an important contracture of the medial rectus muscle caused the abduction limitation, which led to the diagnosis of paralysis instead of paresis.

Another concern in all surgical procedures to eliminate esotropia caused by lateral rectus muscle paralysis is the consequent limitation of adduction. In our study, we had only one patient with adduction deficiency, who was overcorrected (XT15 PD). In this patient, a strong medial rectus contracture was observed preoperatively, by means of the stretching test of Queré et al.<sup>(13)</sup>, and it was not possible to adjust the medial rectus after surgery. Probably the 6 mm-medial-rectus recession led to this restricted adduction. Adduction limitation seems to occur only in cases with large medial rectus recession (higher than 6mm)<sup>(9)</sup>. Ciancia et al.<sup>(14)</sup> described good results in 3 patients with sixth nerve palsy, operated by C&J, with postoperative adduction and abduction around 20 degrees.

We had a reoperation rate of 23%, a result better than that of Homes et al.<sup>(7)</sup>, who used Foster procedure<sup>(13)</sup>. All patients were undercorrected (esotropias between 8 PD and 18 PD).

Some authors stated that better results in these cases are achieved in patients with minimal medial rectus contracture, because the muscle transposition creates a small abducting force and the medial rectus restriction can create a significant opposing force, showing that the preoperative prevention of the MR contracture with botulinum toxin should begin as soon as possible<sup>(11)</sup>.

Another advantage of the C&J procedure is the minimum risk of vertical deviation, because it allows free vertical movements of the transposed superior and inferior fibers, which are not sutured to the sclera, at the immediate postoperative period, leading to a vertical self-adjustment. Only one patient had hypertropia (5 DP), with no complain of diplopia, and fusion with a small head turn.

---

## CONCLUSIONS

---

Our study shows that the Carlson & Jampolsky technique was useful to treat patients with VI nerve palsy. We had low reoperation rates and, among the 7 patients who required a second intervention and only three did not achieve good results. The muscle transposition did not cause important adduction limitation (just one case, in which the postoperative adjustment was not possible).

---

## RESUMO

---

**Objetivo:** Estudar os resultados da técnica de Carlson-Jampolsky em 31 pacientes com paralisia de VI nervo. **Métodos:** Foram avaliados 23 casos unilaterais e 8 bilaterais. A média da esotropia pré-operatória em posição primária nos casos unilaterais foi de 56.8 DP ± 24 DP (30 DP a 100 DP), o seguimento dos pacientes após a cirurgia foi de 14 ± 17.9 meses (3 a 72). A média da esotropia pré-operatória em posição primária nos casos bilaterais foi de 74.5 DP ± 20.7 DP (45 DP to 100 DP), o seguimento dos pacientes após a cirurgia foi de 14.7 ± 15.7 meses (4 a 47). **Resultados:** Entre os pacientes do grupo unilateral, 18 casos tiveram bons resultados, sem necessitar de reoperação. Entre 5 pacientes que foram reoperados (2 subcorreções e 3 supercorreções), 2 tiveram que usar óculos com adição de prismas. Entre os casos bilaterais, 2 casos foram reoperados (1 subcorreção e 1 supercorreção), o paciente que estava subcorrigido manteve após a segunda cirurgia esotropia de 13 DP, e também teve que usar correção óptica com a adição de prisma. **Conclusões:** A técnica de Carlson-Jampolsky foi eficaz para tratar pacientes com paralisia de VI nervo. O número de reoperações foi baixo, e entre os reoperados, apenas 3 não apresentaram bons resultados.

**Descritores:** Oftalmoplegia; Estrabismo; Esotropia/cirurgia; Procedimentos cirúrgicos oftalmológicos; Nervo abducente/cirurgia; Músculos oculomotores; Complicações pós-operatórias

---

## REFERENCES

---

1. Neugebauer A, Fricke J, Klirsch A, Ssmann W. Modified transposition procedure of the vertical recti in sixth nerve palsy. *Am J Ophthalmol.* 2001; 131(3):359-63.
2. Jensen CD. Rectus muscle union: a new operation for paralysis of the rectus muscles. *Trans Pac Coast Otophthalmol Soc Ann Meet.* 1964;45:359-87.
3. Carlson MR, Jampolsky A. An adjustable transposition procedure for abduction deficiencies. *Am J Ophthalmol.* 1979;87(3):382-7.
4. Prieto-Díaz J, Souza-Dias C. Paresias and paralysis of VI nerve. In: Prieto-Díaz J, Souza-Dias C. *Strabismus.* 5<sup>th</sup> ed. Oxford: Butterworth-Heinemann; 2005. p.551-2.
5. Prieto-Díaz J, Souza-Dias C. *Semiologia motora.* In: Prieto-Díaz J, Souza-Dias C. *Strabismus.* 5<sup>th</sup> ed. Oxford: Butterworth-Heinemann; 2005. p.75.
6. Scott AB, Kraft SP. Botulinum toxin injection in the management of lateral rectus paresis. *Ophthalmology.* 1985;92(5):676-83.
7. Holmes JM, Leske DA, Christiansen SP. Initial treatment outcome in chronic sixth nerve palsy. *JAAPOS.* 2001;5(6):370-6.
8. Cline RA, Scott WE. Long-term follow-up of Jensen procedures. *J Pediatr Ophthalmol Strabismus.* 1988;25(5):264-9.

9. Bechac G, Bes MH, Gajan B, Kaiser MP, Marion B, Nardin M. [Value of the Carlson-Jampolsky operation in total paralysis of the 6<sup>th</sup> nerve. Apropos of 10 case]. *Ophthalmologie*. 1989;3(2):140-3. French.
  10. Ogata MM, Souza-Dias C. Resultados obtidos com a cirurgia de Carlson-Jampolsky para a correção da paralisia de VI nervo [monografia]. São Paulo: Santa Casa de Misericórdia de São Paulo; 1989.
  11. Rosenbaum AL, The Efficacy of Rectus Muscle Transposition Surgery in Esotropic Duane Syndrome and VI Nerve Palsy, *J AAPOS* 2004;8:409-419.
  12. Scott AB. Lateral rectus palsy. In: 5<sup>o</sup> Congresso do Conselho Latinoamericano de Estrabismo. Anais. Guarujá, Brasil, October 16-20,1976.
  13. Quere MA, Toucas S, Lavenant F, Pechereau A. [Postoperative secondary divergent strabismus. Statistical analysis of 160 consecutive exotropias]. *J Fr Ophthalmol*. 1989;12(1):3-10. French.
  14. Ciancia AO, Garcia HA, Lavin R. Treatment of the lateral rectus palsy. *Doc Ophthalmol*. 1984;58(1):57-64.
  15. Fink WH. *Surgery of the vertical muscles of the eye*. 2<sup>nd</sup> ed. Springfield, IL: Charles C. Thomas; 1962.
-