

# Effects of morphine on the expression of cytokines and inflammatory mediators in a rabbit model of endotoxin-induced experimental uveitis

## *Efeitos da morfina na expressão de citocinas e de mediadores inflamatórios em coelhos com uveítes experimental induzida por endotoxina*

KETHYE P. ORTENCIO<sup>1</sup>, ROBERTA RENZO<sup>1</sup>, ALEXANDRE A. F. B. SOBRINHO<sup>1</sup>, KARINA KAMACHI KOBASHIGAWA<sup>1</sup>, ROBERTA M. CRIVELARO<sup>1</sup>, GERMANA A. SILVA<sup>1</sup>, MARCELA ALDROVANI<sup>1</sup>, ALEXANDRE PINTO RIBEIRO<sup>2</sup>, TIAGO W. P. MINEO<sup>3</sup>, JOSÉ LUIZ LAUS<sup>1</sup>

### ABSTRACT

**Purpose:** To evaluate the effects of 1% morphine instillation on clinical parameters, aqueous humor turbidity, and expression levels of tumor necrosis factor alpha (TNF- $\alpha$ ), interleukin-1 beta (IL-1 beta), prostaglandin E2 (PGE2), and myeloperoxidase (MPO) in rabbits with endotoxin-induced experimental uveitis.

**Methods:** Twenty four New Zealand white rabbits were divided into four groups (n=6 each): control (CG), morphine (MG), naloxone (NG), and morphine-naloxone (MNG) groups. Under dissociative anesthesia, 0.1 mL of solution containing 0.2  $\mu$ g of lipopolysaccharide (LPS) endotoxin from the *Salmonella typhimurium* cell wall was injected in the vitreous chamber. Clinical evaluations (conjunctival hyperemia, chemosis blepharospasm, and ocular discharge) and laser flaremetry were performed before (baseline), and 10 and 20 hours after induction of uveitis. Rabbits were subsequently euthanized and eyes were enucleated to quantify expression levels of TNF- $\alpha$ , IL-1 beta, PGE2, and MPO.

**Results:** No significant differences in clinical parameters and flare values were observed between the study groups. TNF- $\alpha$  and IL-1 beta levels increased significantly in the CG, MG, NG, and MNG groups compared to baseline (P<0.05). Significant differences in PGE2 levels were observed between the MG and MNG groups (P<0.05). A trend toward increased MPO activity was observed in response to uveitis induction; however, this trend did not reach statistical significance (P>0.05).

**Conclusions:** Morphine has no effect on clinical parameters, flare, or expression levels of inflammatory mediators in a rabbit model of uveitis induced by intravitreal injection of LPS.

**Keywords:** Lasers/diagnostic use; Photometry/methods; Morphine/administration & dosage; Endotoxins/toxicity; Uveitis/chemically induced; Rabbit

### RESUMO

**Objetivo:** Estudaram-se os efeitos da instilação de morfina 1% sobre parâmetros clínicos, turbidez do humor aquoso e expressão de fator de necrose tumoral alfa (TNF- $\alpha$ ), de interleucina-1 beta (IL-1 beta), de prostaglandina E2 (PGE2) e de mieloperoxidase (MPO), em olhos de coelhos com uveíte induzida por endotoxina.

**Material e Métodos:** Vinte e quatro coelhos da raça Nova Zelândia Branco foram distribuídos em quatro grupos (n=6, em cada): grupo controle (GC), morfina (GM), naloxona (GN) e morfina-naloxona (GMN). Sob anestesia dissociativa, injetou-se 0,1 mL de solução contendo 0,2  $\mu$ g de lipossacarídeo (LPS) endotóxico da parede celular de *Salmonella typhimurium* na câmara vítrea. Realizou-se avaliação clínica (hiperemia conjuntival, quemose, blefaroespasmos e secreção ocular) e a flaremetria a "laser" antes (basal) e após 10 e 20 horas da indução da uveíte. No final, os coelhos foram submetidos à eutanásia e os olhos com uveíte foram enucleados para a quantificação dos níveis de TNF- $\alpha$ , IL-1 beta, PGE2 e MPO. Diferenças foram consideradas significativas quando p<0,05.

**Resultados:** Os grupos da pesquisa não diferiram quanto aos parâmetros clínicos e os valores de "flare". Observou-se elevação significativa nos níveis de TNF- $\alpha$  e de IL-1 beta, comparativamente ao basal, nos grupos GC, GM, GN e GMN (p<0,05). Valores de PGE2 variaram entre os grupos GM e GNM (p<0,05). A atividade de MPO aumentou após a indução da uveíte, porém, sem significância estatística (p>0,05).

**Conclusões:** A morfina não atuou sobre parâmetros clínicos, "flare" e expressão dos mediadores inflamatórios estudados, quando instilada em olhos de coelhos com uveíte induzida por injeção intravítrea de LPS.

**Descritores:** Lasers/uso diagnóstico; Fotometria/métodos; Morfina/administração & dosagem; Endotoxinas/toxicidade; Uveítes/induzido quimicamente; Coelhos

### INTRODUCTION

Uveitis is defined as inflammation of the uveal tract and has been shown to be associated with a number intraocular diseases, including cataract<sup>(1-3)</sup>. Experimentally, uveitis can be induced by intravitreal lipopolysaccharide (LPS) injection<sup>(4,5)</sup> leading to inflammatory cell infiltration at four hours after injection, with peak inflammation between 18 and 24 hours later<sup>(4)</sup>. Acute inflammatory responses in uveitis are maintained by the action of molecular mediators which

leads to decreased active secretion of aqueous humor and increased vascular permeability<sup>(6,7)</sup>.

Pro-inflammatory cytokines, such as interleukin-1 alpha (IL-1 alpha) and interleukin-1 beta (IL-1 beta), have been shown to actively recruit leukocytes to sites of inflammation<sup>(6)</sup>. IL-1 alpha and IL-1 beta are predominantly secreted by activated macrophages, B lymphocytes, and endothelial cells<sup>(6)</sup>. Tumor necrosis factor-alpha (TNF- $\alpha$ ) is also synthesized by monocytes, macrophages, neutrophils, mast cells,

Submitted for publication: March 23, 2015  
Accepted for publication: September 14, 2015

<sup>1</sup> Ophthalmology Unit, Department of Veterinary Clinical Medicine and Surgery, Faculdade de Ciências Agrárias e Veterinárias de Jaboticabal, Universidade Estadual Paulista "Julio de Mesquita Filho" (UNESP), Jaboticabal, SP, Brazil.

<sup>2</sup> Department of Veterinary Clinical Medicine, Faculdade de Agronomia, Medicina Veterinária e Zootecnia, Universidade Federal de Mato Grosso (UFMG), Cuiabá, MT, Brazil.

<sup>3</sup> Instituto de Ciências Biomédicas, Universidade Federal de Uberlândia (UFU), Umuarama, MG, Brazil.

**Funding:** This study was supported by FAPESP (São Paulo Research Foundation - process number 2011/08734-8); CAPES (Coordination for the Improvement of Higher Education Personnel); CNPq (National Council for Scientific and Technological Development - process 300833/2010-5).

**Disclosure of potential conflicts of interest:** None of the authors have any potential conflicts of interest to disclose.

**Corresponding author:** José Luiz Laus. Faculdade de Ciências Agrárias e Veterinárias (FCAV). Universidade Estadual Paulista. Departamento de Clínica e Cirurgia Veterinária. Via de Acesso Professor Paulo Donato Castellane, s/n - Jaboticabal, SP - 14884-900 - Brazil - E-mail: jllaus@fcav.unesp.br

**Approved by the following research ethics committee:** Ethics Committee on Animal Use (CEUA), College of Agriculture and Veterinary Sciences, UNESP, Jaboticabal, SP, Brazil, under the protocol 014274/11. Bioethical care, in relation to standards of the Association for Research in Vision and Ophthalmology - ARVO were followed.

and T lymphocytes<sup>(9)</sup>. As inflammation progresses, TNF- $\alpha$  modulates leukocyte infiltration by promoting the synthesis of molecules involved in adhesion, maturation, and maintenance of dendritic cells<sup>(9)</sup>. Evidence suggests that elevated expression of TNF- $\alpha$ , as observed in immune-mediated uveitis, correlates with pea inflammation<sup>(10)</sup>. In corroboration, a recent study reported significantly increased expression of TNF- $\alpha$  at 18 hours after cataract surgery<sup>(11)</sup>.

Prostaglandins (PGs) have also been shown to contribute to intraocular inflammation<sup>(12-14)</sup>. Infectious disease, trauma, ocular surgery, and neoplasia may also cause injury to the aqueous-blood barrier, leading to increased PG synthesis<sup>(7)</sup>. Ribeiro *et al.*<sup>(13)</sup> and Gilmour and Payton<sup>(14)</sup> reported the utility quantifying prostaglandin E2 (PGE2) levels as a measure of intraocular inflammation in dogs.

Opioids bind to specific endogenous receptors inducing antinociceptive effects in the central nervous system. Studies have demonstrated that local application of opioids can elicit analgesia via the neuroimmune system due to the presence of opioid receptors in peripheral tissues<sup>(15,16)</sup>. Wenk *et al.*<sup>(15)</sup> demonstrated attenuation of leukocyte infiltration by infusion of morphine directly into corneal ulcerations in mice. Clark *et al.*<sup>(17)</sup> demonstrated the efficacy of parenteral administration of morphine reducing cutaneous expression of IL-1 beta, interleukin-6, and TNF- $\alpha$ , and local neutrophil infiltration. Studies have also demonstrated the expression of kappa opioid receptors in the anterior chamber of the eye<sup>(18)</sup>. In humans and primates, opioids are known to suppress chemotaxis and migration of neutrophils, thereby modulating adaptive immune responses<sup>(19)</sup>. Dortch-Canes and Russell<sup>(20)</sup> reported that morphine instillation reduced the intraocular pressure in healthy rabbits but only for five minutes.

Naloxone is a non-selective opioid antagonist that may be used to reverse the action of morphine<sup>(21)</sup>. Its effects, however, are limited when administered in patients that have not been pretreated with opioids. The half-life of naloxone is approximately one hour as it is rapidly metabolized by the liver<sup>(22)</sup>.

The stability of the aqueous-blood barrier was evaluated by Ribeiro *et al.*<sup>(16)</sup> as the local administration of opioids, particularly morphine, is frequently used for pain control in ulcerative keratitis. Studies have demonstrated that morphine inhibits the release of proinflammatory cytokines in response to skin incisions and decreases the infiltration of leukocytes in silver nitrate-induced corneal ulcers<sup>(15,17)</sup>. In corneas following lamellar keratectomy, morphine reportedly increases the number of extracellular metalloproteinases without altering the expression of interleukin-10<sup>(16)</sup>. Husain *et al.*<sup>(23)</sup> observed that intraperitoneal administration of morphine has protective effects on retinal ganglion cells in a rat model of experimental ocular hypertension, most likely through inhibition of TNF- $\alpha$  production. A previous study at our institution demonstrated, with the use of laser flaremetry, that morphine increases the total protein content of the aqueous humor when administered after paracentesis of the anterior chamber<sup>(24)</sup>.

The present study aimed to evaluate the effects of morphine instillation on rabbit eyes with uveitis. Morphine is used to promote analgesia in ulcerative keratitis, and after refractive surgeries, condi-

tions that lead to the breakdown of the aqueous-blood barrier and increased expression of cytokines and other inflammatory mediators.

## METHODS

A total of 24 New Zealand White adult rabbits (*Oryctolagus cuniculus*) with a mean weight of 3.0 kg were used in the present study. Rabbits were kept in clean and sanitized individual cages in a ventilated environment. Food and water were offered *ad libitum*. Only rabbits free of ocular and systemic diseases were used in the present study.

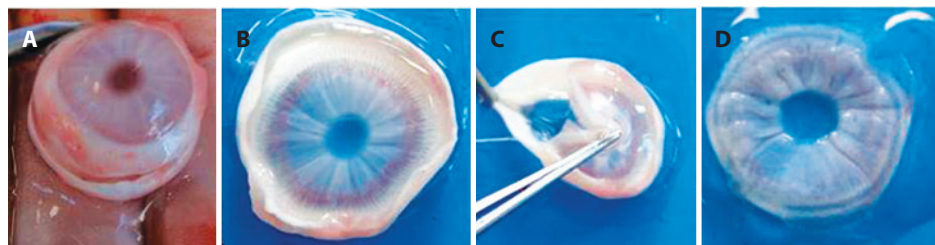
Intravitreal injections in the right eye of each rabbit were given under dissociative anesthesia (ketamine Agener 10% Agener Uniao, Toronto, ON and xylazine Dopaser, Hertape Calier, Juatuba, MG) following the instillation of anesthetic eye drops (anestésico®, Allergan, Guarulhos, SP). Under aseptic conditions, 0.1 mL of a solution containing LPS (0.2  $\mu$ g endotoxin from the *Salmonella typhimurium* cell wall; L6511, Sigma Chemical Co., St. Louis, MO) was applied approximately 3.5 mm from the sclerocorneal limbus to induce uveitis. A 0.25  $\times$  0.7 mm needle and 1 mL syringe were used as previously described<sup>(3)</sup>. Ophthalmoscopy was performed to confirm the absence of iatrogenic retinal lesions<sup>(25)</sup>.

Eyes were clinically evaluated for conjunctival hyperemia, chemosis, blepharospasm, ocular discharge, and aqueous turbidity<sup>(7)</sup>. Laser flaremetry was used to quantify the turbidity of the aqueous humor (Laser Flaremeter® FC-600, Kowa, Japan) before uveitis induction and at 10 and 20 hours after inflammation induction.

Rabbits were divided into four groups (n=6 each): control (CG), morphine (MG), naloxone (NG), and morphine-naloxone (MNG) groups. Eyes with endotoxin-induced uveitis, in a total of 10 applications, received one drop of 0.9% saline solution (CG), 1% morphine (MG), 1% naloxone (NG), or morphine and naloxone (MNG) immediately after the induction of inflammation and at regular 2-hour intervals. Commercially available ophthalmic solutions of 1% morphine sulfate (experimental 1% morphine ophthalmic solution without preservatives, Cristália, Campinas, SP) and 1% naloxone (experimental 1% naloxone ophthalmic solution without preservatives, Cristália, Campinas, SP) were used with the pH adjusted to 6.0. In the MNG, morphine was administered first followed by naloxone 10 minutes later.

Twenty hours after uveitis induction, rabbits were euthanized (overdose of thiopental sodium, Thiopentax, Cristália, Campinas, SP) and subconjunctival enucleation of the right eye was performed. Immediately after, the iris and ciliary body were collected (Figure 1), stored in tubes, and cryogenically preserved at a temperature of -80°C until further use. Approximately four months later, stored samples were macerated, and TNF- $\alpha$ , IL-1beta, MPO, and PGE2 levels were quantified by enzyme-linked immunosorbent assay (ELISA) according to the manufacturer's recommendations (Enzyme-linked Immunosorbent Assay kit, Uscn Life Science Inc., China).

Nonparametric Friedman analysis of variance with *post-hoc* analysis using the Dunn's test was used to evaluate aqueous humor flare data, expressed as the median, maximum, and minimum. Data related



**Figure 1.** Protocol used following enucleation of the right eye in New Zealand white rabbits. A) scleral section to remove the corneoscleral button; B) corneoscleral button; C) separation of the iris and ciliary body by traction; and D) iris and ciliary body storage conditions.

to cytokine levels were compared using one-way ANOVA followed by Turkey's test. Cytokines values were expressed as means and standard errors of the mean. P values <0.05 were considered statistically significant (SigmaStart 3.0®, Systat Software Inc., San Jose, USA).

**RESULTS**

Conjunctival hyperemia, chemosis, blepharospasm, ocular discharge, and aqueous turbidity were observed two hours after LPS injection and persisted for 20 hours in all eyes with endotoxin-induced uveitis.

The median aqueous humor photon counts at 20 hours were not significantly higher than those at the baseline in MG (2.10 vs. 4.10 PC/ms), NG (3.80 vs. 4.40 PC/ms), or MNG (2.90 vs. 3.25 PC/ms) (Figure 2). In CG, there was a trend toward increased median photon counts at baseline compared to other time periods; however, this trend did not reach statistical significance. Twenty hours after the induction of uveitis, there was a trend toward a higher median photon in MG (9.20 PC/ms), followed by MNG (7.90 PC/ms), NG (5.00 PC/ms), and CG (4.25 PC/ms); however, this trend did not reach statistical significance.

In all groups, uveitis induction resulted in increased expression of TNF-α and IL-1 beta (Table 1). Significant differences in TNF-α values as compared to baseline levels (467.1 ± 54.54 pg/mL) were observed in CG (5652 ± 145.7 pg/mL), NG (4601 ± 599.7 pg/mL), MG (5442 ± 417.7 pg/mL), and MNG (4714 ± 426.9 pg/mL; P<0.001 for all). IL-1 beta levels were significantly increased in CG (950.1 ± 71.97 pg/mL), NG (1087 ± 127.9 pg/mL), MG (1137 ± 96.53 pg/mL), and MNG (994.2 ± 86.03 pg/mL) compared to baseline values (509.3 ± 49.59 pg/mL; P<0.001 for all). No significant difference in PGE2 values compared

to baseline values (569.7 ± 73.99 pg/mL) were observed in CG (632.1 ± 77.44 pg/mL), NG (663.7 ± 32.67 pg/mL), MG (694.2 ± 45.12 pg/mL), or MNG (449.4 ± 27.29 pg/mL); however, a significant difference was observed between the MG (694.2 ± 45.12 pg/mL) and MNG (449.4 ± 27.29 pg/mL; P<0.001). No significant difference in MPO levels were observed between baseline (4.780\*10<sup>-4</sup> ± 1.647\*10<sup>-4</sup> mU/mL) and treated groups (CG, 7.975\*10<sup>-4</sup> ± 2.362\*10<sup>-4</sup> mU/mL; NG, 8.826\*10<sup>-4</sup> ± 3.697\*10<sup>-4</sup> mU/mL; MG, 3.838\*10<sup>-4</sup> ± 1.615\*10<sup>-4</sup> mU/mL; MNG, 7.086\*10<sup>-4</sup> ± 1.935\*10<sup>-4</sup> mU/mL).

The results presented in figure 3 demonstrate that the observed increases in the expression levels of all cytokines were similar between groups, except for PGE2 values which were lower in the MNG group.

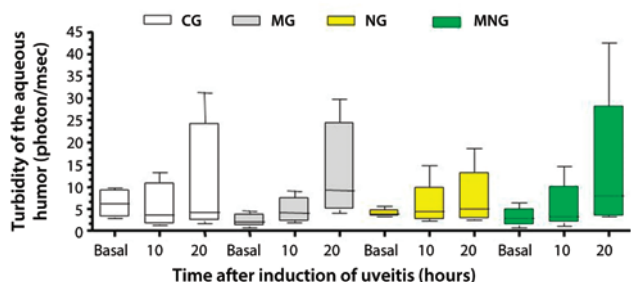
**DISCUSSION**

LPS injection has been demonstrated to be valid as an experimental model of uveitis and can be performed via intraperitoneal, subcutaneous, intracameral, and intravitreal routes<sup>(4,5)</sup>. The intravitreal route<sup>(26)</sup> was chosen in the present study as numerous ocular alterations related to other methods have been reported in previous studies. In corroboration with previous studies<sup>(26)</sup> in rabbits, the clinical signs associated with uveitis, such as conjunctival hyperemia, chemosis, blepharospasm, and ocular discharge, were also observed in the present study.

Nussenblatt *et al.*<sup>(26)</sup> reported a 3-fold increase in flare values in rabbit eyes at 3 hours after LPS injection before decreasing 9 hours later. However, no significant changes in flaremety were observed following endotoxin intravitreal injection in the present study. As albino rabbits were used, the absence of pigmentation in the uveal tract may have influenced the results of the present study.

Inflammatory mediators have been shown to act as vasoactive substances contributing to conjunctival hyperemia, injection of episcleral vessels, and engorgement of iris vessels<sup>(7)</sup> during the uveitis evolution process. The inflammatory process occurs as a tissue response to cell injury<sup>(28)</sup> initiated by the release of pro-inflammatory agents, particularly IL-1 and TNF-α, which stimulate the production of metabolites and cytokines and the liberation of arachidonic acid, PGs, and leukotrienes<sup>(27)</sup>.

In the present study, compared to baseline values, the levels of IL-1 and TNF-α and not of MPO and PGE2 increased after the induction of uveitis; this can be attributed to evaluations being performed during the initial phase of inflammation. The results of the present study corroborate with those of previous studies that have used LPS to induce inflammation<sup>(28)</sup> and increase levels of TNF-α and IL-1beta. TNF-α, IL-1beta, IL-2, IL-6, and interferon-gamma have also been detected in eyes with idiopathic uveitis. Studies in humans and rats have reported increased expression of TNF-α in tissues adjacent to the infiltration of inflammatory cells<sup>(29)</sup>. In contrast, Pinard *et al.*<sup>(12)</sup> observed no significant increases in TNF-α levels in dogs with paracentesis-induced uveitis.

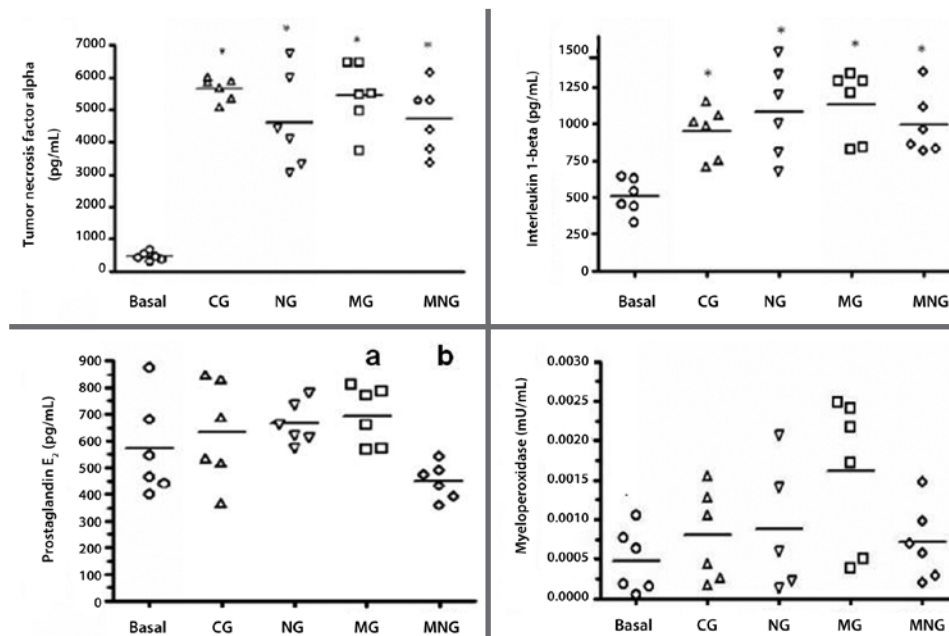


\* Dunn test (P>0.05). **Figure 2.** Median (lines inside boxes), maximum, minimum, and inter-quartile ranges (25 and 75%) for aqueous humor turbidity (photon/msec) before (basal) and 10 and 20 hours after the induction of uveitis in New Zealand white rabbits divided into the following groups: 0.9% saline (CG), 1% morphine (MG), 1% naloxone (NG), and 1% morphine followed by 1% naloxone (MNG).

**Table 1. Expression levels of tumor necrosis factor-alpha (TNF-α), interleukin-1 beta (IL-1 beta), prostaglandin E2 (PGE2), and myeloperoxidase (MPO), before (Baseline) and after 20 hours of induced uveitis in New Zealand white rabbits, quantified by enzyme-linked immunosorbent assay (ELISA) in the following groups: control (CG), morphine (MG), naloxone (NG), and morphine-naloxone (MNG). Data presented as mean ± standard error of the mean**

	TNF-α (pg/mL)	IL-1 beta (pg/mL)	PGE2 (pg/mL)	MPO *10 <sup>-4</sup> (mU/mL)
Baseline	467.1 ± 54.54	509.3 ± 49.59	569.7 ± 73.99	4.780 ± 1.647
CG	5652 ± 145.7*	950.1 ± 71.97*	632.1 ± 77.44	7.975 ± 2.362
NG	4601 ± 599.7*	1087 ± 127.9*	663.7 ± 32.67	8.826 ± 3.697
MG	5442 ± 417.7*	1137 ± 96.53*	694.2 ± 45.12**	3.838 ± 1.615
MNG	4714 ± 426.9*	994.2 ± 86.03*	449.4 ± 27.29**	7.086 ± 1.935

\*= statistically different from baseline; \*\*= statistically different between groups.



\* Turkey's test (P<0.001).

**Figure 3.** Expression levels of tumor necrosis factor alpha (TNF- $\alpha$ ), interleukin-1 beta (IL-1 beta), prostaglandin E<sub>2</sub> (PGE<sub>2</sub>), and myeloperoxidase (MPO) before (basal) and after uveitis induction in New Zealand white rabbits divided into the following groups: 0.9% saline group (CG), 1% morphine (MG), 1% naloxone (NG), and 1% morphine plus 1% naloxone (MNG). Horizontal lines represent mean values, geometric symbols ( $\circ$   $\triangle$   $\nabla$   $\square$   $\diamond$ ) represent data dispersion.

Bonfiglio *et al.*<sup>(30)</sup> reported that local instillation of varying concentrations of morphine causes variable intraocular alterations; for example, they observed that 1% morphine instillation, as used in the present research, increased nitric oxide production and affected the anterior chamber. These same authors, as well as Russel-Randall and Dortch-meat<sup>(18)</sup>, observed the presence of opioid receptors, particularly mu opioid receptors, in the anterior chamber of the eye.

Endogenous and exogenous opioids, such as morphine, are known to have immunosuppressive effects<sup>(22)</sup>. However, there is a lack of data regarding the anti-inflammatory effects of morphine infusion in the uveal tract. In the present study, local administration of morphine was not found to ameliorate increased PGE<sub>2</sub> expression in response to uveitis.

As a limitation of this study, in order to avoid the use of paracentesis, levels of inflammatory mediators in the aqueous humor were not evaluated, which may have biased the results. However, expression levels of TNF- $\alpha$ , IL-1beta, PG<sub>2</sub>, and MPO were measured in iris and ciliary body samples. Previously, Green *et al.*<sup>(4)</sup> observed transient elevations in iris, ciliary body, and choroidal blood flow using fluorescein angiography in rabbits with endotoxin-induced experimental uveitis.

## CONCLUSIONS

In the present study, 1% morphine instillation had no effect on clinical parameters or aqueous humor photon counts, as determined by laser flometry in rabbits with endotoxin-induced experimental uveitis. No significant differences in the expression levels of TNF- $\alpha$ , IL-1beta, PGE<sub>2</sub>, or MPO were between values measured before (baseline) and 20 hours after uveitis induction.

## REFERENCES

1. Collins BK, Moore CP. Diseases and surgery of the canine uvea. In: Gelatt KN. Veterinary ophthalmology. 3<sup>rd</sup> ed. Philadelphia: Lippincott Williams e Wilkins; 1999. p.755-95.

2. Carter WJ, Crispin SM, Gould DJ, Day M. An immunohistochemical study of uveodermatologic syndrome in two Japanese Akita dogs. *Vet Ophthalmol.* 2005;8(1):17-24.

3. Godoy CA, Safatle AM, Souza MS, Barros PS. Síndrome uveodermatológica-relato de caso em chow-chow. *Clín Vet (São Paulo).* 2004;52:78-84.

4. Green K, Paterson CA, Cheeks L, Slagle T, Jay WM, Aziz MZ. Ocular blood flow and vascular permeability in endotoxin-induced inflammation. *Ophthalmic Res.* 1990;22(5):287-9.

5. Wang XQ, Liu HL, Wang JB, Wu PF, Yan T, Xie J. Effect of artesunate on endotoxin-induced uveitis in rats. *Invest Ophthalmol Vis Sci.* 2011;52(2):916-9.

6. Gonçalves RM, Teixeira AL, Campos WR, Orefice F. O papel das quimiocinas nas uveítes. *Arq Bras Oftalmol.* 2007;70(2):363-70.

7. Teixeira AL, Barros LF, Barros PS. Afecções da túnica vascular. In: Laus JL. *Oftalmologia clínica e cirúrgica em cães e em gatos.* São Paulo: ROCA; 2009. Cap. 5, p.97-110.

8. El-Shabrawi YG, Christen WG, Foster SC. Correlation of metalloproteinase-2 and -9 with proinflammatory cytokines interleukin-1b, interleukin-12 and the interleukin-1 receptor antagonist in patients with chronic uveitis. *Curr Eye Res.* 2000;20(3):211-4.

9. Ooi KG, Galatowicz G, Calder VL, Lightman SL. Cytokines and chemokines in uveitis: is there a correlation with clinical phenotype? *Clin Med Res.* 2006;4(4):294-309. Review.

10. de Kozak Y, Verwaerde C. Cytokines in immunotherapy of experimental uveitis. *Int Rev Immunol.* 2002;21(2-3):231-53.

11. Tu KL, Kaye SB, Sidasar G, Taylor W, Shenkin A. Effect of intraocular surgery and ketamine on aqueous and serum cytokines. *Mol Vis.* 2007;12(13):1130-7.

12. Pinard CL, Galvin D, Moreal M, Martel-Pelletier J, Pelletier JP, Troncy E. Measurements of canine aqueous humor inflammatory mediators and the effect of carprofen following anterior chamber paracentesis. *Vet Ophthalmol.* 2011;14(5):296-30.

13. Ribeiro AP, Escobar A, Motheo TF, Godoy GS, Laus JL. Effects of meloxicam administered by different routes to control experimental uveitis in dogs. *Cienc Rural (Santa Maria).* 2009;39(7):2111-6.

14. Gilmour MA, Payton ME. Comparison of the effects of IV administration of meloxicam, carprofen, and flunixin meglumine on prostaglandin E<sub>2</sub> concentration in aqueous humor of dogs with aqueocentesis-induced anterior uveitis. *Am J Vet Res.* 2012;75(5):698-703.

15. Wenk HN, Nannenga MN, Honda CN. Effect of morphine sulfate eye drops on hyperalgesia in the rat cornea. *Pain.* 2003;105(3):455-65.

16. Ribeiro AP, Silva ML, Araújo RL, Ferrucci ML, Mineo T, Thiesen R, et al. Expression of matrix metalloproteinases, type IV collagen, and interleukin-10 in rabbits treated with morphine after lamellar keratectomy. *Vet Ophthalmol.* 2012;15(3):153-6.

17. Clark JD, Shi X, Li X, Qiao Y, Liang D, Angst MS, et al. Morphine reduces local cytokine expression and neutrophil infiltration after incision. *Mol Pain.* 2007;2(3):28-39.

18. Russell-Randall KR, Dortch-Carnes J. Kappa opioid receptor localization and coupling

- to nitric oxide production in cells of the anterior chamber. *Invest Ophthalmol Vis Sci.* 2011;52(8):5233-9.
19. Pruett SB, Han YC, Fuchs BA. Morphine suppresses primary humoral immune responses by a predominantly indirect mechanism. *J Pharmacol Exp Ther.* 1992;262(3):923-287.
  20. Dortch-Carnes J, Russell K. Morphine-stimulated nitric oxide release in rabbit aqueous humor. *Exp Eye Res.* 2007;84(1):185-90.
  21. Stagni E, Bucolo C, Motterlini R, Drago F. Morphine-induced ocular hypotension is modulated by nitric oxide and carbon monoxide: role of  $\mu$ 3 receptors. *J Ocul Pharmacol Ther.* 2010;26(1):31-5.
  22. Ozzani JL. Opióides e antagonistas. *Rev Bras Anesthesiol.* 1994;44(1):65-73.
  23. Husain S, Abidul Y, Crosson CE. Preservation of retina ganglion cell function by morphine in a chronic ocular-hypertensive rat model. *Invest Ophthalmol Vis Sci.* 2012;53(7):4289-98.
  24. Kobashigawa KK, Souza ES, Padua IR, Ribeiro AP, Andrade AL, Laus JL, et al. Clinical features, cellularity of corneal endothelium, laser flaremetry and aqueous humor total protein concentration in rabbits (*Oryctolagus cuniculus*) with uveitis following treatment with 1% morphine sulfate. *Vet Ophthalmol.* 2012;15(1):7.
  25. Rodrigues EB, Maia M, Penha FM, Dib E, Bordon AF, Magalhães Junior O, Farah ME. Técnicas para injeção intravítrea de drogas no tratamento de doenças vitroretinianas. *Arq Bras Oftalmol.* 2008;71(6):902-7.
  26. Nussenblatt RB, Calogero D, Bushen SY, Leder HA, Goodkin M, Eydelman MB. Rabbit intraocular reactivity to endotoxin measured by slit-lamp biomicroscopy and laser flare photometry. *Ophthalmology.* 2012;119(7):19-23.
  27. Carvalho WA, Lemônica L. Mecanismos celulares e moleculares da dor inflamatória. Modulação periférica e avanços terapêuticos. *Rev Bras Anesthesiol.* 1998;48(2):137-58.
  28. Pereira DV, Petronilho F, Pereira HE, Vuolo F, Mina F, Possato JC, et al. Effects of gold nanoparticles on endotoxin-induced uveitis in rats. *Invest Ophthalmol Vis Sci.* 2012; 53(13):8036-4.
  29. Atan D, Heissigerova J, Kuffová L, Hogan A, Kilmartin DJ, Forrester JV, et al. Tumor necrosis factor polymorphisms associated with tumor necrosis factor production influence the risk of idiopathic intermediate uveitis. *Mol Vis.* 2013;19:184-95.
  30. Bonfiglio V, Bucolo C, Camillieri G, Drago F. Possible involvement of nitric oxide in morphine-induced miosis and reduction in intraocular pressure in rabbits. *Eur J Pharmacol.* 2006;534(3):227-32.

## 41º Congresso da Associação Paranaense de Oftalmologia

29 e 30 de abril de 2016

Bourbon Curitiba Convention Hotel

Curitiba - PR

**Informações:**

Site: [www.congressoapo.com.br](http://www.congressoapo.com.br)