

Relationship between erythrocyte sedimentation rate and choroidal and retinal thickness in Behçet's disease

A relação entre a taxa de sedimentação eritrocitária, espessuras de coróide e retina na doença de Behçet

İsa Yuvacı¹, Ender Sırakaya², Emine Pangal², Mustafa Ataş², Nurettin Bayram², Emel Güler³, Fatmagül Ülkü Demir⁴, Orhan Altunel⁵

1. Department of Ophthalmology, Sakarya University Training and Research Hospital, Sakarya, Turkey.

2. Department of Ophthalmology, Kayseri Training and Research Hospital, Kocasinan, Kayseri, Turkey.

3. Department of Physical Medicine and Rehabilitation, Erciyes University, Kayseri, Turkey.

4. Department of Physical Medicine and Rehabilitation, Kayseri Training and Research Hospital, Kocasinan, Kayseri, Turkey.

5. Department of Ophthalmology, Yozgat Akdagmadeni State Hospital, Yozgat, Turkey.

ABSTRACT | Purpose: To compare retinal and choroidal thickness in patients with Behçet's disease with and without ocular involvement as well as to evaluate the correlation between erythrocyte sedimentation rate and choroidal thickness among patients with Behçet's disease. **Methods:** This was a prospective interventional study investigating erythrocyte sedimentation as well as choroidal and retinal thickness among patients with Behçet's disease. Patients who were diagnosed based on The International Criteria for Behçet's Disease with (Group A) or without (Group B) ocular involvement and a matched control group (Group C) participated in the study. Optical coherence tomography measurements and blood tests were performed on the same day. Retinal and choroidal thickness were measured using spectral-domain optical coherence tomography (Spectralis, Heidelberg Engineering, Heidelberg, Germany), and central macular thickness, central subfoveal choroidal thickness, and retinal nerve fiber layer thickness were measured using optical coherence tomography. **Results:** Average erythrocyte sedimentation values were 9.89 mm/h in Group A, 16.21 mm/h in Group B, and 3.89 mm/h in Group C; average central subfoveal choroidal thickness values were 350.66, 331.74, and 325.95 μm , respectively. Average central macular thickness and retinal nerve fiber layer thickness values of patients in Groups A, B and C were 226.39 and 225.97 μm ; 234.11 and 92.00 μm ; and 97.58 and 99.84 μm , respectively. No significant difference was seen between Group

A and B patients in central subfoveal choroidal thickness, central macular thickness, or retinal nerve fiber layer thickness values. Central macular thickness was statistically significantly thinner in Groups A and B than in Group C ($p=0.016$). Group A had thinning in the nasal quadrant of the retinal and general retinal nerve fiber layers when compared with those in Group C ($p=0.010$ and 0.041 , respectively). A connection could not be established between the erythrocyte sedimentation, central subfoveal choroidal thickness, central macular thickness, and retinal nerve fiber layer thickness in the patients with Behçet's disease. **Conclusion:** The erythrocyte sedimentation rate is typically used to test for activation of Behçet's disease and assess treatment response. In our study, we could not establish a connection between the erythrocyte sedimentation rate and central subfoveal choroidal thickness, central macular thickness, and retinal nerve fiber layer thickness in patients with systematically active Behçet's disease without ocular involvement.

Keywords: Behçet syndrome; Blood sedimentation; Erythrocytes indices; Choroid; Retina; Tomography, optical coherence

RESUMO | Objetivos: Comparar a espessura da retina e da coróide em pacientes com doença de Behçet, com e sem acometimento ocular e avaliar a correlação entre a taxa de sedimentação de eritrócitos e a espessura da coróide em pacientes com doença de Behçet. **Métodos:** Estudo prospectivo intervencional que investigou a sedimentação de eritrócitos, espessura de coróide e da retina em pacientes com doença de Behçet. Os pacientes que foram diagnosticados com base nos Critérios Internacionais para a Doença de Behçet com (Grupo A) ou sem (Grupo B) envolvimento ocular e um grupo controle correspondente (Grupo C) participaram do estudo. Medidas de tomografia de coerência óptica e exames de sangue foram realizados no mesmo dia. As espessuras da retina e da coróide foram medidas utilizando tomografia de coerência óptica de domínio espectral (Spectralis, Heidelberg Engineering, Hidelberg, Germany) e a espessura macular central,

Submitted for publication: January 19, 2018

Accepted for publication: November 24, 2018

Funding: No specific financial support was available for this study.

Disclosure of potential conflicts of interest: None of the authors have any potential conflicts of interest to disclose.

Corresponding author: Ender Sırakaya.

Department of Ophthalmology, Kayseri Training and Research Hospital
Sanayi Mah. Atatürk Boulevard Hastane Street, 78
Kayseri - 38010 - Turkey - E-mail: esirakaya@gmail.com

Approved by the following research ethics committee: Erciyes University (# 2014/199).

a espessura coroidal subfoveal central e a espessura da camada de fibra nervosa da retina foram medidas usando tomografia de coerência óptica. **Resultados:** Os valores médios de sedimentação de eritrócitos foram de 9,89 mm/h no Grupo A, 16,21 mm/h no Grupo B e 3,89 mm/h no Grupo C; os valores médios da espessura da coróide subfoveal central foram 350,66, 331,74 e 325,95 μm respectivamente. Os valores médios da espessura macular central e da espessura da camada de fibra nervosa da retina dos pacientes nos grupos A, B e C foram de 226,39, 225,97, 234,11 μm e 92,00, 97,58, 99,84 μm respectivamente. Não houve diferença significativa entre pacientes do Grupo A e B na espessura da coróide subfoveal central, espessura macular central ou valores da espessura da camada de fibra nervosa da retina. A espessura macular central foi estatisticamente significativamente mais fina nos Grupos A e B do que no Grupo C ($p=0,016$). O Grupo A apresentou afinamento na porção nasal das camadas retiniana e geral da fibra nervosa da retina quando comparado com o Grupo C ($p=0,010$, $p=0,041$, respectivamente). Não foi possível estabelecer uma conexão entre a sedimentação dos eritrócitos, a espessura subfoveal central da coróide, a espessura macular central e espessura da camada de fibras nervosas da retina nos pacientes com doença de Behçet. **Conclusão:** A taxa de sedimentação de eritrócitos é comumente utilizada para testar a ativação da doença de Behçet e avaliar a resposta ao tratamento. Em nosso estudo, não foi possível estabelecer uma conexão entre a taxa de sedimentação de eritrócitos e a espessura da coróide subfoveal central, espessura macular central e espessura da camada de fibras nervosas da retina em pacientes com doença de Behçet sistematicamente ativa sem envolvimento ocular.

Descritores: Síndrome de Behçet; Sedimentação sanguínea; Índices de eritrócitos; Coróide; Retina; Tomografia de coerência óptica

INTRODUCTION

Behçet's disease (BD) is a multisystemic chronic vasculitis characterized by recurrent skin lesions, oral and genital aphthous ulcerations, arthritis, and uveitis⁽¹⁾. BD influences nearly every tissue, organ, and system in the body, including cardiovascular, gastrointestinal, renal, ocular, pulmonary, urinary, and central nervous systems and joints (knee, ankle, elbow, wrist)⁽²⁾. Approximately 70% of all patients with BD have ocular involvement. The most common form of ocular involvement is non-granulomatous anterior uveitis (AU). Other ocular findings in patients with BD include keratitis, iridocyclitis, episcleritis, scleritis, vitritis, vitreous hemorrhage, optic neuritis, retinal neovascularization, and chorioretinal scars^(3,4).

Erythrocyte sedimentation rate (ESR) is defined as the speed at which erythrocytes fall in an hour. Factors augmenting fibrinogen and acute phase reactants also play a role in increasing the ESR. Inflammation is the

primary cause of BD^(5,6). The ESR is a sensitive test used to diagnose the disease, track activation, and monitor treatment response⁽⁶⁾.

Numerous studies have investigated the effects of BD in the choroid. Fibrinogen is one of the most important ESR-enhancing plasma proteins^(5,6). Fibrinogen levels rise due to various causes, creating vascular damage. The choroid structure, which has a rich vascular network and extremely high blood flow, is very likely to be affected by BD. However, one of the most common types of posterior uveitis observed in patients with BD is necrotizing vasculitis of the retina and choroid resulting in vascular occlusion with subsequent ischemia and atrophy, followed by retinal and disc neovascularization^(7,8). To our knowledge, no study has yet evaluated choroidal and retinal structures using ESR during an active period of BD without active ocular involvement. Therefore, we investigated the presence of subclinical variations in the posterior tissue in patients with active BD and high ESR but without ocular involvement and their association with ESR.

METHODS

We conducted this prospective study at our clinic between February 2014 and November 2016. All experiments were performed according to the principles of the Declaration of Helsinki. The study was approved by the institutional ethics committee (number 2014/199), and all participants provided informed consent to participate in the study.

Patients with a diagnosis of BD based on The International Criteria for BD in the Rheumatology Department of our hospital and for whom an eye consultation was requested during routine follow-up were included⁽⁹⁾. The patients were divided into two groups based on the presence of past ocular involvement (sign or history). Patients with a history/sign of iridocyclitis were classified as Group A, whereas those with no history/sign of uveitis were classified as Group B.

Healthy volunteers with demographic features similar to those of the patients with BD formed the control group (Group C) in our study.

Inclusion criteria were current absence of active ocular involvement, best-corrected visual acuity $\times 0.8$, axial length (AL) < 25 mm, and spherical equivalent (SE) values in the range of ± 4 D.

All patients underwent visual acuity testing, slit-lamp biomicroscopy with intraocular pressure (IOP) measurement using tonometry, and fundus examination after

dilation. Fundus fluorescein angiography (FFA) was performed (CS-60DSi, Canon, Tokyo, Japan) to assess retinal vascular leakage. Only patients with grade zero leaks were included in the study (grade 0, no vascular leakage or staining; grade 1, mild; grade 2, moderate; and grade 3, severe)⁽¹⁰⁾. Biometry was performed using the Zeiss IOLMaster device (Carl Zeiss Meditec, Inc., Dublin, CA, USA). Macular, choroidal, and retinal nerve fiber layer (RNFL) analyses were subsequently performed for each patient using spectral-domain optical coherence tomography (OCT; Spectralis, wave length: 870 nm; Heidelberg Engineering, Heidelberg, Germany) under the appropriate conditions. All of these processes were completed within 2h of the blood test.

Image acquisition

RNFL thickness, central macular thickness (CMT), and central subfoveal choroidal thickness (CSCT) were measured using the Spectralis OCT. The procedure used to obtain enhanced depth imaging (EDI)-OCT was described previously⁽¹¹⁾. Briefly, CSCT was measured using spectral-domain OCT (Spectralis) with EDI modality. CSCT was defined as the vertical distance from the hyper-reflective line of Bruch's membrane to that of the inner surface of the sclera. A single experienced technician imaged all of the study subjects, and two masked clinicians (IY and NB) without any knowledge of the subject matter independently measured CSCT

and presented them as values. Measurements for which differences >10% were recorded between the interpreters were excluded. Thickness parameters of the peripapillary RNFL were automatically calculated using spectral-domain (SD)-OCT and divided into regions including average RNFL (G) thickness (360°), temporal (T) quadrant thickness (90°), temporal superior (Ts) quadrant thickness (45°), nasal superior (Ns) quadrant thickness (45°), nasal (N) quadrant thickness (90°), nasal inferior (Ni) quadrant thickness (45°), and temporal inferior (Ti) quadrant thickness (45°). SD-OCT CMT, CSCT, and peripapillary RNFL thickness imaging of a normal eye are shown in figures 1 and 2, respectively.

Statistical analyses

All statistical analyses were performed using IBM SPSS Statistics for Windows, version 22.0 (IBM Corp., Armonk, NY, USA). Continuous variables were presented as mean \pm standard deviation, and qualitative variables were assessed using the Pearson chi-squared test. The Kolmogorov-Smirnov test was used to evaluate normal distribution. Homogeneity of variance was assessed using Levene test, and one-way analysis of variance test was used to analyze parametric data. Tukey HSD (honestly significant difference) test was used for post hoc comparisons when a significant result was obtained. Non-parametric data were analyzed using the Kruskal-Wallis test. The Mann-Whitney *U* test with Bon-

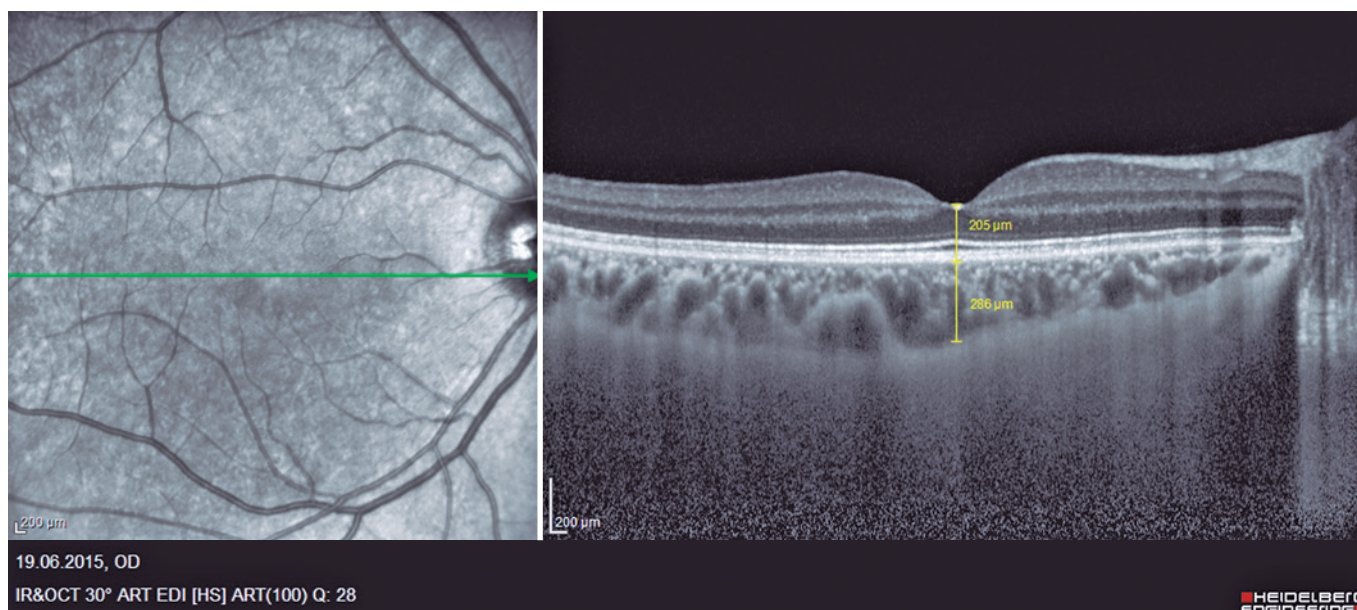


Figure 1. Central macular thickness (CMT) and central subfoveal choroidal thickness (CSCT) measurement in EDI-OCT imaging of normal eye.

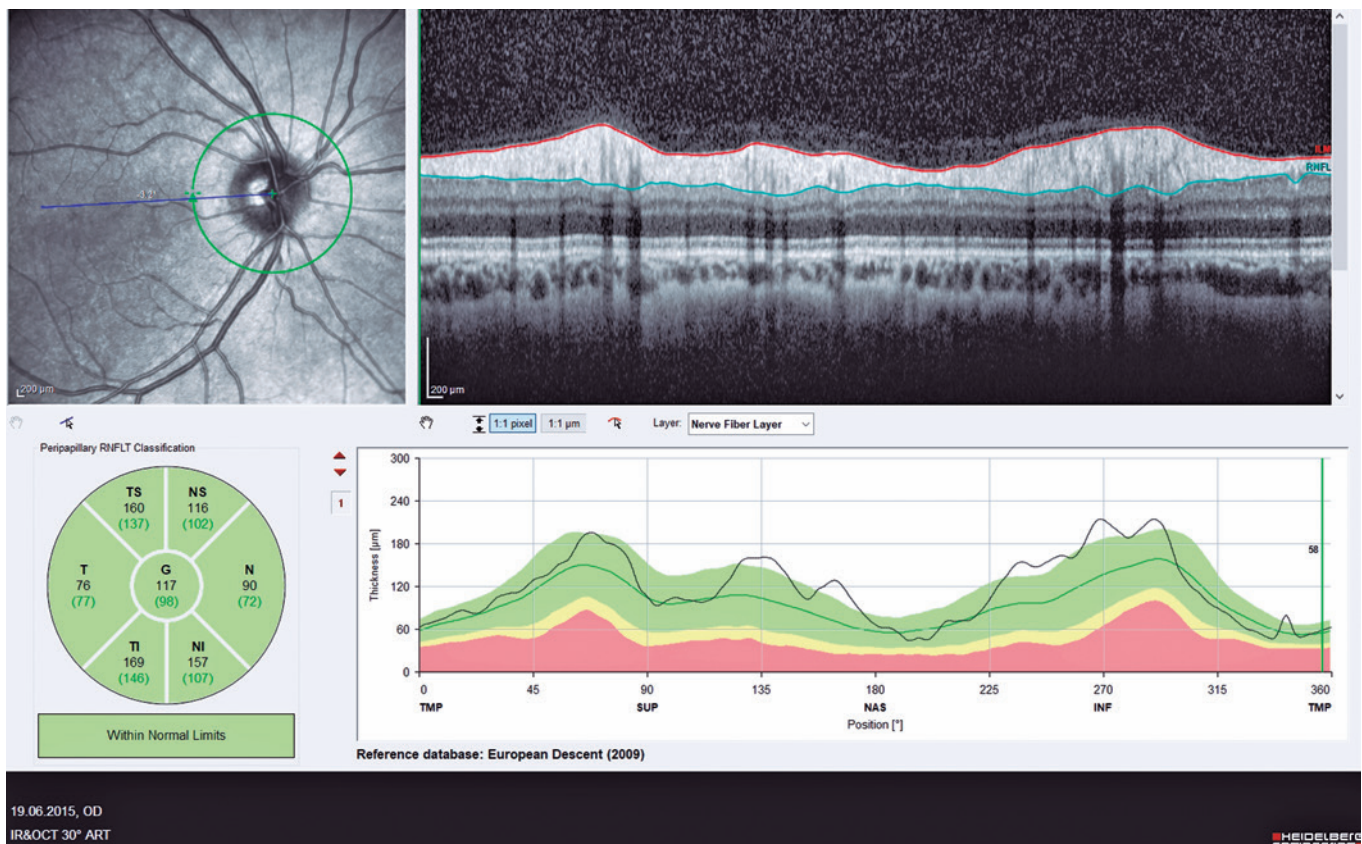


Figure 2. SD-OCT retinal nerve fiber layer (RNFL) imaging of the same eye. Numbers are expressed as individual mean RNFL thickness. Numbers in parentheses are the mean thickness in the Spectralisnormative database.

ferroni correction was used for post hoc comparisons of non-parametric statistics. The Spearman rho test was used to evaluate the correlation between ESR and OCT parameters in patients with BD. $P < 0.05$ was considered statistically significant.

RESULTS

Of the 37 patients with BD who participated in the study, 18 were categorized as Group A and 19 as Group B. Active anterior and posterior inflammation was not observed in any of the patients. With varying degrees, 37 patients had aphthous, 32 had arthritis, 28 had urethritis, 2 had skin involvement, 6 had vascular involvement, 3 had gastrointestinal involvement, and 2 had neuropsychiatric involvement. Nineteen healthy volunteers with demographic features similar to those of patients with BD comprised the control group (Group C).

The mean participant age was 36.36 years, the mean AL was 23.33 mm, the mean SE was -0.1D, and the mean IOP was 14.915 mmHg. Table 1 presents the demographic values of all of the patients.

The average ESR was 9.89 ± 5.54 (2-24) mm/h in Group A, 16.21 ± 15.82 (2-58) mm/h in Group B, and 3.89 ± 2.20 (1-9) mm/h in Group C. The average CSCTs were $350.66 \mu\text{m} \pm 55.09 \mu\text{m}$, $331.74 \mu\text{m} \pm 79.60 \mu\text{m}$, and $325.95 \mu\text{m} \pm 80.16 \mu\text{m}$ in Groups A, B, and C, respectively. All posterior structure values of the groups are presented in table 2.

No statistically significant difference in CSCT measurements was found between groups ($p > 0.05$). CMT was significantly thinner in patients with BD (Groups A and B) than in controls (Group C) ($p = 0.016$).

When RNFL thickness was analyzed, patients with BD with ocular involvement (Group A) had statistically significant thinning in Ns and G compared with the control group patients ($p = 0.010$, $p = 0.041$).

No statistically significant differences were observed in the correlations between all OCT findings and ESR ($p > 0.05$). The association between ESR and CSCT was not significant. Similarly, no association was established between ESR level and CMT or RNFL thickness. These parameters are shown in table 3.

Table 1. A summary of demographics and ocular parameters

	A (year)	S (M/F)	AL (mm)	Se (diopters)	IOP (mmHg)	ESR (mm/h)
Group A (n=18)	34.33 ± 7.23	8/10	23.36 ± 0.42	-0.21 ± 1.24	14.11 ± 2.87	9.89 ± 5.54
Group B (n=19)	39.53 ± 11.56	8/11	23.22 ± 0.78	-0.75 ± 1.18	15.21 ± 2.30	16.21 ± 15.82
Group C (n=19)	35.11 ± 8.71	7/12	23.42 ± 0.93	0.15 ± 1.05	15.37 ± 2.79	3.89 ± 2.21
P value	0.4590 ^a	0.890 ^b	0.695 ^c	0.820 ^a	0.424 ^a	0.000 ^a

n= number; A= age; S= sex; M= male; F= female; AL= axial length; Se= spherical equivalent; IOP= intraocular pressure; ESR= erythrocyte sedimentation rate.

Variables are expressed as mean ± standard deviation; level of significance p<0.05.

^a= Kruskal-Wallis test; ^b= Pearson chi-squared test; ^c= One-way analysis of variance test.

Table 2. SD-OCT measurements of choroidal, macular, and retinal nerve fiber layer thickness between groups

	Group A (n=18)	Group B (n=19)	Group C (n=19)	p value ^a
CMT	226.39 ± 37.03 µm	225.97 ± 32.59 µm	234.11 ± 15.14 µm	0.016 ^a
CSCT	350.06 ± 55.09 µm	331.74 ± 79.60 µm	325.95 ± 80.17 µm	0.581 ^b
G	92.00 ± 8.36 µm	97.58 ± 12.59 µm	99.84 ± 5.86 µm	0.041 ^b
Ti	131.67 ± 13.96 µm	143.26 ± 28.87 µm	131.05 ± 17.13 µm	0.133 ^a
Ni	105.00 ± 23.89 µm	113.79 ± 21.16 µm	108.00 ± 15.87 µm	0.420 ^b
N	70.17 ± 12.72 µm	74.74 ± 15.44 µm	80.53 ± 8.81 µm	0.052 ^b
Ns	93.83 ± 11.06 µm	100.74 ± 21.46 µm	113.37 ± 22.38 µm	0.010 ^b
Ts	120.17 ± 12.59 µm	132.21 ± 19.09 µm	124.53 ± 15.86 µm	0.079 ^b
T	72.94 ± 14.21 µm	70.63 ± 9.25 µm	74.05 ± 10.93 µm	0.580 ^a
ESR	9.89 ± 5.54 mm/h	16.21 ± 15.82 mm/h	3.89 ± 2.21 mm/h	0.000 ^a

n= number; CMT= central macular thickness; CSCT= central subfoveal choroidal thickness; G= median retinal nerve fiber layer; Ti= temporal inferior; Ni= nasal inferior; N= nasal; Ns= nasal superior; Ts= temporal superior; T= temporal; ESR= erythrocyte sedimentation rate; mm/h= millimeter per hour.

Variables are expressed as mean ± standard deviation; level of significance p<0.05.

^a= Kruskal-Wallis test; ^b= One-way analysis of variance test.

Table 3. Evaluation of the correlation between erythrocyte sedimentation rate and optical coherence tomography parameters

	All patients with BD (n=37)	P value ^a
CMT	226.08 ± 34.33 µm	0.558
CSCT	340.65 ± 68.46 µm	0.555
G	94.86 ± 10.97 µm	0.503
Ti	137.62 ± 23.32 µm	0.147
Ni	109.51 ± 22.65 µm	0.861
N	72.51 ± 14.18 µm	0.199
Ns	97.38 ± 17.33 µm	0.723
Ts	126.35 ± 17.15 µm	0.629
T	71.76 ± 11.82 µm	0.606

n= number; CMT= central macular thickness; CSCT= central subfoveal choroidal thickness; G= median retinal nerve fiber layer; Ti= temporal inferior; Ni= nasal inferior; N= nasal; Ns= nasal superior; Ts= temporal superior; T= temporal.

Variables are expressed as mean ± standard deviation; level of significance p<0.05.

^a= values for the Spearman Rho test.

DISCUSSION

The choroidea is a vascular layer with important functions, including oxygenation of the inner nuclear layers and the retinal pigment epithelium⁽¹²⁾. The development of EDI-OCT enabled more precise evaluations of the choroid tissue. For some diseases and conditions,

choroidal thickness and various other functions, such as feeding the various retinal layers, oxygenation, and adjusting temperature, were investigated and the results published⁽¹³⁻¹⁸⁾.

Several studies investigated variations in the thickness of choroidal and posterior tissues in patients with BD. While Ataş et al.⁽¹⁹⁾ found no difference in choroidal thickness in the BD group when compared with the normal group, they noted an increased macular thickness in patients with BD without active uveitis who had experienced varying degrees of uveitis. Kim et al.⁽²⁰⁾ reported an increase in subfoveal choroidal thickness in patients with BD with posterior uveitis during the active and inactive phases, demonstrating a correlation between FA and retinal vascular leakage. Coskun et al.⁽²¹⁾ showed thinning of the subfoveal choroidal thickness in patients with BD with posterior segment involvement. In the present study, no statistically significant difference was observed in CMT and CSCT between Groups A and B. These results are consistent with the above-cited studies, because our study did not show any evidence of posterior involvement or active attacks. Our study found that CMT was significantly thinner in patients with BD

than in controls. Due to the small number of participants in our study, it may be useful to investigate this issue using a larger number of participants.

After analyzing disc topography in healthy controls and in patients with BD with and without ocular involvement using OCT, Tekeli et al.⁽²²⁾ determined that the average disc area, cup area, cup volume, and cup depth in patients with BD with and without ocular involvement were significantly smaller than in the control group. Moreover, Şakalar et al.⁽²³⁾ did not find any statistically significant differences between the groups when comparing RNFL measurements in patients with BD without ocular involvement and those of normal individuals. Berker et al.⁽²⁴⁾ found that the cup area, cup volume, rim volume, and cup depth were greater in patients with BD with mild versus severe uveitis. Meanwhile, the cup-to-disk ratio was similar in the two groups. Karadag et al.⁽²⁵⁾ demonstrated no significant differences between patients with BD with and without ocular involvement for RNFL, retinal, and choroidal thicknesses. However, they identified thinner RNFL and thicker choroidal thicknesses in these patients compared with healthy controls. In our study, RNFL was significantly thin in some quadrants in Group A in comparison with Group C.

These results may be by chance or due to the patients' history of uveitis. Damage may occur during AU because IOP may be elevated in ganglion cells, which are extremely sensitive to ischemia. The correlation between ESR and RNFL thickness was not statistically significant. In addition, no evidence of active uveitis was observed in any of the patients in our study. Roizenblatt et al.⁽²⁶⁾ reported the possibility of silent disease progression even if clinical signs or signs of mild inflammation were absent in patients with BD; therefore, they reported that OCT and FFA were important ancillary exams in the management of such patients.

In our study, considering that homogeneous classification of the frequency and severity of previous attacks and drugs used for management could not be performed, we did not establish a group of patients with BD with posterior and ocular involvement. In addition, opacities, such as cataract and vitreous condensation, may negatively affect OCT imaging quality in such patients. In our study, there was no sign of uveitis in the posterior tissues of any patients, and this condition was confirmed by inspection and FFA. To our knowledge, no previous study has yet investigated the relation between ESR and choroidal thickness. To achieve this goal, macular and RNFL analyses were performed, with particular

focus on the choroid, within 2 hours of the blood test. No differences in CSCT or CMT findings were observed between the two groups. These findings are compatible with the aforementioned studies, and there was no difference in the thickness between choroidal and other posterior structures if there was no current attack. Studies including a larger number of patients with posterior ocular involvement will be more informative. The most important limitation of our study is the small number of patients. The other limitation is a manual measurement of various retinal layer thicknesses, automatic software may allow a more objective evaluation.

In conclusion, we investigated the relationship between the choroidal and other posterior tissues and ESR in patients with BD without active uveitis and did not find any association. Because no studies are available to make a comparison, more comprehensive studies are needed.

REFERENCES

- Behcet H. Über rezidivierende Aphthe durch ein virüs verursachte Geschwure am Mund, am Auge und an den Genitalien. *Dermatol Wochenschr.* 1937;105:1152-7.
- Azizlerli G, Köse AA, Sarica R, Gül A, Tutkun IT, Kulaç M, et al. Prevalence of Behçet's disease in Istanbul, Turkey. *Int J Dermatol.* 2003;42(10):803-6.
- Evereklioglu C. Current concepts in the etiology and treatment of Behçet disease. *Surv Ophthalmol.* 2005;50(4):297-350.
- Saadoun D, Cassoux N, Wechsler B, Boutin D, Terrada C, Lehoang P, et al. [Ocular manifestations of Behçet's disease]. *Rev Med Interne.* 2010;31(8):545-50. French.
- Bridgen ML. Clinical utility of the erythrocyte sedimentation rate. *Am Fam Physician.* 1999;60(5):1443-50.
- Sox HC Jr, Liang MH. The erythrocyte sedimentation rate guidelines for rational use. *Ann Intern Med.* 1986;104(4):515-23.
- Özdamar PC, Ortac S, Taskintuna I, Firat E. Posterior segment involvement in ocular Behçet's disease. *Eur J Ophthalmol.* 2002;12(5):424-31.
- Atmaca LS. Fundus changes associated with Behçet's disease. *Graefes Arch Clin Exp Ophthalmol.* 1989;27(4):340-4.
- International Team for the Revision of the International Criteria for Behçet's Disease (ITR-ICBD). The International Criteria for Behçet's Disease (ICBD): a collaborative study of 27 countries on the sensitivity and specificity of the new criteria. *J Eur Acad Dermatol Venereol.* 2014;28(3):338-47.
- Tugal-Tutkun I, Herbort CP, Khairallah M, Montovani A. Interobserver agreement in scoring of dual fluorescein and ICG inflammatory angiographic signs for the grading of posterior segment inflammation. *Ocul Immunol Inflamm.* 2010;18(5):385-9.
- Spaide RF, Koizumi H, Pozzoni MC. Enhanced depth imaging spectral-domain optical coherence tomography. *Am J Ophthalmol.* 2008;146(4):496-500. Erratum in: *Am J Ophthalmol.* 2009;148(2):325.
- Nickla DL, Wallman J. The multifunctional choroid. *Prog Retin Eye Res.* 2010;29(2):144-68.

13. Fujiwara T, Imamura Y, Margolis R, Slakter JS, Spaide RF. Enhanced depth imaging optical coherence tomography of the choroid in highly myopic eye. *Am J Ophthalmol.* 2009;148(3):445-50.
14. Imamura Y, Fujiwara T, Margolis R, Spaide RF. Enhanced depth imaging optical coherence tomography of the choroid in central serous chorioretinopathy. *Retina.* 2009;29(10):1469-73.
15. Spaide RF. Age-related choroidal atrophy. *Am J Ophthalmol.* 2009;147(5):801-10.
16. Usui S, Ikuno Y, Akiba M, Maruko I, Sekiryu T, Nishida K, et al. Circadian changes in subfoveal choroidal thickness and the relationship with circulatory factors in healthy subjects. *Invest Ophthalmol Vis Sci.* 2012;53(4):2300-7.
17. Dervişoğulları MS, Totan Y, Tenlik A, Yüce A. Effects of cigarette smoking on choroidal and retinal thickness and ocular pulse amplitude. *Cutan Ocul Toxicol.* 2015;34(3):217-21.
18. Vural AD, Kara N, Sayin N, Pirhan D, Ersan HB. Choroidal thickness changes after a single administration of coffee in healthy subjects. *Retina.* 2014;34(6):1223-8.
19. Ataş M, Yuvacı İ, Demircan S, Güler E, Altunel O, Pangal E, et al. Evaluation of the macular, peripapillary nerve fiber layer and choroid thickness changes in Behçet's disease with spectral-domain OCT. *J Ophthalmol.* 2014;2014:865394.
20. Kim M, Kim H, Kwon HJ, Kim SS, Koh HJ, Lee SC. Choroidal thickness in Behçet's uveitis: an enhanced depth imaging-optical coherence tomography and its association with angiographic changes. *Invest Ophthalmol Vis Sci.* 2013;54(9):6033-9.
21. Coskun E, Gurler B, Pehlivan Y, Kisacik B, Okumus S, Yayuspayı R, et al. Enhanced depth imaging optical coherence tomography findings in Behçet's disease. *Ocul Immunol Inflamm.* 2013;21(6):440-5.
22. Tekeli O, Özdemir O. Heidelberg retina tomography in ocular Behçet's disease. *Eye (Lond).* 2004;18(2):143-6.
23. Şakalar YB, Keklikçi U, Çakmak SC, Arı S, Erdem Ş, Ünlü K. Retinal nerve fiber layer thickness and features of the optic disc in patients with non ocular Behçet's disease. *Tur J Ophthalmol.* 2010;40(4):190-3.
24. Berker N, Elgin U, Özdalp, Batman A, Soykan E, Ozkan SS. Topographic optic disc analysis by Heidelberg retinal tomography in ocular Behçet's disease. *Br J Ophthalmol.* 2007;91(9):1199-201.
25. Karadag AS, Bilgin B, Soylu MB. Comparison of optical coherence tomographic findings between Behçet disease patients with and without ocular involvement and healthy subjects. *Arq Bras Oftalmol.* 2017;80(2):69-73.
26. Roizenblatt M, Fares N, Nascimento H, Novais EA, Muccioli C, Belfort R Jr. Asymptomatic progression of ocular Behçet's Disease. *Ophthalmic Sur Lasers Imaging Retina.* 2017;48(1):18-35.