

# CHEMICAL PLEURODESIS FOR HEPATIC HYDROTHORAX

Ilka de Fatima Santana Ferreira **BOIN\***, Aurea Maria Oliveira **SILVA\*\*** and Luiz Sergio **LEONARDI\*\*\***

**ABSTRACT** – Background - *Ascites can occur after hepatic diseases causing dyspnea, coughing and pain. When associated with pleural effusion it can also increase respiratory distress. In a bibliographic survey hydrothorax has been observed in up to 20% of the patients and the kind of treatment is still being discussed.* Objective – *This case report shows the occurrence of a large volume of ascites and pleural effusion in a cirrhotic patient and his treatment.* Methods – *Report the case of a patient with hepatic cirrhosis due to chronic alcoholism and massive pleural effusion and ascites. He was submitted to several pleural paracenteses without success. Scintigraphy showed the presence of ascites and confirmed a possible pleuroperitoneal communication. The thoracic surgery group was called and after evaluation it was decided to submit the patient to a pulmonary decortication and chemical pleurodesis.* Results – *These procedures were carried out with success. The pleural effusion was solved and the treatment of ascites was decided upon because the patient did not accept any surgical procedure.* Conclusion - *This treatment could be applied to patients with hydrothorax who could not be submitted to a liver transplantation.*

**HEADINGS** – *Pleurodesis. Hydrothorax. Ascites. Liver diseases.*

## INTRODUCTION

Any kind of hepatic pathology could produce histopathologic liver and hepatic function alteration causing other disorders, ascites being one of them. Today, a case of ascites is easy to diagnose as this problem has been studied in detail. Ascites may also cause pleural effusion that could result in dyspnea, cough, discomfort and pain. During the evolution of the disease, the reduction in the kinetics of the diaphragm is another preoccupying occurrence which calls for a thorough discussion of the treatment for hydrothorax and ascites.

On reviewing literature, it was noted that 1% to 20% of patients with hepatic cirrhosis could develop hydrothorax<sup>(9)</sup>. It usually occurs on the right side of the pleural space<sup>(8,9)</sup> and is probably caused because the ascitic liquid passes through

due to: a structural defect of the diaphragm<sup>(8)</sup>, fragile diaphragmatic muscles, a defect in the tendinous part of the diaphragm, 0.03 to 1.2 mm orifices at the tendinous center of the diaphragm<sup>(5)</sup>, transdiaphragmatic lymphatic migration<sup>(10)</sup>, hypoalbuminemia<sup>(5, 6, 9, 10)</sup>, hypertension of the portal vein<sup>(6, 9)</sup>, hypertension of the azygos vein<sup>(6, 8, 10)</sup>, hyperaldosteronism<sup>(4)</sup>, hypertension of the pulmonary veins<sup>(3)</sup>, intrathoracic lymphatic stasis following hypertension of the thoracic duct<sup>(6, 10)</sup> and splenomegaly<sup>(5, 9)</sup>.

The pleural and ascitic fluid undergo laboratory tests, pulmonary radiography and/or abdominal and peritoneal scintigraphy<sup>(1,4)</sup>. The treatment consists of pleural drainage, diuretics, pleurodesis and surgical repair of the diaphragm<sup>(5,6,10)</sup>.

Cases of pleural effusion in the absence of ascites were also studied as illustrations. The mechanisms that produce

Unit of Liver Transplantation – Department of Surgery - Faculty of Medical Sciences – State University of Campinas (UNICAMP), Campinas, SP, Brazil.

\* Assistant Professor of Surgery. Faculty of Medical Sciences - UNICAMP.

\*\* Physiotherapist. Unit of Liver Transplantation. Faculty of Medical Sciences – UNICAMP.

\*\*\* Professor and Chairman. Unit of Liver Transplantation – Department of Surgery - Faculty of Medical Sciences – (UNICAMP).

Address for correspondence: Dra. Ilka Boin - Rua Aldo de Oliveira Barbosa, 184 – 13086-030 - Campinas, SP, Brazil. e-mail: ilka@fcm.unicamp.br

this syndrome, the therapeutic responses and the diagnostic procedures for these cases were analyzed but the case studied differed as the patient had a large quantity of ascitic abdominal liquid.

A bibliographic survey was conducted on hydrothorax and ascites in order to define the parameters for the treatment of the patient who had a possibility of undergoing liver transplantation as he suffered from hepatic cirrhosis worsened by massive pleural effusions, ascites and malnutrition.

**CASE REPORT**

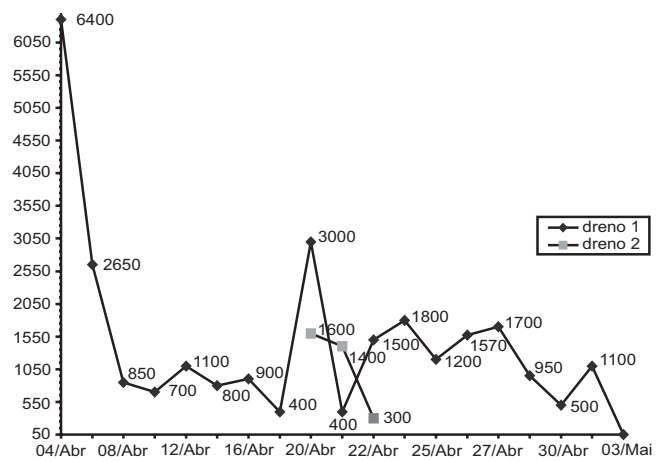
CAGDS, male, 39 years old, a clerk, separated, an alcoholic for 20 years, has been smoking a pack a day for 9 years, edema in the lower limbs for a year and ascites for the last 4 months. He was previously hospitalized elsewhere four times for ascites – on two occasions pleural drainage was performed and on another occasion, abdominal paracentesis. On March 29, 1996, he was hospitalized in order to carry out a hepatic biopsy, pleural drainage and to regularize his general condition. The etiology diagnosed was hepatic cirrhosis probably due to alcohol. The physical examination revealed edema of the lower limbs 4+/4, dyspnea, voluminous ascites, fever and a mild state of malnutrition. Child–Pugh classification was C.

The results of the study of the ascitic fluid and pleural fluid obtained through diagnostic puncturing on March 30, 1996 was in the ascitic fluid: 225 leucocytes/mm<sup>3</sup>, 60.5 neutrophils/mm<sup>3</sup>, 1.6 mg% protein and 115 mg% glucose and in the pleural fluid 7600 leucocytes/mm<sup>3</sup>, 90 neutrophils/mm<sup>3</sup>, 2.6 mg% protein and 30 mg% protein were shown. The following results were obtained in April with regard to the pulmonary function: CVF - 42%; VEF1 - 46%; VEF - 25%-52%; FEF max - 56%; FIF 50%-36%; VVM - 28%. These results indicated the presence of a severe limiting defect. A radiograph of the thorax was taken on the same day and it revealed massive left-sided pleural effusion. Pleural drainage was carried out and 2,000 mL of serous fluid was removed and 10,000 mL of serous fluid was removed through abdominal paracentesis and human albumin having a 20% concentration was replaced. On April 5 the radiography of the thorax revealed total atelectasis of the left lung, the thoracic drain was changed as it was not effective (Fig. 1). The ascitic and pleural fluids studied on April 8 were observed to be positive for *Escherichia coli* and sensitive to all antibiotics. The antibiotic therapy was not changed as the patient was already being treated with intravenous cephalosporin (1 g/bid).

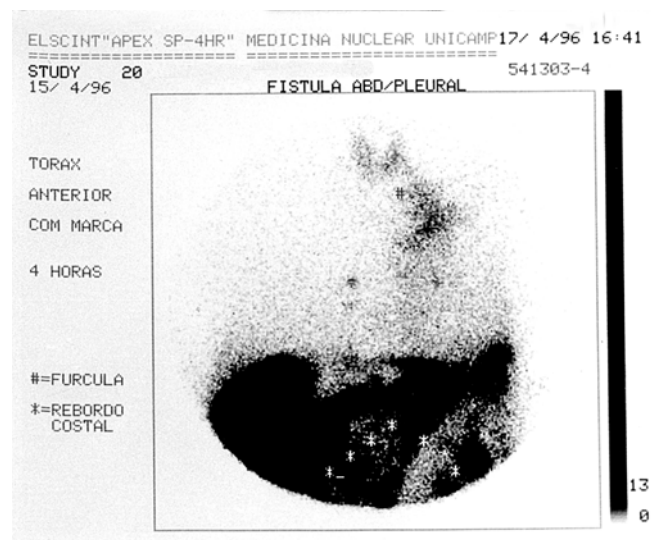
On April 14, chemical pleurodesis (2.5 g tetracyclin in 100 mL of saline solution) was effected by performing thoracic surgery under general anesthesia because the quantity of thoracic fluid did not diminish after 7 days of drainage. On April 15, a nuclear medicine scanning test was conducted to check for a pleural abdominal fistula. The peritoneal scintigraphic method utilizing the Tc-<sup>99m</sup> MAA and

the Tc-<sup>99m</sup> SC markers<sup>(4, 7, 9)</sup> used in diagnosing the case was the same as that reported in literature (Fig. 2). After the thoracic drain was clipped, 250 mL of saline solution was introduced through a teflon catheter into the peritoneal cavity. A series of images with 5 minute intervals was obtained during a period of 30 minutes. The distribution of the marker and a possible pleural-peritoneal communication were verified. The presence of a fistula was confirmed.

On April 19 the patient underwent pulmonary decortication as there was serious pulmonary incarceration. During this surgery, the pleural abdominal fistula was not observed. On April 21 the patient



**FIGURE 1** – Evolution of the pleural drainage during hospitalization time (volume in mL)



**FIGURE 2** – Scintigraph test showed a position of inferior ribs and presence of ascitis and pleural effusion

suffered intermittent enterorrhagia. Colonoscopy revealed bleeding at the end of the ileum and a biopsy was performed. The result of the biopsy indicated Crohn's disease. The treatment began with two tablets of aminosalicylic-5 acid, taken orally three times a day. The histopathological results of the pleura showed fibrinous pleuritis being formed. On May 4 the last thoracic drain was removed. The patient was discharged on May 6. The patient came for his first check-up at the outpatient clinic on July 30 and showed no signs of ascites, edema or tremors of the lower limbs. Auscultation revealed reduced vesicular murmurs in the left hemithorax and the presence of murmurs in the right hemithorax. He complained of spider nevus, painful gynecomastia, pain on the left-side in the region of the last rib, lumbago which receded when he rested, pain and edema in the sternal region. The region was punctured and the culture obtained showed that it was contaminated by *Candida albicans*. He was first treated with cephalexine 500 mg four times daily and itraconazol 200 mg twice daily for 21 days. The patient returned 5 months later without any complaints edema or ascites. He was anicteric, had gained weight, had spider nevus on the trunk and refused to be treated for Crohn's disease. Up to the present moment, the patient's general condition is stable but he is still an alcoholic and refuses treatment.

## DISCUSSION

The patient in the above report presented left pleural effusion, while in most cases it occurs on the right<sup>(4, 6)</sup>. The scintigraphic examination confirmed the defect in the tendinous part of diaphragm. The peritoneal scintigraphic method utilizing the Tc-<sup>99m</sup> MAA and Tc-<sup>99m</sup> SC markers<sup>(2, 4, 6)</sup> used in diagnosing the case was the same. After the thoracic drain was clipped, 250 mL of saline solution was introduced through a teflon catheter into peritoneal cavity. A series of images with 5 minutes intervals were obtained during a period of 30 minutes. The distribution of the marker and a possible pleural-peritoneal connection were verified. The diagnosis in the case of the patient in this report: the defect in the tendinous part of the diaphragm whereas confirmation of the case described by RUBISTEIN et al.<sup>(5)</sup> was obtained through surgery. A biochemical examination of the pleural fluid showed the presence of a transudate, which was in keeping with the reports in literature<sup>(10)</sup>, although sometimes the fluid could be an exudate.

Pleural drainage<sup>(4)</sup>, according to literature, was used to rapidly improve the symptoms and discomfort caused by pleural infusion. This procedure was contested by KAPLAN et al.<sup>(2)</sup>, as the massive

drainage caused an increase in morbidity, its efficacy was inconsistent and the recurrence rate was about 97%. Generally the use of diuretics together with a poor sodium intake reduce ascites and consequently hydrothorax<sup>(4, 8)</sup>.

As pleural effusion persisted in this case, some procedures were adopted such as: thoracic drainage, chemical pleurodesis (most frequently used) using tetracycline powder, bleomycin, radioactive phosphorus, gold, traumatic pleurodesis, thoracotomy or thoracoscopy in repairing the diaphragm, pleurectomy, more recently TIPS – intrahepatic percutaneous portosystemic shunt (this is a palliative) and an orthotopic liver transplant<sup>(5, 8, 10)</sup>. In order to relieve the patient's symptoms in the case cited above, thoracocentesis was performed and as there was a recurrence, chemical pleurodesis was carried out. Later, a thoracotomy and pleurectomy were performed. According to literature, in order to diagnose a case regarding pleural effusion, the first option after pulmonary auscultation and a radiograph of the thorax is a thoracocentesis, as it is a low risk procedure. The sequence used in this case was the same as that found in literature followed by: pleural drainage, chemical pleurodesis and thoracocentesis with pleurectomy in the case of recurrence after thoracocentesis.

A study of the pleural and ascitic fluids showed the presence of equal quantities of glucose and protein in both the fluids but the cellularity was observed to be less than that reported in literature<sup>(2, 5)</sup>. The reports in literature are comparative studies of the pleural and ascitic fluids with regard to the proteins, glucose, LDH, amylase, cytology, pH and deaminase adenosine. KAPLAN et al.<sup>(2)</sup>, DALY et al.<sup>(1)</sup> and RUBISTEIN et al.<sup>(5)</sup> described some cases in which the cultures were normally negative and observed that the proteins were more than 30 g/dL and the quantity of lactate hydrogenase was more than 200 mU/mL. Some articles discuss cases of massive pleural effusion in chronic hepatopathy patients in the absence of ascites<sup>(1, 5)</sup>. MENTES et al.<sup>(3)</sup> state the possibility of traumas taking place during peritoneal dialysis and splenectomy or a serious defect in the hemidiaphragm causing pneumothorax and pleural effusion. A liver transplant could not be carried out in the case of the patient in this study, even after having overcome hydrothorax, ascites and malnutrition because the patient was still on alcohol. During the scintigraphic examination of the above patient, the peritoneal–pleural connection was observed but this anatomical defect was not observed during thoracotomy. This could mean that an increase in the abdominal pressure due to voluminous ascites may have caused this connection.

Boin I de FSF, Silva AMO, Leonardi LS. *Uso da pleurodese química em hidrotórax de origem hepática. Arq Gastroenterol 2001;38(2):125-128.*

**RESUMO** – Racional – *A ascite aparece no decorrer da doença hepática causando dispnéia, tosse, desconforto, dor e, quando associada ao derrame pleural, acentua a diminuição da cinética respiratória. O aparecimento de hidrotórax é descrito na literatura em até 20% dos doentes e seu tratamento é ainda discutível. Pode ocorrer devido a defeitos diafragmáticos, lesões diafragmáticas ou comunicações peritônio-pleurais sem defeito anatômico, que podem ser diagnosticados através de cintilografia toracoabdominal.* Objetivos – *Abordar a fisiopatologia e a discussão sobre o tratamento e resolução do hidrotórax em um paciente com cirrose hepática.* Métodos – *Tratava-se de um paciente com cirrose hepática de origem alcoólica, com ascite e derrame pleural volumosos. O hidrotórax de origem abdominal foi confirmado pela cintilografia toracoabdominal. O doente foi submetido a várias paracenteses abdominais e torácicas, sempre apresentando recidiva de derrame pleural maciço. Após avaliação da cirurgia torácica, optou-se pela realização da decorticação pulmonar e pleurodese química.* Resultados – *A cirurgia foi realizada com sucesso e não houve recidiva de derrames pleural. A ascite foi controlada parcialmente com diuréticos e orientação alimentar e o paciente não quis ser submetido ao transplante de fígado.* Conclusão – *A pleurodese química pode ser útil nos doentes que, como o do caso descrito, não aceitam o transplante de fígado como terapêutica definitiva e são portadores de derrames pleural causados por ascite volumosa.*

**DESCRITORES** – *Pleurodese. Hidrotórax. Ascite. Hepatopatias.*

---

## REFERENCES

1. Daly JJ, Potts JM, Gordon L, Buse MG. Scintigraphic diagnosis of peritoneo-pleural communication in the absence of ascites. *Clin Nucl Med* 1994;19:892-4.
2. Kaplan LM, Epstein SK, Schwartz SL, Cao QL, Pandian NG. Clinical echocardiographic and hemodynamic-evidence of cardiac tamponade caused by large pleural effusions. *Am J Respir Crit Care Med* 1995;151:904-8.
3. Menten BB, Kayhan B, Gurgul A, Ünal S. Hepatic hydrothorax in the absence of ascites: report of two cases and review of the mechanism. *Dig Dis Sci* 1997;42:781-8.
4. Park CH, Phan CD. Hepatic hydrothorax scintigraphic confirmation. *Clin Nucl Med* 1995;20:278.
5. Rubinstein D, McInnes IE, Dudley FJ. Hepatic hydrothorax in the absence of clinical ascites: diagnosis and management. *Gastroenterology* 1985;88:188-91.
6. Schustter DM, Mukundan S Jr, Small W, Fajman WA. The use of the diagnostic radionuclide ascites scan to facilitate treatment decisions for hepatic hydrothorax. *Clin Nucl Med* 1998;23:16-8.
7. Strauss RM, Boyer TD. Hepatic hydrothorax. *Semin Liver Dis* 1997;17:227-32.
8. Van Thiel DH, Nadir A, Hassanein T, Wright HI. Simultaneous right-sided volume overload and left-sided hypovolemia in a man with massive ascites and a hydrothorax. *Am J Gastroenterol* 1995;90:478-81.
9. Vargas-Tank L, Escobar C, Fernandez G, Rilter L, Soto JR, Jiron MI, Armas-Merino R. Massive pleural effusions in cirrhotic patients with ascites. *Scand J Gastroenterol* 1984;19:294-8.
10. Walker-Renard PB, Vaughan LM, Sahn SA. Chemical pleurodesis for malignant pleural effusions. *Ann Intern Med* 1994;120:56-64.

Recebido em 15/9/1999.  
Aprovado em 7/1/2000.