

CARDIOPLASTY AND ROUX-EN-Y PARTIAL GASTRECTOMY (SERRA-DÓRIA PROCEDURE) FOR REOPERATION OF ACHALASIA

Helio PONCIANO¹, Ivan CECCONELLO², Leosarte ALVES¹,
Berivaldo Dias FERREIRA¹ and Joaquim GAMA-RODRIGUES²

ABSTRACT - Background - After cardiomyotomy for the treatment of megaesophagus, recurrence of symptoms occur in up to 15% of the patients, but only some require a reoperation. **Aim** - To evaluate the results of reoperation - cardioplasty with Roux-en-Y partial gastrectomy, a technique proposed by Serra-Dória. **Casuistic and Methods** - Twenty patients with achalasia previously treated by cardiomyotomy, were retrospectively studied. The etiology of symptoms recurrence was reflux esophagitis in nine (45.0%) patients, healing of the myotomy in five (25.0%), end staging megaesophagus in five (25.0%) and incomplete myotomy in one (5%). Intra and postoperative complications were analyzed. The patients were studied by clinical (dysphagia, regurgitation, heartburn and weight gain), radiological and endoscopic evaluation, in the pre- and postoperative period. **Results** - Five (25.0%) patients had complications in the immediate postoperative period. No deaths were observed. Dysphagia improved in all the patients. Regurgitation and heartburn almost disappeared in the whole group. Weight was maintained or increased in 64.7% of the patients. Radiological studies showed a decrease in the caliber of the esophagus in 53.0%, while the remaining patients maintained the pre-operative diameter. Endoscopy, performed during the late postoperative period in 17 patients, showed that 6 among the 9 with reflux esophagitis improved; 2 among the 8 with a normal esophagus during the preoperative period, developed esophagitis. **Conclusions** - The Serra-Dória procedure for the treatment of megaesophagus in patients who had already undergone cardiomyotomy and whose symptoms recurred, presented a low morbidity and no mortality. It offered a significant relief of symptoms with a decrease of the caliber of the esophagus in several patients. The patients also improved with regards to reflux esophagitis. In some cases reflux was still present after surgery. Others with normal esophagus in the preoperative period developed esophagitis.

HEADINGS - Esophageal achalasia, surgery. Gastrectomy. Esophagectomy. Anastomosis, Roux-en-Y.

INTRODUCTION

Recurrence of dysphagia after cardiomyotomy that is performed to relieve achalasia are gastroesophageal reflux with esophagitis, incomplete myotomy, fibrosis at the site of the esophagogastric junction (EGJ), inadequate indication of the technique for patients with severe megaesophagus and intra-thoracic migration of the gastric fundus^(7, 51).

Reoperations in general have had less success than the original procedure^(11, 14, 56), and some patients require esophageal resection, with the inherent well known complications.

The surgical treatment of recurrent achalasia varies depending on the mechanism causing the recurrence. Thus, for patients with incomplete myotomy or fibrotic scarring of the myotomy, a new myotomy complemented by partial fundoplication^(48, 56, 57) is indicated, provided the esophageal wall has not been injured during dissection.

For patients with significant reflux esophagitis or dolichomegaesophagus, the therapy of choice has been

esophagectomy without thoracotomy and replacing the esophagus with the stomach (cervical gastroplasty)^(1, 46, 47). In the past, this operation involved thoracotomy and replacement of the esophagus by the stomach⁽²⁴⁾ or the colon⁽⁵³⁾. When there is esophagitis without dilatation, an alternative method includes interposing a jejunal loop after resection of the distal esophagus using the MERENDINO and DILLARD⁽⁴¹⁾ technique.

HOLT and LARGE⁽³³⁾, in 1961, suggested the use of the Roux-en-Y partial gastrectomy for the reoperation of achalasia with severe reflux esophagitis secondary to a GRÖNDHAL type cardioplasty⁽²⁹⁾. SERRA-DÓRIA et al.⁽⁵⁸⁾ combined a long latero-lateral anastomosis extending through the esophagus onto the gastric fundus (GRÖNDHAL type cardioplasty⁽²⁹⁾), to facilitate esophageal emptying, with a Roux-en-Y partial gastrectomy⁽⁵⁵⁾ in order to prevent bile reflux for initial treatment of patients with Chagas' megaesophagus. One hundred and thirty patients were submitted to this procedure, with positive results in terms of relief of dysphagia. Since then, this has been known in Brazil as the Serra-Dória procedure^(58, 59).

¹ Federal University of Goiás Medical School, Goiânia, GO; ² University of São Paulo Medical School, São Paulo, SP, Brazil
Address for correspondence: Dr. Ivan Ceccconello - Av. Arnolfo Azevedo, 208 - 01236-030 - São Paulo, SP, Brazil.

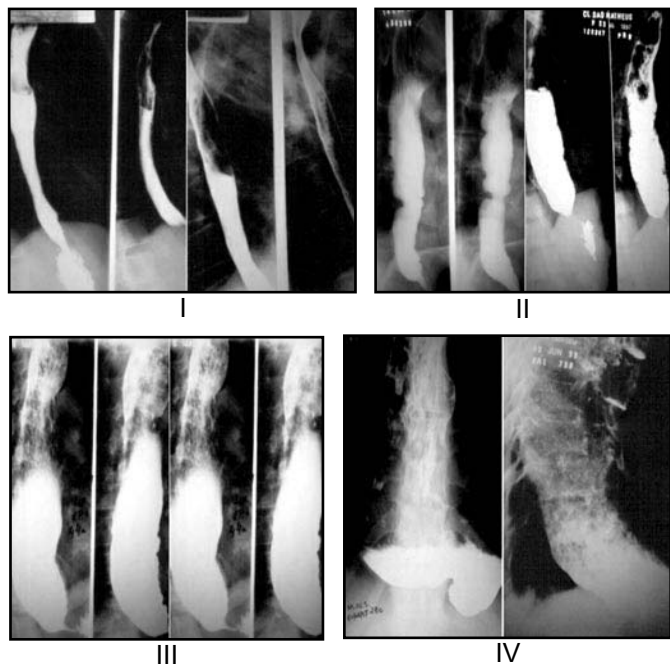


FIGURE 1 - Radiologic classification of achalasia in four groups according to the grade of dilatation motor alterations of the esophagus (Rezende et. al.⁽⁵⁴⁾)

The purpose of this study was to assess the results of the Serra-Dória procedure for the treatment of achalasia in patients with recurrence of symptoms after cardiomyotomy.

METHODS

Twenty patients with achalasia due to Chagas’ disease, who had previously undergone cardiomyotomy with or without fundoplication were studied. All of them underwent reoperation by the Serra-Dória procedure^(58,59). Patients who had esophageal neoplasia associated with achalasia were excluded. Patient’s age ranged from 18 to 70 (mean 49.6) years. Fifteen (75%) were male and five (25%), female.

Clinical evaluation – patients were evaluated as to the presence of dysphagia, regurgitation and heartburn.

Dysphagia was ranked as mild, when occurring with oral intake of solid foods, moderate, with pasty food, and severe, with liquid food. Regurgitation and heartburn were classified as either present or absent. The patients’ body weight was also considered.

Radiologic assessment – patients underwent radiologic study of the esophagus, stomach and duodenum, and were classified according to the findings into four groups, using the REZENDE et al.⁽⁵⁴⁾ classification (Figure 1), as:

- group I – esophageal diameter close to normal, with mild emptying difficulty and small retaining of barium in the esophagus;
- group II – esophagus with moderate dilatation, slow emptying, presence of tertiary waves and moderate stasis;
- group III – significant dilatation of the esophagus, hypotonic esophagus, massive retaining of barium, terminal esophagus elongated at the cardia but still in vertical position;
- group IV - significant dilatation of the esophagus, with axis turned to the right over the diaphragm (dolichomegaesophagus),

prolonged retention of barium, with difficult barium entrance into the stomach.

Endoscopic evaluation – all patients underwent endoscopic assessment of the esophagus. The aspect of the esophageal mucosa was thoroughly assessed as to the absence or presence of reflux esophagitis.

Diagnosis of symptom recurrence after cardiomyotomy – recurrence was classified into: incomplete myotomy, scarring at the site of the myotomy, gastroesophageal reflux with esophagitis, and severe megaesophagus (group IV) according to the time for recurrence of symptoms after cardiomyotomy, the radiologic classification of achalasia, and the presence or absence of reflux esophagitis at endoscopy (Table 1).

TABLE 1 – Etiology of recurrence of symptoms after cardiomyotomy

	Time until recurrence of symptoms	Group according to esophagogram	Endoscopy
Reflux esophagitis	>6 (months)	I, II, III, IV	Reflux esophagitis
Incomplete myotomy	<3 a 6 (months)	I, II, III	Normal mucosa
Fibrosis at the myotomy	>6 (months)	I, II, III	Normal mucosa
Severe megaesophagus (group IV)	<3 a 6 (months)	IV	Normal mucosa

Surgical technique – all the patients were reoperated by the Serra-Dória technique^(58, 59) (Figure 2), as described below.

- washing of the esophagus with a sodium chloride solution instilled through an esophageal tube, 12 h before the operation;
- upper median laparotomy;
- release of adhesions from the previous operation, section of the left triangular ligament of the liver and isolation of the esophagus;
- latero-lateral gastroesophageal anastomosis by the Gröndahl technique⁽²⁹⁾ with one or two layers, with interrupted stitches or mechanical stapler (Figure 2A);
- partial gastrectomy with oralis totalis Roux-en-Y gastrojejunal anastomosis (Figure 2B);

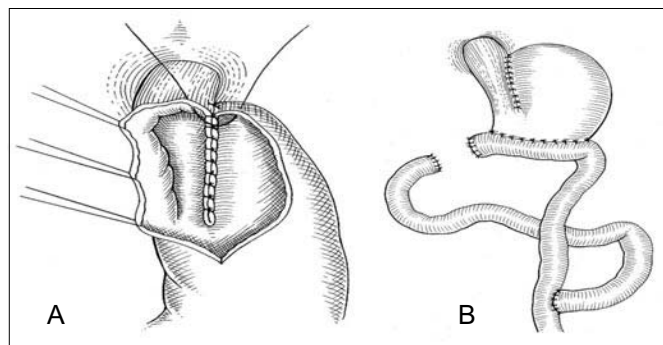


FIGURE 2 - Gröndahl cardioplasty and Roux-en-Y portal gastrectomy Serra-Dória for procedure reoperation of achalasia after cardiomyotomy

Intra- and postoperative complications – intraoperative complications were assessed mainly as to the difficulties in dissecting adhesions from the original operation. Postoperative complications included:

- immediate: those occurring 30 to 60 days after surgery
- late: those noted 6 to 108 months (mean 22.3 months) after surgery.

Patients underwent clinical evaluation (presence and intensity of dysphagia, regurgitation and heartburn) in the immediate and late follow-up periods. Weight gain, radiologic (caliber of the esophagus

according to the REZENDE et al. classification⁽⁵⁴⁾ and endoscopic (presence or absence of reflux esophagitis) evaluations were assessed in the late postoperative follow-up. The results thus obtained were compared with those from the preoperative period.

Statistical analysis – the Wilcoxon’s test was used to compare the pre- and postoperative results relative to the clinical (dysphagia, regurgitation and heartburn), radiologic and endoscopic evaluation. Significance level was established at $P \leq 0.05$.

RESULTS

Diagnosis of symptom recurrence – nine (45%) patients were diagnosed with reflux esophagitis, five (25%) with fibrotic scarring of the myotomy, five (25%) with severe megaesophagus (group IV) and one (5%) with incomplete myotomy

Intra- and postoperative complications – adhesions joining the stomach and neighboring structures, which were released with no further consequence, were found in all the patients. There was perforation in the anterior wall of the esophagus in one patient during isolation of the organ. Such perforation was widened, and the procedure was completed with latero-lateral gastroesophageal anastomosis.

Duration of the operation ranged from 140 to 405 minutes (mean 246.2), and time of hospitalization lasted 8 to 42 days (mean 12).

Two patients (10%) developed fistula of the gastroesophageal anastomosis, and were fed parenterally until total occlusion of the fistula. They were discharged from hospital on the 22nd and the 42nd postoperative days, respectively. Two patients (10%) had transient dysphagia, and one (5%) had pneumothorax. In the latter one the left pleura was perforated during isolation of the esophagus, which was then sutured; however, he had pneumothorax soon after the operation. A thoracic drainage was successfully performed. There was no mortality.

Clinical evaluation – three patients (15%) presented with moderate, and 17 (85%) with severe dysphagia preoperatively. In the immediate postoperative period clinical evaluation showed: 16 (80%) patients with no dysphagia, and 4 (20%) with mild dysphagia (Table 2). All patients significantly improved from dysphagia in the postoperative period ($P = 0.001$).

TABLE 2 - Pre-operative and immediate post-operative evolution of dysphagia in patients submitted to the Serra-Dória procedure for reoperation of achalasia - 20 patients

Dysphagia	Pre-operative		Immediate post-operative	
	n	%	n	%
Without	0	0	16	80
Mild	0	0	4	20
Moderate	3	15	0	0
Severe	17	85	0	0
Total	20	100	20	100

$P = 0,001$

In the late postoperative period, 17 patients came back for evaluation. All showed improvement from dysphagia. Ten (58.5%) had no difficulty in swallowing, six (35.3%) presented with mild, and one (5.9%) with moderate dysphagia. A significant difference ($P = 0.001$) was seen in the comparison of the pre- with the late postoperative period (Figure 3).

Regurgitation was found in 16 (80%) of the patients in the preoperative period. Only 4/20 patients (20%) had regurgitation in the

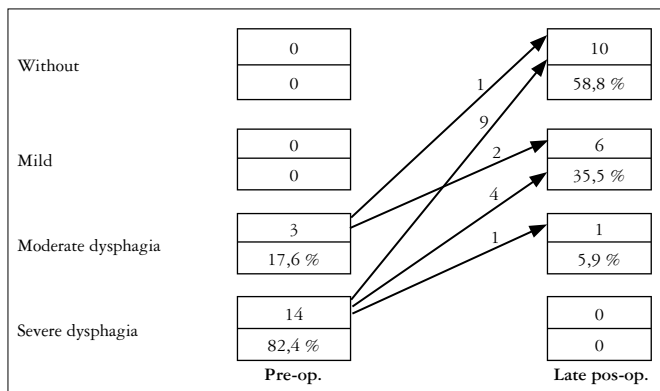


FIGURE 3 - Pre-operative and late post-operative evaluation of dysphagia in patients submitted to the Serra-Dória procedure for reoperation of achalasia - 17 patients

immediate, and 2/17 (11.8%) in the late postoperative period. Thus, 80% of patients were asymptomatic in the immediate, and 88.2% in the late postoperative period. There was a significant difference in terms of regurgitation from the pre- to the immediate ($P = 0.001$) and to the late ($P = 0.005$) postoperative periods.

Heartburn was present in 65% of patients in the pre-operative assessment. Only 2/20 (10%) patients suffered heartburn in the immediate, and 3/17 (17.6%) in the late postoperative periods. A significant improvement was seen both in the immediate ($P = 0.005$) and late ($P = 0.005$) postoperative periods.

Interestingly, two (10%) patients presented with a mild dumping syndrome. Symptoms disappeared in the late postoperative period. One patient had anemia 9 years after surgery.

Seventeen patients were assessed as to weight gain in the late postoperative period. Five (29.4%) gained weight, six (35.4%) remained with the same weight, and six (35.4%) lost weight. Average weight gain was 11.8 kg, and weight loss was 7.7 kg.

Radiologic evaluation – was performed pre- and postoperatively in 13 (65%) patients. Preoperatively, the exam showed six (46.2%) patients with group III, and six (46.2%) with group IV megaesophagus; one patient’s esophagogram (7.6%) was compatible with group II megaesophagus. Postoperatively, six (46.2%) patients had group II roentgenogram, and four (30.7%) group III megaesophagus; three (23.1%) patients remained as group IV megaesophagus (Figure 4). There was a significant narrowing ($P = 0.003$) of esophageal caliber after the operation, including three patients who had severe megaesophagus before.

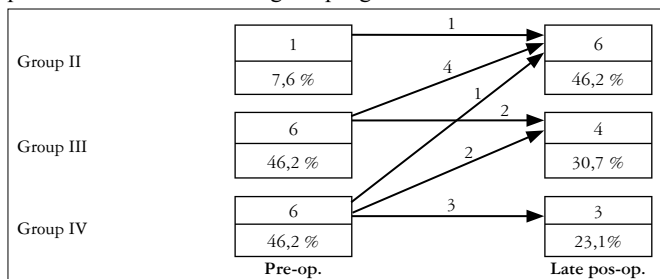


FIGURE 4 – Pre-operative and late post-operative radiologic assessment of patients submitted to the Serra-Dória procedure for reoperative of achalasia (13 patients)

Endoscopic evaluation – pre-and late postoperative endoscopy was performed in 17 patients (Figure 5). Three of the nine patients who had reflux esophagitis in the preoperative period still had it after the operation. Thus, six patients experienced improvement from esophagitis.

Two new cases were seen after surgery. No significant difference from the pre- to the postoperative evaluation was seen ($P = 0.157$).

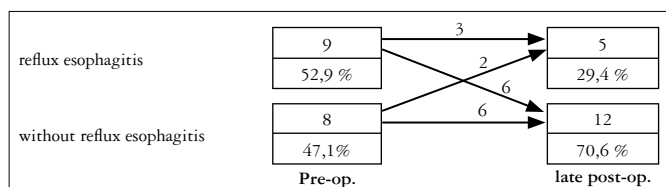


FIGURE 5 – Pre-operative and late post-operative endoscopic assessment of patients submitted to the Serra Dória's procedure for reoperation of achalasia (17 patients)

DISCUSSION

Historically, the treatment of achalasia by cardiomyotomy was first designed by GOTTSTEIN⁽²⁷⁾, in 1901. However, HELLER⁽³⁰⁾, in 1913, acclaimed the procedure by performing it in the anterior and posterior esophageal walls.

Myotomy became the surgery of choice to treat achalasia because of its simple technique on the anterior wall of the esophagus, accessed either by abdominal⁽²⁸⁾ or thoracal route⁽⁶³⁾. However, because it alters the normal anatomy of the gastroesophageal junction, the procedure often is complicated by the occurrence of gastroesophageal reflux.

In an attempt to prevent such reflux, fundoplication was added to the myotomy, thus promoting an antireflux mechanism and obtaining improved results^(12, 35, 45), with rates of esophagitis between 2.8% to 5%^(13, 21). Although cardiomyotomy with fundoplication for treatment of non-advanced megaesophagus brings good results in 85% to 97.6% of the patients^(10, 14, 15, 21, 25, 31, 43, 45), dysphagia can still be maintained. Its occurrence has not decreased along the years, despite the larger experience with the technique.

When only cardiomyotomy is performed, reflux esophagitis occurred in 17% to 30% of the patients^(8, 10, 60). Myotomy increases exposure of the esophagus to acid or alkaline secretion, and in doing so it opens the door to future complications, among which are inflammation of the esophageal mucosa, heartburn and recurrence of dysphagia.

Other causes of recurrence of dysphagia following cardiomyotomy are^(14, 15, 25, 40, 51): **incomplete cardiomyotomy** – represented by the inadequate sectioning, either in depth or in extension, of the bundle of muscles of the EGJ; as a consequence, dysphagia remains practically unaltered soon after operation, or will have only minor improvement; **fibrotic healing at the site of myotomy** – reapproaching the fibrotic edges of the myotomy is the cause for relapse of dysphagia in the relatively late postoperative period. Bleeding in the area of the myotomy and mucosa injuries, although identified and treated at the time of the operation, would be the main causes for this type of recurrence of symptoms; **inappropriate indication of the cardiomyotomy technique for severe megaesophagus** – the aperistaltic esophagus fails to present appropriate emptying, therefore there is a very short period of improvement from dysphagia^(11, 48, 51, 57).

For a proper treatment, identification of the cause of recurrence of dysphagia after surgical treatment of achalasia is necessary⁽¹⁵⁾. Data of the previous operation, time for recurrence of symptoms and findings during reoperation are important information for finding the right diagnosis. Other investigators add endoscopic and radiologic evaluations⁽¹⁶⁾, preoperative^(4, 18, 51, 56) or intraoperative esophageal pressure⁽¹¹⁾, or 24-hour esophageal pH measurements⁽¹¹⁾ as diagnostic

methods. In the present study, time to recurrence of symptoms after the first operation, barium swallow to observe the degree of esophageal dilatation, and esophagoscopy to study mucosal damage were used to diagnose relapse. Reflux esophagitis was observed in nine patients (45%), healing of myotomy in five (25%), failed myotomy in severe megaesophagus in five (25%) and incomplete myotomy in one (5%). PINOTTI and FELIX⁽⁵¹⁾ observed the following causes for recurrence of symptoms in 118 patients: incomplete myotomy in 23 (34.7%), reflux esophagitis in 36 (30.5%), dolichomegaesophagus in 23 (19.5%), migration of fundoplication into the thorax in 2 (1.7%), and healing of myotomy in 16 (13.6%).

Based on our results and those from the literature^(4, 18, 25, 48, 51, 56), we conclude that inadequate indication of cardiomyotomy for severe megaesophagus, or inadequate myotomy, are the main factors of early failure of the first procedure. Both are manifested by early recurrence of dysphagia. On the other hand, both reflux esophagitis and a fibrotic healing at the site of cardiomyotomy characteristically show later recurrence of symptoms.

Besides cardiomyotomy, other types of operation, such as the earlier HEYROVSKY⁽³²⁾ and the GRÖNDAHL⁽²⁹⁾ cardioplasties, or more recently the THAL et al.⁽⁶¹⁾ procedure, are used to treat achalasia, but are also followed by recurrence of symptoms. Their short- and medium-term results show gastroesophageal reflux, and later, stenosis and Barrett's esophagus^(6, 22) as complications. The THAL et al.⁽⁶¹⁾ operation is still used in several medical services in Brazil^(2, 3, 23) for initial or second surgical treatment of achalasia.

For treating severe reflux esophagitis in achalasia patients who had previously undergone Gröndahl⁽²⁹⁾ cardioplasty, HOLT and LARGE⁽³³⁾, in 1961, designed a secondary operation — a Roux-en-Y partial gastrectomy with vagotomy⁽⁵⁵⁾. An immediate improvement of symptoms was obtained, with no evidence of postoperative reflux esophagitis.

Following the procedure described by HOLT and LARGE⁽³³⁾, SERRA DÓRIA et al.⁽⁵⁸⁾ started to use an association of Gröndahl cardioplasty with partial Roux-en-Y gastrectomy, as the first treatment for achalasia, with good results. In this operation, a large exposition of the intraabdominal esophagus must be undertaken, with the dissection extended proximally as far as the dilated portion of the organ, which is easily identified. The vagus nerve must be isolated, especially its anterior branch; however, this can be accidentally injured in some instances where there are technical difficulties, when the area has a massive fibrosis.

In reoperations on the EGJ the probability of esophageal injury is higher due to the adhesions of this organ with neighboring structures. The intramediastinal esophageal access by median phrenotomy⁽⁴⁶⁾, if necessary, allows for reaching the esophagus outside the fibrotic area, thus enabling better visualization and safe dissection of the structures in this area.

One patient presented an intraoperative pleural damage; suture of the damage was performed immediately. However, the patient developed pneumothorax, requiring postoperative thoracic drainage.

The main postoperative complication was fistula of the gastroesophageal anastomotic, which occurred in two patients (10%). Both were treated with total parenteral nutrition and progressed well. The occurrence of these fistulae was probably related to the difficulty with EGJ dissection due to the adhesions resulting from the previous operation. One of the patients had undergone two operations before. This was also observed by MENDELSSOHN et al.⁽³⁹⁾, who reported higher occurrence of

fistulae when performing THAL et al.⁽⁶¹⁾ operation in 17 patients who had previously undergone more than one operation for the treatment of achalasia.

SERRA-DORIA et al.⁽⁵⁸⁾ did not report any fistulae in 130 patients operated on by their technique. Neither did GOLDEMBERG⁽²⁶⁾ in the 11 patients operated on by the same technique, in which a vagotomy was also associated with the procedure.

Many investigators have used selective criteria to indicate the technique used for correction of symptoms recurrence^(15, 17, 20, 34, 42, 44, 51, 57, 59). There is a trend to perform a new myotomy over the previous one, or beside it, in the cases of incomplete or fibrotic myotomies^(40, 48, 56, 57). Esophageal resection would be reserved for patients with severe megaesophagus⁽⁴⁸⁾.

After conservative surgical treatment of achalasia some degree of dysphagia may persist, and this could be explained by the motility alterations already existing in the esophagus, which do not improve after surgery⁽¹³⁾. Intense dysphagia appearing early after surgery is related to a defective technique. In incomplete myotomies, dysphagia occurs in the majority of patients up to 6 months after surgery^(25, 48). In severe megaesophagus, even when a technically perfect myotomy is performed, emptying of the esophagus is not adequately done because it is an atonic organ.

All the patients in this study had preoperative moderate or severe dysphagia and improved significantly after the procedure. As to the relief from dysphagia, results obtained with the Serra-Dória operation^(58, 59) are similar to those obtained with cardiomyotomies^(5, 51, 57) and with the Thal et al. operation^(2, 3, 23).

The Serra-Dória^(58, 59) operation also showed improvement of regurgitation, more significantly in the late follow-up. The operation yielded reduction of stasis, and regression of the esophageal caliber was observed in several patients. Six patients remained with the same degree of esophageal dilation, a fact that was also reported by ELLENBOGEN⁽¹³⁾, who credited the lack of esophageal caliber reduction after cardiomyotomy to fibrosis and atony.

Although there was improvement of heartburn, two patients developed reflux esophagitis postoperatively, even using the Roux-en-Y partial gastrectomy⁽⁵⁵⁾, due to the large communication resulting from the latero-lateral gastroesophageal anastomosis; the patients presenting with esophagitis were treated with proton pump inhibitors, and are presently asymptomatic. On the other hand, SERRA et al.⁽⁵⁷⁾ performed a new myotomy in patients with symptom recurrence due to incomplete myotomy and observed postoperative reflux esophagitis in 40% of the patients. With the Thal et al. cardioplasty⁽⁶¹⁾, a rate of 30% postoperative reflux esophagitis⁽²³⁾ was observed.

Several types of treatment for severe megaesophagus have been suggested, almost always with high indices of complications: 27.8% stripping mucosectomy with maintenance of the esophageal tunica muscularis followed by cervical gastroplasty⁽¹⁾; 28% in esophagectomy without thoracotomy^(50, 52, 56); and more than 50% in coloplasty⁽⁵³⁾.

No mortality was observed by CECCONELLO et al.⁽⁵⁾, in 12 patients who failed cardiomyotomy and underwent esophagectomy without thoracotomy. Late postoperative results were observed in 83.3% of the

patients. In the present study the Serra-Dória operation^(58, 59) proved similarly efficient to treat severe megaesophagus. The method is simple and any surgeon who has training in abdominal surgery can perform it.

The main indication for cardioplasty with Roux-en-Y partial gastrectomy is for reoperation of achalasia due to reflux esophagitis. Nine of the patients with gastroesophageal reflux experienced postoperative improvement, and in seven patients the endoscopic assessment revealed no esophagitis. Other investigators have also used the Roux-en-Y partial gastrectomy⁽⁵⁵⁾ to treat reflux esophagitis in reoperations of the megaesophagus, with excellent results^(17, 18, 19, 20, 25).

Fundoplication in patients with massive reflux from previous cardiomyotomy hardly ever shows good results. CECCONELLO et al.⁽⁵⁾ observed persistence of symptoms in 17/29 patients (41.2%) in whom partial fundoplication was associated with the previously existing cardiomyotomy. However, they observed good results in 8/9 patients (88.8%) undergoing esophagectomy without thoracotomy with cervical gastroplasty. High esophagogastric anastomoses, on the other hand, are followed by reflux esophagitis and Barrett's esophagus in the cervical stump^(4, 38, 39). The occurrence of esophagitis increases with the years of postoperative follow-up^(6, 38).

Thus, reflux esophagitis represents a complication to be found in reoperations for megaesophagus, independent of the technique used, new myotomy, esophagectomy and gastroplasty (esophageal stump esophagitis), cardioplasty, and also the Serra-Dória operation.

Ulcers of the gastrojejunal anastomosis were not observed, since a vagotomy associated with gastrectomy was not performed. It is possible that this fact relates to the decrease in the baseline secretion of acid by the stomach in patients with Chagas' achalasia⁽³⁷⁾, and to partial gastrectomy.

The nutritional status of patients have improved after treating achalasia by cardiomyotomy⁽¹³⁾, cardioplasty⁽²⁾, esophageal resection^(4, 49), or in reoperation for megaesophagus⁽⁵⁷⁾. The majority of patients in this study either maintained or gained weight; however, 35% lost weight. These results may be related to partial gastrectomy.

From the clinical viewpoint, no symptoms suggesting slow gastric emptying were observed, although this was evidenced in patients who underwent Roux-en-Y partial gastrectomy^(3, 6, 36, 62) to treat other diseases. Mild dumping syndrome was seen in two (10%) patients. They both experienced improvement in the first postoperative weeks with dietary measures.

Thus, it was observed that the Serra-Dória operation^(58, 59), can be easily performed, with low morbidity and mortality. It yielded important relief from symptoms, specially from dysphagia, and in most instances, a reduction of esophageal caliber. There was also improvement of reflux esophagitis. Yet, it is possible the occurrence of reflux in patients who did not present it before.

Because it yields good results in terms of symptoms relief, it can be accredited as viable alternative for treating patients with failed cardiomyotomy for the treatment of achalasia. Further studies, with longer follow-up terms, are required in order to reach more definitive conclusions, in special as to the occurrence of later complications not identified in the present study.

Ponciano H, Ceconello I, Alves L, Ferreira BD, Gama-Rodrigues J. Cardioplastia e gastrectomia parcial em Y-de-Roux (operação de Serra-Dória) para reoperações no megaesôfago. *Arq Gastroenterol* 2004;41(2):155-61.

RESUMO - Racional - Nas operações de cardiomiectomia para tratamento do megaesôfago ocorre recidiva dos sintomas em até 15% dos pacientes, sendo que alguns necessitam reoperação. **Objetivo** - Avaliar os resultados de reoperações através de cardioplastia e gastrectomia parcial em Y-de-Roux, conforme técnica proposta por Serra-Dória. **Casística e Métodos** - Foram estudados de forma retrospectiva, 20 pacientes com megaesôfago previamente tratados por cardiomiectomia. A causa de recidiva dos sintomas foi esofagite de refluxo em nove (45,0%), miotomia incompleta em um (5,0%), cicatrização da miotomia em cinco (25,0%) e presença de megaesôfago avançado em cinco (25,0%). Analisaram-se as complicações intra e pós-operatórias. Os pacientes foram avaliados sob o ponto de vista clínico (disfagia, regurgitação, pirose e variação de peso), radiológico e endoscópico, no pré e no pós-operatório imediato e tardio. **Resultados** - Cinco (25,0%) doentes apresentaram complicações no pós-operatório imediato. Não houve mortalidade. Todos os doentes melhoraram da disfagia, com quase total desaparecimento da regurgitação e pirose. Houve manutenção ou aumento de peso em 64,7% dos pacientes. O estudo radiológico mostrou diminuição do calibre do esôfago em 53,0% e manutenção nos demais. Não houve aumento do calibre em nenhum dos pacientes. No exame endoscópico realizado no pós-operatório tardio em 17 pacientes, observou-se que 6 entre 9 que apresentavam esofagite de refluxo, melhoraram; 2 entre 8, que apresentavam esôfago normal no pré-operatório, desenvolveram esofagite. **Conclusões** - A operação de Serra-Dória para tratamento do megaesôfago, operado por cardiomiectomia com recidiva dos sintomas, apresentou baixa morbidade e ausência de mortalidade. Permiteu expressivo alívio dos sintomas e diminuição do calibre do esôfago em vários doentes. Possibilitou, também, melhora da esofagite de refluxo, havendo, entretanto, a possibilidade de sua manutenção, bem como do seu aparecimento em doentes que não a apresentavam.

DESCRIPTORIOS - Acalasia esofágica, cirurgia. Gastrectomia. Esofagectomia. Anastomose em-Y-de Roux.

REFERENCES

- Aquino JLB, Reis-Neto JA, Muraro CL, Camargo JGJ. Esophageal mucosectomy in the treatment of the advances megaesophagus: analysis of 60 cases. *Rev Col Bras Cir* 2000;27:109-16.
- Barbosa H, Barrichello AW, Vianna AL, Mendelssonh P. Megaesôfago chagásico: tratamento pela cardioplastia a Thal. *Rev Col Bras Cir* 1981;8:16-28.
- Barbosa H, Barrichello AW, Vianna AL, Mendelssonh P, Watanabe LM. Tratamento cirúrgico do megaesôfago: duas décadas de experiência numa região endêmica. *Rev Goiana Med* 1989;35:1-23.
- Ceconello I, Mariano-da-Rocha JR., Pollara WM, Zilberstein B. Long-term evaluation of gastroplasty in achalasia. In: Siewert R, A.H. Holscher AH, editors. - Diseases of the esophagus. Berlin: Springer-Verlag; 1988. p.975-9.
- Ceconello I, Zilberstein B, Domene CE, Nasi A, Pinotti HW. Recurrence of symptoms after management of achalasia. In: 3rd International Polydisciplinary Congress of OESO; 1990; Paris.
- Ceconello I, Mariano-da-Rocha JR, Zilberstein B, Felix VN, Pinotti HW. Reflux esophagitis and development of ectopic columnar epithelium in the esophageal stump after gastric transposition: a prospective study. In: Nabeya K, Hanaoka T, Nogami H, editors. Diseases of the esophagus. Tokyo: Springer-Verlag; 1993. p.91-6.
- Ceconello I, Sallum RA, Zilberstein B, Pinotti HW. When fundoplication is added to the miotomy, is there a risk of intra-thoracic migration of the valve after reduction of the esophageal caliber? In: Giuli R, Galmiche JP, Jamieson GG, Scarpignato C, editors. The esophagogastric junction. Paris: John Libbey Eurotext; 1998. p.1441-3.
- Chaib SA, Lopasso FP, Parra OM, Saad WA, Vasconcelos E. Tratamento do megaesôfago pela técnica de Heller-Vasconcelos. Experiência de 200 casos. *Rev Hosp Clin Fac Med São Paulo* 1977;32:178-83.
- Csendes A, Velasco N, Braghetto I. A prospective randomized study comparing forceful dilatation and esophagomyotomy in patients with achalasia of the esophagus. *Gastroenterology* 1981;80:789.
- Csendes A. Results of surgical treatment of achalasia of the esophagus. *Hepatogastroenterology* 1991;38:474-80.
- Del Genio A, Di Martino N, Mafettone V, Izzo G, Zampello P, Mugione P. Insuccessi della terapia chirurgica dell'achalasia: diagnosi e trattamento. *Ann Ital Chir* 1995;66:587-95.
- Dor J, Humbert P, Dor V, Figarelatt J. L'interet de la technique de Nissen modifié dans la prévention du reflux après cardiomiectomie extramuqueuse de Heller. *Mem Acad Chir* 1962;88:877.
- Ellenbogen G. Megaesôfago não avançado; tratamento pela cardiomiectomia associada à esofagofundogastropexia. Avaliação clínica, morfológica e funcional dos seus resultados [tese livre docência]. São Paulo, Faculdade de Medicina, Universidade de São Paulo; 1979.
- Ellis FH Jr, Gibb SP. Reoperation after esophagomyotomy for achalasia of the esophagus. *Am J Surg* 1975;129:407.
- Ellis FH Jr, Crozier RE, Gibb SP. Reoperative achalasia surgery. *J Thorac Cardiovasc Surg* 1986;92:859-65.
- Fékété F, Lortat-Jacob JL. Échecs et prétendus échecs de l'opération de Heller pour méga-oesophage idiopathique. Étude de 55 malades réopérés. *Ann Chir* 1977;31:515-24.
- Fékété F, Breil PH. Les réintervencion après intervention de Heller pour achalasia ey autres dysfonctionnements moteurs de l'oesophage. *Acta Chir Belg* 1982;82:333-43.
- Fékété F, Breil PH, Tossen JC. Reoperation after Heller's operation for achalasia and other motility disorders of the esophagus: a study of eight-one reoperation. *Int Surg* 1982;67:103-10.
- Fékété F, Pateron D. What is the place of antrectomy with Roux-en-Y in the treatment of reflux disease? Experience with 83 total duodenal diversions. *World J Surg* 1992;16:349-53.
- Felix VN, Ceconello I, Pinotti HW. Diagnóstico da causa de recidiva após tratamento cirúrgico do megaesôfago não avançado. *ABCD Arq Bras Cir Dig* 1989;5 (Supl 4):259-61.
- Felix VN. Tratamento do megaesôfago chagásico incipiente. Estudo comparativo entre a dilatação hidroestática forçada da cárdia e esofagocardiomiectomia com esofagofundopexia [tese]. São Paulo: Faculdade de Medicina, Universidade de São Paulo; 1994.
- Ferooq PA, Keren DF. Barrett's esophagus complicating achalasia after esophagomyotomy. *J Clin Gastroenterol* 1987;9:232-7.
- Ferraz AAB, Nóbrega Jr BG, Mathias CA, Bacelar TS, Lima FEA, Ferraz EM. Late results on the surgical treatment of chagasic megaesophagus with the Thal-Hatafuku procedure. *J Am Coll Surg* 2001;193:493-8.
- Ferreira-Santos R. Tratamento cirúrgico da aperistalse esofágica (megaesôfago) [tese - provimento de cátedra]. Ribeirão Preto: Faculdade de Medicina de Ribeirão Preto, Universidade de São Paulo; 1963.
- Gayet B, Fékété F. Surgical management of failed esophagomyotomy (Heller operation). *Hepatogastroenterology* 1991;38:488-92.
- Goldenberg S. Cirurgia megaesôfago - operação de Grondahl-Dória modificada. *Rev Goiana Med* 1973;19:195-201.
- Gottstein G. Technik und klinik der oesophagus kopie. *Mitt Grenzgeb Med Chir* 1981;8:57-152.
- Groeneveldt B Jr. Over cardiospasmus. *Nederl T Geneesk* 1918;54:1281-2.
- Gröndahl NB. Cardioplastik Ved Cardiospasmus. *Nord Kirurgisk Forenings* 1916;11:236-40.
- Heller E. Extramukose cardioplastik beim chonischen cardiospasmus mit dilatation des oesophagus. *Mitt Grenzgeb Med Chir* 1913;27:141-9.
- Herbella FAM, Del Grande JC, Lourenço LG, Mansur NS, Haddad MC. Resultados tardios da operação de Heller associada à fundoplicatura no tratamento do megaesôfago: análise de 83 casos. *Rev Assoc Med Bras* 1999;45:317-22.
- Heyrovsky H. Casuistik und therapie der idiopathischen dilatation der speiseoher. Oesophagogastronastomosis. *Langenbecks Arch Klin Chir* 1913;100:703-15. (apud Ellenbogen 1979)
- Holt CJ, Large AM. Surgical management of reflux esophagitis. *Ann Surg* 1961;153:555.

34. Jamieson GG. Gastro-esophageal reflux following myotomy for achalasia. *Hepatogastroenterology* 1991;38:506-9.
35. Jekler J, Lhotka J. Modified Heller procedure to prevent postoperative reflux esophagitis in patients with achalasia. *Am J Surg* 1867;113:251-4.
36. Mathias JR, Fernandez A, Sninsky CA, Clench MH, Davis RH. Nausea, vomiting, and abdominal pain after Roux-en-Y anastomosis: motility of the jejunal limb. *Gastroenterology* 1985;88:101-7.
37. Mariano-da-Rocha JR, Gama-Rodrigues JJ, D'Albuquerque LAC, Garrido Jr AB, Cecconello I, Laudanna AA, Sallum RAA, Pinotti HW. Serum gastrin, pepsinogen levels and gastric acid secretion in patients with Chagas' disease. *ABCD Arq Bras Cir Dig* 1989;4:83-90.
38. Mariano-da-Rocha JR, Cecconello I, Zilberstein B, Sallum RAA, Sakai P, Ishioka S, Pinotti HW. Esôfago de Barrett no coto esofágico após esofagectomia subtotal com esofagogastroplastia cervical. *Rev Hosp Clin Fac Med S Paulo* 1992;47:69-70.
39. Mendelsohn P, Vianna AL, Barichello AW, Watanabe LM, Barbosa H. Megaesôfago chagásico recidivado: tratamento pela cardioplastia à Thal. *Rev Goiana Med* 1984;30:97-109.
40. Mercer CD, Hill LD. Reoperation after failed esophagomyotomy for achalasia. *Can J Surg* 1986;29:177-80.
41. Merendino KA, Dillard DK. The concept of sphincter substitution by an interposed jejunal segment for anatomic and physiologic abnormalities at the esophagogastric junction, with special reference to reflux esophagitis, cardiospasm and esophageal varices. *Ann Surg* 1955;142:486-509.
42. Patrick DL, Payne WS, Olsen AM, Ellis FH. Reoperation for achalasia of the esophagus. *Arch Surg* 1971;103:122-8.
43. Patti MG, Pellegrini CA, Arcerito M, Tong J, Mulvihill SJ, Way LW. Comparison of medical and minimally invasive surgical therapy for primary esophageal motility disorders. *Arch Surg* 1995;130:606-16.
44. Peracchia A, Nosadina A, Tremolada C, Bardini R. Reoperation after Heller's operation for megaesophagus. *Chirurgie* 1986;112:50-5.
45. Pinotti HW, Gama-Rodrigues JJ, Ellenbogen G, Raia A. Nova técnica no tratamento cirúrgico do megaesôfago: esofagocardiomiectomia associada com esofagofundogastropexia. *Rev Goiana Med* 1974;20:1-13.
46. Pinotti HW. Acesso extrapleural ao esôfago por frenolaparotomia. *Rev Assoc Med Bras* 1976;22:57-60.
47. Pinotti HW. Esofagectomia subtotal por túnel transmediastinal sem toracotomia. *Rev Assoc Med Bras* 1977;23:395-8.
48. Pinotti HW, Felix VN, Domene CE, Purceli EL. Recurrence of dysphagia in patients operated on for megaesophagus: analysis of determining factors. *Chir Gastroenterol* 1979;13:1-7.
49. Pinotti HW, Cecconello I, Mariano-da-Rocha JR, Zilberstein B. Resection for achalasia of the esophagus. *Hepatogastroenterology* 1991;38:470-3.
50. Pinotti HW, Felix VN, Zilberstein B, Cecconello I. Surgical complications of Chagas diseases: megaesophagus, achalasia of the pylorus, and cholelithiasis. *World J Surg* 1991;15:198-204.
51. Pinotti HW, Felix VN. Reoperação no megaesôfago recidivado por transecção mediana do diafragma. In: Pinotti HW, editor. *Acesso ao esôfago torácico por transecção mediana do diafragma*. São Paulo: Atheneu; 1999. p.121-8.
52. Pinotti HW, Mariano-da-Rocha JR. Acesso por transecção mediana do diafragma do esôfago no tratamento do megaesôfago avançado - resultados imediatos. In: Pinotti HW, editor. *Acesso ao esôfago torácico por transecção mediana do diafragma*. São Paulo: Atheneu; 1999. p.167-72.
53. Rassi L. Esofagocoloplastia retroesternal no tratamento cirúrgico do dolicoesôfago. *Rev Goiana Med* 1973;19:153-68.
54. Rezende JM, Lauer KM, Oliveira AR. Aspectos clínicos e radiológicos da aperistalse do esôfago. *Rev Bras Gastroenterol* 1960;12:247.
55. Roux PPE. Chirurgie gastrointestinale. *Rev Chir* 1893;13:402-13.
56. Serra HO, Felix VN, Cecconello I, Pinotti HW. Manometric aspects of the incomplete myotomy. *ABCD Arq Bras Cir Dig* 1996;11:62-5.
57. Serra HO, Felix VN, Cecconello I, Pinotti HW. Reapplication of myotomy and fundoplication in the surgical treatment of recurrent dysphagia after incomplete myotomy. *Rev Hosp Clin Fac Med São Paulo* 1998;53:129-33.
58. Serra-Dória OB, Silva-Dória OM, Silva-Dória OR. Nova conduta cirúrgica para o tratamento do megaesôfago (técnica de Serra Dória). *An Paul Med Cir* 1970;97:115-21.
59. Serra-Dória OB. Tratamento cirúrgico do megaesôfago operação de Serra Dória. *Rev Goiana Med* 1973;19:185-93.
60. Stipa S, Belsey R. Esophagomyotomy and antireflux operation for achalasia. *Chir Gastroenterol* 1976;10:3.
61. Thal PA, Hatafuku T, Kurtzman R. New operation for distal esophageal stricture. *Arch Surg* 1965;90:464.
62. Vogel BS, Vair DB, Woodward MD. Alteration in gastrointestinal emptying of 99m-Techetium-labeled solids following sequential antrectomy, truncal vagotomy and Roux-Y gastroenterostomy. *Ann Surg* 1983;198:506-13.
63. Zaaizer JH. Cardiospasm in the aged. *Ann Surg* 1923;77:615-7.

Recebido em 16/5/2003.
Aprovado em 9/10/2003.