

THE VITAMIN E REDUCES LIVER LIPOPEROXIDATION AND FIBROSIS IN A MODEL OF NONALCOHOLIC STEATOHEPATITIS

Idilio ZAMIN Jr., Angelo Alves de MATTOS, Ângelo Zambam de MATTOS, Gabriela CORAL, Diogo SANTOS and Cláudia RHODEN

ABSTRACT – *Context* - No effective treatment is available for nonalcoholic steatohepatitis in nowadays. *Objectives* - To develop a model of nonalcoholic steatohepatitis induced by a methionine and choline deficient diet, as well as to evaluate the role of metformin, vitamin E and simvastatin in the nonalcoholic steatohepatitis progression. *Methods* - The study analyzed prospectively 50 Wistar rats for a 90-day period and divided them into five groups of 10 rats. One group was given standard rat diet and the others received the methionine and choline deficient diet. Among the four groups that received this diet, one received saline 0,9% and the others received metformin, vitamin E or simvastatin. After the study period, the animals were sacrificed and their blood was collected for biochemical analysis. The livers were removed for lipoperoxidation analysis and for the histological examinations. *Results* - The methionine and choline deficient diet was able to induce steatosis in 100% of the animals and nonalcoholic steatohepatitis in 27 (69.2%). The alanine aminotransferase levels were significantly higher in the simvastatin group. The aspartate aminotransferase levels were also higher in the simvastatin group, but were statistically significant only in relation to the standard diet group. When lipoperoxidation values were compared, the groups that received standard rat diet and methionine and choline deficient with vitamin E presented significantly lower rates than the others. The presence of fibrosis was significantly smaller in the group receiving vitamin E. *Conclusions* - The diet used was able to induce steatosis and nonalcoholic steatohepatitis. Besides vitamin E showed to reduce the liver oxidative stress, as well as the fibrosis development.

HEADINGS – Vitamin E. Fatty liver. Rats.

INTRODUCTION

Schaffner and Adler⁽³⁶⁾, in the late 70's, when studying obese individuals without a history of abusive alcohol consumption, observed liver histological findings similar to those found in alcohol-consuming patients or patients that underwent intestinal bypass. The continuity of such studies by Ludwig et al.⁽²²⁾, in 1980, led to the use of the term nonalcoholic steatohepatitis (NASH) to name this disease. Those authors called attention to its association with obesity, female gender and diabetes mellitus (DM), as well as to its evolutive potential. Later, other researchers⁽²⁾ showed that NASH can also occur in male and non-obese individuals.

The exact prevalence of NASH is still unknown, mainly due to its silent course in most of the patients^(6, 22, 28). In our environment, when 912 obese individuals without DM were prospectively evaluated, it was possible to determine a prevalence on the order of 3.18%⁽⁴⁶⁾. This prevalence, however, is underestimated, provided that only patients with elevated aminotransferases were evaluated.

The acknowledgement of its high prevalence and its evolutive potential^(1, 2, 4, 7, 8, 22, 33, 36, 37, 39, 43, 45) are the main reasons raising the scientific community's interest in it. However, until now, no treatment has showed conclusive results in relation to NASH^(9, 10, 30, 33, 40).

There are few studies testing drugs in human beings, in whom one of the biggest difficulties observed is the need to perform a second liver biopsy, provided that this is the only reliable manner to evaluate the drug's effect on NASH evolution. Thus, it becomes very relevant to test the therapeutic efficacy of drugs in animal models of NASH.

Among the several drugs that have already been tested, the hypoglycemic substances^(23, 27, 34) and the antioxidant agents^(12, 18) are currently those that have presented the most promising results.

This study aims at developing a model of NASH and at evaluating the role of the hypoglycemic metformin, the antioxidant vitamin E and the antihyperlipidemic simvastatin in the development of nonalcoholic fatty liver disease.

Research carried out in the Post-Graduation Program in Hepatology of the Fundação Faculdade Federal de Ciências Médicas de Porto Alegre, Porto Alegre, RS, Brazil. Correspondence: Dr. Idílio Zamin Jr. - Rua Armando Pereira Câmara, 111 - apt. 801 - 90470-070 - Porto Alegre, RS, Brazil. E-mail: izamin@terra.com.br

METHODS

Animals

The study used 50 male heterozygous rats, 45-day-old, from the Biotery of the Fundação Faculdade Federal de Ciências Médicas de Porto Alegre, RS, Brazil, weighing between 200 and 250 g, from the *Rattus norvegicus* species and Wistar lineage. Those rats were kept in polypropylene cages, in groups of five animals, under a 12 h-clear/dark cycle and under controlled temperature conditions.

Diet

The induction of NASH was carried out through a diet deficient in methionine and choline (MCD), handmade according to the Rogers and Newberne's model⁽³⁵⁾.

Drugs

The study used the commercial forms of the following drugs with their respective doses: a) simvastatin (0.5 mg/kg/day); b) vitamin E (10 IU/kg/day); c) metformin (35 mg/kg/day). The drugs were diluted immediately prior to their administration.

Experimental procedure

NASH induction was carried out through feeding the animals with a diet poor in methionine and in choline, ad libitum, for 3 months. The animals were divided, randomly, in five groups:

- **Group 1:** 10 rats receiving a standard diet (Nuvilab CR-1- Nuvital Nutrientes Ltda®) but no drug for 3 months.
- **Group 2:** 10 rats receiving an MCD diet concomitantly to the use of saline 0,9% 1 mL/kg, on a daily basis, administered by gavage, for 3 months.
- **Group 3:** 10 rats receiving an MCD diet concomitantly to the use of vitamin E 10 IU/kg, on a daily basis, administered by gavage, for 3 months.
- **Group 4:** 10 rats receiving a MCD diet concomitantly to the use of metformin 35 mg/kg, on a daily basis, administered by gavage, for 3 months.
- **Group 5:** 10 rats receiving a MCD diet concomitantly to the use of simvastatin 0.5 mg/kg, on a daily basis, administered by gavage for 3 months.

During the study period, the animals were weighed on a weekly basis and the drugs dose was readjusted as necessary.

On the first day of the study, besides determining the animals' weight, their blood was collected through retro-orbital plexus puncture for biochemical analysis: alanine-aminotransferase (ALT) and aspartate-aminotransferase (AST) (colorimetric test, using the Labtest kit). One day after concluding the induction period and the drugs administration (90 days), the animals were sacrificed by decapitation. Once more, each animal's blood was collected for biochemical analysis. Then, laparotomy with total hepatectomy and liver preparation were carried out for lipoperoxidation (LPO) and histological analysis.

Lipoperoxidation analysis

A liver tissue sample was destined to LPO through the thiobarbituric-acid reactant substance (TBARS) measurement according to the method described by Lowry et al.⁽²¹⁾; the results were expressed in nmol of malondialdehyde/mg of protein.

Histological analysis

The slides with liver fragments were dyed with hematoxylin-eosine and picrosirius, in order to evaluate the fibrosis level, and with Perls to evaluate the presence of iron stores, having been examined by an only pathologist blinded to the animals' data. The minimum histological criterion for NASH diagnosis was the presence of hepatocellular ballooning-related steatosis, involving zone 3 and lobular inflammatory infiltrate^(3,13). Mallory corpuscles and sinusoidal fibrosis, involving zone 3 might be present or not^(3,13).

The graduation of both necroinflammatory and fibrosis activity was carried out according to the classification proposed by Brunt et al.⁽³⁾.

Ethics Committee

This research project was submitted and approved by the Ethics Committee of Fundação Faculdade Federal de Ciências Médicas de Porto Alegre.

Statistic analysis

The averages and standard deviations of all quantitative and ordinal variables were calculated. The comparison was made through variance analysis with a classification criterion that, when applied on the posts, is equivalent to the Kruskal-Wallis' procedures. The localization of any differences among the groups was based on the Tukey's procedure, performed on the posts (when necessary). The dichotomic variables were compared through the Fisher's exact test. A *P*-value <0.05 was considered statistically significant for all analyses. Data were analyzed in the SPSS v12.0 software.

RESULTS

Among the 50 rats submitted to the study, 49 completed the 90-day diet and treatment. Only one rat died during the study period due to hemorrhage caused by a lesion during the gavage procedure for medication administration. This animal belonged to the metformin group.

Animals' weight

The animals' initial weight was similar among the groups, but the rats that received the MCD diet, regardless of the medication used, presented a significant weight loss at the end of 3 months with malnutrition signals. On the other hand, the group that received the standard diet presented weight gain (Table 1).

Aminotransferases

In relation to aminotransferases, all the animals presented normal AST and ALT levels in the first measurement carried out 1 day prior to treatment start. However, at the end of the

TABLE 1. Rats weight (grams) before and after intervention

| Group | Initial weight (g) | Final weight (g) | P |
|---------------|-----------------------------|---------------------------|--------|
| standard diet | 260,7 ± 24,9 ^b | 368.1 ± 32.9 ^b | <0.001 |
| saline 0,9% | 237.1 ± 11.4 ^a | 213.2 ± 25.3 ^a | 0.002 |
| vitamin E | 270.7 ± 18.6 ^{b,c} | 226.1 ± 18.3 ^a | <0.001 |
| metformin | 279.3 ± 18.2 ^a | 212.6 ± 29.1 ^a | <0.001 |
| simvastatin | 253.6 ± 21.4 ^{a,b} | 229.8 ± 31.4 ^a | 0.001 |
| P* | <0.001 | <0.001 | |

Data are presented as average ± standard deviation
Non-coincident index-letters within the variables "initial weight" or "final weight" represent statistically significant differences

study, the aminotransferases presented alterations in most of the animals submitted to the MCD diet, while those that received standard diet remained with normal aminotransferases. When the AST levels were analyzed among the groups, a statistically significant difference was observed between group 1 (standard diet) and the other groups (Figure 1). However, the ALT levels were significantly higher only in group 5 (simvastatin) when compared to group 1 (standard diet) (Figure 2). In the other groups, there was no significant difference.

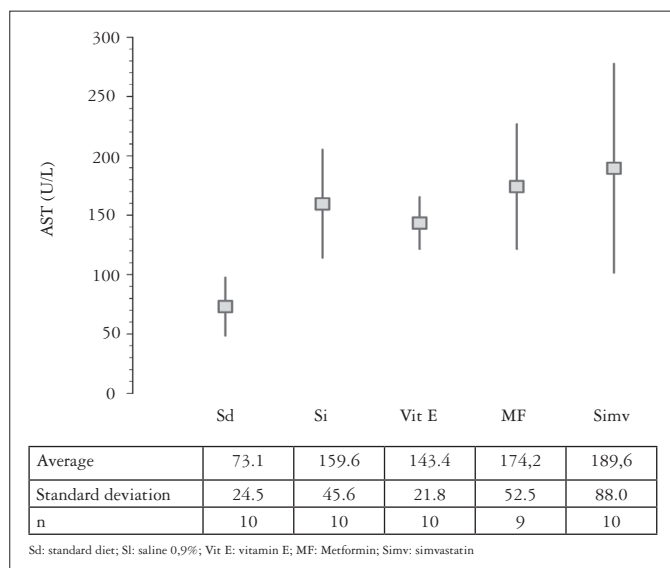


FIGURE 1. Comparison of the AST levels (U/L) among groups

Lipoperoxidation analysis

When comparing lipoperoxidation values, obtained through thiobarbituric-acid reactant substance measurement in liver samples, groups 1 (standard diet) and 3 (vitamin E) presented significantly lower values than the others (Figure 3).

Histology

In relation to the histological findings, none of the 10 rats that received standard diet presented histological alterations, and they were considered as having a normal liver.

All of the 39 rats that received the MCD diet presented at least some degree of macrovesicular steatosis, which always prevailed in relation to the microvesicular one. No difference

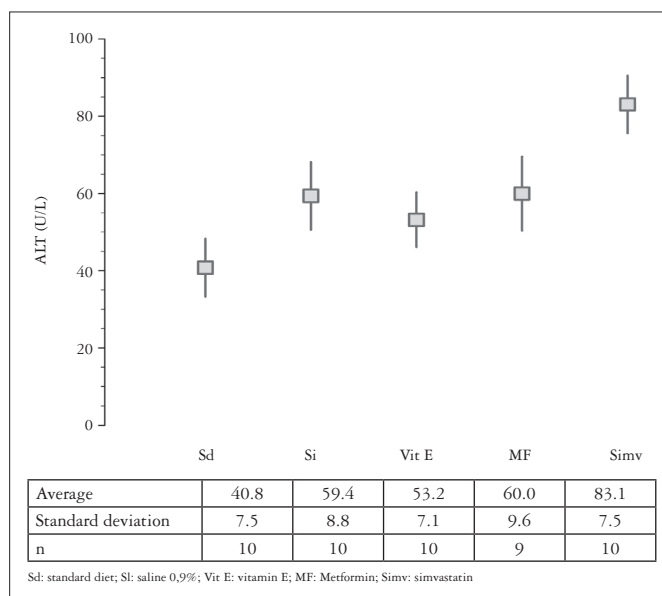


FIGURE 2. Comparison of the ALT levels (U/L) among groups

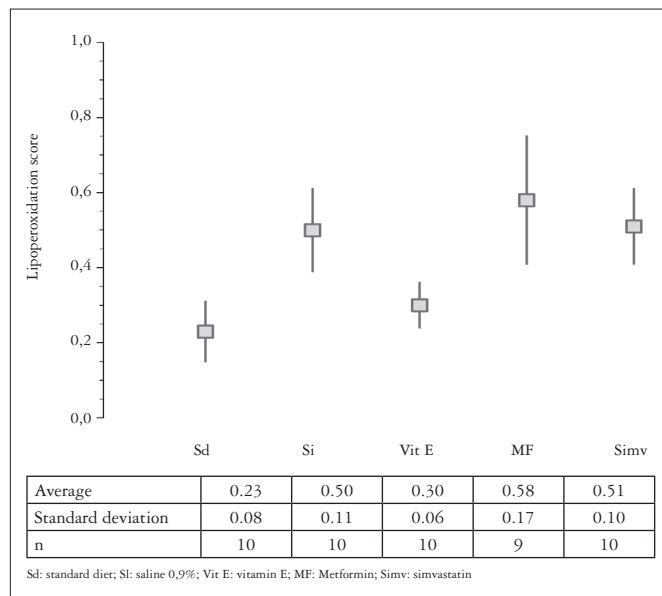


FIGURE 3. Comparison of the lipoperoxidation scores (nmol of malondialdehyde/mg of protein) among groups

in the steatosis degree was observed among the groups that used this diet. The presence of NASH was observed in 27 rats (69.2%), being diagnosed in the 10 rats that received simvastatin; however, in the group that received vitamin E, only 4 rats met NASH diagnostic criteria. It was diagnosed in 6 and 7 rats that received metformin and saline 0,9%, respectively. When NASH presence was compared among the groups, it was significantly more frequent in those that received simvastatin and similar among the other groups that received the MCD diet.

When comparing the inflammatory activity degree among the groups, it was significantly higher in those that received simvastatin, when compared to the groups that received vitamin E ($P = 0.003$) and metformin ($P = 0.009$). However, among the other groups, no significant difference was observed, although there was a tendency to be lower in the groups that received vitamin E and metformin, when compared to those that received saline 0,9% (Figure 4).

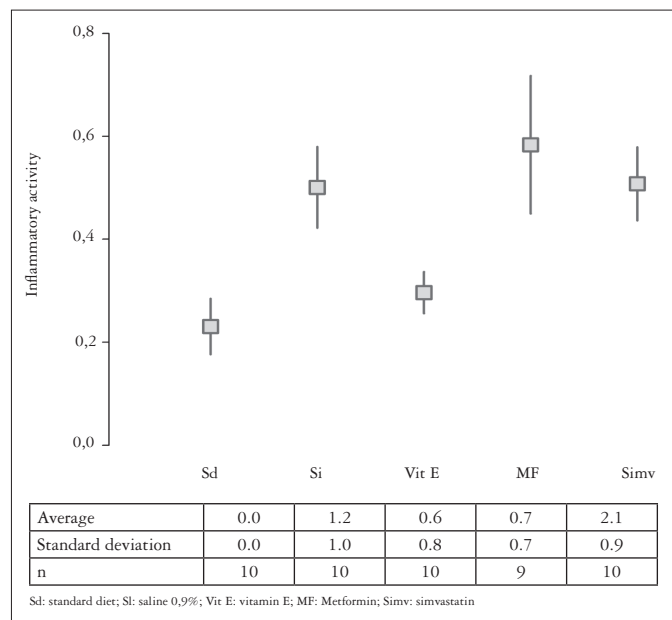


FIGURE 4. Comparison of the inflammatory activity scores among groups

Although it is absent in two cases, fibrosis was more frequent in the group that received simvastatin. In this group a rat presented cirrhosis. On the other hand, in the group that received vitamin E, only two rats presented fibrosis. When comparing the degree of fibrosis in the different groups, it was significantly higher in the group that received simvastatin ($P = 0.003$). However, among the other groups, there was no significant difference (Figure 5). When the comparison was made based exclusively on the presence or absence of fibrosis, it was significantly less present in the group that received vitamin E ($P < 0.05$).

In respect to other histological aspects, no iron stores were observed, and the presence of Mallory corpuscles occurred in only five cases, four of which belonged to the simvastatin group.

DISCUSSION

The use of animal models with NASH is very important in the study of this disease, because it may allow a better understanding of its pathogenesis, may help elucidating the mechanisms involved in the transition of steatosis to

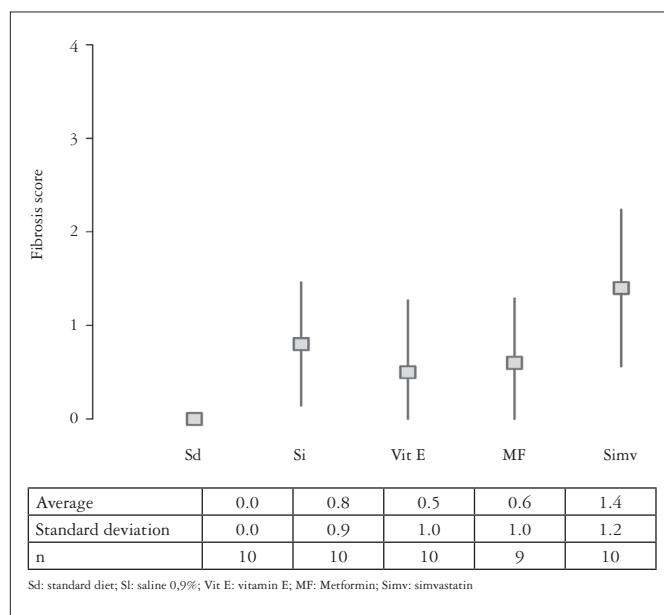


FIGURE 5. Comparison of the fibrosis scores among groups

NASH, as well as may test the result of several drugs in its treatment.

The NASH induction was carried out in this study through the MCD diet and, similarly to the findings of other authors^(11, 19, 29, 44), the animals that used this diet presented a significant weight loss after 90 days of treatment, with unequivocal signs of protein-calorie malnutrition.

In the evaluation of hepatocellular damage, aminotransferases alterations were observed in the animals that received the MCD diet. The animals that received simvastatin presented significantly higher ALT levels, while there was no difference among the other groups. Metformin and the vitamin E did not present any protective role. The AST levels were also higher in the simvastatin group, but the difference was significant only in relation to the standard diet group. In spite of the existence of only a few studies in literature, Lin et al.⁽²⁰⁾ when studying the metformin effect in genetically obese rats, observed significantly lower aminotransferases levels in the group that received the drug in relation to the control groups. We emphasize that the studies in patients with NASH also verified that this drug improves the aminotransferases levels^(5, 26, 38).

The group that used vitamin E presented the lowest average aminotransferases levels among the animals that used the MCD diet, but with no statistical significance. In human beings, Harrison and Neuschwander-Tetri⁽¹³⁾ did not observe a reduction in the aminotransferases level with vitamin E, while other authors^(14, 18, 42) did observe a significant reduction in this levels.

There are few studies in the literature that used statins to treat NASH. Kiyici et al.⁽¹⁶⁾ carried out a study evaluating atorvastatin in patients with NASH, and observed a significant reduction in the aminotransferases levels.

Among the animals studied, those that used vitamin E presented significantly less oxidative stress evidence than the other groups submitted to the MCD diet. The lipoperoxidation levels observed in this group were similar to the levels of the control group (standard diet). A trial carried out with rats⁽³²⁾ also verified that vitamin E reduces significantly the oxidative stress, provided that, in the control group, the authors observed a depletion in the liver glutathione stores, which did not occur in those that received vitamin E, leading to the conclusion that such vitamin has an important therapeutic role in animal NASH model.

In human beings, Kugelmas et al.⁽¹⁷⁾ studied a group of 16 patients with NASH, which were submitted to a weight-reduction diet and physical exercises and randomized to receive vitamin E or no therapy associated. The authors⁽¹⁷⁾ observed, after 12 weeks of treatment, a reduction in serum aminotransferases levels and interleukin 6, which is considered as a marker of oxidative stress and inflammatory response⁽²⁴⁾. However, there was no significant difference between the group that was submitted only to the diet and physical exercises and the group that received vitamin E.

In relation to liver lipoperoxidation, both the metformin and the simvastatin did not show any benefits, and the results of the TBARS were similar to the ones of the animals that used saline 0,9%.

In this study, the animals that received vitamin E presented the lowest incidence of NASH. Its diagnosis was performed in only 4 (40%) of the 10 rats, although NASH was diagnosed in 100% of the animals that received simvastatin, in 70% of the saline 0,9% group and 66% of those treated with metformin. When NASH presence was compared among the groups, it was significantly more frequent in those groups that received simvastatin and it was similar among the other groups that received the MCD diet, although it tended to be less frequent in the group that received vitamin E. It can be inferred that, with a bigger sample, it would probably be possible to verify the protective effect of vitamin E in the occurrence of NASH more accurately. No study with similar methodological design was found to compare the effect of such drugs in the prevention of NASH.

The inflammatory activity was significantly higher in those groups that received simvastatin and, although it tended to be lower in the groups that received vitamin E and metformin, when compared to those that received saline 0,9%, no significant difference was observed. These data contrast with those verified by Lin et al.⁽²⁰⁾, provided that they observed, in an animal model, a reduction in inflammatory activity using metformin. However, in patients

with NASH, Uygun et al.⁽⁴¹⁾ and Nair et al.⁽²⁶⁾ did not observe any improvement in necroinflammatory activity and steatosis using this drug. Nevertheless, Bugianesi et al.⁽⁵⁾, in a study of doubtful methodology, when comparing the effects of metformin and vitamin E in 17 patients that underwent a new liver biopsy after the treatment, observed that, in metformin group, the inflammatory activity and fibrosis decreased in 10 patients, remained unmodified in 6 cases, and only 1 patient presented an unfavorable evolution. From such data, they concluded that the metformin is superior to vitamin E in the treatment of NASH.

The fibrosis occurrence was also more frequent in those animals that received simvastatin, suggesting that it worsen the histological findings in NASH. This result contests those observed in two studies that used statins in patients with NASH and that carried out a histological control. Horlander et al.⁽¹⁵⁾ verified an improvement in steatosis and in the inflammatory activity, while Nair and Wiseman⁽²⁵⁾ did not observe any histological difference in relation to the control group. In the present study, metformin did not present any benefit, when compared to the saline 0,9% in reducing fibrosis. In the study by Lin et al.⁽²⁰⁾, the authors did not analyze fibrosis. In human beings, Uygun et al.⁽⁴¹⁾ and Nair et al.⁽²⁶⁾ did not observe any difference in relation to the fibrosis degree with the use of metformin, while Bugianesi et al.⁽⁵⁾ observed that the fibrosis decrease in 10 of the 17 patients that underwent a new liver biopsy after using metformin.

The animals that received vitamin E were the ones that presented the lowest degree of fibrosis, which was present in only two (20%) rats. Among the four groups that received the MCD diet, such difference was statistically significant only in relation to the simvastatin group. However, in the group that used vitamin E fibrosis was less frequent than in the others that received the MCD diet, suggesting a protective role in the fibrosis development. Phung et al.⁽³²⁾, in an animal model of NASH induced by an MCD diet, observed the occurrence of a statistically significant lower fibrosis degree, in the animals that received vitamin E when compared to the control group. In humans, Harrison et al.⁽¹²⁾ randomized 45 patients with NASH to receive vitamins E and C or placebo and verified a reduction in the fibrosis degree in the group treated. Other studies also verified that vitamin E has a therapeutic effect on NASH, mainly in the prevention of fibrosis^(14, 31).

From this study, it can be concluded that in an animal model of NASH, vitamin E presented a protective effect. On the other hand, simvastatin caused the worsening of the histological parameters, which suggests a reflection about its use in patients with NASH and dislipidemia.

Zamin Jr. I, Mattos AA, Mattos AZ, Coral G, Santos D, Rhoden C. A vitamina E reduz a lipoperoxidação hepática e a fibrose em modelo experimental de esteatohepatite não-alcoólica. *Arq Gastroenterol.* 2010;47(1):86-92.

RESUMO – Contexto - Ainda não há um tratamento comprovadamente eficaz para a esteatohepatite não-alcoólica. **Objetivo** - Desenvolver um modelo experimental de esteatohepatite não-alcoólica induzida por dieta deficiente em metionina e colina, bem como avaliar o papel do metformina, da vitamina E e da sinvastatina na evolução da esteatohepatite não-alcoólica. **Métodos** - Foram estudados prospectivamente 50 ratos da linhagem Wistar, por um período de 90 dias, sendo os mesmos divididos em cinco grupos de 10 ratos. Um grupo recebeu ração convencional e os demais a dieta deficiente em metionina e colina. Dentre os quatro grupos que receberam a dieta, para um foi administrado soro fisiológico e para os demais o metformina, a vitamina E e a sinvastatina. Após o período de estudo os animais foram mortos, sendo colhido sangue para análise bioquímica e removido o fígado para análise da lipoperoxidação através do teste de substâncias reativas ao ácido tiobarbitúrico e para a realização dos exames histológicos. **Resultados** - A dieta deficiente em metionina e colina foi capaz de induzir esteatose em 100% dos animais enquanto que esteatohepatite não-alcoólica foi diagnosticada em 27 (69,2%). Os níveis da ALT foram significativamente maiores no grupo da sinvastatina. Os níveis de AST também foram maiores no grupo da sinvastatina, mas apenas foram estatisticamente significantes em relação ao grupo da ração. Quando se compararam os valores de lipoperoxidação, os grupos da ração convencional e da vitamina E apresentaram índices significativamente menores que os demais. A presença de fibrose foi significativamente menor no grupo que recebeu a vitamina E. **Conclusões** – A dieta utilizada foi capaz de induzir esteatose e esteatohepatite não-alcoólica, sendo que a vitamina E demonstrou reduzir o estresse oxidativo hepático, bem como o desenvolvimento de fibrose.

DESCRITORES - Vitamina E. Fígado gorduroso. Ratos.

REFERENCES

1. Angulo P. Nonalcoholic fatty liver disease [medical progress]. *N Engl J Med.* 2002;346:1221-31.
2. Bacon BR, Farahvash MJ, Janney CG, Neuschwander-Tetri BA. Nonalcoholic steatohepatitis: an expanded clinical entity. *Gastroenterology.* 1994;107:1103-9.
3. Brunt EM, Janney CG, Di Bisceglie AM, Neuschwander-Tetri BA, Bacon BR. Nonalcoholic steatohepatitis: a proposal for grading and staging the histological lesions. *Am J Gastroenterol.* 1999;94:2467-74.
4. Bugianesi E, Leone N, Vanni E, Marchesini G, Brunello F, Carucci P, Musso A, De Paolis P, Capussotti L, Salizzoni M, Rizzetto M. Expanding the natural history of nonalcoholic steatohepatitis: from cryptogenic cirrhosis to hepatocellular carcinoma. *Gastroenterology.* 2002;123:134-40.
5. Bugianesi E, Gentilcore E, Manini R, Natale S, Vanni E, Villanova N, David E, Rizzetto M, Marchesini G. A randomized controlled trial of metformin versus vitamin E or prescriptive diet in nonalcoholic fatty liver disease. *Am J Gastroenterol.* 2005;100:1082-90.
6. Byron D, Minuk G. Clinical hepatology: profile of an urban, hospital-based practice. *Hepatology.* 1996;24:813-5.
7. Caldwell SH, Oelsner DH, Iezzoni JC. Cryptogenic cirrhosis: clinical characterization and risk factors for underlying disease. *Hepatology.* 1999;29:664-9.
8. Diehl AM, Goodman Z, Ishak KG. Alcohol-like liver disease in nonalcoholics. A clinical and histological comparison with alcohol-induced liver injury. *Gastroenterology.* 1988;95:1056-62.
9. Dixon JB, Bhathal PS, Hughes NR, O'Brien PE. Nonalcoholic fatty liver disease: improvement in liver histological analysis with weight loss. *Hepatology.* 2004;39:1647-54.
10. Eriksson S, Eriksson KF, Bondesson L. Nonalcoholic steatohepatitis in obesity: a reversible condition. *Acta Med Scand.* 1986;220:83-8.
11. Grattagliano I, Vendemiale G, Caraceni P, Domenicali M, Nardo B, Cavallari A, Trevisani F, Bernardi M, Altomare E. Starvation impairs antioxidant defense in fatty livers of rats fed a choline-deficient diet. *J Nutr.* 2000;130:2131-6.
12. Harrison SA, Torgerson S, Hayashi P, Ward J, Schenker S. Vitamin E and vitamin C treatment improves fibrosis in patients with nonalcoholic steatohepatitis. *Am J Gastroenterol.* 2003;98:2485-90.
13. Harrison SA, Neuschwander-Tetri BA. Nonalcoholic fatty liver disease and nonalcoholic steatohepatitis. *Clin Liver Dis.* 2004;8:861-79.
14. Hasegawa T, Yoneda M, Nakamura K, Makino I, Terano A. Plasma transforming growth factor β 1 level and efficacy of α -tocopherol in patients with non-alcoholic steatohepatitis: a pilot study. *Aliment Pharmacol Ther.* 2001;15:1667-72.
15. Horlander JC, Kwo PY, Cummings OW, Koukoulis G. Atorvastatin for the treatment of NASH. *Gastroenterology.* 2001;120:A544.
16. Kiyici M, Gulten M, Gurel S, Nak SG, Dolar E, Savci G, Adim SB, Yerci O, Memik F. Ursodeoxycholic acid and atorvastatin in the treatment of nonalcoholic steatohepatitis. *Can J Gastroenterol.* 2003;17:713-8.
17. Kugelmas M, Hill DB, Vivian B, Marsano L, McClain CJ. Cytokines and a pilot study of the effects of lifestyle modification and vitamin E. *Hepatology.* 2003;38:413-9.
18. Lavine JE. Vitamin E treatment of nonalcoholic steatohepatitis in children: a pilot study. *J Pediatr.* 2000;136:734-8.
19. Leclercq IA, Farrell GC, Field J, Bell DR, Gonzalez FJ, Robertson GR. CYP2E1 and CYP4A as microsomal catalysts of lipid peroxides in murine nonalcoholic steatohepatitis. *J Clin Invest.* 2000;105:1067-75.
20. Lin HZ, Yang SQ, Chuckaree C, Kuhajda F, Ronnet G, Diehl AM. Metformin reverses fatty liver disease in obese, leptin-deficient mice. *Nat Med.* 2000;6:998-1003.
21. Lowry OH, Rosebrough NJ, Farr AL, Randall RJ. Protein measurement with the folin phenol reagent. *J Biol Chem.* 1951;193:265-75.
22. Ludwig J, Viggiano TR, McGill DB, Oh BJ. Nonalcoholic steatohepatitis. Mayo Clinic experiences with a hitherto unnamed disease. *Mayo Clin Proc.* 1980;55:434-8.
23. Marchesini G, Brizi M, Bianchi G, Tomassetti S, Zoli M, Melchionda N. Metformin in non-alcoholic steatohepatitis. *Lancet.* 2001;358:893-4.
24. McClain CJ, Barve S, Deaciuc I, Kugelmas M, Hill D. Cytokines in alcoholic liver disease. *Semin Liver Dis.* 1999;19:205-19.
25. Nair S, Wiseman M. HMG-CoA reductase inhibitors in non alcoholic fatty liver disease: is their potential hepatotoxicity an issue in these patients? A case control study based on histology. *Hepatology.* 2002;36:A409.
26. Nair S, Diehl AM, Wiseman M, Farr GH Jr, Perrillo RP. Metformin in the treatment of non-alcoholic steatohepatitis: a pilot open label trial. *Aliment Pharmacol Ther.* 2004;20:23-8.
27. Neuschwander-Tetri BA, Brunt EM, Wehmeier KR, Oliver D, Bacon BR. Improved nonalcoholic steatohepatitis after 48 weeks of treatment with the PPAR- γ ligand rosiglitazone. *Hepatology.* 2003;38:1008-17.
28. Nonomura A, Mizukami Y, Unoura M, Kobayashi K, Takeda Y, Takeda R. Clinicopathologic study of alcohol-like liver disease in non-alcoholics; non-alcoholic steatohepatitis and fibrosis. *Gastroenterol Jpn.* 1992;27:521-8.
29. Okan A, Astarcioglu H, Tankurt E, Sagol O, Altekin E, Astarcioglu I, Gonen O. Effect of ursodeoxycholic acid on hepatic steatosis in rats. *Dig Dis Sci.* 2002;47:2389-97.
30. Palmer M, Schaffner F. Effect of weight reduction on hepatic abnormalities in overweight patients. *Gastroenterology.* 1990;99:1408-13.
31. Parola M, Muraca R, Dianzani I, Barrera G, Leonarduzzi G, Bendinelli P, Piccoletti R, Poli G. Vitamin E dietary supplementation inhibits transforming growth factor β 1 gene expression in the rat liver. *FEBS.* 1992;308:267-70.
32. Phung N, Farrell G, Robertson G, George J, Westmead Millennium Inst at Westmead Hosp, Univ of Sydney, Sydney Australia. Vitamin E but not glutathione precursors inhibits hepatic fibrosis in experimental NASH exhibiting oxidative stress and mitochondrial abnormalities. *Hepatology.* 2001;34:A361.
33. Powell EE, Cooksley WG, Hanson R, Searle J, Halliday JW, Powell LW. The natural history of nonalcoholic steatohepatitis: a follow-up study of forty-two patients for up to 21 years. *Hepatology.* 1990;11:74-80.

34. Promrat K, Lutchman G, Uwaifo GI, Freedman RJ, Soza A, Heller T, Doo E, Ghany M, Premkumar A, Park Y, Liang TJ, Yanovski JA, Kleiner DE, Hoofnagle JH. A pilot study of pioglitazone treatment for nonalcoholic steatohepatitis. *Hepatology*. 2004;39:188-96.
35. Rogers AE, Newberne PM. Alcoholic and nutritional fatty liver and cirrhosis. *Am J Pathol*. 1973;73:817-20.
36. Schaffner F, Adler M. Fatty liver hepatitis and cirrhosis in obese patients. *Am J Med*. 1979;67:811-6.
37. Schaffner F, Thaler H. Nonalcoholic fatty liver disease. *Prog Liver Dis*. 1986;8:283-8.
38. Schwimmer JB, Middleton MS, Deutsch R, Lavine JE. A phase 2 clinical trial of metformin as a treatment for non-diabetic pediatric non-alcoholic steatohepatitis. *Aliment Pharmacol Ther*. 2005;21:871-9.
39. Teli MR, James OF, Burt AD, Bennett MK, Day CP. The natural history of nonalcoholic fatty liver: a follow-up study. *Hepatology*. 1995;22:1714-9.
40. Ueno T, Sugawara H, Sujako K. Therapeutic effects of restricted diet and exercise in obese patients with fatty liver. *J Hepatol*. 1997;27:103-7.
41. Uygun A, Kadayifci A, Isik AT, Ozgurtas T, Deveci S, Tuzun A, Yesilova Z, Gulsen M, Dagalp K. Metformin in the treatment of patients with non-alcoholic steatohepatitis. *Aliment Pharmacol Ther*. 2004;19:537-44.
42. Vajro P, Mandato C, Franzese A, Ciccimarra E, Lucariello S, Savoia M, Capuano G, Migliaro F. Vitamin E treatment in pediatric obesity-related liver disease: a randomized study. *J Pediatr Gastroenterol Nutr*. 2004;38:48-55.
43. Wanless IR, Lentz JS. Fatty liver hepatitis (steatohepatitis) and obesity: an autopsy study with analysis of risk factors. *Hepatology*. 1990;12:1106-10.
44. Weltman MD, Farrell GC, Liddle C. Increased hepatocyte CYP2E1 expression in a rat nutritional model of hepatic steatosis with inflammation. *Gastroenterology*. 1996;111:1645-53.
45. Younossi Z, Diehl AM, Ong JP. Nonalcoholic fatty liver disease: an agenda for clinical research. *Hepatology*. 2002;35:746-52.
46. Zamin IJ, Mattos AA, Zettler CG. Non-alcoholic steatohepatitis in nondiabetic obese patients. *Can J Gastroenterol*. 2002;16:303-8.

Received 26/8/2008.
Accepted 28/5/2009.