

LATERAL LARYNGOPHARYNGEAL DIVERTICULA: a videofluoroscopic study of laryngopharyngeal wall in wind instrumentalists

Milton Melciades Barbosa **COSTA** and Fátima Lago **ALVITE**

ABSTRACT – *Context* - This paper analyze healthy musicians who play wind instruments. *Objective* - To identify possible diverticular formations on the laryngopharyngeal wall produced by pharyngeal overpressure during the use of these instruments. *Methods* - Through a videofluoroscopic method, 22 professional musicians had their pharynx analyzed in frontal face and profile, by swallowing 20 mL of barium sulfate solution and blowing against resistance. *Results* - All the volunteers showed lateral laryngopharyngeal diverticula (3 unilateral and 19 bilateral) with areas ranging from 0.7 to 6 cm². Trumpet and clarinet players showed larger diverticula, on both the right and left sides. Any important complaints were noted spontaneously or after questions. In the barium-swallow analyses, the 41 diverticula previously identified in the blowing tests were not seen or appeared to be smaller, because of the free flux passage from the pharynx to the esophagus. Despite the existence of the other, less resistant areas on the laryngopharyngeal segment, no other protrusions could be found in this group of wind instrumentalists. *Conclusions* - The lateral laryngopharyngeal diverticula that occur in blow instrumentalists is distinct of diverticula produced by laryngopharyngeal overpressure determined by abnormally high resistance to flux passage from pharynx to esophagus. In musicians is the persistent and continuous pharyngeal overpressure induced by the resistance of the instrument's mouthpiece will strongly distend the anatomically less resistant areas of the pharynx, producing a large protrusion. Laryngopharyngeal overpressure without abnormal resistance to flux passage explain the way blow instrumentalists protrusions did not appear as full sacs in a barium-swallow test, despite their larger dimensions. As final conclusion the musician-acquired diverticula must be considered as an "occupational overuse syndrome".

HEADINGS – Zenker diverticulum. Fluoroscopy. Occupational disorders. Cumulative trauma disorders. Music.

INTRODUCTION

Following the vertical axis from above to below, there are three anatomically less resistant areas in the laryngopharyngeal segment, where the diverticular formations may be found. The uppermost area is bilaterally less resistant, where the foramen allowing passage of the internal branch of the inferior laryngeal nerve is located. The next area is located on the posterior surface of the laryngopharyngeal wall, between the oblique and transverse fascicle of the cricopharyngeal muscle. This area, first described by Killian, is the site where the posterior laryngopharyngeal diverticula can be found (Zenker's diverticula). The last is located on the anterior insertion of the cricopharyngeal muscle over the cricoid cartilage, there is a lateral depression on each side, where the rarer Killian-Jamiesen laryngopharyngeal diverticula may occur^(10, 12, 13, 19, 29).

The characteristics, consequences and ease of

imaging of Zenker's diverticula leads us to believe that they are the commonest type of pharyngeal diverticula⁽¹⁷⁾. They are considered to be 4 times more frequent than Killian-Jamiesen diverticula⁽¹⁹⁾. However, the lateral laryngopharyngeal protrusions are at least 9 times more frequent than the Zenker type⁽⁶⁾.

Lateral laryngopharyngeal diverticula are small pathological sacs that appear as "ears", projecting at the level of the vallecula, and are usually bilateral. These diverticula are more frequent in older people, and show no difference in prevalence with respect to the sex of the person, the side of the pharynx, or in volume. The protrusions are found in the anatomically less resistant area in the upper portion of the pyriform recess, and are usually produced by pharyngeal overpressure related to difficulty in swallowing. This less resistant area is the region of the thyrohyoid membrane, where the internal branch of the superior laryngeal nerve passes to the laryngopharyngeal submucous membrane⁽⁶⁾.

This study was performed at the Laboratory of Digestive Motility and Videofluoroscopy of Biomedical Science Institute of the Federal University of Rio de Janeiro, Brazil. Correspondence: Dr. Milton M. B. Costa - Laboratório de Motilidade Digestiva e Imagem - Bloco F1 - Sala 8, Instituto de Ciências Biomédicas, Universidade Federal do Rio de Janeiro - 21941-590 - Rio de Janeiro, Brazil. E-mail: mcosta@acd.ufrj.br

Lateral laryngopharyngeal diverticula have been variously considered to be rare^(17, 23, 31) or common^(10, 20); as a pathological entity^(1, 10, 11, 22, 25, 27, 28); and also as a variation of the normal morphology⁽²⁾. They have been described as a pouch or bulge with a narrow or wide neck⁽¹⁰⁾, and also as true⁽¹⁰⁾ and as false diverticula⁽⁶⁾. They have been termed a well-known entity^(2, 10), or also as a subject that remains open to new research⁽⁶⁾.

A lateral laryngopharyngeal diverticulum is formed by the pharyngeal internal layers passing through a hole developed in the thyrohyoid membrane, via a mechanism similar to that observed in the protrusions that occur in the lower alimentary tract^(4, 6, 8).

The anatomically less resistant laryngopharyngeal areas are adequate to sustain the physiological pressure of swallowing and phonation. Nevertheless, when subjected to continuous and atypical overpressure regimens, they can be a site of out-pouching. Physiologically, during swallowing, the pressure in the pharynx will find the pharyngoesophageal transition open, allowing passage for food under pressure to the esophagus, and protecting the less resistant areas on the laryngopharynx wall. In a group of human subjects with 33 diagnosed lateral laryngopharyngeal diverticula, only 4 subjects showed no degree of dysphagia to impede the pharyngeal clearance⁽⁶⁾.

Usually a lateral laryngopharyngeal diverticulum is a small protrusion^(6, 10). Larger lateral diverticula are normally described as case reports, especially in players of wind instruments. The constant overpressure on the pharynx is considered to be the main factor responsible for the development of these diverticula^(12, 15, 26).

The aims of this study were to identify, in a group of long-time wind instrumentalists, who are considered healthy individuals, possible morphological injury to the pharyngeal wall, related to the continuous use of their instruments.

METHODS

This study was carried out in full agreement with the ethical guidelines proposed by the World Medical Association (WMA Helsinki Declaration, Finland, 1995, supplemented by the 52nd WMA General Assembly, Edinburgh, United Kingdom, 2000, with amendments in Washington, 2002 and Tokyo, 2004). The protocol was previously approved by the Ethics Committee for Scientific Investigation of the Federal University of Rio de Janeiro, RJ, Brazil (CEP - No. 240/07) in agreement with Resolution 196/96 of the Brazilian Ministry of Health. All volunteers gave their informed consent to participate.

The pharynxes of 22 healthy male volunteers (who presented no spontaneous complaints), professional wind instrumentalists, with ages between 27 and 56 years (mean 35 years) were evaluated by a videofluoroscopic method, on the left lateral and antero-posterior planes.

Before the videofluoroscopic examination, all the volunteers were questioned about their general health and specifically about hoarseness, raucousness, dysphonia, phonatory

weariness, cervical pain, difficulty in swallowing (dysphagia), choking, or pain in association with deglutition (odinophagia). All of them were requested to report any other complaints.

The musicians were seated on a special chair, to enable them to change their position with respect to the x-ray emission tube, thus varying the radiological incidence without having to physically move their bodies. A calibration system allowed the quantification of dimensional variations in the object, by means of the metric scale attached to the chair. The calibration grid pattern (with known measurements) is registered in an analogous frontal plane to the plane occupied by the study object⁽⁷⁾. All the measurements were made from frontal images (antero-posterior incidence).

All the musicians were submitted to a videofluoroscopic study for morphological and functional analysis of the pharyngeal dynamics during swallowing of 20 mL of contrast medium (barium sulfate solution diluted 50% with distilled water). Each volunteer was observed with at least three distinct gulps in each swallow test. After the contrast-medium series, the musicians were instructed to blow against two fingers, seeking to produce an equal or larger resistance to that necessary to use their own instruments. The blowing against resistance was also performed in each videofluoroscopic incidence, with intermittent effort and rest.

The videofluoroscopic examinations were carried out with a Philips BV 22 C-arm (Philips; The Netherlands) with a 100 kV, 20 mA, Philips LR24424 intensifier (Philips; The Netherlands). The television system is black and white, based on the NTSC standard, comprising a black and white 20" Philips monitor and a black and white CCD Sony Mythos B/W (Sony; USA) camera (0.1 lux; $f = 3.6$ mm; 400-line resolution) coupled with the image intensifier.

The images generated by the radiological equipment are captured from a video output (BNC) of the black and white monitor, and are recorded simultaneously on an analog VHS Panasonic NV-MV 40 video recorder (Panasonic; Brazil) and on a digital Philips DVD recorder model DVDR 3455H (Philips; USA), with the image control being displayed on the Panasonic CT-1383VY 13" color monitor screen (Panasonic; Mexico).

All protrusions identified were measured in the antero-posterior plane, using institutional software able to measure areas based on a previous calibration (Videomed Version 1-16.9.2002-alpha)⁽⁵⁾. Each area was measured at least twice. Each result is the mean of the measured areas. The statistical analysis used the Mann-Whitney test with a significance level of $P < 0.05$ (GraphPad Prism version 5.00, Graphpad software, 2003, La Jolla, California, USA).

RESULTS

All volunteers were observed under left lateral and antero-posterior incidences. The left lateral profile does not contribute to the diverticula analyses, but shows the large pharyngeal distension against the closed pharyngoesophageal transition. All the diverticula characteristics and measurements were examined by frontal (antero-posterior) incidence (Table 1).

TABLE 1. Volunteers grouped by wind instrument frequencies

Ident.	Age	Instrument	Years of use	Hours per day	Complaint	Side and area (cm ²)			
						Barium solution		air	
						Left	right	left	right
RXSS	28	trumpet	09	06	no	0.1	0.4	1.7	2.2
GNF	36	trumpet	27	06	no	0.0	0.3	2.7	6.0
MAPF	32	trumpet	10	02	no	0.4	0.3	1.3	2.3
CMM	33	trumpet	11	04	no	0.6	0.6	3.4	5.0
CASJ	29	trumpet	17	05	no	0.0	0.0	1.4	4.0
HLF	36	trumpet	20	05	no	0.0	0.0	3.0	2.7
M1	32.3		15.66	4.6		0.18	0.27	2.25	3.7
ARG	53	saxophone	30	03	no	0.2	0.0	0.9	0.7
CZ	27	saxophone	12	06	no	1.4	0.3	2.0	1.7
RP	40	saxophone	25	06	no	0.3	0.0	0.9	0.0
RMF	30	saxophone	3	04	no	1.1	0.0	2.6	1.6
WRB	37	saxophone	08	02	no	0.0	0.3	0.0	0.7
M2	37.4		15.6	4.2		0.6	0.12	1.28	0.94
CAC	34	clarinet	22	03	no	0.0	1.0	1.3	2.0
ASS	31	clarinet	13	06	no	0.0	3.4	3.5	6.0
FO	36	clarinet	17	06	no	0.2	0.5	2.5	3.2
FAF	35	clarinet	19	04	no	0.4	0.2	0.8	1.5
JLSO	40	clarinet	28	05	no	0.1	0.4	0.9	2.5
M3	35.2		19.8	4.8		0.14	1.1	1.8	3.04
MSN	32	flute	20	04	no	0,0	0,0	1,5	0,0
ERS	34	flute	25	04	no	0,3	0,7	0,9	1,1
M4	33		22.5	04		0,15	0,35	1,2	0,55
LF	46	oboe	28	04	no	0.4	0.3	3.4	1,4
LPS	38	saxhorn	21	04	no	0.0	0.0	2.5	3.1
MZ	40	bassoon	22	03	no	0.0	0.0	1.5	2.6
RGC	34	trombone	15	03	no	0.4	0.4	1.4	0.8
M5	39.5		21.5	3.5		0.25	0.41	2.2	1.97
MF	35.4		19	4.2		0.3	0.5	1.75	2.0

M= Mean, MF= Final Mean. The table presents the measurements of areas (cm²) of the lateral pharyngeal protrusion, obtained by a videofluoroscopic study using a barium solution and air as the contrast media

All 22 musicians are professionals, who have played their wind instruments for a mean period of 19 years (from 3 to 30 years). They reported playing their instruments from 2 to 6 h per day, for a mean of 4.2 h. Trumpet (6), saxophone (5), and clarinet (5) were the most frequent instruments played by the volunteers. Other, less frequently played instruments were the flute, oboe, saxhorn, bassoon, and trombone. All the musicians blew against two closed fingers apposed on the lips, which allowed us to identify, in all of them (100%), a unilateral (3 volunteers) or bilateral (19 volunteers) air protrusion; these protrusions varied in size from 0.7 to 6 cm².

The dimensions of the diverticula observed with air as the contrast medium varied with respect to the size and side, and showed no relationship to the length of time that the musician had used the instrument. Eight diverticula showed areas from 0.7 to 0.9 cm² (5 on the left side and 3 on the right); 12 showed areas between 1 and 1.9 cm² (6 on the right side and 6 on the left); and of 15 musicians with bilateral diverticula, 21 ranged from 2 cm² to 6 cm² (6 on both sides, 6 on the right, and 3 on the left). There was no correlation between the length of time that the musician had played the instrument

and the area of the diverticula. Also, neither side showed a statistically significant prevalence (Figure 1).

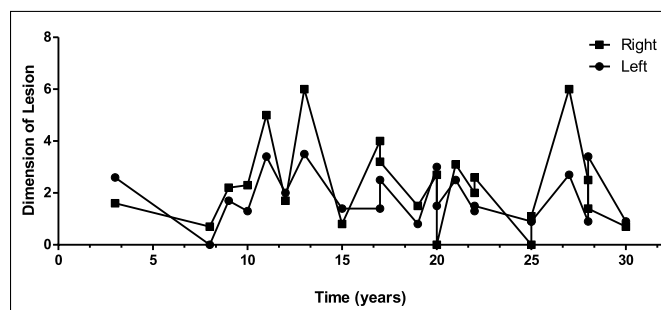


FIGURE 1. Correlation between dimensions of diverticula and length of use of wind instruments in the 22 musician subjects. Dimensions of diverticula on the right and left laryngopharyngeal sides, with the length of time that the 22 musicians had played their instruments. There was no correlation between the length of playing time and the dimensions of the right and left diverticula. Based on the values distribution; the anatomically less resistant areas on the right and left sides of the laryngopharynx showed the same degree ($P = 0.4956$) of weakness under the overload pressure

The trumpet and clarinet players showed the largest mean areas on the right and left sides (trumpet right side 3.7 cm² and left side 2.25 cm²; clarinet right side 3.04 cm² and left side 1.8 cm²).

The three groups of trumpet, clarinet, and saxophone players were large enough to allow statistical analysis. The trumpet and clarinet produced the same level of injury on the left ($P = 0.4633$) and on the right side ($P = 0.4642$). The trumpet and clarinet produced more overload than the saxophone, with statistical significance on the right side of the pharyngeal wall (trumpet x saxophone $P = 0.0043$, clarinet x saxophone $P = 0.0317$), and without statistical significance on the left side (trumpet x saxophone $P = 0.2222$, clarinet x saxophone $P = 0.6723$). There were no statistical differences in the lateral laryngopharyngeal right and left side resistance to overpressure imposed by the trumpet ($P = 0.0996$), clarinet ($P = 0.2492$) or saxophone ($P = 0.4620$).

In the barium-swallow observation, five volunteers did not show their laryngopharyngeal diverticula (four of them had been identified with the air test as bilateral). In seven other volunteers, unilateral protrusions were identified (five of them showed bilateral diverticula with the air test). Bilateral diverticula were identified in 10 of the 19 subjects identified with air distension. All the 27 protrusions identified with barium were under-scaled. Twenty of them with dimensions less than 0.5 cm² were only identified after air identification in frame-by-frame analyses. Six, also under-scaled, ranged from 0.6 cm² to 1.4 cm². One volunteer, a clarinet player, showed a unilateral right-side diverticulum with the barium solution (3.4 cm²). However, with air distension this right diverticulum measured 6.00 cm² and the left side showed a diverticulum with a diameter of 3.5 cm². The other 14 air-identified diverticula were not seen by the barium study (Figures 2, 3 and 4).

The volunteers did not present any spontaneous complaints. Specific questions about hoarseness, raucousness, dysphonia, phonatory weariness, cervical pain, difficulty in swallowing (dysphagia), choking, or pain in association with deglutition (odinophagia) received negative responses, and also none of these symptoms were observed. Nevertheless, cervical lateral pressure, during instrument use, was admitted

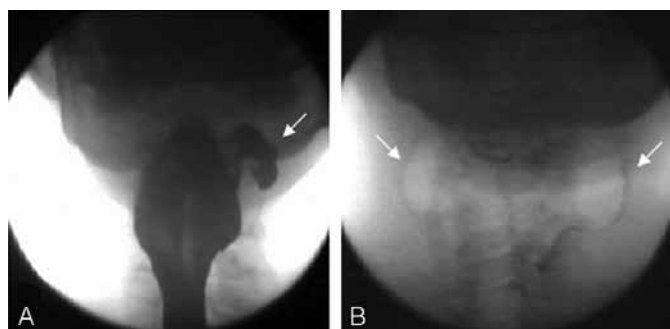


FIGURE 2. (A) Frame from a barium solution swallow, showing a large unilateral diverticulum (arrow) and (B) the same volunteer, a clarinet player, blows against resistance, showing large bilateral laryngopharyngeal diverticula (arrow)

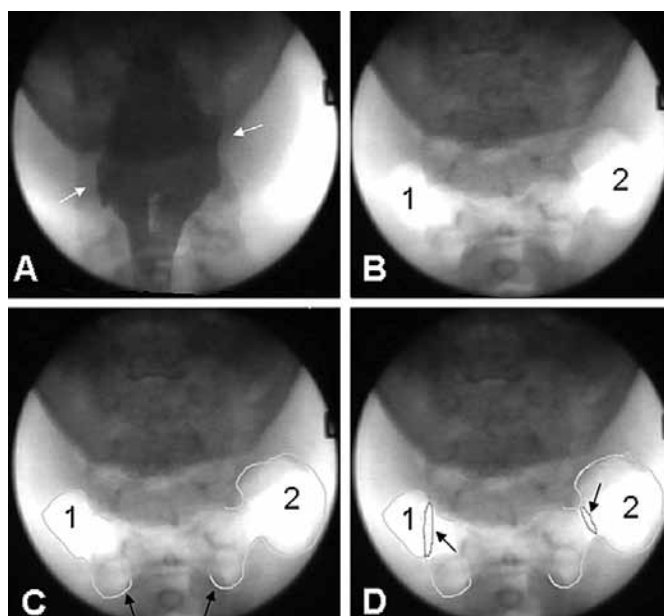


FIGURE 3. From a barium solution swallow: frame (A) shows the lateral contour of the laryngopharynx with a discrete irregularity, probably not appreciated because there is no residual volume of contrast after the swallow. (B, C and D) show a sequence, obtained by blowing against resistance, by the same trumpet player shown in (A). These images show large diverticula on both sides, where the left diverticulum (1) is smaller than the right (2). In frames (C and D), for didactical interest, we artificially accentuated the lateral and inferior contour of the laryngopharynx to show the total air pharyngeal distension accentuating the pyriform recess (indicated by arrows in C). In (D) we estimated with a circle (arrow) the projection of the limit between the diverticula on both sides and the laryngopharynx

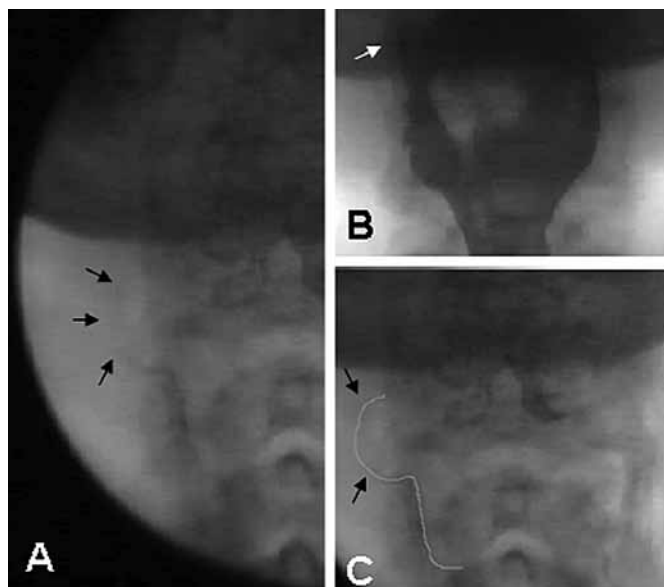


FIGURE 4. (A), a small left unilateral diverticulum (arrows) from a saxophone player, evidenced by blowing against resistance. (B) with a barium-solution swallow, a discrete mark on the left lateral side of the pharynx, corresponding to the location of the diverticulum, which was only identified by the previous air distension. (C) the same frame as (A) with the lateral and inferior contours accentuated artificially; the arrows indicate the lateral laryngopharyngeal diverticulum

as “normal” discrete discomfort. This was admitted especially by the three volunteers in whom intermittent protrusions were seen at the cervical external surface in association with blowing against resistance (Figure 5).

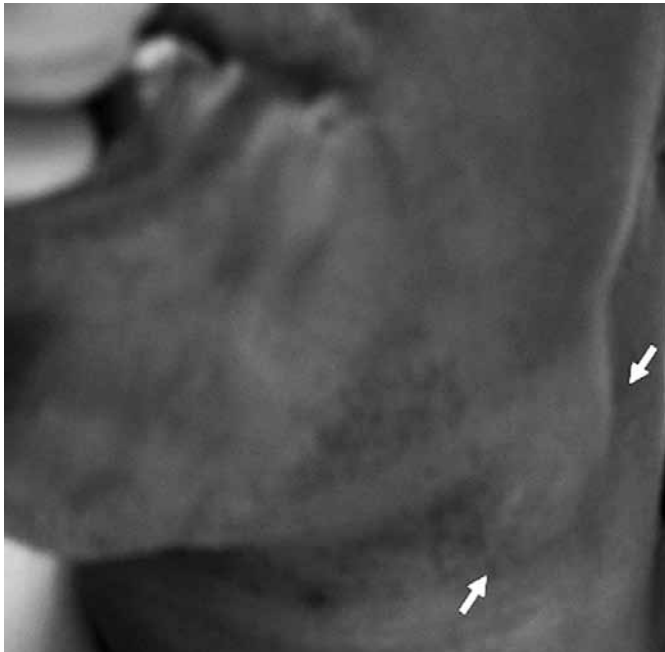

FIGURE 5. A man, without cervical extension, showing external cervical projections of the lateral pharyngeal diverticula (arrows) evidenced by blowing against resistance

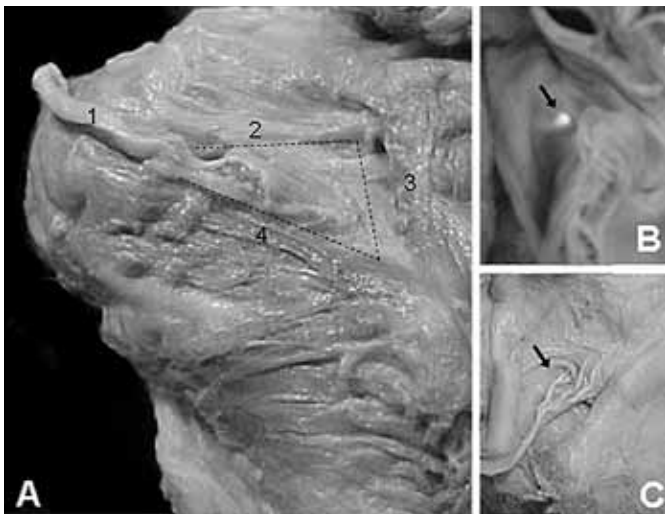


FIGURE 6 (A). Right and superior anatomically less resistant lateral laryngopharyngeal triangular formation, for passage of the laryngeal superior nerve (1). The superior margin (2) great horn of the hyoid bone; the inferior margin (3) is formed by the thyropharyngeal muscle, and the vertical margin (4) is formed by the thyrohyoid muscle; 4- esophagus. (B) a sagittal section, where the arrow indicates the trans-illuminated thin area on the top of the pyriform recess. In (C) a lateral external view showing an irregular thin area, where the arrow indicates the internal branch of the superior laryngeal nerve entrance; 5- esophagus

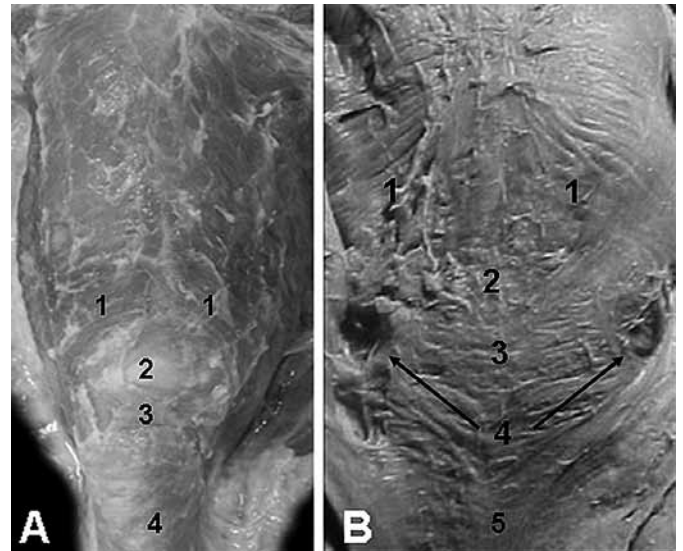


FIGURE 7. (A) Dissection of non-formalin-fixed tissue showing an external posterior view of the laryngopharynx wall, including 1- oblique fascicle of cricopharyngeal muscle, 2 - less resistant area described by Killian (Zenker site), and 3- transverse fascicle of cricopharyngeal muscle. In (B) dissection of formalin-fixed tissue showing the internal posterior surface of the pharyngopharyngeal wall, including 1- oblique fascicle of cricopharyngeal muscle, 2 - less resistant area described by Killian, 3- transverse fascicle of cricopharyngeal muscle, and 4- arrows indicate antero-lateral insertion of transverse fascicle over cricoid cartilage where we can see the less resistant area where Killian-Jamiesen can be produced

No other protrusions could be found in this group of wind instrumentalists despite the existence of the other, less resistant areas on the laryngopharyngeal wall (Figures 6 and 7).

DISCUSSION

In a group of 22 wind instrumentalists examined by means of a videofluoroscopic study, we could observe 41 protrusions on the less resistant lateral laryngopharyngeal area by air distension, and these protrusions ranged in size from 0.7 to 6 cm². In the same group, under a videofluoroscopic barium-swallow study, the lateral diverticula that were previously observed in the air-distension study did not appear, or appeared as a small protrusion. With air distension, the 41 diverticula were clearly identified, and with barium as the contrast medium, only 7 protrusions larger than 0.6 cm were clearly identified. Nineteen others were identified from frame-by-frame analyses, and showed under-scaled areas less than 0.5 cm² and only after their identification with air distension.

Two different mechanisms can cause lateral laryngopharyngeal diverticula. They can be produced by pharyngeal intra-luminal overpressure without abnormal resistance to flux passage from the pharynx to the esophagus (in wind instrumentalists), or by overpressure produced by abnormally high resistance to flux passage from the pharynx to the esophagus (in dysphagia). These two mechanisms ex-

plain the differences between the definition that consider the diverticular formations as small protrusions that appear as full sacs in a barium-swallow test^(6, 10, 13) and our results for the musician subjects examined in this study, in which the protrusions did not appear as full sacs in a barium-swallow test, despite their larger dimensions.

Physiologically, during swallowing, the high pressure into the pharynx finds the pharyngoesophageal transition open, giving food under pressure free passage to the esophagus and indirectly protecting the less resistant areas on the upper sides of the lateral laryngopharyngeal wall.

Pharyngeal protrusions are frequently associated with dysphagia. In a previous study⁽⁶⁾ that examined 33 lateral laryngopharyngeal diverticula, dysphagia was not identified in only four cases. The dysphagic process usually causes pharyngeal overpressure secondary to a high resistance to flux passage from the pharynx to the esophagus, because of the lower efficiency of the mechanism responsible for opening the pharyngoesophageal transition.

The anatomically less resistant area located above the narrow region, which configures the pharyngeal esophageal transition, is a floor where the lateral laryngopharyngeal protrusions emerge^(4, 6, 8). These anatomically less resistant areas provide sufficient elasticity to sustain a physiological and certainly, some discrete overpressure.

Nevertheless, a continuous overpressure regimen, secondary to a flux resistance produced by dysphagia, can generate a small retractile lateral protrusion that can be seen in a barium-swallow study, as a transient sac with a large neck or without a neck. This sac, which has some residual elasticity, is best defined as a pouch. The presence of somewhat larger protrusions leads to the definition of diverticula as protrusions that appear as full barium sacs, variable in size, connected to the persistent sac by a proportionately short neck^(6, 10, 13).

In wind instrumentalists, the protrusions are produced by intra-luminal pharyngeal overpressure, and do not involve difficulty in swallowing. The persistent and continuous pharyngeal overpressure induced by the resistance of the instrument's mouthpiece will strongly distend the anatomically less resistant areas of the pharynx, producing a large protrusion that is best defined as an acquired diverticulum. Nevertheless, these diverticula either did not appear, or appeared as a discrete protrusion when studied with the barium solution, because there is no abnormal resistance to flux passage from the pharynx to the esophagus during the swallowing process.

Acquired laryngopharyngeal diverticula are a consequence of overpressure. Under continuous overpressure, a permanent protrusion, with or without a neck, can be produced. This permanent large sac, with or without contrast retention, must be considered as a diverticulum. Therefore, to analyze the pharyngeal wall it is necessary to complement the barium-swallow study with a test of pharyngeal distension against resistance.

Despite the existence of the other, less resistant areas on the laryngopharyngeal segment, no other protrusions could be found in this group of wind instrumentalists. The video-

fluoroscopic lateral profile study showed a large pharyngeal distension against the closed pharyngoesophageal transition, when the musicians blew against resistance, allowing us to presume that the other, less resistant areas were exempt from the overpressure effect produced by wind instruments. We believe that this exemption from overpressure results from the inferior position of the two other, less resistant areas.

The anatomically weaker area in the lateral laryngopharyngeal wall has characteristics of individual weakness, which is accentuated with aging⁽⁶⁾. All the wind instrumentalists analyzed showed acquired diverticula, and the dimensions had no relationship to the age of the subject or the period of time of instrument use, indicating some degree of individuality in the weakness characteristics.

Blowing against resistance, as is necessary to play a wind instrument, clearly produces overload and damage in the anatomically weaker area in the laryngopharynx. Nevertheless, the kind of instrument seems to be more important than the length of time that it has been played. There were several examples in the group as a whole and also within the groups of users of the same instruments, where larger diverticula were found in musicians who had played their instruments for shorter periods. In the groups of trumpet, saxophone and clarinet players where the number of musicians allowed a comparison, the length of time that the instrument had been played and the size of the acquired diverticula showed no correlation.

There was no statistically significant difference in the lateral laryngopharyngeal right and left side resistance to overpressure imposed by the trumpet, clarinet or saxophone. The trumpet and clarinet players showed similar degrees of injury on the left and right sides. However, trumpet and clarinet overload produced more injury than the saxophone on the right and left sides, with statistically significant damage on the right side. These results lead us to believe that the overload is the factor responsible for the lateral pharyngolaryngeal injury, and that there is no real difference in the resistance of the two sides.

Without a clear dimension reference, absence of symptoms was previously considered to be common in cases of pharyngeal lateral diverticula^(6, 9, 10). In agreement with these previous observations, no spontaneous complaints were expressed by the 22 subjects all of them wind instrumentalists with large diverticula. Nevertheless, there are descriptions of complaints associated with lateral laryngopharyngeal diverticula, such as dysphagia⁽¹⁰⁾, cervical aching and odynophagia⁽¹⁵⁾, dysphagia and hoarseness⁽¹¹⁾, dysphagia, suffocation, and cervical discomfort⁽⁹⁾, aspiration after swallowing^(16, 28), laryngeal superior nerve neuralgia⁽³⁾, cervical mass⁽²⁴⁾, halitosis, and the sensation of a foreign body in the throat⁽¹⁸⁾. For this reason, all these complaints were directly mentioned to each volunteer, and all of them denied any such complaints.

Dysphagia, when present, probably is a cause of lateral laryngopharyngeal diverticula rather than a symptom. It is possible that all the other above-listed complaints attributed to diverticula are part of the same disease that is also responsible for the presence of the diverticula. If diverticula

were the cause, we certainly would have found at least one of these complaints in this group of wind instrumentalists, not their complete absence.

In three volunteers, we observed at the cervical external surface, an intermittent protrusion associated with blowing against resistance. These external cervical projections, which are associated with large diverticula, must be the cervical mass that had been mentioned previously⁽²⁴⁾. These persons also mentioned the perception of cervical pressure, described as discomfort, associated with instrument use, as observed previously⁽⁹⁾.

Acquired lateral laryngopharyngeal diverticula were identified in 100% of the musicians studied. Therefore, these diverticula should be considered as an “occupational overuse syndrome” (OOS) or, as previously described for other lesions that are produced by repetitive actions, as a “cumulative trauma disorder” (CTD) or “repetitive strain injury” (RSI). Under these several designations, this syndrome is responsible

for causing injury by repetitive tasks, as observed here in the wind instrumentalists. The absence of clear discomfort or other evident symptoms does not negate the possibility that the repetitive overload produced by a wind instrument is responsible for this condition^(14, 21, 30).

CONCLUSION

Acquired lateral laryngopharyngeal diverticula are a consequence of pharyngeal overpressure. The absence of full barium sacs upon lateral laryngopharyngeal barium-swallow examination of the diverticula of the musicians indicates a lack of difficulty in the flux passage from the pharynx to the esophagus. The acquired diverticula produced by use of a wind instrument must be considered as an OOS. The lack of symptoms does not exclude the possibility that the repetitive tasks are the main factor responsible for the development of these diverticula.

Costa MMB, Alvite FL. Divertículo faríngeo-lateral: estudo videofluoroscópico da laringofaringe em instrumentistas de sopro. *Arq Gastroenterol.* 2012;49(2):99-106.

RESUMO – *Contexto* - São apresentados os resultados de um estudo em profissionais sadios, instrumentistas de sopro. *Objetivo* - Identificar possíveis formações diverticulares produzidas nas paredes da laringofaringe pela alta pressão que a distende durante o uso desses instrumentos. *Métodos* - Utilizando o método videofluoroscópico examinou-se a faringe de 22 músicos profissionais nas incidências frontais e perfil com deglutição de 20 mL de solução de sulfato de bário e após, soprando contra resistência. *Resultados* - Em todos os voluntários detectou-se a presença de divertículo faríngeo-lateral (3 unilaterais e 19 bilaterais) com áreas de projeção variando de 0,7 a 6 cm². Trompetistas e clarinetistas apresentaram divertículos grandes e bilaterais. Nenhuma queixa importante foi referida espontaneamente ou mesmo após questionamento. No estudo baritado da deglutição ou não se detectaram ou se detectaram com pequena dimensão, devido à livre passagem do fluxo de contraste para o esôfago, os 41 divertículos identificados quando os músicos sopraram contra resistência. Embora existam na laringofaringe outras áreas anatomicamente menos resistentes, nenhuma delas apresentou protrusão no grupo de instrumentistas de sopro estudado. *Conclusões* - A formação diverticular lateral que ocorre nos instrumentistas de sopro é distinta daquela que ocorre por aumento da pressão laringofaríngea determinada por resistência anormalmente elevada à livre passagem do fluxo para o esôfago. As formações diverticulares laterais nos instrumentistas devem-se ao prolongado e repetitivo supranormal aumento da pressão laringofaríngea produzida pelo sopro contra resistência. A ausência, durante a deglutição, de resistência aumentada ao fluxo do meio de contraste em passagem para o esôfago explica o fato de os divertículos de maior dimensão, identificados pela distensão por ar, não apresentarem retenção da solução de sulfato de bário em seu interior durante a deglutição. Pode-se ainda concluir, com base na presença em 100% dos casos, que os divertículos faríngeo-laterais observados nos instrumentistas de sopro constituem-se em síndrome de sobrecarga funcional.

DESCRITORES – Divertículo de Zenker. Fluoroscopia. Doenças ocupacionais. Transtornos traumáticos cumulativos. Música.

REFERENCES

1. Atkinson L. Pharyngeal diverticula with particular reference to lateral protrusions of various types. *Arch Middx Hosp.* 1952;2:245-54.
2. Bachman AL, Seaman WB, Macken KL. Lateral pharyngeal diverticula. *Radiology.* 1968;91:774-82.
3. Bagatzounis A, Geyer G. Lateral pharyngeal diverticulum as a cause of superior laryngeal nerve neuralgia. *Laryngorhinootologie.* 1994;73:219-21.
4. Cardenal L. *Diccionario terminológico de ciencias médicas.* 6. ed. Barcelona: Salvat; 1958. p.1304.
5. Costa MMB, Moreno MPR. Videomed. Software without patent. Rio de Janeiro: Center for Electronic Computation, Universidade Federal do Rio de Janeiro. Brazil: NCE/UFRJ; Version 1-16.9.2002-alpha.
6. Costa MM, Koch HA. Lateral laryngopharyngeal diverticulum: anatomical and videofluoroscopic study. *Eur Radiol.* 2005;15:1319-25.
7. Costa MMB, Canevaro LV, Koch HA, DeBonis R. Videofluoroscopy chair for the study of swallowing and related disorders. *Radiol Bras.* 2009;42:179-84.
8. Crawford JM. The gastrointestinal tract. In: Cotran RS, Kumar V, Collins T, editors. *Robbins pathologic basis of disease.* 6th ed. Philadelphia: WB Saunders; 1999. p.755-842.
9. Curtis DJ, Cruess DF, Crain M, Sivit C, Winters C Jr, Dachman AH. Lateral pharyngeal outpouchings: a comparison of dysphagia and asymptomatic patients. *Dysphagia.* 1988;2:156-61.
10. Ekberg O, Nylander G. Lateral diverticula from the pharyngo-esophageal junction area. *Radiology.* 1983;146:117-22.
11. Ettman IK, Ramey DR 3rd. Lateral pharyngeal diverticulum: unusual cause of dysphagia and hoarseness. *Am J Gastroenterol.* 1967;47:490-7.
12. Flores-Franco RA, Limas-Frescas NE. The overused airway: lessons from a young trumpet player. *Med Probl Perform Art.* 2010;25:35.
13. Fowler WG. Lateral pharyngeal diverticula. *Ann Surg.* 1962;155:161-5.
14. Fry HJ. Overuse syndrome of the upper limb in musicians. *Med J Aust.* 1986;144:182-5.
15. Hankins WD. Traumatic hernia of the lateral pharyngeal walls. *Radiology.* 1944;42:499.
16. Huang PC, Scher RL. Endoscopic management of lateral pharyngeal pouch. *Ann Otol Rhinol Laryngol.* 1999;108:408-10.
17. Kaufman SA. Lateral pharyngeal diverticula. *Am J Roentgenol Radium Ther Nucl Med.* 1956;75:238-41.
18. Lee SW, Lee JY. Lateral pharyngeal diverticulum. *Otolaryngol Head Neck Surg.* 2010;143:309-10.
19. Lerut T, Coosemans W, Decaluwé H, Decker G, De Leyn P, Naftoux P, van Raemdonck D. Zenker's diverticulum. *Multimedia manual of cardio-thoracic surgery.* (February 24, 2009). doi:10.1510/mmcts.2007.002881.
20. Liston SL. Lateral pharyngeal diverticula. *Otolaryngol Head Neck Surg.* 1985;93:582-5.
21. McKeag D. Overuse injuries. The concept in 1992. *Prim Care.* 1991;18:851-65.
22. McMyn JK. Lateral pharyngeal diverticula. *J Fac Radiologists Lond.* 1957;8:421-3.
23. Pace-Balzan A, Habashi SM, Nassar WY. View from within: radiology in focus lateral pharyngeal diverticulum. *J Laryngol Otol.* 1991;105:793-5.
24. Pinto JA, Marquis VB, de Godoy LB, Magri EN, Brunoro MV. Bilateral hypopharyngeal diverticulum. *Otolaryngol Head Neck Surg.* 2009;141:144-5.
25. Ramsey GH, Watson JS, Gramiak R, Weinberg SA. Cinefluorographic analysis of the mechanism of swallowing. *Radiology.* 1955;64:498-518.
26. Rommelfanger KW. Lateral pharyngeal pouches (Author's transl). *Laryngol Rhinol Otol (Stuttg).* 1980;59:710-4.
27. Rubesin SE, Jessurum J, Robertson D, Jones B, Bosma JF, Donner MW. Lines of the pharynx. *Radiographics.* 1987;7:217-37.
28. Rubesin SE. The pharynx. Structural disorders. *Radiol Clin North Am.* 1994;32:1083-101.
29. Rubesin SE, Levine M S. Killian-Jamieson diverticula: radiographic findings in 16 Patients. *AJR Am J Roentgenol.* 2001;177:85-9.
30. van Tulder M, Malmivaara A, Koes B. Repetitive strain injury. *Lancet.* 2007;369:1815-22.
31. Weller MD, Porter MJ, Rowlands J. An audit of pharyngeal pouch surgery using endoscopic stapling. The patient's viewpoint. *Eur Arch Otorhinolaryngol.* 2004;261:331-3.

Received 16/11/2011.
Accepted 14/12/2011.