

Residual gastric volume evaluation with ultrasonography after ingestion of carbohydrate- or carbohydrate plus glutamine-enriched beverages: a randomized, crossover clinical trial with healthy volunteers

Paulo Cesar GOMES, Cervantes CAPOROSI, Jose Eduardo AGUILAR-NASCIMENTO, Ageo Mario Candido da SILVA and Viviane Maeve Tavares de ARAUJO*

Received 25/7/2016
Accepted 22/8/2016

ABSTRACT – Background – Abbreviation of preoperative fasting to 2 hours with maltodextrin (CHO)-enriched beverage is a safe procedure and may enhance postoperative recovery. Addition of glutamine (GLN) to CHO beverages may include potential benefits to the metabolism. However, by adding a nitrogenous source to CHO beverages, gastric emptying may be delayed and increase the risk of bronchoaspiration during anesthesia. **Objective** – In this study of safety, we aimed at investigating the residual gastric volume (RGV) 2 hours after the intake of either CHO beverage alone or CHO beverage combined with GLN. **Methods** – We performed a randomized, crossover clinical trial. We assessed RGV by means of abdominal ultrasonography (US) in 20 healthy volunteers (10 males and 10 females) after an overnight fast of 8 hours. Then, they were randomized to receive 600 mL (400 mL immediately after US followed by another 200 mL 2 hours afterwards) of either CHO (12.5% maltodextrin) or CHO-GLN (12.5% maltodextrin plus 15 g GLN). Two sequential US evaluations were done at 120 and 180 minutes after ingestion of the second dose. The interval of time between ingestion of the two types of beverages was 2 weeks. **Results** – The mean (SD) RGV observed after 8 hours fasting (13.56 ± 13.25 mL) did not statistically differ ($P > 0.05$) from the RGV observed after ingesting CHO beverage at both 120 (16.32 ± 11.78 mL) and 180 minutes (14.60 ± 10.39 mL). The RGV obtained at 120 (15.63 ± 18.83 mL) and 180 (13.65 ± 10.27 mL) minutes after CHO-GLN beverage also was not significantly different from the fasting condition. **Conclusion** – The RGV at 120 and 180 minutes after ingestion of CHO beverage combined with GLN is similar to that observed after an overnight fast.

HEADINGS – Gastric emptying. Glutamine. Ultrasonography. Drinking behavior. Randomized controlled trial.

INTRODUCTION

A strong emphasis has been given to perioperative care to improve postoperative recovery^(2,10). An important measure to be taken in this regard is to abbreviate preoperative fasting. Current protocols for anesthesia suggest fasting for 2 hours before the procedure, instead of the conventional 8 hours of fasting^(6,9,18,22,24,25,30-32). Aguilár-Nascimento and colleagues conducted randomized trials where they compared the results of conventional fasting, usually 8 hours, with that obtained when patients had abbreviated fasting with carbohydrate (CHO)-enriched beverages at 4 and 2 hours before surgery. The results showed that abbreviated fasting is a safe approach that is not associated with any known anesthesia-related complications. Additionally, it provides less irritability compared to 8-hour fasting, improves metabolic responses, and abbreviates hospital stay^(1,13).

Glutamine is the most abundant amino acid in plasma. It is the main substrate for enterocytes and immune cells. It also enhances

the peripheral sensibility to insulin, thereby reducing hyperglycemia. Additionally, glutamine is a precursor of glutathione, which is an important endogenous antioxidant^(3,4,16,20,21,23,28,29,33-35). The addition of glutamine to the CHO-enriched beverage enhances its nutritional and biochemical activity and boosts the patient's immune response⁽⁷⁾. However, the potential consequences of adding glutamine to the CHO-enriched beverage given 2 hours before anesthesia in order to enhance preoperative metabolism are not completely known, especially whether or not it alters the ability of gastric emptying. For instance, would the new formula increase the residual gastric volume 2 hours after ingestion and increase the risk of aspiration during the induction of anesthesia? This important question requires an answer.

The measuring of residual gastric volume has traditionally been done with manual aspiration of gastric residues with the aid of a syringe connected to a catheter positioned in the stomach. However, imaging tools also can be used to estimate the volume of

Declared conflict of interest of all authors: none

Disclosure of funding: no funding received

* Faculdade de Medicina, Universidade Federal de Mato Grosso, MT, Brasil.

Correspondence: Paulo Cesar Gomes. Faculdade de Medicina. Universidade Federal de Mato Grosso. Av. Fernando Correa da Costa, 2367. Bairro Boa Esperança – CEP: 78060-900 – Cuiabá MT, Brasil. E-mail: pcgomesdr@hotmail.com

gastric residue, including scintigraphy^(11,15), MRI⁽¹⁷⁾ and ultrasound (US)^(5,12,14,19). Two-dimensional ultrasound has been used since 1981 to assess gastric emptying with sensitivity comparable to that of scintigraphy, which is considered the gold standard for measuring liquid nutrients. The gastric antrum is the area of choice to evaluate gastric residue and emptying time^(5,12,14,15,27). Therefore, we measured residual gastric volume using echographic ultrasound examinations, a technique that is non-invasive, inexpensive, widely available, safe, and can be repeated as often as necessary.

The objective of this study is to analyze the evolution of the gastric residual volume by ultrasound evaluation 2-3 hours after drinking a beverage containing carbohydrate alone or carbohydrate plus glutamine.

METHODS

This was a randomized, crossover clinical trial, registered under protocol number 972/CEP – HUJM/2010, and approved by the Research Ethics Committee (CEP) of Julio Muller University Hospital (HUJM), Cuiabá, Brazil.

Echographic ultrasound examinations were performed at the Institute for Diagnostic Imaging of Santa Rosa Hospital (IMEDI) in Cuiabá, Mato Grosso. Study participants were randomly chosen among IMEDI adult volunteers.

Eligibility criteria to participate in this study were: healthy volunteers aged between 18 and 40 years, body mass index ranging between 20 and 29 kg/m², and ability to understand and adhere to the study protocol. Pregnant women or individuals with diabetes mellitus, previous history of esophagus or stomach surgery, or gastroesophageal reflux disease were excluded. Our goal was to obtain a sample of healthy individuals in order to minimize the presence of factors that could affect the results.

A total of 20 subjects (10 males and 10 females) participated in this study. Two collaborators were responsible for study randomization, scheduling the exams, preparation of beverages, providing the beverages to individuals, and recording the data. Sachets containing 12.5% maltodextrin (CHO) or 12.5% maltodextrin plus 15 g glutamine (CHO+GLN) were prepared and diluted in 400 or 200 mL water. Participants drank the solutions 4 hours (400 mL) and 2 hours (200 mL) before the scheduled time for echographic ultrasound evaluation. Table 1 shows the composition and characteristics of the solutions prepared. Two volunteers dropped out due to lack of compliance with the protocol, and four volunteers dropped out because of the taste of the solution. Other volunteers were recruited to complete the groups.

TABLE 1. Composition of oral solutions ingested by volunteers

	Solution			
	Maltodextrin		Maltodextrin + Glutamine	
Volume (mL)	400	200	400	200
Calories (kcal)	200	100	260	160
Maltodextrin (g)	50	25	50	25
Glutamine (g)	0	0	15	15
pH	4.85	4.85	5.2	5.2
Density (g/mL)	1.012	1.023	1.036	1.043
Osmolarity(mOsm/L)	232	232	315	315

The measuring of residual gastric volume was performed at three time points for each volunteer. The first ultrasound evaluation was recorded after 8 hours overnight fasting. Just after the ultrasound evaluation, the volunteer drank 400 mL of a beverage containing one of the two-tested solutions (CHO or CHO-GLN). Two hours after having ingested the beverage he drank another 200 mL of the same solution (CHO or CHO-GLN). A second and a third ultrasound evaluation was done at 120 and 180 minutes after drinking the second dose. The volunteers of this crossover study were given the solutions for ingestion (CHO or CHO+GLN) at randomly times so that the intervals between assessments were two weeks apart for each participant. The residual gastric volume after 8 hours of fasting was measured twice (for each different beverage he drank) for each participant. For statistical purposes the lowest value of the two measurements was discarded.

Data were registered and filed under the following labels: Tfasting (data collected after 8 hour fast); T120CHO and T180CHO (evaluation sequence at 120 and 180 minutes after ingestion of 12.5% maltodextrin solution); and T120CHO+GLN and T180CHO+GLN (evaluation sequence at 120 and 180 minutes after ingestion of 12.5% maltodextrin solution plus 15 g glutamine) (Figure 1).

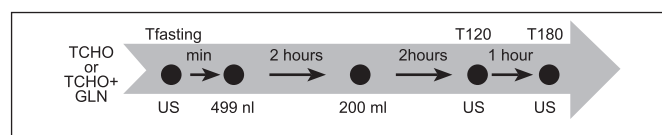


FIGURE 1. Design of the study. TCHO, 12.5% maltodextrin solution; TCHO+GLN, 12.5% maltodextrin plus 15 g glutamine solution; Tfasting, data collected after 8 hour fast; T120, data collected 120 minutes after ingestion of CHO or CHO+GLN; and T180, data collected 180 minutes after ingestion of CHO or CHO+GLN.

Residual gastric volume assessment was performed using a Philips model Envisor CHD ultrasound device; all exams were done by the same physician. Participants were positioned in the right lateral decubitus position for 5 minutes, and then an echographic ultrasound examination was done to capture frozen cross-sectional and longitudinal images of the gastric antrum. The antral residual gastric volume was then calculated using a formula to assess the volume of an ellipsoid cavity (longitudinal diameter x transverse diameter x anteroposterior diameter x 0.52). Echographic evaluation of the gastric body and fundus were always performed to assure that all liquid content had flowed into the antral area. Figure 2 shows one example of the echographic image obtained.

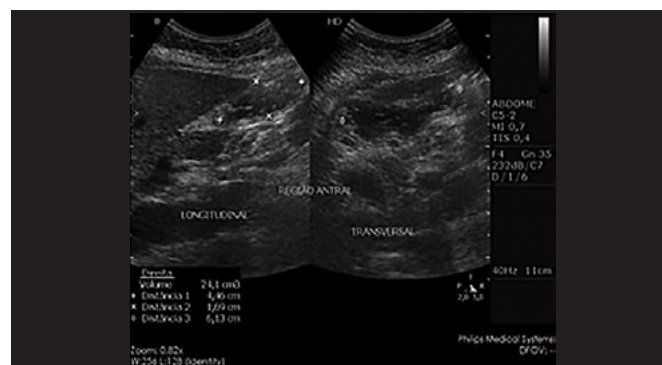

FIGURE 2. Ultrasound images showing the gastric antrum and methodology for calculation of the residual gastric volume.

Data were analyzed with SPSS version 18.0. Analysis of variance (ANOVA) was used to compare residual gastric volumes. Microsoft Excel and SPSS were used to analyze all data. The 5% level ($P < 0.05$) was established as statistically significant.

RESULTS

Demographic data are shown in Table 2. Mean residual gastric volume obtained after 8 hour fasting (Tfasting) was 13.56 ± 13.25 mL. At 120 and 180 minutes after drinking 12.5% maltodextrin solution (TCHO), the residual gastric volumes were 16.32 ± 11.78 mL and 14.60 ± 10.39 mL, respectively. Residual gastric volumes at 120 and 180 minutes after drinking 12.5% maltodextrin plus 15 g glutamine (TCHO+GLN) were 15.63 ± 18.83 mL and 13.65 ± 10.27 mL, respectively. There was no difference between the gastric volumes obtained after 8 hours of fasting and those obtained at 120 and 180 minutes after ingestion of either volume (200 or 400 mL) of CHO or CHO+GLN ($P > 0.05$) (Table 3 and Figure 3).

TABLE 2. Demographic data of study population after randomization

	Mean±SD
Body weigh (kg)	69.97 ± 10.99
Age (years)	24.90 ± 3.91
Height (m)	1.68 ± 0.09
BMI (kg/m ²)	24.50 ± 2.61

TABLE 3. Mean ± standard derivation of residual gastric volume (mL) after an 8 hour fast (Tfasting), and at 120 (T120) and 180 (T180) minutes after drinking a beverage containing maltodextrin or maltodextrin plus glutamine

Tfasting	13.56±13.25 *	
	CHO	CHO+GLN
T120	16.32 ± 11.78	15.63 ± 18.83
T180	14.60 ± 10.39	13.65 ± 10.27

* $P > 0.05$ vs T120 and T180 (CHO and CHO+GLN). CHO: carbohydrate (maltodextrin); CHO+GLN: maltodextrin + glutamine.

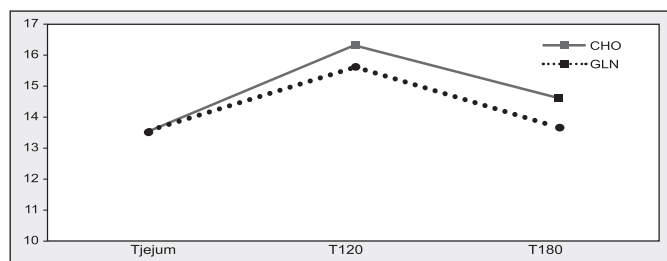


FIGURE 3. Residual gastric volume after 8 hour fasting (Tfasting), and at 120 (T120) and (T180) minutes after drinking solution containing maltodextrin or maltodextrin plus glutamine. Data represent the mean ± standard deviation values. CHO: carbohydrate beverage; CHO+GLN: carbohydrate beverage plus glutamine. * $P > 0.05$ versus T120 and T180 (CHO and CHO+GLN).

DISCUSSION

In the present study, the mean residual gastric volume after 8 hour fasting was very close to that obtained with 2 hour fasting and then having participants drink beverages containing either maltodextrin alone or maltodextrin plus glutamine. No significant difference was observed in regard to the volumes used (400 or 200 mL) for both beverages.

Assessment of the residual gastric volume can be done with several methods: aspiration by an enteral tube positioned in the stomach^(6,8), scintigraphy^(11,15), 3-D ultrasonography⁽¹¹⁾, and MRI⁽¹⁷⁾. Two-dimensional ultrasonography can be used for this analysis, and it is a noninvasive exam that can be performed at bedside^(26,27).

Dock-Nascimento and colleagues studied 56 women who underwent elective video laparoscopic cholecystectomy, and assessed their residual gastric volume through aspiration by a nasogastric tube during anesthetic induction. Patients were randomly assigned to four groups: standard fasting, and three groups with abbreviated fasting using respectively water, 12.5% maltodextrin, or 12.5% maltodextrin with 50 g glutamine. Patients drank 400 mL of the solution on the night before surgery, and 200 mL of solution 2 hours before anesthetic induction. Mean residual gastric volumes were around 10 mL, and all were statistically similar^(6,8). Their findings corroborate ours, but our residual volumes measured by ultrasound assessment were greater. In our study, 8 hour fasting resulted in 13.56 mL vs 5 mL in their study, 2-hour maltodextrin resulted in 16.32 mL vs 7 mL, and maltodextrin + glutamine resulted in 15.63 mL vs 4.5 mL. We believe that the higher volumes obtained with ultrasound were due to improvement of the evaluation method, with ultrasound providing direct observation of the volume concentrated inside the gastric antrum.

Gentilcore and colleagues studied gastric emptying time using scintigraphy and 3-D ultrasonography and two distinct diets, and found no significant differences between the approaches⁽¹¹⁾. The authors concluded that the residual gastric volume after 8 hour fasting was similar for the two types of diet (39.9 and 51.8 mL), a finding that is consistent with our results. This finding indicates that ultrasound is a good alternative for measuring residual gastric volume, and thus should be further investigated.

Lobo and colleagues measured the residual gastric volume using MRI in subjects who drank one of three types of liquid diet: one enriched with carbohydrate diluted in 400 mL of liquid, and two other more complex diets. The mean residual gastric volume was calculated after 8 hour fasting or at 120 and 180 minutes after diet intake. Residual gastric volume after 8 hour fasting ranged between 12 and 42 mL⁽¹⁷⁾, which is similar to that found in our study. After drinking the carbohydrate plus glutamine beverage, the gastric volumes observed by Lobo and colleagues were 30 and 15 mL at 120 and 180 minutes, respectively. The result obtained at 120 minutes was greater than ours, although the volume of solution used in the study by Lobo and colleagues was twice as much as that used in our study. After 180 minutes, however, the result obtained was similar to that of our study.

The use of ultrasonography to measure the residual gastric volume is inexpensive and can be done with high-technology handheld devices that can be used at the bedside or in the operating room. However, it is a subjective exam, and the skill of the operator performing the examination may directly affect the quality of the results. Instructing individuals to lie down in decubitus position, as performed in this study, prevents the flow of liquid into other areas of the stomach, which would compromise the measurement of residual gastric volumes.

Our results show that abbreviation of fasting, followed by intake of a carbohydrate solution alone or in association with glutamine, diluted in either 400 or 200 mL, is safe method that produces results similar to those observed after an 8 hour fast. Therefore, this alternative approach should be investigated further to produce additional data supporting the widespread use of this technique.

Authors' contributions

Gomes PC: data collection, literature review, article elaboration, study design, project development. Aguilar-Nascimento JE: study design, project development and treatment supervision and critical

analysis. Araujo VMT: nutritional assessment and guidance of solutions used, literature review. Silva AMC: statistical analysis and writing of text. Caporossi C: project development, literature review, study design, treatment supervision and critical analysis.

Gomes PC, Caporossi C, Aguilar-Nascimento JE, Silva AMC, Araujo VMT. Avaliação do volume residual gástrico em voluntários saudáveis usando a ultrassonografia, após ingestão de solução líquida enriquecida com carboidrato e glutamina. Estudo clínico, randomizado, duplo cego e cruzado. *Arq Gastroenterol.* 2017;54(1):33-6.

RESUMO – Contexto – A abreviação do jejum pré-operatório com solução enriquecida com maltodextrina é segura, recomendada por sociedades de anestesiologia e acelera a recuperação pós-operatória. A associação de glutamina à maltodextrina resultaria em benefícios metabólicos, porém, esta associação pode alterar o volume do resíduo gástrico e consequentemente risco de broncoaspiração. **Objetivo** – Avaliaremos, usando a ultrassonografia, o volume residual gástrico em jejum de 8 horas e após 120 e 180 minutos da ingestão de solução de maltodextrina isolada ou associada a 15 g de glutamina. **Métodos** – Estudo clínico, randomizado, duplo cego e cruzado. Vinte voluntários saudáveis, sendo 10 do sexo masculino e 10 do sexo feminino, foram submetidos a seguinte sequência de avaliação, independente da solução usada. Os voluntários foram avaliados em jejum de 8 horas, 120 e 180 minutos após a ingestão da solução de maltodextrina 12,5% e 120 e 180 após a ingestão da solução de maltodextrina 12,5% mais 15 g de glutamina. **Resultados** – Não houve diferença estatisticamente significativa entre os volumes obtidos após jejum de 8 horas (13,56 mL) e os obtidos após 120 (16,32 mL) e 180 minutos (14,60 mL) da ingestão da solução de maltodextrina 12,5% ($P>0,05$). Para a solução enriquecida com glutamina, os volumes obtidos após 120 minutos (15,63 mL) e 180 minutos (13,65 mL) também não demonstraram diferença estatisticamente significativa quando comparados ao jejum ($P>0,05$). **Conclusão** – O volume residual gástrico após 120 e 180 minutos da ingestão das soluções de maltodextrina a 12,5% isolada ou associada a 15 g de glutamina é semelhante ao observado em jejum.

DESCRIPTORIOS – Esvaziamento gástrico. Glutamina. Ultrassonografia. Comportamento de ingestão de líquido. Ensaio clínico controlado aleatório.

REFERENCES

- Aguilar-Nascimento JE, Dock-Nascimento DB, Faria MSM, et al. Preoperative ingestion of carbohydrates decreases the occurrence of postoperative gastrointestinal symptoms in patients undergoing cholecystectomy. *ABCD Arq Bras Cir Dig.* 2007;20:77-80.
- Aguilar-Nascimento JE, Bicudo-Salomão A, Caporossi C, Silva RM, Cardoso EA, Santos TP. Enhancing surgical recovery in Central-West Brazil: The ACERTO protocol results. *Eur J Clin Nutr Metab.* 2008;3:e78-e83.
- Ardawi MS, Newsholme EA. Maximum activities of some enzymes of glycolysis, the tri-carboxylic acid cycle and ketone-body and glutamine utilization pathways in lymphocytes of the rat. *Biochem J.* 1982;208:743-8.
- Bakalar B, Duska F, Pachel J, Fric M, Otahal M, Pazout J, Andel M. Parentally administered dipeptide alanyl-glutamine prevents worsening of insulin sensitivity in multiple-trauma patients. *Crit Care Med.* 2006;34:381-6.
- Bateman DN, Whittingham TA. Measurement of gastric emptying by real-time ultrasound. *Gut.* 1982;23:524-7.
- Borges Dock-Nascimento D, Aguilar-Nascimento JE, Caporossi C, Sepulveda Magalhães Faria M, Braganolo R, Caporossi FS, Linetzy Waitzberg D. Safety of oral glutamine in the abbreviation of preoperative fasting: a double-blind, controlled, randomized clinical trial. *Nutr Hosp.* 2011;26:86-9.
- Déhelotte P, Hasselmann M, Cynober L, Allaouchiche B, Coeffier M, Hecketsweiler B, et al. L-alanyl-L-glutamine dipeptide-supplemented total parenteral nutrition reduces infectious complications and glucose intolerance in critically ill patients: The French controlled, randomized, double-blind multicenter study. *Crit Care Med.* 2006;34:598-604.
- Dock-Nascimento DB, de Aguilar-Nascimento JE, Magalhães Faria MS, Caporossi C, Shlessarenko N, Waitzberg DL. Evaluation of the effects of a preoperative 2-hour fast with maltodextrin and glutamine on insulin resistance, acute-phase response, nitrogen balance and serum glutathione after laparoscopic cholecystectomy: a controlled randomized trial. *JPEN J Parenter Enteral Nutr.* 2012;36:43-52.
- Faria MS, de Aguilar-Nascimento JE, Pimenta OS, Alvarenga LC Jr, Dock-Nascimento DB, Shlessarenko N. Preoperative fasting of 2 hours minimizes insulin resistance and organic response to trauma after video-cholecystectomy: a randomized, controlled clinical trial. *World J Surg.* 2009;33:1158-64.
- Fearon KC, Ljungqvist O, Von Meyenfeldt M, et al. Enhanced recovery after surgery: a consensus review of clinical care for patients undergoing colonic resection. *Clin Nutr.* 2005;24:466-77.
- Gentilecore D, Hausken T, Horowitz M, Jones KL. Jones Measurements of gastric emptying of low- and high-nutrient liquids using 3D ultrasonography and scintigraphy in healthy subjects. *Neurogastroenterol Motil.* 2006;18:1062-8.
- Gilja OH, Hausken T, Degard S, Berstad A. Gastric emptying measured by ultrasonography. *World J Gastroenterol.* 1999;5:93-4.
- Hausel J, Nygren J, Lagerkranser M, Hellstro PM, Hammarqvist F, Almstrom C, et al. A carbohydrate-rich drink reduces preoperative discomfort in elective surgery patients. *Anesth Analg.* 2001;93:1344-50.
- Holt S, Cervantes J, Wilkinson AA, Wallace JH. Measurement of gastric emptying rate in humans by real-time ultrasound. *Gastroenterology.* 1986;90:918-23.
- Hveem K, Jones KL, Chatterton BE, Horowitz M. Scintigraphic measurement of gastric emptying and ultrasonographic assessment of antral area: relation to appetite. *Gut.* 1996;38:816-21.
- Li C, Buettger C, Kwagh J, Matter A, Daikhin Y, Nissim IB, Collins HW, Yudkoff M, Stanley CA, Matsuhashi FM. A signaling role of glutamine in insulin secretion. *J Biol Chem.* 2004;279:1393-401.
- Lobo DN, Hendry PO, Rodrigues G, Marciani L, Totman JJ, Wright JW, et al. Gastric emptying of three liquid oral preoperative metabolic preconditioning regimens measured by magnetic resonance imaging in healthy adult volunteers: A randomised double-blind, crossover study. *Clinical Nutrition.* 2009;28:636-41.
- Maltby JR. Preoperative fasting guidelines. *Can J Surg.* 2006;49:138-9.
- Marzio L, Giacobbe A, Conoscitore P, Facciorusso D, Frusciantone V, Modoni S. Evaluation of the use of ultrasonography in the study of liquid gastric emptying. *Am J Gastroenterol.* 1989;84:496-500.
- McCauley R, Kong SE, Hall J. Glutamine and nucleotide metabolism within enterocytes. *JPEN J Parenter Enteral Nutr.* 1998;22:105-11.
- Melis GC, Ter Wengel N, Boelens PG, Van Leeuwen PA. Glutamine: Recent developments in research on the clinical significance of glutamine. *Curr Opin Clin Nutr Metab Care.* 2004;7:59-70.
- Mendelson CL. The aspiration of stomach contents into the lungs during obstetric anesthesia. *Am J Obstet Gynecol.* 1946;52:191-205.
- Newsholme P. Why is L-glutamine metabolism important to cells of the intestinal tract. *JPEN J Parenter Enteral Nutr.* 1985;9:608-17.
- Nygren J, Thorell A, Jacobsson H, Larsson S, Schnell PO, Hylen L, et al. Preoperative gastric emptying. Effects of anxiety and oral carbohydrate administration. *Ann Surg.* 1995;222:728-34.
- Nygren J. The metabolic effects of fasting and surgery. *Best Pract Res Clin Anaesthesiol.* 2006;20:429-38.
- Perlas A, Chan VW, Lupu CM, Mitsakakis N, Hanbidge A. Ultrasound Assessment of Gastric Content and Volume. *Anesthesiology.* 2009;111:82-9.
- Ricci R, Bontempo I, Corazziari E, La Bella A, Torsoli A. Real time ultrasonography of the gastric antrum. *Gut.* 1993;34:173-6.
- Saito H, Furukawa S, Matsuda T. Glutamine as an immunoenhancing nutrient. *JPEN J Parenter Enteral Nutr.* 1999;23:59-61.
- Singleton KD, Beckey VE, Wischmeyer PE. Glutamine prevents activation of NF Kappa B and stress kinase pathways, attenuates inflammatory cytokine release, and prevents acute respiratory distress syndrome (ARDS) following sepsis. *Shock.* 2005;24:583-9.
- Søreide E, Eriksson LI, Hirlekar G, Eriksson H, Henneberg SW, Sandin R. Pre-operative fasting guidelines: an update. *Acta Anaesthesiol. Scand.* 2005;49:1041-7.
- Stuart PC. The evidence base behind modern fasting guidelines. *Best Pract Res Clin Anaesthesiol.* 2006;20:457-69.
- Weimann A, Braga M, Harsanyi L, Laviano A, Ljungqvist O, Soeters P, et al. ESPEN Guidelines on Enteral Nutrition: Surgery including organ transplantation. *Clin Nutr.* 2006;25:224-44.
- Wernerman J. Glutamine and acute illness. *Curr Opin Crit Care.* 2003;9:279-85.
- Yang R, Tan X, Thomas AM, Steppacher R, Qureshi N, Morrison DC, Van Way CW. Alanine-glutamine dipeptide (AGD) inhibits expression of inflammation-related genes in hemorrhagic shock. *JPEN J Parenter Enteral Nutr.* 2007;31:32-6.
- Yeh CL, Hsu CS, Yeh SL, Lin MT, Chen WJ. Dietary glutamine supplementation reduces cellular adhesion molecule expression and tissue myeloperoxidase activity in mice with gut-derived sepsis. *Nutrition.* 2006;22:408-13.