

MOYAMOYA DISEASE

CT SCAN STUDY OF A BRAZILIAN-BORN JAPANESE GIRL

*GUILBERTO MINGUETTI, PhD **
*MARLUS VINICIUS COSTA FERREIRA ***

Moyamoya is a rare form of cerebro-vascular disease of occlusive nature. The entity was regarded as such by Nishimoto et al. in 1964, who described three cases of their own and twenty one other cases collected from the Japanese literature. When reported by Nishimoto in 1964 the entity was thought to be unique to the Japanese people, but some reports have been made in the Western literature about non-Japanese patients. The case here reported presented typical clinical course and arteriographic findings.

Genetical studies and CT scan are included. While the karyotype does not show any abnormality, CT findings are consistent with several areas of old infarcts and severe brain atrophy with subsequent ventricular dilation, which may be the results of the vascular abnormalities found in cases of moyamoya disease.

ANALYSIS OF THE CASE

S. S., three years old girl with history of attacks of headache and slight incoordination of the right lower and upper limbs since the age of one year and, more recently, periods of sudden generalised weakness which used to last seconds were referred by a paediatrician. The parents which are Brazilian-born Japanese related that apart from the patient they have another girl of six with a history of fits and right sided weakness starting at about the age of two years. At that time an air-encephalogram was performed during which there occurred troubles with the anaesthetics and she became demented and tetraplegic; the correct diagnosis was never given. They have also a girl of six months and the family history is otherwise negative. On the examination it was found no clinical abnormality and all laboratory tests were normal, less the EEG which was suggestive of left sided focal abnormality at the fronto-rolandic area. Serum and urinary chromatography for inborn metabolic error were also negatives. The patient was kept with phenobarbitone which had been prescribed by the paediatrician and was kept under close observation. Two weeks later she awaked with the right leg paralysed and she could not stand. At that time on examination

Trabalho realizado no Centro de Tomografia Computadorizada (CETAC) de Curitiba.

* Assistant Professor, Department of Internal Medicine (Neurology), Federal University of Paraná, Curitiba, PR; ** Neurologist.

it was found complete paralysis of the right lower limb with a diminished tendon reflex and extensor plantar response. A new EEG was carried out and showed delta waves in the left cerebral hemisphere. A brain scintilogram showed increased uptake of the technicium in the left fronto-parietal area, suggestive of a vascular problem. The patient was asked to start with physiotherapy and a week later she had exactly the same picture, but at that time in the left side. She was then submitted to a cerebral angiography using a femoral catheter. Both carotid circulations were demonstrated and showed very well the distinctive features of moyamoya disease (Fig. 1). A short course of steroids was started along with physiotherapy. Several others attacks occurred after the angiogram and each one of them made the neurological state of the girl worser.

CT scan of the patient and genetical studies of the three girls were carried out almost two years after the first symptoms. Although the karyotype of the patient and her sisters did not show any abnormalities (Fig. 2) her brain scan showed areas of old infarcts and marked brain atrophy with subsequent enlargement of the ventricular system (Fig. 3 — A, B, C and D).

DISCUSSION

The initial symptoms of moyamoya disease are correlated with age. The most common manifestation in those under twenty one years of age is sudden weakness of a limb or limbs (about 70% in the group of 73 patients studied by Nishimoto and Takeuchi in 1968). These attacks of weakness quickly

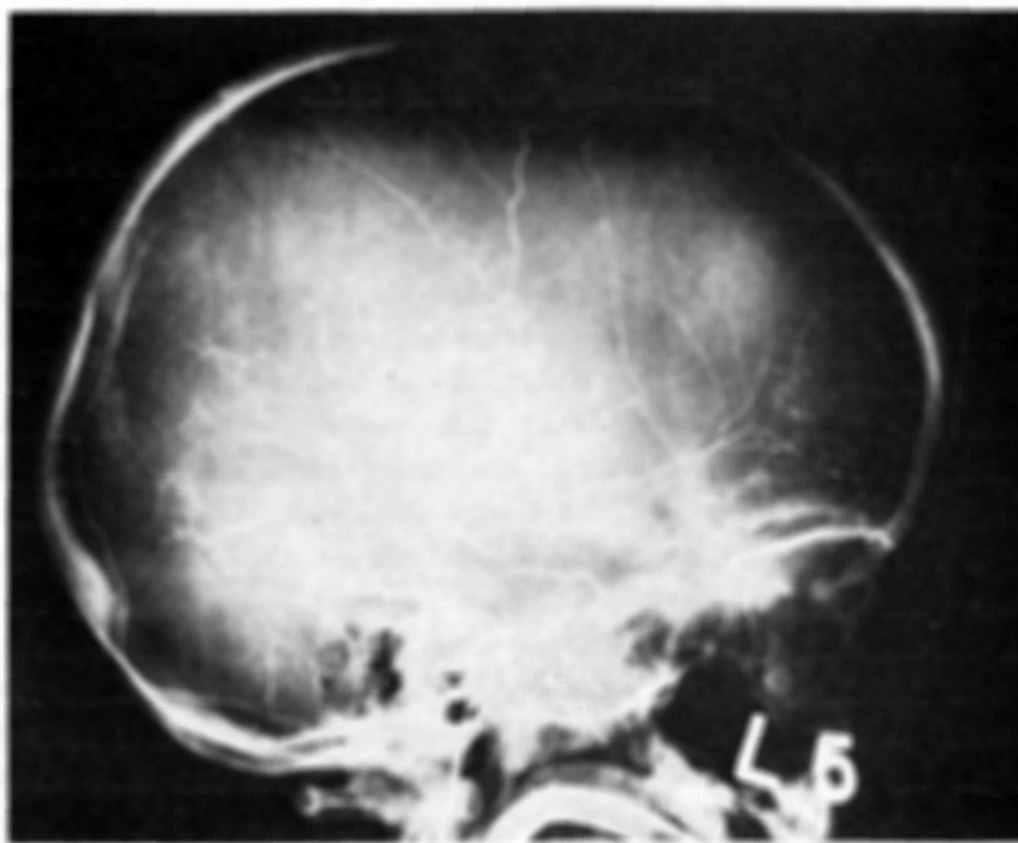


Fig. 1 — Left cerebral angiogram showed narrowing of the internal carotid artery, hemangiomatous malformations in the basilar supply and prominent collateral networks.

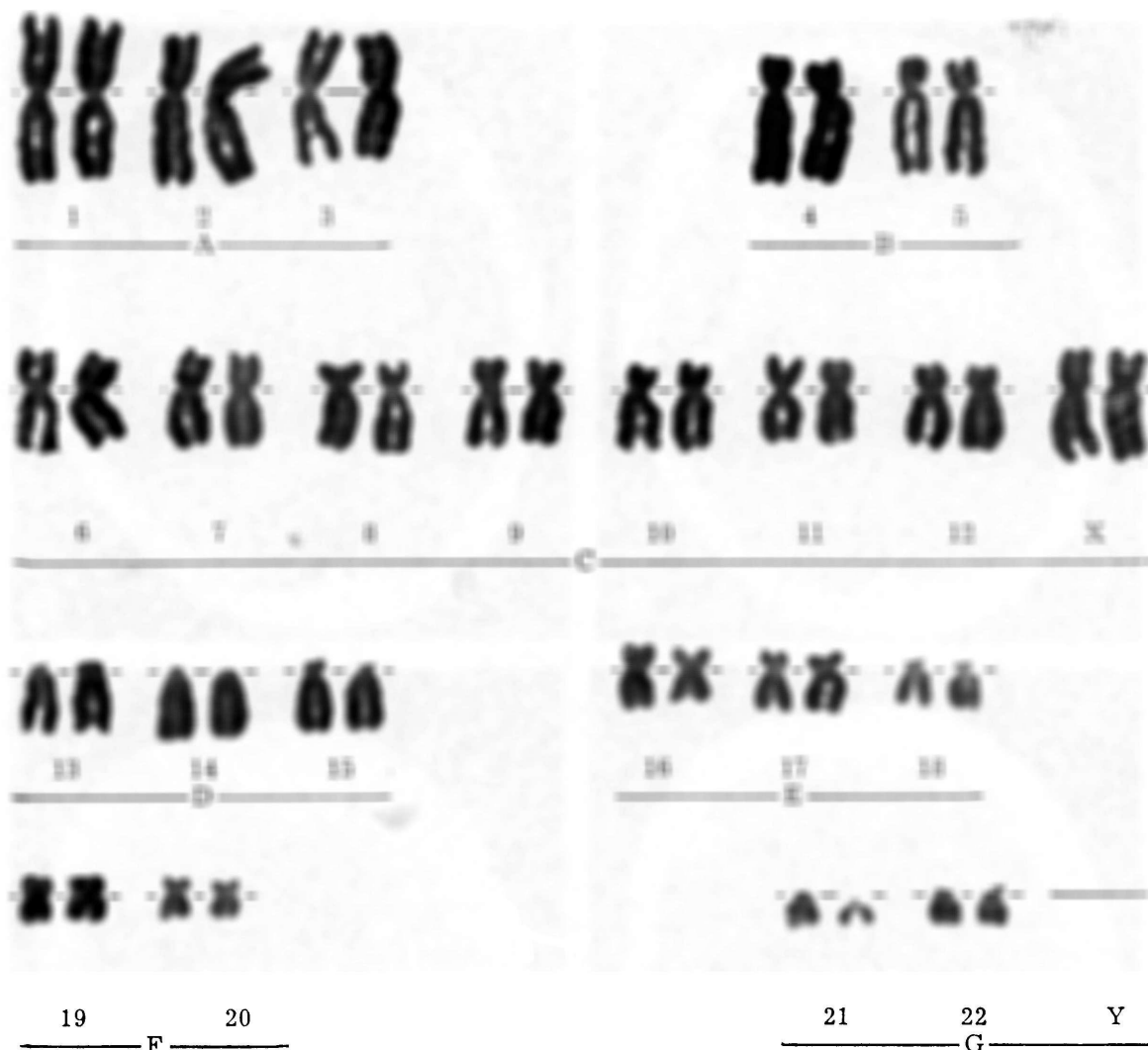


Fig. 2 — Karyotype of the patient (46, XX) presenting normal pattern.

disappear but are recurrents. Other symptoms of these group are: convulsion, nystagmus and visual disturbances. In the Nishimoto group of patient over twenty one year of age with moyamoya disease 52% had subarachnoid hemorrhage as initial manifestation. Yet in this group motor weakness was the next most common sign. The hallmark of this entity is the angiographic appearance which are characterized by occlusion of both internal carotid arteries, hemangiomas in the basilar supply, prominent collateral networks in the region of the basal ganglia and multiple transdural anastomoses between external and internal carotid circulations. Standard laboratory studies have failed to show any evidence of an underlying immunological, metabolic or infectious disorder. Thus, the etiology of moyamoya disease has not been conclusively determined and opinion is divided as to whether it is due to a true congenital vascular malformation or an acquired disease (Jones and Wetzel, 1970; Vuia et al., 1970; Pecker et al., 1973). There are only few autopsy reports and they do not help in clarifying the origin of the disease: there is no evidence of atheroma or inflammation in the vessel walls. The prognosis seems to be worse to those patients with symptoms starting on the early stages of life. The majority of patients presenting with symptoms after 21 years seems to run a better prognosis (Iivanainen et al., 1973). There is no specific treatment available and there is no good evidence to suggest that anticoagulants

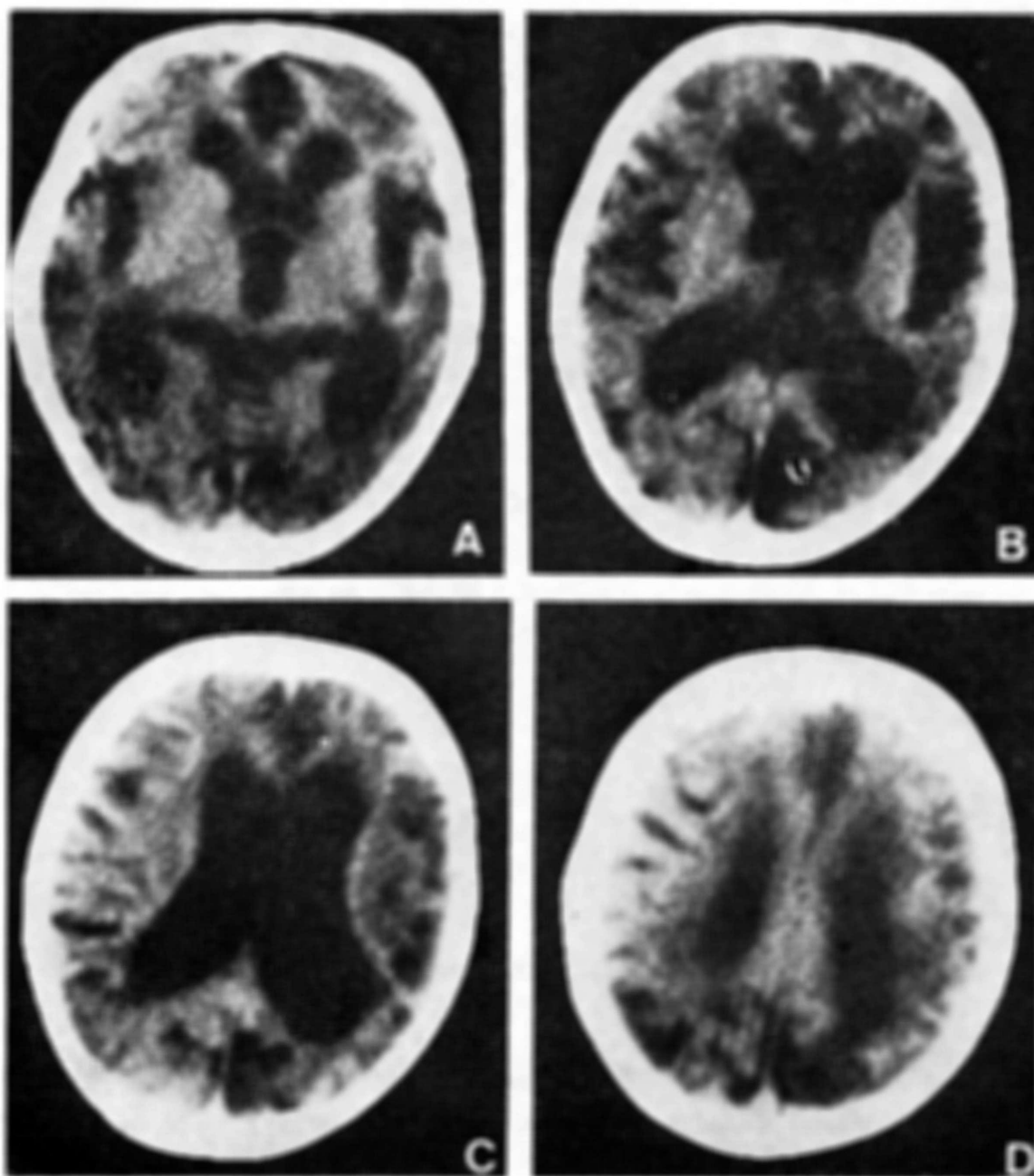


Fig. 3 (A, B, C and D) — CT findings: plain scan showed symmetrical ventricular dilatation of lateral and third ventricle. The sylvian fissures and basal cistern as well as the cortical sulcal markings are quite prominent. Several large focal areas of low density (12 — 19H) consistent with old infarcts are seen. After contrast infusion (not showed) there was no enhancement (CT performed by the "Delta 25" scanner, matrix 256 x 256).

are helpful. In the case here described it was felt that the use of steroids (dexamethazone — 2mg six hourly) for short periods during and after the acute episodes helped in minimise the intensity of them.

Computed tomography has proved to be the most effective mode of evaluating cerebral infarction and this is especially true when multiple focal infarcts are present. Old infarcts (over 4 weeks), as in the case of moyamoya disease here described, appear as an area of diminished absorption which are well defined and homogeneous in density. While in the acute infarcts visible contrast enhancement is observed in 88,1% of the patients by some authors (Lee et al.,

1978), no visible contrast enhancement is demonstrated in the old stages of the disease. Old infarcts are rounded, oval, or cleft like in shape, ranging from several millimeters to several centimeters in size. Ipsilateral or focal dilation of the ventricular system with widening of the fissures and sulci are commonly seen and sometimes may occur pencephaly or arachnoid cyst formation.

RESUMO

Doença de moyamoya: tomografia computadorizada de uma menina de origem japonesa

Moyamoya é uma doença cérebro-vascular de etiologia desconhecida que aparece predominantemente nos indivíduos de raça japonesa. Poucos são os relatos de casos desta doença cujos sintomas principais são decorrentes de infartos cerebrais múltiplos, convulsões e hemorragia subaracnoide. Os achados principais nos casos de moyamoya são os angiográficos que se caracterizam por oclusão parcial ou total das carótidas, malformações angiomasos, circulação colateral proeminente na região dos gânglios da base e anastomoses transdurais múltiplas.

O caso aqui descrito apresenta, além do estudo angiográfico, avaliação genética e tomografia computadorizada cerebral (TCC). O cariotipo levado a efeito na paciente e em suas duas irmãs não apresenta qualquer anormalidade. A TCC, contudo, mostra claramente um padrão compatível com infartos cerebrais múltiplos antigos e a consequente repercussão de tais lesões no cérebro da paciente.

REFERENCES

1. IIVANAINEN, M.; VUOLIO, M. & HALOMEN, V. — Occlusive disease of intracranial main arteries with collateral networks (moyamoya disease) in adults. *Acta Neurol. Scandinav.* 49:307, 1973.
2. JONES, R. R. & WETZEL, N. — Bilateral vertebrobasilar rete mirabile. *J. Neurosurg.* 33:581, 1970.
3. LEE, K. F.; CHAMBERS, R. A.; DIAMOND, C.; PARK, C. H.; THOMPSON Jr., N. L.; SCHNAPF, D. & PRIPSTEIN, S. — Evaluation of cerebral infarction by computed tomography with special emphasis on microinfarction. *Neuroradiology* 16:156, 1978.
4. NISHIMOTO, A. & SUGIU, R. — Hemangiomasous malformation of bilateral internal carotid artery at the base of brain: preliminary report. *Proc. Annual Meeting of the Neuro-Radiological Association of Japan (Tokyo)* 5:2, 1964.
5. NISHIMOTO, A. & TAKEUCHI, S. — Abnormal cerebrovascular network related to the internal carotid arteries. *J. Neurosurg.* 29:255, 1968.
6. PECKER, J.; SIMOM, J.; GUY, G. & HERRY, J. F. — Nishimoto's disease: significance of its angiographic appearances. *Neuroradiology* 5:223, 1973.
7. VUIA, O.; ALEXIANU, M. & GABOR, S. — Hypoplasia and obstruction of the circle of Willis in a case of atypical hemorrhage and its relationship to Nishimoto's disease. *Neurology (Minneapolis)* 20:361, 1970.

Current address of Dr. Guilberto Minguetti: CETAC, Rua Brigadeiro Franco 122 — 80000, Curitiba, PR — Brasil.