

ELEMENTARY MOTOR PERSEVERATION IN EARLY DIAGNOSIS OF PROGRESSIVE SUPRANUCLEAR PALSY

RICARDO NITRINI *

The clinical hallmarks of progressive supranuclear palsy (PSP) are supranuclear ophthalmoplegia chiefly affecting vertical gaze, axial dystonia in extension of the neck, pseudobulbar palsy and mild dementia^{3,4,10,11}. When the clinical picture is complete diagnosis is easily established but at the beginning of the illness complaints are vague and the neurological examination is inremarkable. Therefore early diagnosis is often difficult. Kristensen⁴, reviewing the literature on PSP pointed out that the average time from the onset of symptoms until diagnosis was of 3.9 years (ranging from two months to 23 years).

Three PSP patients presented an uncommon neurologic sign before the appearance of the distinctive features of the illness. This sign is discussed in this paper.

CASUISTICS

Patient 1 — A.C., a 62-year-old woman was first examined in June 1981. Two years before she began to have frequent falls and her gait became unsteady. Her brother found her to be emotionally unstable and it was noted that her handwriting was illegible. Her past medical history had been good. The general physical examination was unremarkable. Her orientation for time and place were normal and she did not have disturbances in attention, memory and speech. The facies was immobile; her gait was uncertain, with small steps and she tended to fall backwards when unsupported. Muscle tone and power were normal. The ability for reproduction of rhythmic structures and for performance of sequences of hand movements were disturbed by frequent perseverations. Gross perseverations occurred in any attempt to draw simple geometric shapes (Fig. 1). Eye movements were full. Routine blood and CSF examinations, CT scan of the head and EEG were normal. Six months later a neurologic examination disclosed a loss of willed downward eye movements. In May 1982 her neck was held in a slightly extended position. Treatment with levodopa associated with benserazide, with anticholinergic drugs and with methysergide were unsuccessful. Her condition progressively deteriorated and she developed truncal ataxia, dysarthria and dysphagia with repeated respiratory infections. Death was due to aspiration pneumonia in May 1984.

Patient 2 — S.S., a 59-year-old man was examined in February 1984. Twenty months before he had suffered a head trauma with a brief unconsciousness period after which he began to show some visual difficulty. Progressively, he developed trouble in swallowing fluids and episodes of immotivated laughter. He had a history of mild arterial hypertension. At examination blood pressure was 150/105 mmHg. His orientation for time and place, memory, attention and speech were normal. His facies was immobile. Gait, muscle power and tone were normal. There were perseverations in rhythmic structure reproductions, in the performance of sequences of hand movements and in drawing of simple geometric shapes. Eye movements were

Department of Neurology, University of São Paulo School of Medicine: *Assistant Professor.

full. Routine blood and CSF examinations, CT scan of the head and EEG were normal. He was given hydrochlorothiazide but there was progressive visual difficulty that was not relieved by lenses. In November 1984 his gait became unstable and the willed downward eye movements were almost impossible. Treatment with levodopa associated with benserazide caused slight improvement of the gait disturbance. Recently he was given amitriptyline.

Patient 3 — F.N., a 59-year-old man was first seen in June 1985. He had a five-years history of slight memory decline. During the previous year his speech had become slurred and his handwriting was illegible. He had been in treatment for diabetes mellitus type 2. His mother had had senile dementia. His orientation for time and place and his attention were normal. He had a slight memory deficit for recent events. Stance and gait were normal. There was a plastic rigidity in the limbs without cogwheel phenomenon. Muscle power was normal. When he tried to draw simple geometric shapes and to repeat rhythmic or sequential movements there were intense perseverations (Fig. 1). Eye movements were full in all directions. Routine blood and CSF examinations were normal. CT scan of the head showed cortical and subcortical atrophy. Four months later the willed downward movements of the eyes were lost and his stance was broad-based. In January 1986 the neurologic examination disclosed truncal ataxia, extension of the neck and dysphagia for fluids. Treatment with levodopa associated with benserazide caused a slight improvement in his handwriting. Recently he was given amitriptyline.

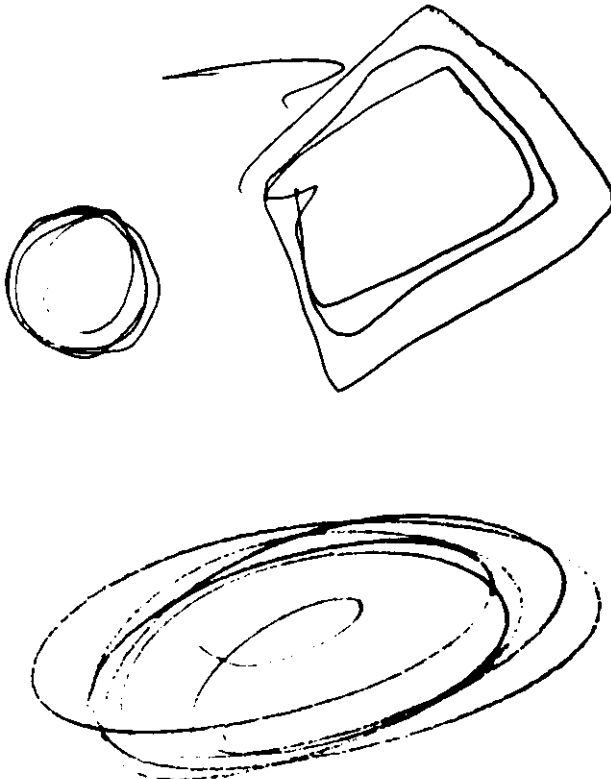


Fig. 1 — Above: drawings of geometric shapes by patient 1. Below: drawing of a circle by patient 3.

COMMENTS

The first neurologic examinations were performed in the three reported patients before the appearance of the main features of PSP. The initial complaints were frequent falls in the first patient, visual difficulties in the second, and impaired memory in the third patient. These symptoms are usually reported at the beginning of PSP in the majority of the cases⁴.

All three patients presented intense perseverations that caused dysdiadokokinesia and impaired the reproduction of rhythmic structures. The perseverations were particularly obvious in drawing of simple geometric shapes. When drawing a circle the patients performed repetitive movements and in so doing they drew the same shape several times. The phenomenon known as "elementary motor perseveration" or as "efferent perseveration" occurs when the inhibitory and modulating function of the premotor cortex relative to the basal ganglia is abolished, so that once an element of a movement has begun it is no longer inhibited at the right time and continues unchecked^{6,8}. This kind of perseverations is seen in patients with lesions in the frontal lobes that extend deeper into the brain, involving the connections between the premotor region and the basal ganglia⁷. Luria^{6,8} reported elementary motor perseveration in the case of a tumor that affected both frontal lobes and the basal ganglia, as well as in a deep-seated hemorrhage in the premotor area and also during the edematous phase after removing of a meningioma of the premotor area. Elementary motor perseveration should not be mistaken for the more common type of perseveration usually found in states of disturbed consciousness and in diffuse lesions of the central nervous system^{1,2}. In these conditions perseveration is characterized by maintenance of recurrence of a purposeful response to a preceding stimulus rather to the succeeding one which has just been given¹. For example, if a patient with this type of perseveration is asked to draw a circle he will do it correctly but if after this he is asked to draw a square he will draw a circle again, showing that he cannot easily switch from one action to another.

Elementary motor perseverations have not been described in Alzheimer's and Pick's disease and can be occasionally found in multi-infarct dementia. In Parkinson's disease perseverations occur during tests for dysdiadokokinesia but elementary motor perseverations are not observed. Treatment with anti-parkinsonian drugs did not improve perseverations. Two patients showed slight improvement of other symptoms of PSP when treated with levodopa associated with benserazide. The effectiveness of amitriptyline in the treatment of PSP has been described^{5,9} but this drug had just been prescribed for two of the patients when this paper was written.

Concluding, elementary motor perseveration occurred in three PSP patients with different onset symptoms before the appearance of the distinctive features of the illness. Though this sign has not yet been described in PSP it is possible that an adequate search for its occurrence may show it to be an important sign for early diagnosis and an element for the clinical characterization of PSP.

SUMMARY

Three patients with progressive supranuclear palsy (PSP) with different symptoms at onset presented intense elementary motor perseverations before the appearance of the distinctive features of the illness. In elementary motor perseveration once an element of a movement has begun it is no longer inhibited at the right time and continues unchecked. Perseverations were observed in these patients during tests for dysdiadokokinesia, for reproduction of rhythmic structures and during the drawing of simple geometric shapes. Though this sign has not yet been described in PSP it is possible that an adequate search for its occurrence may show it to be an important sign for early diagnosis and an element for the clinical characterization of PSP.

RESUMO

Perseveração motora elementar no diagnóstico precoce da paralisia supranuclear progressiva.

Em três casos de paralisia supranuclear progressiva (PSP) com diferentes manifestações clínicas iniciais foram constatadas intensas perseverações motoras elementares antes do aparecimento dos sinais neurológicos característicos da doença. Na perseveração motora elementar, após o início de um elemento de movimento não há inibição no momento adequado, ocorrendo tendência à repetição incessante. As perseverações foram observadas nestes casos aos testes da diadococinesia, da capacidade de reprodução de estruturas rítmicas e às tentativas de desenhar formas geométricas simples. Embora este sinal ainda não tenha sido descrito na PSP, é possível que sua pesquisa sistemática possa demonstrar que a perseveração motora elementar seja sinal útil para o diagnóstico precoce e um elemento semiótico para a caracterização clínica da PSP.

REFERENCES

1. ALLISON, R.S. — Perseveration as a sign of diffuse and focal brain damage — I. Brit. med. J. 2:1027, 1966.
2. ALLISON, R.S. — Perseveration as a sign of diffuse and focal brain damage — II. Brit. med. J. 2:1095, 1966.
3. JANKOVIC, J. — Progressive supranuclear palsy. Neurologic Clinics 2:473, 1984.
4. KRISTENSEN, M.O. — Progressive supranuclear palsy-20 years later. Acta neurol. scand. 71:177, 1985.
5. KVALE, J.N. — Amitriptyline in the management of progressive supranuclear palsy. Arch. Neurol. 37:387, 1982.
6. LURIA, A.R. — Two kinds of motor perseverations in massive injuries of the frontal lobes. Brain 88:1, 1965.
7. LURIA, A.R. — Disturbances of higher cortical functions with lesions of the frontal region. In A.R. Luria: Higher Cortical Functions in Man. Basic Books, New York, 1966.
8. LURIA, A.R. — Sensorimotor and premotor zones and the organization of movement. In A.R. Luria: The Working Brain. Penguin Books, London, 1973.
9. NEWMAN, G.C. — Treatment of progressive supranuclear palsy with tricyclic antidepressants. Neurology 35:1189, 1985.
10. STEELE, J.C. — Progressive supranuclear palsy. Brain 95:693, 1972.
11. STEELE, J.C.; RICHARDSON, J.C. & OLSZEWSKI, J. — Progressive supranuclear palsy. Arch. Neurol. 10:333, 1964.