

## HISTOPATHOLOGICAL AND IMMUNOHISTOCHEMICAL STUDY OF THE BRAIN AND HEART IN THE CHRONIC CARDIAC FORM OF CHAGAS' DISEASE

JOSÉ EYMARD HOMEM PITTELLA \*, CICERO MENEGUETTE \*,  
ALFREDO J. AFONSO BARBOSA \*

---

**SUMMARY** — A histopathological and immunohistochemical study of the brain and heart was made in 50 patients with the chronic cardiac form of Chagas' disease. The immunohistochemical technique used was the peroxidase-antiperoxidase method adapted for the demonstration of the *T. cruzi* amastigotes. Histological and immunohistochemical examination of the brain showed encephalitis in multiple foci, although sparse, in four patients (8%). In one of the patients the process was recent, active, and containing parasites. In the other three patients, the lesions were of minor intensity, with light exudative inflammatory changes, suggesting a process becoming inactive, or already inactive. The search for parasites in these three patients was negative, even with use of immunoperoxidase. The heart histological and immunohistochemical study showed, besides the chronic myocarditis in multiple foci associated with interstitial fibrosis, amastigotes in seven patients (14%). The absence of parasites and of inflammatory changes in the brain in the great majority of patients with chronic Chagas' disease, contrasting with the constant finding of inflammatory changes and the occasional finding of amastigotes in the myocardium of the same patients, allows us to state, in the same way other authors did, that there is no histopathological basis to support the existence of the chronic nervous form of Chagas' disease.

**KEY WORDS:** Chagas' disease, brain, Chagasic encephalitis, immunoperoxidase.

### **Estudo histopatológico e imuno-histoquímico do encéfalo e coração na forma crônica cardíaca da doença de Chagas.**

**RESUMO** — Fez-se o estudo histopatológico e imuno-histoquímico sistematizado do encéfalo e coração de 50 pacientes com forma crônica cardíaca de doença de Chagas. A técnica imuno-histoquímica empregada foi o método da peroxidase-antiperoxidase adaptado para a demonstração de formas amastigotas do *T. cruzi*. O exame histológico e imuno-histoquímico do encéfalo revelou, em 4 casos (8%), encefalite em focos múltiplos, não sistematizados. Num dos casos o processo era recente, em atividade, contendo parasitas. Nos outros três casos as lesões eram de menor intensidade, com fenômenos exsudativos discretos, sugerindo tratar-se de processo em extinção ou já inativo. A pesquisa de parasitas nestes três casos, mesmo com o uso da imunoperoxidase, foi negativa. O estudo histológico e imuno-histoquímico do coração mostrou, além da miocardite crônica em focos múltiplos acompanhada de fibrose endomisial, amastigotas em 7 casos (14%). A ausência de parasitas e de processo inflamatório no encéfalo da grande maioria dos chagásicos crônicos, contrastando com o achado constante de lesões inflamatórias e o encontro ocasional de amastigotas no miocárdio destes mesmos pacientes, permite afirmar, de modo semelhante a outros autores, que não há base histopatológica para que se possa admitir a existência da forma crônica nervosa da doença de Chagas.

**PALAVRAS-CHAVE:** doença de Chagas, encéfalo, encefalite chagásica, imunoperoxidase.

---

\* M.D., Laboratory of Neuropathology, Department of Pathology, Federal University of Minas Gerais (UFMG) Medical School, Belo Horizonte. Aceite: 26-junho-1992.

Since Chagas' earliest papers it is known that the central nervous system (CNS) involvement by *Trypanosoma cruzi* (*T. cruzi*) may occur<sup>8-10</sup>. In spite of its low frequency, chagasic encephalitis cases in their acute form are well known, the majority of cases affecting children under 1 year old<sup>7,10-13,16,23,25,27,28,31,34-36,39,43,46</sup>. Chagas<sup>8-10</sup> postulated the existence of a chronic nervous form, directly caused by *T. cruzi*. This author has justified the existence of the chronic nervous form based on the presence of encephalitis in the acute cases<sup>5</sup>. Still according to Chagas, the chronic nervous form would be consequent to the lesions observed in the acute form, or rather, it would represent sequelae of the encephalitis. Afterwards the author admitted that the chronic nervous form cases would be, in their majority, evolution forms of the histopathological changes<sup>9</sup>. However, the pathological documentation presented by him and by the authors who studied it has been poor, not allowing definitive conclusions about the existence or non-existence of an anatomical basis to characterize the chronic nervous form as postulated by Chagas<sup>1,5,6,18,19,45</sup>. Recent papers based on histopathological study of the brain in a great number of patients have denied the existence of an anatomical basis to characterize the chronic nervous form<sup>33,37</sup>. Nevertheless, recent publications about Chagas' disease, although describing minor, focal inflammatory changes in the CNS of a few patients with chronic Chagas' disease, still propose the existence of a morphological basis of the chronic nervous form<sup>26,29</sup>.

The development of immunohistochemical techniques which have made it possible to find with greater sensitivity and specificity the presence of many parasites (viruses, bacteria, protozoa) has led us into searching, with immunohistochemical method, amastigotes in the brain and heart of patients with chronic chagasic carditis confirmed by histopathological diagnosis. The conventional histological study of these brains was also undertaken. Thus, using similar methodology, it was possible to compare the immunohistochemical and histopathological findings in the brain and heart, the latter serving as a standard model of the Chagas' disease chronic form.

#### MATERIALS AND METHODS

Fifty patients with chronic cardiac Chagas' disease were studied, all of them presenting histopathological changes characteristic of chronic chagasic carditis. Among these 50 patients, 19 were retrieved consecutively in the period 1980 to 1986 in the Department of Pathology, Federal University of Minas Gerais Medical School, in Belo Horizonte. The other 31 patients had been subject of a former study<sup>33</sup>. Forty-five patients were between 20 and 60 years old (90%), three patients were over 60 years old (6%) and two were under 20 years old (4%). Forty-five patients showed clinical and pathological signs of congestive heart failure. Three patients had a sudden death, without previous symptoms; other two patients died of other causes not related to the chagasic carditis. Neurologic examination was performed in all patients.

The brain, after being fixed in totum in 10% formaldehyde, was examined and sectioned by frontal sections of the cerebral hemispheres and transversal sections of the brainstem and cerebellum. Fragments were taken from the frontal, parietal, temporal and occipital lobes, basal ganglia, thalamus, hypothalamus, midbrain, pons, medulla and cerebellar hemispheres. For each patient three fragments of the heart were examined, taken from the atrium and ventricular walls. The brain and heart fragments were processed for embedding in paraffin, and 7  $\mu$ m-thick sections were obtained. From each brain and heart fragments two consecutive sections stained with haematoxylin and eosin and with peroxidase-antiperoxidase (PAP) were taken. The PAP technique used was the one introduced by Sternberger et al.<sup>42</sup> and adapted by Barbosa<sup>4</sup> for the demonstration of *T. cruzi* amastigotes in tissue sections. Briefly: (1) incubate with 0.3% hydrogen peroxide during 30 minutes to block endogenous peroxidase activity; (2) incubate at 40C overnight with sera anti-*T. cruzi* (dilution 1:1000) obtained from rabbits with experimental trypanosomiasis cruzi; (3) incubate with goat anti-rabbit IgG (Miles-Yeda Ltd, Israel), dilution 1:80, at room temperature for 30 minutes; (4) incubate with rabbit PAP complex (Miles-Yeda Ltd, Israel), dilution 1:200; (5) the sections were revealed by the diaminobenzidine method under microscope control, and afterwards, counterstained with haematoxylin, dehydrated and mounted in Entellan (Merck, Brazil). Phosphate buffer solution, 0.01M, pH 7.2, was used as a diluent and as a washing solution between each step. For positive controls, heart sections of mice with acute trypa-

nosomiasis cruzi were used; for negative controls, the absorbed antiserum samples or normal rabbit serum samples were used, instead of rabbit anti-T. cruzi sera.

## RESULTS

The brain sections stained with haematoxylin and eosin showed encephalitis in multiple foci, although sparse, in four patients (8%). A detailed histopathological study of these inflammatory changes was formerly reported<sup>33</sup>. In the four patients, the basic change was formed by inflammatory nodules composed by mononuclear cells among a variable number of microglial cells. In one of the patients (number 2), rare amastigotes forming nests close to glial cells with no inflammatory reaction, or in small accumulations surrounded by inflammatory nodules were observed (Fig. 1). The other three patients (9, 15 and 40) in which the search for amastigotes was negative showed inflammatory nodules smaller and more hypocellular than in patient 2 (Fig. 2). Except for degenerative changes in rare neurons close to or within the inflammatory nodules (patients 2) and for focal loss of neurons of the cerebellum dentate nucleus (patient 15), all the nervous tissue components close to the inflammatory nodules were preserved. Immunohistochemical study of the brain in patient 2 revealed the same number of amastigotes as identified in haematoxylin and eosin stained sections, however with better parasite individualization (Fig. 3). In patients 9, 15 and 40, and in the 46 remaining patients, amastigotes in the sections stained with PAP were not observed. Ischemic cerebral changes, related to thromboembolic phenomena and hypoxemia following congestive heart failure and disturbances of the cardiac rhythm, were found in 74% of the patients. A systematized pathological study of these ischemic changes was previously reported<sup>32</sup>. Except for neurological symptomatology associated with cerebrovascular disease in some patients, no neurological manifestations that could be attributed to the inflammatory changes above mentioned were observed.

The microscopic analysis of the heart sections stained with haematoxylin and eosin showed chronic myocarditis in multiple foci, with light mononuclear infiltration in 16 patients (33%), moderate in 28 patients (56%) and intense in 6 patients (12%). The inflammatory infiltration was generally associated with interstitial fibrosis, from discrete to mode-

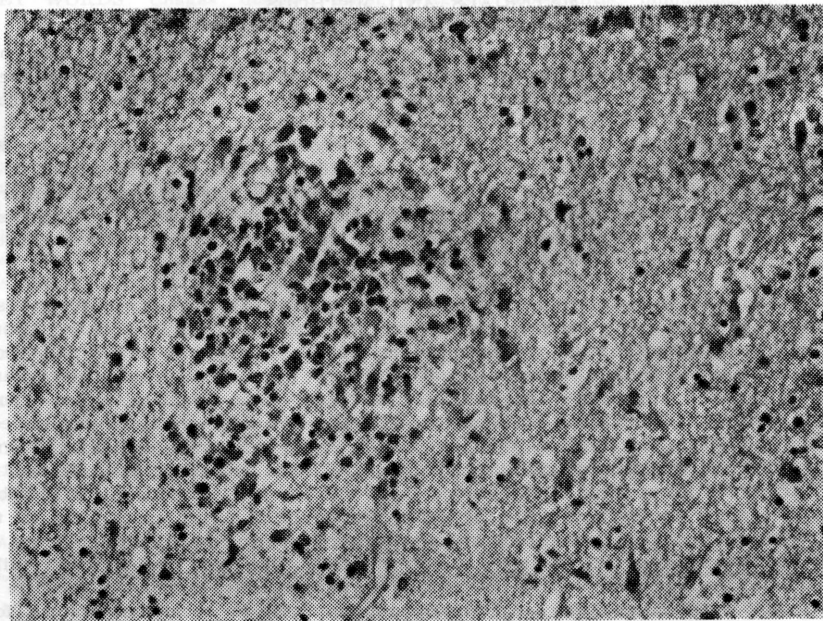
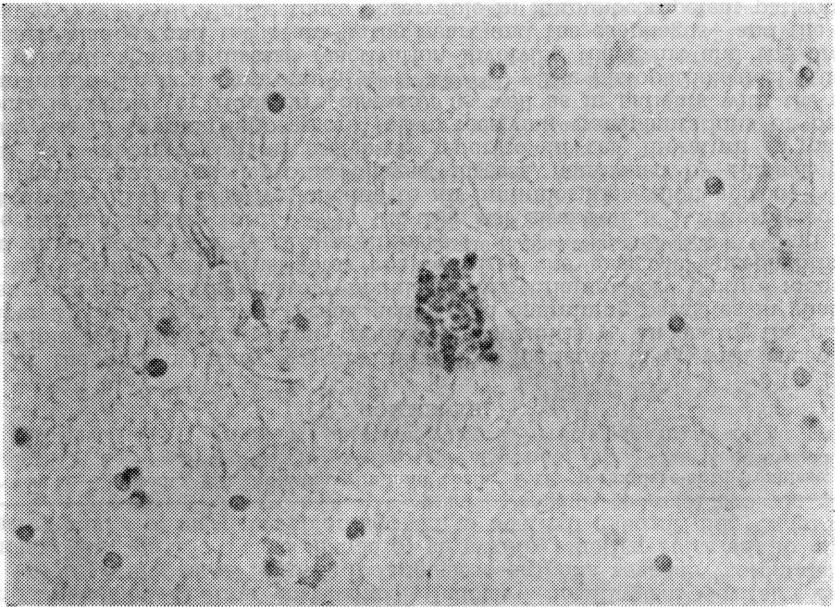
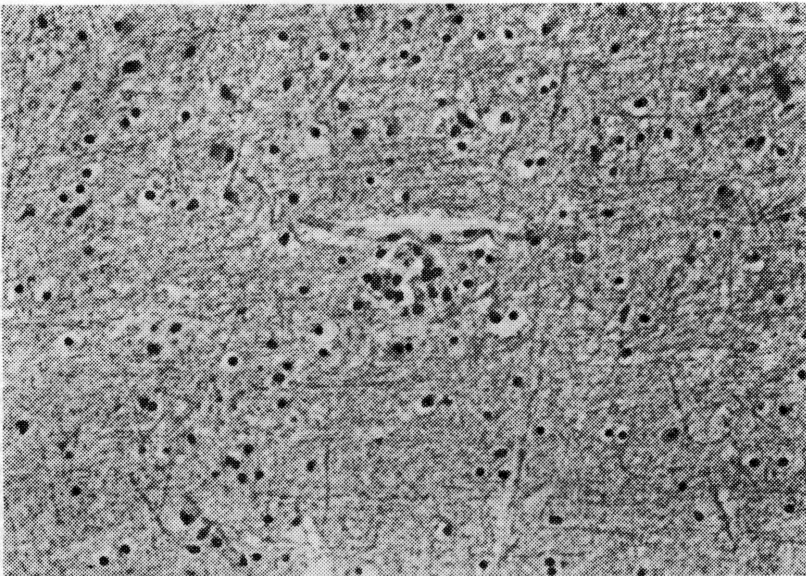


Fig. 1. Case 2. Cerebral cortex-white substance junction. Inflammatory nodule formed by mononuclear and microglial cells. Preserved neurons can be observed to the right. Haematoxylin and eosin, X 256.



**Fig. 2.** Case 40. Cerebral white substance. Residual inflammatory nodule, without changes of the adjacent nervous tissue. Compare with Fig. 1. Haematoxylin and eosin, X 256.



**Fig. 3.** Case 2. Cerebral white substance. Amastigote nest without inflammatory reaction. PAP, counterstaining with haematoxylin, X 256.

rate. Two patients (4%) presented amastigotes in the cardiac muscle cells and, rarely, among the inflammatory infiltrate. The other patients (96%) did not show amastigotes in the sections stained with haematoxylin and eosin. The microscopic study of sections stained with PAP showed, besides the parasitism in the two patients already mentioned, amastigotes in other five patients, adding up to seven patients (14%). It is interesting to point out that the only patient in which amastigotes were found in the brain (patient 2), the search of parasites in the myocardium was negative, even in the sections stained with PAP. No clinical or pathological evidence of immunosuppression was found in this patient. Data on patients presenting *T. cruzi* amastigotes in cardiac muscle cells or encephalitis with or without the presence of parasites are showed in Table 1.

Table 1. Data on chronic chagasic patients presenting *T. cruzi* amastigotes in cardiac muscle cells or encephalitis with or without the presence of parasites.

Case	Sex	Age (yrs)	Brain			Heart		
			Encephalitis	Amastigotes		Myocarditis	Amastigotes	
				HE	PAP		HE	PAP
2	M	35	+	+	+	+	—	—
3	F	25	—	—	—	+	—	+
9	M	24	+	—	—	+	—	—
11	M	48	—	—	—	+	—	+
15	M	60	+	—	—	+	—	—
19	M	37	—	—	—	+	—	+
30	M	56	—	—	—	+	+	+
31	M	50	—	—	—	+	—	+
34	M	20	—	—	—	+	+	+
37	F	48	—	—	—	+	—	+
40	F	44	+	—	—	+	—	—

+, present; —, absent; HE, haematoxylin and eosin; PAP, peroxidase-antiperoxidase.

#### COMMENTS

In the present study we identified four patients (8%) with encephalitis in multiple foci, although sparse (nodular encephalitis)<sup>40</sup>. In one of the patients (number 2) the process was recent, active, and containing parasites in glial cells and surrounded by inflammatory nodules. This inflammatory picture associated with the presence of amastigotes characterizes the chagasic encephalitis described in the acute form of Chagas' disease<sup>7,10-13,16,23,25,27,31,34-36,39,43,46</sup> and rarely in the chronic cardiac form<sup>19,23,33</sup>. In this last situation it is interpreted as a result of the disease reactivation due to an immunosuppression episode<sup>28,33</sup>. In fact, reactivation of the chronic Chagas' disease, confirmed by clinical, pathological and laboratory data, has been reported in the literature in patients making use of immunosuppressors (after receiving transplantations or because of acute leukemias or Hodgkin's disease), as well as in patients with the acquired immunodeficiency syndrome<sup>2,14,20,21,24,30,38,41</sup>. The histopathological study of these patients showed disease reactivation involving the heart and the brain<sup>28</sup>, the heart, bladder and the brain<sup>20</sup>, the heart and the esophagus<sup>2</sup> and the brain separately<sup>14,24,30,33,41</sup>. Unlike those observable in immunocompetent patients, the cerebral lesions in immunosuppressed patients are often voluminous, forming single or multiple necrotic masses. Rarely, the parasites could not be found in the examined viscera and, then, the diagnosis of Chagas' disease reactivation was based on laboratory studies<sup>35</sup>.

When a non-immune host is infected with *T. cruzi* the parasites are widely destroyed by macrophages at the inoculation site<sup>44</sup>. However, the organisms which escape from the macrophages transform into trypomastigotes which can infect non-phagocytic cells, mainly cardiac muscle, skeletal muscle, and glial cells. The appearance of an efficient immune response against *T. cruzi* is responsible for reduction of the blood and tissue parasitism to virtually undetectable levels, providing the host with a solid acquired resistance<sup>15,22</sup>. In the chronic phase, spontaneous relapses are not observed, unless after the host immunosuppression. The immune response in the chronic phase still precludes parasitaemia elevation (reappearance of the acute phase), even in the experimentally reinoculated hosts. However, the acquired immunity is not the sterilizing type, that is, it does not destroy the first infection parasites totally or the ones reinoculated afterwards<sup>22</sup>. Thus the host remains infected for the rest of its life; some structures as the suprarenal central vein may act as a parasite reservoir<sup>3</sup> and contribute to the disease reactivation when there is some immunosuppressive episode.

The other three patients analysed in this present work (patients 9, 15 and 40), who presented brain inflammatory changes, had minor lesions, with light exudative phenomena, suggesting a process becoming inactive, or already inactive, which could represent sequelae of the acute form. The search for parasites in these three patients was negative, even with PAP. The small dimensions and the low cellularity of these inflammatory nodules, as well as the absence of parasites, allows us to interpret these lesions as the final regression phase of the inflammatory nodule of the acute form<sup>33</sup>. Such interpretation would also be valid for the minor, focal inflammatory changes, also devoid of parasites, described by other authors in the brain of some chagasic patients with the chronic cardiac form<sup>29,37</sup>.

In 92% of the chronic chagasic patients examined, neither parasites, inclusively through a sensitive and specific immunohistochemical method, nor inflammatory changes in the brain were observed. This fact strongly suggests that these individuals would not have had a CNS infection in the acute phase of Chagas' disease or, alternatively, they would have presented mild encephalitis, in very sparse foci, with total regression of the lesions. The absence of parasites and inflammatory nodules in the brain in the great majority of chronic chagasic patients analysed in this work (only a small percentage presents inflammatory changes relatively insignificant, residual), contrasting with the constant finding of inflammatory changes and the occasional finding of amastigotes in the myocardium of the same patients, allows us to conclude in the same way Queiroz<sup>37</sup> and Pittella<sup>33</sup> did, through the lack of histopathological basis to characterize the chronic nervous form of Chagas' disease.

**Acknowledgements** — This work was supported by FINEP (Financiadora de Estudos e Projetos) and by Grant 302036/76 from CNPq (Conselho Nacional de Desenvolvimento Científico e Tecnológico).

#### REFERENCES

1. Alencar A. Encefalopatia crônica chagásica. *J Bras Neurol* 1982, 18:7-12.
2. Almeida HO, Tafuri WL, Bogliolo L, Cunha JC. Parasitismo incomum do miocárdio e do esôfago em chagásico crônico, portador de doença de Hodgkin e em uso de imunodepressores. *Rev Soc Bras Med Trop* 1974, 8:117-121.
3. Almeida HO, Teixeira VP, Oliveira AC. Flebite com parasitismo em supra-renais de chagásicos crônicos. *Arq Bras Cardiol* 1981, 36:341-344.
4. Barbosa AJA. Método imunocitoquímico para a identificação de amastigotas do *Trypanosoma cruzi* em cortes histológicos de rotina. *Rev Inst Med Trop São Paulo* 1985, 27: 293-297.
5. Borges-Fortes A. As lesões do sistema nervoso na enfermidade de Chagas (tripanosomíase americana). *J Clin* 1942, 23:353-361.
6. Borges-Fortes A. As lesões do sistema nervoso na enfermidade de Chagas (tripanosomíase americana). *J Clin* 1945, 26:277-286.
7. Cardoso RA. Lesões do sistema nervoso central em 4 casos infantis agudos de doença de Chagas. *Bol Inst Puer Univ Brasil* 1960, 17:101-110.
8. Chagas C. Nova entidade mórbida do homem: resumo geral de estudos etiológicos e clínicos. *Mem Inst Oswaldo Cruz* 1911, 3:219-275.

9. Chagas C. Les formes nerveuses d'une nouvelle trypanosomiase: *Trypanosoma cruzi* inoculé par *Triatoma magista* (maladie de Chagas). Nouv Iconogr Salpêtrière 1913, 26:1-9.
10. Chagas C. Tripanosomiase americana: forma aguda da moléstia. Mem Inst Oswaldo Cruz 1916, 8:37-59.
11. DeCoursey E. The first fatal case of Chagas' disease observed on the isthmus of Panama. Am J Trop Med 1935, 15:33-40.
12. Dominguez A, Gavallér B. Encephalitis chagastica. Z Tropenmed Parasitol 1962, 13:308-311.
13. Elejalde P. Lesões cerebrais na doença de Chagas aguda. An Paul Med Cir 1958, 76:348-350.
14. Ferreira MS, Ferreira RG, Oliver W, Rocha A, Silva AM. Meningoencefalite aguda causada pelo *Trypanosoma cruzi* em paciente portador da síndrome da imunodeficiência adquirida (AIDS). Rev Soc Bras Med Trop 1989, 22(Suppl2):91.
15. Hudson L, Britten V. Immune response to south american trypanosomiasis and its relationship to Chagas'disease. Br Med Bull 1985, 41:175-180.
16. Johnson CM, DeRivas GT. Six new cases of Chagas' disease in Panama with review of previous cases. Am J Trop Med Hyg 1936, 16:47-57.
17. Jörg ME. Histopatología neural en disfunción cerebral mínima, secuela de meningoencefalitis por *Trypanosoma cruzi*. Prensa Med Argent 1978, 65:229-238.
18. Jörg ME, Rovira IZ. Formas clínicas encefalopáticas de enfermedad de Chagas crónica observadas en la Argentina. Prensa Med Argent 1980, 67:757-764.
19. Jörg ME, Orlando AS. Neurosíndrome mínimo en la tripanosomiasis cruzi crónica (estudio de dos casos de encefalopatía chagásica crónica). Mem Inst Oswaldo Cruz 1967, 65:63-79.
20. Jost L, Turin M, Etchegoyen F, Leiguarda R, Torcuato A, Iotti R. Meningoencefalitis chagásica en paciente con tratamiento inmunosupresor por trasplante renal. Rev Neurol Arg 1977, 3:425-428.
21. Kohl S, Pickering LK, Frankel LS, Yaeger RG. Reactivation of Chagas' disease during therapy of acute lymphocytic leukemia. Cancer 1982, 50:827-828.
22. Kretzli AU. Resposta imune humoral na doença de Chagas. Interciência 1983, 8:374-383.
23. Laranja FS, Dias E, Nóbrega G, Miranda A. Chagas' disease: A clinical, epidemiologic, and pathologic study. Circulation 1956, 14:1035-1060.
24. Leiguarda R, Roncoroni A, Taratuto AL, Jost L, Berthier M, Nogues M, Freilig H. Acute CNS infection by *Trypanosoma cruzi* (Chagas' disease) in immunosuppressed patients. Neurology 1990, 40:850-851.
25. Lisbôa AC. Sobre a forma congênita da doença de Chagas: estudo anatomo-patológico de 6 casos. Rev Inst Med Trop São Paulo 1960, 2:319-334.
26. Lopes ER, Chapadeiro E, Tafuri WL, Prata AR. Doença de Chagas. In Chapadeiro E, Lopes ER, Raso P, Tafuri WL (eds): Bogliolo Patologia. Ed 4 Rio de Janeiro: Guanabara Koogan, 1987, p 1047-1065.
27. Lundeberg KR. A fatal case of Chagas' disease occurring in a man 77 years of age. Am J Trop Med Hyg 1938, 18:185-196.
28. Mattosinho-França LC, Fleury RN, Ramos HA Jr, Lemos S de, Melaragno Filho R, Pasternak J. Moléstia de Chagas crónica associada a leucemia linfática: ocorrência de encefalite aguda como alteração do estado imunitário. Arq Neuro-Psiquiatr (São Paulo) 1969, 27:59-66.
29. Menezes AC, Lopes ER, Chapadeiro E. Estudo anatomopatológico sistematizado de encéfalos de chagásicos crônicos falecidos subitamente. Rev Inst Med Trop São Paulo 1988, 30:441-442.
30. Monteverde DA, Taratuto AL, Lucatelli N. Meningoencefalitis chagásica aguda en pacientes inmunosuprimidos. Rev Neurol Arg 1976, 2:260-266.
31. Noetzel H von, Elejalde P, Dias E. Über die Gehirnveränderungen bei der Chagaskrankheit. Z Tropenmed Parasitol 1958, 9:27-32.
32. Pittella JEH. Ischemic cerebral changes in the chronic chagasic cardiopathy. Arq Neuro-Psiquiatr (São Paulo) 1984, 42:105-115.
33. Pittella JEH. Brain involvement in the chronic cardiac form of Chagas' disease. J Trop Med Hyg 1985, 88:313-317.
34. Queiroz AC. Tumor-like lesion of the brain caused by *Trypanosoma cruzi*. Am J Trop Med Hyg 1973, 22:473-476.
35. Queiroz AC. O envolvimento do sistema nervoso central em algumas doenças parasitárias. J Bras Med 1976, 30:26-38.
36. Queiroz AC. Estudo das alterações encefálicas em casos humanos agudos da doença de Chagas. Rev Pat Trop 1978, 7:13-22.
37. Queiroz AC. Estudo anatomopatológico do encéfalo na forma crónica da doença de Chagas. Rev Pat Trop 1978, 7:135-145.
38. Rivero I, Boris E, Moravenik M, Morales JA, Gomez ME, Rosas JM. Leucemia aguda y enfermedad de Chagas: estudio de 4 casos. Medicina 1975, 35:73-78.

39. Rubio M, Howard J. Congenital Chagas' disease: II. Pathological findings in nine cases. *Bol Chil Parasitol* 1968, 23:113-121.
40. Scaravilli F. Parasitic and fungal infections of the nervous system. In Hume Adams J, Corsellis JA, Duchen LW (eds): *Greenfield's Neuropathology*. Ed 4. London: Edward Arnold, 1984, p 304-337.
41. Sevelever G, Taratuto AH, Carreras MC de las, Leiguarda R, Nogues M. Catatonia secondary to acute Chagas' encephalitis. *J Neurol Neurosurg Psychiatry* 1987, 50:1244.
42. Sternberger LA, Hardy PH, Cuculis JJ, Meyer HG. The unlabeled antibody-enzyme method of immunocytochemistry: preparation and properties of soluble antigen-antibody complex (horseradish peroxidase-antihorseradish peroxidase) and its use in identification of spirochetes. *J Histochem Cytochem* 1970, 18:315-333.
43. Teixeira AR, Roters FA, Mott KE. Acute Chagas' disease. *Gaz Méd Bahia* 1970, 3:176-186.
44. Teixeira ARL. Chagas' disease: trends in immunological research and prospects for immunoprophylaxis. *Bull WHO* 1979, 57:697-710.
45. Torres CM. A tripanosomose americana e a sua anatomia patológica. *Fol Méd* 1923, 4:25-29.
46. Vianna G. Contribuição para o estudo da anatomia patológica da «Moléstia de Carlos Chagas». *Mem Inst Oswaldo Cruz* 1911, 3:276-294.