

MACHADO-JOSEPH DISEASE OF AZOREAN ANCESTRY IN BRAZIL: THE CATARINA KINDRED

NEUROLOGICAL, NEUROIMAGING, PSYCHIATRIC AND NEUROPSYCHOLOGICAL FINDINGS IN THE LARGEST KNOWN FAMILY, THE «CATARINA» KINDRED

J. RADVANY *, C.H.P. CAMARGO **, Z.M. COSTA ***, N.C. FONSECA ****,
E.D. NASCIMENTO *****

SUMMARY — At the moment 9 seemingly independent families with the clinical diagnosis of MJD are known in Brazil. The largest family tree of Azorean ancestry contains 622 individuals in 9 generations. 236 were examined, 39 found to be affected by two examiners. Phenotypes I, II and III were expressed by 12, 23 and 4 patients with age of onset by phenotypes being 10-48, 14-54 and 30-55 respectively. Although clinically more severe, juvenile onset type I disease did not show as severe a ponto-mesencephalic atrophy on MRI as the father with type II disease of similar symptomatic duration. None of the 8 patients examined with MRI showed olivary atrophy or pallidal abnormalities. 12 affected and 23 at risk were evaluated with neuropsychological tests. Attention was normal in both groups. Verbal memory scores were below normal in the affected and there was greater decay with time than in the risk group. Both scored below normal in identifying silhouettes and constructional praxis. Visual memory scores were well below normal for both, with many rotations but no omissions or confabulations. A peculiar pattern of multiplying internal details called «the fly-eye effect» was observed in 6 affected and 8 at risk. Defective color distinction when multiple colors presented close to each other, in face of proper naming of individual colors («color simultagnosia»), was looked for in 29 people. 4/10 affected and 4/19 at risk showed this phenomenon. Cognitive dysfunctions in this MJD family are prominent in the sphere of vision. Whether they constitute an early manifestation in those at risk and thus serve as a clinical identifier of the illness is yet to be established. Depression was looked for in the history of the family with DSM III-R criteria and an attempt at quantification with the Montgomery-Asberg Rating Scale. There was no significant quantitative difference between affected and at risk. Once undeniably symptomatic however, the patients had no, or less depression than themselves before or at the early stages of the illness. Covert depression was appropriately excluded. Fully established MJD in this family seemed to exert a protective effect from depression.

KEY WORDS: Machado-Joseph disease, MRI, neuropsychology, visual memory, color naming, depression.

Doença de Machado-Joseph de ascendência dos Açores no Brasil: a linhagem Catarina. Achados neurológicos, de neuroimagem, psiquiátricos e neuropsicológicos na maior família conhecida, a linhagem «Catarina»

RESUMO — Há, até o momento, notícia de 9 famílias não aparentadas com o diagnóstico clínico de doença de Machado-Joseph (MJD) no Brasil. Esta é a maior família do mundo

From the: Departments of Neurology and Neuroimaging, Hospital Israelita Albert Einstein, São Paulo (*) MD; Neuropsychology Section, Division of Neurosurgery of the Hospital das Clínicas, Faculdade de Medicina da Universidade de São Paulo (HC, FMUSP) (**) BA; Social Services of the Children's Institute, HC, FMUSP (***); Instituto de Neurologia e Neurocirurgia, Hospital da Beneficência Portuguesa de São Paulo (****) MD; Department of Neurology, Hospital Marieta Konder, Itajaí SC (***** MD. Aceite: 20-agosto-1992.

Dr. João Radvany — Departamentos de Neurologia e Neuroimagem, Hospital Israelita Albert Einstein — Av. Albert Einstein 627, conj. 389 — 05652-000 São Paulo SP — Brasil.

com a doença. É de origem açoriana e contém 622 indivíduos na árvore genealógica. Destes, 236 foram examinados. Dois examinadores julgaram 39 como afetados. Respectivamente 12, 23 e 4 pacientes tinham os fenótipos I, II e III da doença, com idades no início variando entre 10-48, 14-54 e 30-55. Doença tipo I de início juvenil não mostrou atrofia tão severa nas imagens por ressonância magnética (RM) quanto doença tipo II de duração igual, demonstrando que severidade clínica e grau de atrofia não caminham paralelamente. Nenhum dos 8 pacientes examinados por RM tinha atrofia olivar ou anormalidades no globo pálido. Doze pacientes e 23 sob risco foram submetidos a avaliação neuropsicológica. A atenção foi normal em todos. Memória verbal estava pior nos doentes com maior decaimento com o tempo que nos sob risco. Ambos os grupos tiveram pontuação abaixo do normal na identificação de silhuetas e praxia construtiva. Memória visual estava bem abaixo do normal para ambos, com muitas rotações, porém sem omissões ou confabulação. Padrão peculiar de multiplicação dos detalhes internos, que denominamos o «efeito olho de mosca» foi visto em 6 doentes e 8 sob risco. Discriminação defeituosa de cores, quando múltiplas cores eram apresentadas lado a lado, na ausência de anomia ou cegueira a cores, caracterizável como «simultanagnosia a cores», surgiu como achado e foi pesquisada em 29 sujeitos. 4/10 doentes e 6/19 sob risco mostraram esta dificuldade. Conclui-se que disfunções cognitivas na esfera visual são proeminentes nesta família. Se seriam próprias da doença e manifestação precoce daqueles sob risco, está ainda para ser estabelecido. Depressão foi avaliada com critérios do DSM III-R e com o Montgomery-Asberg Depression Rating Scale. Não houve diferença entre doentes e sob risco. Entretanto, os pacientes tiveram menos depressão do que tinham tido antes ou nas fases precoces da doença. A MJD plenamente instalada parecia exercer efeito protetor da depressão.

PALAVRAS-CHAVE: doença de Machado-Joseph, ressonância magnética, neuropsicologia, memória visual, distinção de cores, depressão.

In 1977 two groups^{7,20} independently reached the conclusion that three previously described illnesses^{18,22,26} in American families of Azorean ancestry represented a single genetic entity. One group demonstrated the disease in several families in the Azores⁷, the other group described it in a fourth American family of Azorean background seen clinically and pathologically²⁰. Six other families of Azorean descent in Massachusetts were described subsequently²¹. In the ensuing years it became generally accepted that the disease, as diagnosed by clinical criteria alone⁸, did exist in populations other than those of proven Azorean ancestry^{11,15}. Pathologically proven non-Azorean cases were first reported from Japan²³. By consensus a single nosologic entity named Machado-Joseph disease (MJD) was established in 1986². The absence of mental changes had since been generally accepted as characteristic of the illness, although never substantiated by formal neuropsychological evaluations. Although generally held to be often depressed, patients with MJD have not been submitted to formal psychiatric investigations to substantiate this impression.

«Joseph-syndrome» was first presented in Brazil in 1984¹⁶. Although possibly MJD, it did not satisfy the clinical criteria¹⁵ for this diagnosis. In 1988 two additional families were presented¹⁹. The first publication of a family with this clinical diagnosis occurred in 1991²⁴.

Here we describe the largest Brazilian family with MJD, with clinical, neuroimaging, neuropsychological and psychiatric studies.

REPORT

History of the «Catarina» kindred

The kindred received its name from Manoel Antonio Vieira (A/K Catarina), II-1. He was the son born to one of three affected brothers who came from the Azores around the turn of the XIXth century. Catarina (nickname designating place of origin) was probably born on the island of Santa Catarina from where he moved to the Itajai river delta, where most of the family is still to be found. Catarina's grandson, IV-2 was his first descendant of whom we obtained documentary evidence (1887-1941). III-10 (Fig. 1) was said to be a descendant of Catarina or one of his siblings, raised by a family with the frequent surname

Machado. His descendants, following the family lore, identify themselves as cousins to the descendants of Catarina. We accepted the story as evidence because we obtained it from sources unknown to each other.

Diagnostic criteria

The «Catarina» kindred (Fig. 1) was diagnosed as having MJD obeying generally accepted criteria 2,15. Disequilibrium walking, enhanced by turning head to the sides, up or down, or by closing the eyes was considered the mildest symptom; tandem gait imbalance and nystagmus, the earliest signs for inclusion of an individual in the list of the affected.

Findings

A. Neurological findings and categorization

The «Catarina» family tree contains at the moment 622 individuals distributed in 9 generations. The pattern of inheritance of the illness is autosomal dominant (Fig. 1). 236 persons were examined and of these 39 were found to have the disease by two examiners. Nystagmus and ataxia attributable to alcohol, anticonvulsants or benzodiazepines were enough to exclude some subjects from the count of the affected. Table 1 lists age, age of onset, symptoms and signs of all the affected.

Phenotypes I, II, and III were expressed by 12, 23 and 4 patients, with the age of onset by phenotype being 10-48, 14-54 and 30-55 respectively. It is worth noting that the two examiners did not always agree on the predominance of involvement of one or other component of the motor system when attempting to fit patients into the three phenotypes. This was particularly true in the advanced cases, in which atrophy and increased tone predominated.

A few representative case histories are detailed at next. V-12 was seen at age 64. Gait imbalance started at age 40. Soon he started walking with feet set wide apart and later supporting himself against walls. At age 58 gait became impossible even when supported. Difficulty to speak and to swallow appeared in the course of the illness. In the last two months he started loosing urine. According to the wife he never did loose hope in the course of the illness. He always insisted in doing things himself within his progressive limitations. — We found him in his wheelchair, emaciated, immobile, but attentive and manifesting interest in the visit. With «yes» and «no» questioning he manifested anticipating pleasure with the coming visit of his grandchildren and some shows on TV. He did not complain of his fate. He was cooperative beyond the limits of his fatigability. His face was peculiar, showing muscle atrophy, hyper and dystonia: cheeks caved in and an almost permanent contraction of peri-oral and peri-orbital musculature, accentuated by action, shown as anarchic contractions of isolated muscle bundles, and lid retraction at attempts at visual fixation. This conveyed him a face with a permanently elongated shape. The eyes showed constant movements, often disconjugated. There was upgaze limitation on pursuit and disconjugate nistagmus on lateral or vertical attempts at gaze. Slow bundle contractions were seen on his tongue when protruded. Speech, almost incomprehensible, was hypophonic at the expense of great effort, slow and staccato. He often choked on saliva. Could not support himself standing, but at some instances sudden increase in extensor tone of the lower extremities lifted him off the wheelchair. The muscles were globally atrophied with conflicting tone; at times increased, at times paratonic. There were rare dystonic posturings of the limbs. Dismetria was intense in the upper limbs, untestable in the lower. Only the biceps and triceps tendon jerks were elicitable and the plantar reflexes were bilaterally extensor.

V-34 was seen at age 59. At age 38 his imbalance was clearly noted by the family but he denied it, because he did not want to retire. This became unavoidable at age 42. Difficulty to speak and to swallow came on slowly. He complained of double vision. He looked continuously perplexed due to an almost permanent lid retraction accentuated on upgaze which was slightly limited. Conjugate nystagmus was seen on all directions of gaze. Speech was hypophonic, guttural and halting. He could only stand supported, oscillating from side to side, only attempting an uncoordinated gait with a narrow base. Other motor findings were increased tone, at times flexor, at other times extensor, dystonic postures (foot inversion, flexed hallux), gross dysmetria, only bi, and tricipital tendon jerks and bilateral Babinski signs.

VI-91 son of V-34 was seen at age 29. Since age 10 his mother noticed him to be less well balanced than others. At age 14 this became obvious and by 18 he became unable to walk. Difficulty to speak, to swallow and double vision were additional complaints. — The

elongated face showed atrophy of the muscles, dystonic grimacing, anarchic fascicular contractions to voluntary movements and lid retraction on visual fixation. There was bilateral paresis of the abducting eye and limitations of vertical gaze. Attempts at lateral gaze evoked nystagmus. Speech required enormous effort because of dystonic interruptions. Confined to a wheelchair he was overall rigid with seemingly involuntary or intention evoked dystonic movements or postures that emptied themselves in transient hypotonia at times with athetoid movements. Finger to nose and heel to shin maneuvers were executed with great slowness and dystonic contaminations. Global muscle atrophy contrasted with generalized hyperreflexia, ankle clonus and extensor plantar responses.

V-53 was seen at age 52. Her father, presumed to be carrier of the gene died without sign of the illness at age 69. By age 30 she could stand up from the sitting position only with the support of her hands on her thighs. By age 42 she was restricted to a few steps at home and wheelchair anywhere else. On examination there was decreased muscle tone

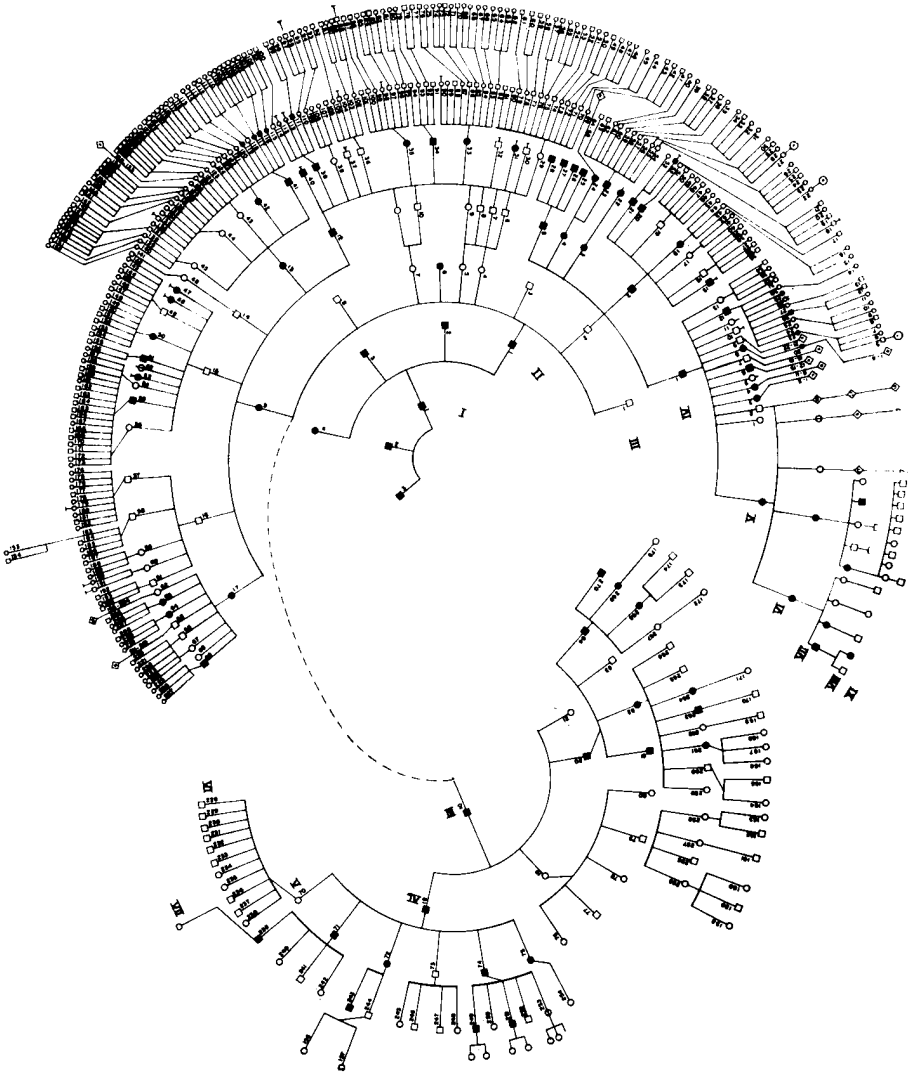


Fig. 1. Family tree of the Catarina kindred.

and severe atrophy in the lower extremities with almost no anti-gravitational muscle movements. When standing there was marked knee hyperextension and lumbo-thoracic lordosis. The upper limbs showed proximal atrophy and weakness. There was global arreflexia and no plantar response. Eye movements, speech and swallowing were normal.

V-55 (brother of V-53) was seen at age 49. The need to stand up with support on his thighs and gait imbalance were first noted at age 38. Difficulty to swallow and blurred vision followed. On examination there was short lasting, rapid, small amplitude, conjugate nystagmus on lateral gaze to either side. There were side to side oscillations of the upper body when standing. These became more marked when walking with wide base. There was dysmetria of limb movements, moderate global muscle atrophy, arreflexia and absent plantar responses.

V-23. Seen at age 65. Onset at age 55 with progressive gait imbalance. Double vision and swallowing difficulties supervened. On exam there was minimal conjugate lateral gaze nystagmus, dysarthria, dysphagia, lurching with based gait with a circumducting component, moderate limb dysmetria, hypotonia, global atrophy and fasciculations. Ankle jerks were absent and the plantar responses were extensor.

VI-23, daughter of V-12 was seen at age 44, five years after the onset of progressive gait and visual difficulties. Findings were slight lid retraction on visual fixation, nystagmus on conjugate lateral gaze, upgaze paresis, dysarthria, wide based gait, dysmetria greater with lower limb movements, absent ankle jerks and bilateral Babinski sign.

VI-95. Seen at age 37. At 32 started awakening by stereotyped nightmares in which he felt himself falling and crippled by the illness. He looked for well known signs but could not find any. He became severely depressed. At age 35 started with gait imbalance, muscle cramps for a few months and visual difficulties. Looking afar he would either see double or jumping images. Facing his family he still refuses to admit having the illness. On examination there was nystagmus on lateral gaze to either side and upgaze paresis. Gait was of narrow base oscillating the upper body side-to-side. Tandem gait was impossible. There was slight dysmetria of the lower limbs and the deep tendon jerks were brisk with extensor plantar responses.

VI-270 (son of V-84 dead at 47 after 19 years of illness). Seen at age 22. For the last three years progressive imbalance of gait when looking up while walking and checking the power lines in his work as inspector of an electric company. Gait imbalance also with ever decreasing amounts of alcohol, at the moment brought on by one can of beer. On examination bilateral conjugate lateral gaze evoked nystagmus and tandem gait as if he were balancing on a tightrope without loosing equilibrium.

B. Magnetic Resonance Imaging

Ten patients were submitted to MR examinations. The images of the brainstem were obtained with 3-5 mm thick sections perpendicular to the floor of the fourth ventricle. The inferior olives were always normally prominent. The pons was decreased in all by visual estimation alone. In VI-91 a 19 year long type I illness determined much greater physical disability but less brainstem atrophy, than a 21 year long illness in his father, V-34, with type II disease and less disability. This is the first documentation to the effect that severe incapacity due to extrapyramidal findings in juvenile type I MJD need not be accompanied by an atrophy as severe as the one seen in later illness of the same duration and less severe clinically but with more cerebellar signs in its course.

C. Psychiatric evaluations

Psychiatric interviews were conducted with 36 patients and 79 persons at risk. One patient was excluded because of large right frontal lobe lesion since age four and recent lateral medullary infarct with painful hemidysaesthesia. One person at risk was not included because of temporal lobe epilepsy related interictal behaviour problems. A quantitative estimation was obtained with the Montgomery-Asberg Depression Rating Scale ^{1,18}. Of a maximum score of 60, scores of 0 were registered in 17/36 patients (47%) and in 46/79 (57%) at risk. Scores rangind from 1-9 and 10-22 were respectively obtained by 15/36 and 4/36 patients (42 and 11%), as well as 25/79 and 5/79 persons at risk (31 and 6%). The overrepresentation of patients with the scores of 10-22 was explained by sleep disturbances⁵ and lack of motor initiative due to the illness, but computed in the scores. It is to be noted that there were no scores above 22. Qualitative estimation of the present state of mood and history of

individuals revealed frequent depressive episodes before the installation of the full blown clinical picture of the illness. Once the affection became undeniable, depression turned out to be rare. Only one affected and two at risk had committed suicide. Alcoholism often ceased as the person became ataxic. One living patient was just coming out of a five year long depression as she stopped denying her 15 year long illness. One woman had 9 post-partum depressions. Her tenth child was born when already affected. There was no depression then or thereafter. All the patients were however demoralized proportionally to their disability and they called this feeling «depression». When asked if they felt depressed the answer was almost always affirmative. None were however anhedonic and most had normal libido, having intercourse far into many years of illness.

D. Neuropsychological examination

Thirty-five subjects (12 affected and 23 at risk) were evaluated with neuropsychological tests: visual perception (Luria), color identification, digit span, logical memory, visual reproduction (WMS-R), verbal fluency (FAS), constructional ability, Rey auditory verbal learning test, proverbs, similarities (WAIS) 15. Age varied between 24-63 in the affected and 18-64 in the others. Education ranged between 4 years elementary to college level. Whenever possible the findings were quantified. The affected and the at risk groups were compared to each other and to the normal population. The following salient features deserve mention:

1. The subjects were always alert and very cooperative. There were no fluctuations in the engagement in the tasks even when realizing their own difficulties.
2. Attention span was under normal for both affected and at risk. In spite of this, the capacity to maintain attention and self-monitoring during verbal tasks, as measured by the FAS, was above normal in the at risk and only slightly sub-normal in the affected.
3. In verbal memory people at risk did not differ from the general population when the age distribution was taken into account. The score of the affected was below normal,

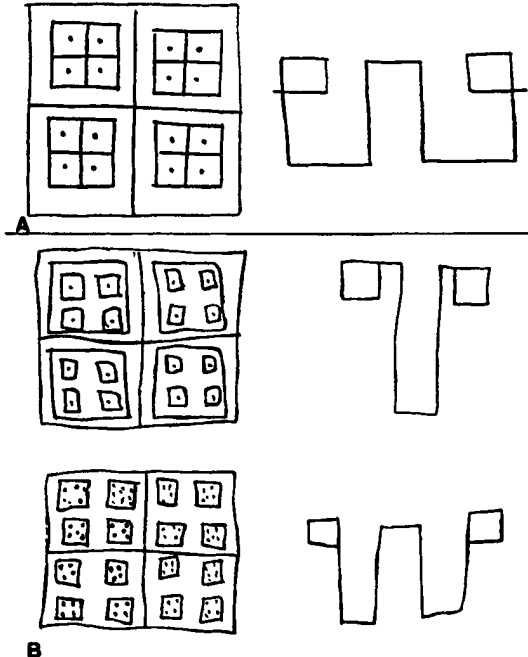


Fig. 2. A. Normal reproduction of the model from memory. B. Examples illustrating defective reproduction from memory: multiplication of internal details and rotation.

decay between immediate and delayed recall was greater in the affected. There were no confabulations.

4. Visual functions and constructional praxis scored below normal for both the affected and at risk. In visual perception the difficulties in both groups was in identifying silhouettes against dark background. Copy of the cube was under normal for both groups.

5. Visual memory was under normal for both affected and at risk. There were rare omissions however, and no perseverations. Rotations were excessive in both groups. An unusual pattern of multiplying internal details (Fig. 2), which we called the «fly-eye effect», was seen in 14/33 of the examined (6 affected and 8 at risk). All were requested to memorize one drawing at a time and reproduce it immediately and 30 minutes later. There was surprisingly no decay between the immediate and delayed recall of the affected. They reproduced the drawings with the exact same errors. Some patients were tested again and requested «to copy» the same models, which they did without error, thus excluding perceptual or praxis difficulties within this task.

6. Defective color discrimination became evident during the neuropsychological work-up. In 29/35 subjects this difficulty was specifically looked for. It was found in 4/10 affected and 6/19 at risk. Many claimed not to be able to identify all colors. There was no color blindness when tested with the Ishihara charts. Naming of individual colors was accurate when presented alone. On the other hand colors were named with much less precision, or not at all, when plates were shown with the simultaneous presence of multiple colors side by side. Oddly in most homes of people not examined neuropsychologically many of the affected were dark sunglasses and the TV was either black-and-white or had the colors turned off. By these maneuvers these people claimed to have better image discrimination.

COMMENTS

A. Level of diagnostic certainty

Ideally the diagnosis of autosomal dominant hereditary ataxias with multi-system degeneration should rely on the identification of the genetic marker of the disease. As of this writing this is only feasible in chromosome 6 linked spinocerebellar ataxia (SCA1)^{13,27}. Short of this precision, the next level of diagnostic certainty lies in the pathological demonstration of the involved nuclei and tracts, whenever possible with clinico-pathological correlations. Diagnosis on clinical grounds alone, even when entire families are examined, may lead to mistakes because of the overlap of clinical findings between the various nosological entities. Occasionally however, some of the clinical features are so striking that they determine a distinct disease entity within a generic pathological label^{3,8,25}. Short of pathology MRI may bridge some of the gaps in the diagnosis of these families, but standardized, quantitative studies of brainstem with thin sections perpendicular to its long axis are still lacking. Images so far contribute only slightly to clinical reasoning and are never diagnostic by themselves.

One can be fairly confident of the diagnosis of MJD in the Catarina kindred. The clinical criteria^{2,15} were satisfied, there was no early pontine and cerebellar atrophy on MRI as seen in OPCA Menzel type¹², slow saccades as defined by Wadia and Swami²⁵, or retinal degeneration^{8,23} that would have pointed to specific disorders in this group of illnesses. There was no choreo-athetosis as seen in dentato-rubro-pallido-luysian atrophy¹⁰. SCA1, although on OPCA may offer the greatest difficulty in differential diagnosis when genetic studies are unavailable. In SCA1 olivary atrophy by MRI may not be seen, as indeed happened in advanced illness of a patient from a family of Portuguese ancestry presumed to have MJD¹⁹ but which turned out to have positive chromosome 6 linkage (G. Rouleau, personal communication). Retrospectively, we had to conclude that the dystonic component in two advanced cases in that family had been overrated in their clinical descriptions¹⁹. Overvaluing one clinical sign from the many, mostly when they often modify each other is frequent in ataxic multisystem degenerations. Indeed, the same dystonic manifestations seen on video at the Workshop for Research Initiatives on MJD at the NINDS in June 1991, when described by the various neurologists experienced in MJD, gained different verbal emphasis. This again raised the appropriate question

as to how much we should rely on clinical criteria alone for the diagnosis of ataxic multisystem degeneration. We strongly feel that in the absence of a severe spastic/dystonic phenotype in a young individual the clinical diagnosis of MJD should receive only the cautious qualification as «possible». On the other hand dominant multisystem degenerations of Portuguese ancestry with only spastic/dystonic phenotype¹⁶ do not fulfill the clinical criteria^{2,15} for the diagnosis of MJD. Although we have no pathological confirmation in the Catarina kindred, we are confident of no mistakes with SCA1, because this has been ruled out by genetic linkage analysis⁴.

B. Depression

Depression in this family with comparable rates between affected and at risk is contrary to what would be expected in patients with progressive diseases of the motor system. The neuropsychological examination revealed no dementia, unconcern or neglect as one sees in covert depression of organic diseases of the brain. In the patients of the «Catarina» kindred the illness once established seemed to exert a protective effect from depression. Whether this would be due to dysfunction in vast networks or lesions verifiable in circumscribed nuclei is still to be looked for in future neuropathological studies, if these findings are confirmed in other families with proven MJD.

C. The «fly-eye effect» and «color simultanagnosia»

The most interesting findings in the neuropsychological testing were in the realm of visual functions, notably the «fly-eye effect» in visual reproduction from memory with intact copying of the same model. One tentative explanation would be that visual reproduction from memory would call for a kinesthetic component in memory which in these patients would be impaired because of the defective visual scanning due to complex oculomotor defects⁹. In other words the interference pattern generated by the visual scanning disorder resulted in a defective retention of visual memory traces. Oddly enough not all the patients and many subjects at risk exhibited this deficit. Would this mean that we were detecting an early manifestation of the illness by documenting the «fly-eye effect» in a person at risk, without clinically detectable oculomotor findings? Could it be that some patients only inherit a «fragment» of the disease or are we dealing with two independently inherited factors?

We also attributed the defective color discrimination to the eye movement disorder. The phenomenon, for its similarity called a «simultanagnosia for colors» could be explained by superimposition of the undesirable retinal afterimage with the desirable image resulting in an only approximate «reading» of the color to name as the net result.

We conclude that the generally held notion that MJD is not accompanied by any mental changes needs to be reviewed with neuropsychological methodology in other families. The mechanisms of the frequent «fly-eye effect», an otherwise very rare phenomenon in neuropsychological practice need to be further investigated. «Color simultanagnosia» as seen here is a phenomenon has never been characterized as such before. Crosscultural studies are also warranted to establish if there is indeed a biologically protective role of the illness against depression.

Acknowledgements — We are indebted to the Hospital Israelita Albert Einstein of São Paulo for the MRI studies, the Hospital Marieta Konder of Itajai for providing the space for the clinics, Dr. Guy Rouleau of the Montreal General Hospital for the genetic studies, Dr. Patrick MacLeod from the University of Kingston, Ontario for his kind guidance, and the Hotel San Remo of Camboriu for their support.

REFERENCES

1. Asberg M, Montgomery S, Ferris C, Schalling D, Sedvall G. A comprehensive psychopathological rating scale. *Acta Psychiatr Scand* 1978 (Suppl), 271:5-27.
2. Barbeau A, Roy M, Cunha L, de Vicente AN, Rosenberg RN, Nyhan WL, MacLeod PL, Chazot G, Langston LB, Dawson DM, Coutinho P. The natural history of Machado-

- Joseph disease: an analysis of 138 personally examined cases. *Can J Neurol Sci* 1984, 11:510-525.
3. Bergstedt J., Johansson M, Muller G. Hereditary spastic ataxia with central retinal degeneration and vestibular impairment: a clinical report on a family. *Neurology* 1962, 12:124-132.
 4. Carson WJ, Radvany J, Farrer LA, Vincent D, Rosenberg RN, MacLeod PM, Rouleau GA. The Machado-Joseph disease locus is different from the spinocerebellar ataxia locus (SCA1). *Genomics* 1992, 13:852-855.
 5. Coutinho P. Neglected features of Machado-Joseph disease (Abstr) Research Initiatives in Machado-Joseph Disease. Bethesda MD: NINDS, June 3-4, 1991.
 6. Coutinho P, Andrade C. Autosomal dominant system degeneration in Portuguese families of the Azores Islands: a new genetic disorder involving cerebellar, pyramidal, extra-pyramidal and spinal cord motor functions. *Neurology* 1978, 28:703-709.
 7. Coutinho P, Calheiros JM, Andrade C. Sobre uma nova doença degenerativa do sistema nervoso central transmitida de modo dominante e afectando famílias originárias dos Açores. (Nota prévia). *O Médico* 1977, 82:1-3.
 8. Dawson DM, Feudo P, Zubick HH, Rosenberg R, Fowler H. Electrooculographic findings in Machado-Joseph disease. *Neurology* 1982, 32:1272-1276.
 9. Foster JB, Ingram TTS. Familial cerebro-macular degeneration and ataxia. *J Neurol Neurosurg Psychiatry* 1962, 25:63-68.
 10. Goto I, Tobimatsu S, Ohta M, Hosokawa S, Shibasaki H, Kuroiwa Y. Dentatorubro-pallydoluysian degeneration: clinical, neuro-ophtalmologic, biochemical and pathologic studies on autosomal form. *Neurology* 1982, 32:1395-1399.
 11. Heaton EB, Brust JCM, Kerr DR, Resor S, Penn A. Presumably Azorean disease in a presumably non-Azorean family. *Neurology* 1980, 30:1084-1089.
 12. Iwabuchi K. Clinicopathological study on autosomal dominant forms of spinocerebellar degeneration (SCD) with special reference to Menzel's disease, hereditary ataxia linked to SCA1 and Japanese Machado-Joseph disease in Japan (Abstr). Research Initiatives in Machado-Joseph Disease. Bethesda MD: NINDS, June 3-4, 1991.
 13. Jackson JF, Currier RD, Terasaki PI, Morton NE. Spinocerebellar ataxia and HLS linkage: risk prediction by HLA typing. *N Engl J Med* 1977, 296:1138-1141.
 14. Lezak MD: Neuropsychological assesment. New York: Oxford Univ Press, 1983.
 15. Lima L, Coutinho P. Clinical criteria for diagnosis of Machado-Joseph disease: report of a non-Azorean family. *Neurology* 1980, 30:319-322.
 16. Lisboa MFS, Mariotto GSS. Síndrome de Joseph: observação em uma família (Abstr). *Arq Neuro-Psiquiat (São Paulo)* 1984 (Suppl), p 45.
 17. Montgomery S, Asberg M. A new depression scale designed to be sensitive to change. *Br J Psychiatry* 1979, 134:382-389.
 18. Nakano KK, Dawson DM, Spence A. Machado disease: a hereditary ataxia in Portuguese immigrants to Massachusetts. *Neurology* 1972, 22:49-55.
 19. Radvany J, Avila JO, Gabbai AA, Bacheschi LA. Doença de Machado-Joseph no Brasil: o relato das primeiras duas famílias (Abstr). *Arq Neuro-Psiquiat (São Paulo)* 1988 (Supl), 46B.
 20. Romanul FCA, Fowler HL, Radvany J, Feldman RG, Feingold M. Azorean disease of the nervous system. *N Engl J Med* 1977, 296:1506-1508.
 21. Romanul FCA, Radvany J, Fowler HL, Tarsy D. Azorean disease of the nervous system: report of six additional families (Abstr). *Ann Neurol* 1978, 4:183.
 22. Rosenberg RN, Nyhan WL, Bay C, Shore P. Autosomal dominant striato-nigral degeneration: a clinical, pathological and biochemical study of a new genetic disorder. *Neurology* 1976, 26:703-714.
 23. Sakai T, Ohta M, Ishino H. Joseph disease in a non-Portuguese family. *Neurology* 1983, 33:74-80.
 24. Teive HAG, Arruda WO, Tevisol-Bittencourt PC. Doença de Machado-Joseph. *Arq Neuro-Psiquiat (São Paulo)* 1991, 49:172-179.
 25. Wadia NH, Swami RK. A new form of heredofamilial spinocerebellar degeneration with slow eye movements (nine families). *Brain* 1971, 94:359-374.
 26. Woods BT, Schaumburg HH. Nigro-spino-dentatal degeneration with nuclear ophtalmoplegia: a unique and partially treatable clinicopathological entity. *J Neurol Sci* 1972, 17:149-166.
 27. Zoghbi HY, Pollack MS, Lyons LA, Ferrel RE, Daiger SP, Beaudet AL. Spinocerebellar ataxia: variable age of onset and linkage to human leukocyte antigen in a large kindred. *Ann Neurol* 1988, 23:580-584.