

ISOLATED AND PAINLESS INFRASPINATUS ATROPHY IN TOP-LEVEL VOLLEYBALL PLAYERS

REPORT OF TWO CASES AND REVIEW OF THE LITERATURE

CÉLIA HARUMI TENGAN*, ACARY S. BULLE OLIVEIRA*, BEATRIZ HITOMI KIYMOTO*,
MARIA DA PENHA ANANIAS MORITA*, JOVANY L. ALVES DE MEDEIROS*,
ALBERTO A. GABBAI*

SUMMARY — Isolated and painless infraspinus atrophy and weakness are described in two top-level volleyball players. EMG revealed isolated denervation of the infraspinus muscle. One athlete continued playing and his clinical features have not changed. The other recovered her muscle bulk and strength after stopping playing. These findings were attributed to intense activity of the shoulder joint, without any direct trauma. On clinical grounds, we did not consider these cases as true examples of entrapment neuropathy. Pathogenesis was related to traction of the distal branch of the suprascapular nerve during the act of reception of the ball («Manchete»).

KEY WORDS: volleyball, infraspinus muscle, atrophy.

Atrofia isolada e não dolorosa do músculo infraespinhoso em jogadores de voleibol: descrição de dois casos e revisão da literatura.

RESUMO — Atrofia isolada e não dolorosa do músculo infraespinhoso e fraqueza são descritas em 2 jogadores de voleibol. EMG mostrou desnervação isolada do músculo infraespinhoso. Um dos atletas continuou jogando e não foi notada qualquer alteração no quadro clínico. O outro, após cessar as suas atividades esportivas, recuperou progressivamente a força e o trofismo muscular. Estes dados sugerem íntima relação entre comprometimento do músculo infraespinhoso e atividade intensa da articulação do ombro, mas sem qualquer trauma direto. Não consideramos estes casos como verdadeiros exemplos de neuropatia por compressão. Patogênese foi relacionada à tração dos ramos distais do nervo supraescapular durante o ato da recepção da bola («Manchete»).

PALAVRAS-CHAVE: voleibol, músculo infraespinhoso, atrofia.

Injury to the nervous system can occur in almost any sport and may involve any level of the nervous system. Peripheral nerves are vulnerable to various types of trauma. They may be injured in any sport, be it competitive or recreational. The following cases are examples of unusual nerve injury in the upper extremities related to athletic activities.

CASE REPORTS

Case 1 — SLM a 19 year old right handed female professional volleyball player had been alerted by teammates to right scapular trophy ten months before being examined. She was still able to play, without any changes in her performance, and denied numbness, pain and cervical symptoms. The patient had no history of major illness, other injuries, precipitating event, or any history of neuromuscular dysfunction. Examination revealed a well-nourished woman in a good physical condition, except for marked atrophy of the right infraspinus muscle and weakness of external rotation of the right shoulder joint. There were no sensory changes or other neurological signs. Active and passive ranges of motion of the shoulders

*From the Department of Neurology, Neurosurgery and Experimental Neurology of Escola Paulista de Medicina, São Paulo. Aceite: 03-julho-1992.

and cervical spine were full and painless. X-Ray films of the cervical, dorsal spine and right shoulder appeared normal. Electromyographic examination (EMG) of the right infraspinatus muscle showed spontaneous activity, increased potential duration and polyphasic potentials. Electric stimulation at Erb's point revealed low amplitude, dispersed evoked motor response with prolonged latency to the corresponding infraspinatus muscle, whereas those from the supraspinatus, deltoid and rhomboid major were all normal. She continued playing volleyball for four years and no changes in the bulk of the muscle or strength were noted. One year ago, because of a ligament lesion in the ankle, she had to stop playing. Since then, she has noticed improvement in the atrophy and weakness of her right shoulder.

Case 2 — FV, a 22 year old right handed man professional volleyball player was seen with a complaint of painless asymmetry of the posterior scapular musculature. The patient denied any change in his performance, besides of restricted inability to lift any weight overhead when the right arm was abducted. There was no precipitating event and his past medical history was negative. Examination revealed a marked wasting in the region of the right infraspinatus fossa, and the right infraspinatus muscle was very atrophic and weak (Fig. 1 and 2). The supraspinatus muscle was normal on examination. There was no winging of the scapula. No sensory changes could be detected. Active and passive ranges of motion of the shoulders and cervical spine were full and painless. X-Ray films of the cervical, dorsal spine and shoulder revealed no abnormalities. EMG showed an isolated denervation of the infraspinatus muscle. The nerve latencies were normal to the supraspinatus muscle and prolonged to the infraspinatus muscle. The patient was treated conservatively and continued his volleyball activities. His strength and scapular muscle bulk have not changed.

COMMENTS

The clinical features and the EMG findings in these two top-level volleyball players were compatible with partial denervation of the right suprascapular nerve branch to the infraspinatus muscle. The absence of sensory findings and pain, distribution of motor impairment, normal deep tendon reflexes, and isolated denervation of the infraspinatus muscle excluded primary myopathy, radiculopathy, brachial plexus lesion, Parsonage-Turner syndrome and rotator cuff injury, the major alternatives in the differential diagnosis. The progression of symptoms favored a chronic neuropathy.

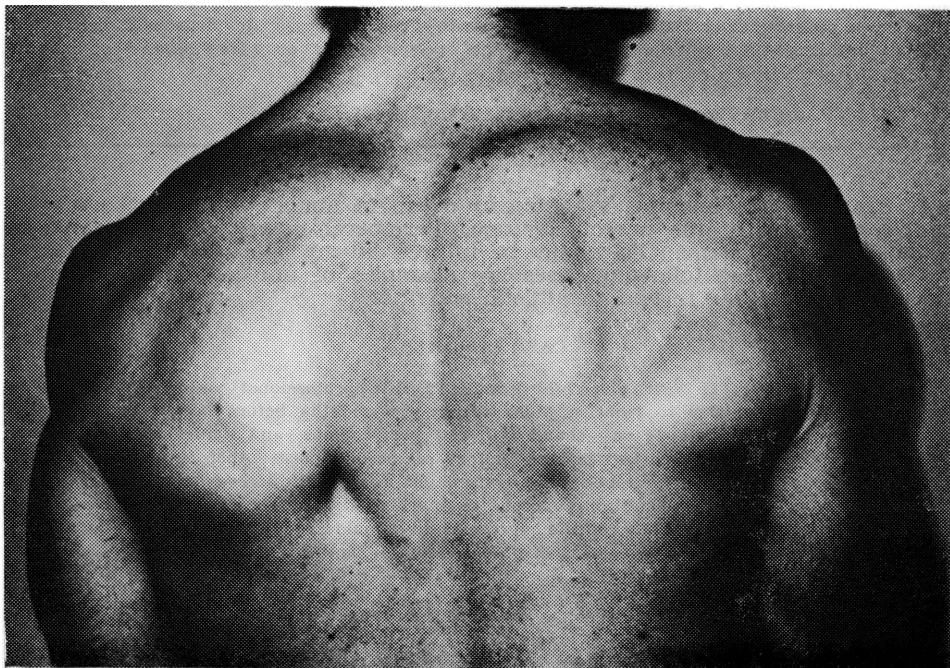


Fig. 1. Isolated infraspinatus atrophy of the right shoulder (Case 2). Posterior view.

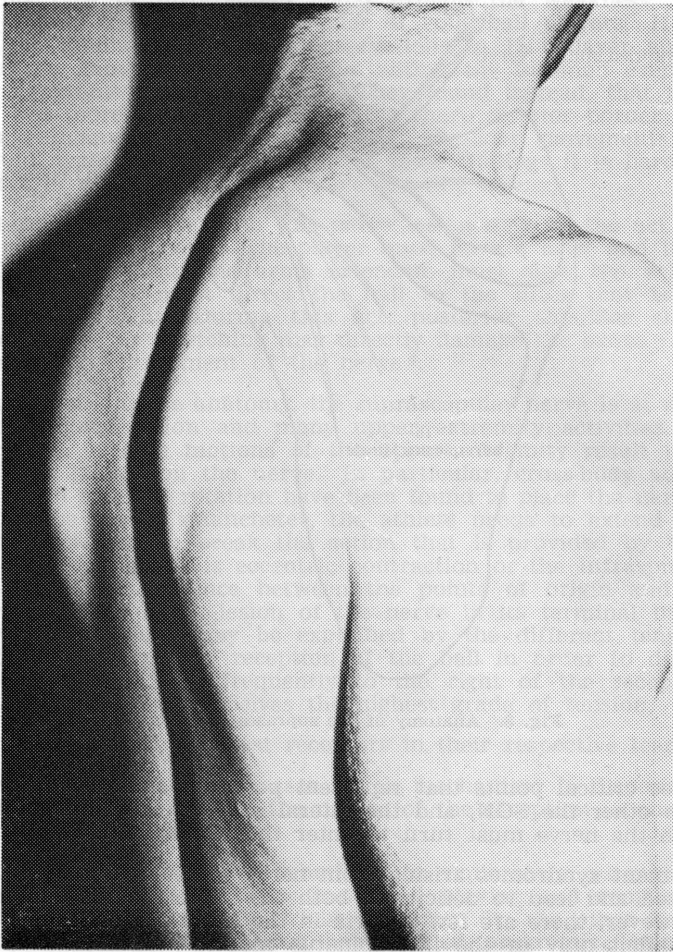


Fig. 2. Isolated infraspinatus atrophy on the right shoulder (Case 2). Lateral view.

Before reviewing the different mechanisms which may affect the suprascapular nerve, one must be aware of certain anatomic and kinesiologic aspects of the shoulder and suprascapular nerve.

The mixed suprascapular nerve (C-4 to C-6) arises from the upper trunk of the brachial plexus. It courses laterally, deep to the trapezius and omohyoid muscles, to enter the supraspinous fossa via the suprascapular notch (SSN), passing under the transverse scapular ligament. The suprascapular artery and vein do not pass through the notch. The suprascapular nerve continues deep to the supraspinatus muscle, which it innervates with two branches, also supplying sensory articular filaments to the glenohumeral and acromioclavicular joints. It courses laterally to the lateral edge of the spine of the scapula, then turns around it to course medially in the infraspinous fossa, deep to the infraspinatus muscle. In 50% of subjects an osteofibrous orifice (Spinoglenoid notch, SGN) is found enclosed by the spinoglenoid ligament, an aponeurotic band that separates the supraspinatus and the infraspinatus muscles¹ (Fig. 3). Two fixed sites and three critical points have been identified along the course of the suprascapular nerve. It is fixed at its origin from C5 or the upper trunk of the brachial plexus and its termination in the infraspinatus. Between these two

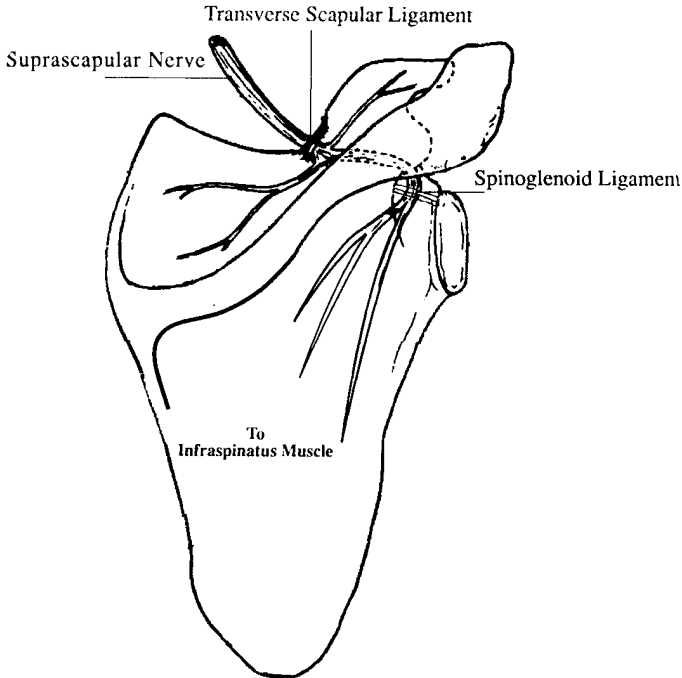


Fig. 3. Anatomy of the suprascapular nerve.

sites are three critical points that represent potential sites of injury, one being the SSN, the other the SGN, and the lateral edge of the spine of the scapula, around which the nerve must turn to enter the infraspinatus.

Entrapment syndromes arising from nerve pressure at the SSN have been well recognized and lead to deficits in both the supraspinatus and infraspinatus muscles. However, there are few reports in the literature of lesions at the SGN that cause deficit only in the infraspinatus muscle². Liveson et al.⁶ reviewed all the 10 isolated infraspinatus muscle atrophy patients previously reported and joined more three cases. These included weight lifters, a baseball player, a fencing instructor, a racketball player, and a 79 year old woman who performed arm pulley exercises. In all cases, there was a relationship with strenuous exercise and pain was a common complaint. Compression of the nerve was identified in some cases: ganglionic cyst in two cases, and a hypertrophic spinoglenoid ligament in another.

At first, when we examined Case 1, we thought that the pathogenesis could be attributed to the act of female defense in volleyball where the athlete frequently is obliged to fall on the ground on her back and roll backward. That might cause a lesion on the shoulder with suprascapular nerve injury. But, after examining Case 2, a man, another explanation was needed.

Picot⁷ hypothesized that the nerve could be injured during extreme movements of the shoulder as the nerve slides back and forth through the foramen. Ferreti et al.³ and Holzgraefe et al.⁵ noted a high frequency of asymptomatic suprascapular nerve injuries, in its distal branch, in top-level volleyball players. Ferreti et al. attributed these findings to repeated stress due to stretching of the nerve during the sportive activity. They related the pathogenesis to the only two asymmetrical and powerful movements that are typical of the game: the service and the smash. Biomechanically, the smash and the service are similar, but this latter activates more intensely the infraspinatus muscle and this may cause lesion of the supraspinatus nerve in its terminal branch by

traction. This type of involvement could explain the weakness, atrophy and absence of pain in the dominant shoulder of volleyball players. However, Rengachary et al.⁸ conducted anatomic observations in 15 cadaver specimens and did not find any movement of the nerve within the foramen even with movements at the extreme range of motion. They found instead, that the suprascapular nerve was more closely opposed to the sharp inferior border of the transverse scapular ligament with three different shoulder movements: depression, retraction, and hyperabduction. Because of these findings it is hard to consider only the serve in volleyball as responsible for this lesion.

An alternative hypothesis to this nerve lesion may be the act of reception of the ball named «Manchete». The player must have a brief and instantaneous contact with the ball with the arms extended, must slow the velocity of the opponent's serving and must direct the ball to the lifter that is located frequently to his/her right. During this act, posterior shoulder structures are severely stretched. This stretching may directly damage the axons (axonotmesis) even if there is no entrapment of the nerve⁴.

Because of its unique anatomy, the suprascapular nerve is at risk of injury by both direct compression and many upper extremity activities. Due to its circuitous course, specific motions of the upper extremity result in alterations in tension being placed on the nerve. In particular, cross-body adduction, forward flexion, and external rotation have been found to place the nerve at highest risk². During the act of «Manchete», the athlete needs to extend the arms in adduction, to cock and to break the action that is provided by the posterior muscles of the shoulder. This eccentric contraction of the infraspinatus that is required increases the distance between the points of origin and termination of the nerve and may cause lesion of the nerve in its terminal branches. The unilaterality of the injury may be explained by the different tension between the two shoulders during the reception of the ball in order to direct the ball to the lifter that is located frequently to the right of the receptor. In this situation the right shoulder receives the highest grade of tension.

Our two cases were the best receptors in their respective teams.

It is hard to tell in these cases which mechanism is responsible for the nerve injury, but we assume that the nature of the reception is one of the keys to the pathogenesis of the lesion.

Our two patients were not submitted to exploratory surgery mainly due the absence of pain. Patient 2 has continued playing and remained with the same atrophy and weakness in his right shoulder. On the other hand, Patient 1 stopped her volleyball activities and has verified progressive improvement in both the atrophy and weakness of the infraspinatus muscle. These findings suggest that the atrophy and weakness of this muscle in our volleyball players are not caused by a true entrapment neuropathy.

REFERENCES

1. Aiello I, Serra G, Traina GC, Tugnoli V. Entrapment of suprascapular nerve at spinoglenoid notch. *Ann Neurol* 1982, 12:314-316.
2. Black KP, Lombardo JA. Suprascapular nerve injuries with isolated paralysis of the infraspinatus. *Am Sports Medicine* 1990, 18:225-229.
3. Ferreti A, Cerullo G, Russo G. Suprascapular neuropathy in volleyball players. *J Bone Joint Surg* 1987, 69a: 260-263.
4. Hadley MN, Sonntag UKH, Pittman HW. Suprascapular nerve entrapment: a summary of seven cases. *J Neurosurg* 1986, 64:843-848.
5. Holzgraefe M, Klingelholfer J, Eggert S, Benecke R. Zor chronischen Neuropathie des n. suprascapularis bei Hochleistungssportlern. *Nervenarzt* 1988, 59:545-548.
6. Liveson JA, Bronson MJ, Pollack MA. Suprascapular nerve lesions at the spinoglenoid notch: report of three cases and review of the literature. *J Neurol Neurosurg Psychiatry* 1991, 54:241-243.
7. Picot C. Neuropathie canalaire du nerf sussescapulaire. *Rheumatologie* 1969, 21:367-376.
8. Rengachary SS, Burr D, Lucas S, Hassanein KM, Mohn MP, Matzke H. Suprascapular entrapment neuropathy: a clinical, anatomical, and comparative study. Part 2: anatomical study. *Neurosurgery* 1974, 5:441-446.