

# CEREBELLAR ATROPHY RELATED TO CHRONIC EXPOSURE TO TOLUENE

## CASE REPORT

*BENITO PEREIRA DAMASCENO\*, EDUARDO MELLO DE CAPITANI\*\**

---

**SUMMARY** - A 31-year-old woman presented slowly progressing ataxia and neurasthenic symptoms after 14-year occupational exposure to low concentration toluene vapour. Examination disclosed only cerebellar signs. Cognitive functions were normal except moderate visuo-spatial and constructive deficit. CT imaging showed severe pancerebellar atrophy without pathological signs in other brain structures. Two years after she was removed from workplace, CT imaging and ataxia showed no worsening, while visuo-constructive function improved. The authors warn against possible neurotoxic risk associated with this kind of exposure.

**KEY-WORDS:** cerebellar atrophy, organic solvent toxicity, toluene.

### **Atrofia cerebelar relacionada à exposição ocupacional crônica ao tolueno: relato de caso**

**RESUMO** - Uma mulher de 31 anos desenvolveu síndrome cerebelar e neurastênica, de evolução lentamente progressiva, após 14 anos de exposição ocupacional a vapores de tolueno em baixas concentrações. Os únicos achados do exame neurológico e neuropsicológico foram sinais cerebelares (severos) e déficit visuo-espacial e prático-construcional (moderado). A neuroimagem tomográfica mostrava acentuada atrofia pancerebelar, com preservação das outras estruturas cerebrais. Dois anos após interrompida a exposição, a ataxia e a neuroimagem (TC) estavam inalteradas, enquanto a função visuo-construcional havia parcialmente melhorado. Os autores chamam a atenção para o possível risco neurotóxico relacionado a esse tipo de exposição, numa tentativa de prevenção de casos semelhantes.

**PALAVRAS-CHAVES:** atrofia cerebelar, neurotoxicidade, solventes orgânicos, tolueno.

---

Toluene is a volatile organic solvent, constituent of thinner and various types of glue. Its neurotoxic effects have been observed mostly among glue sniffers<sup>8</sup>. The behavioural effects of acute intoxication are immediate and include initially euphoria, desinhibition, delusions or hallucinations and dizziness, and later other more severe signs of an acute encephalopathy. Complete reversion of this picture is seen among most intoxicated children, while adults tend to present persistent sequelae of encephalopathy, optic atrophy and cerebellar ataxia. Prolonged exposure can cause fatigue, difficulty in concentration, reduced memory, emotional lability, irritability, depression, personality change, headache, dizziness, as well as cerebellar, pyramidal and neuropathic signs. Neuroradiological examination can reveal cerebellar atrophy with widening of cortical sulci, subarachnoid cisternae and ventricles<sup>4</sup>. After the first reported case of cerebellar atrophy secondary to toluene sniffing<sup>6</sup>, many other case reports and epidemiological studies have been published<sup>1</sup>. In most of these cases, toluene was mixed with other neurotoxic substances and there were lesions of nervous structures other than the cerebellum<sup>4,7,8</sup>. Our case adds to some others in the literature in which toluene alone led to exclusively cerebellar damage.

---

Faculdade de Ciências Médicas (FCM), Universidade Estadual de Campinas (UNICAMP): \*Departament of Neurology; \*\*Department of Preventive and Social Medicine. Aceite: 10-julho-1993.

Dr. Benito Pereira Damasceno - Departamento de Neurologia, FCM/UNICAMP - Caixa Postal 6111 - 13081-970 Campinas SP - Brasil.

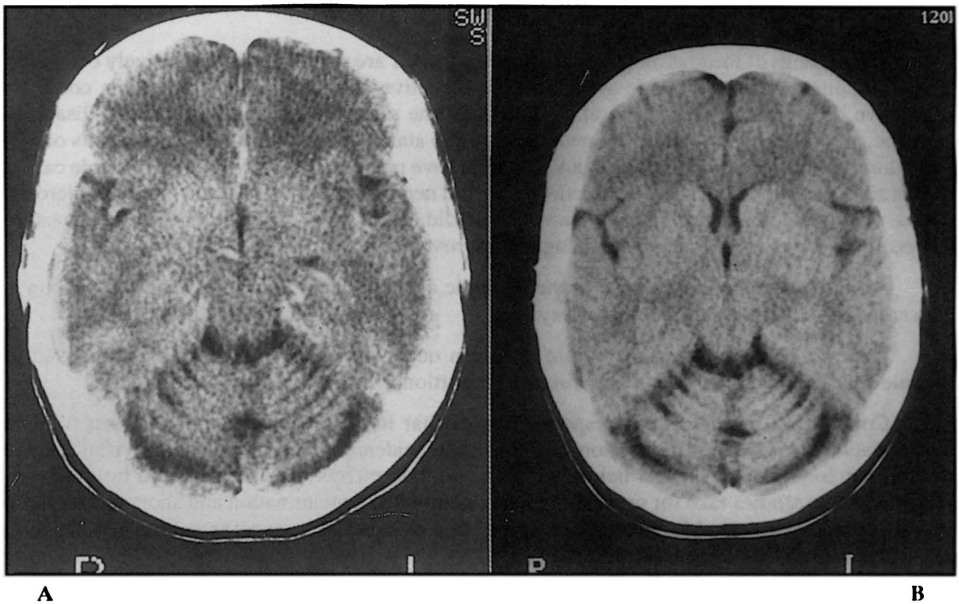


Figure 1. CT shows only marked pancerebellar atrophy (A). Control CT two years later remains unchanged (B).

This paper aims to warn against the possible neurotoxic risk associated with prolonged occupational exposure to low concentration toluene vapour.

### CASE REPORT

CFT, a 31-year-old woman came to our neurological clinic in May 1989 complaining of dizziness, progressive unsteadiness, visual blurring, headache, nervousness, irritability and auto-aggression for at least one year. She denied weight loss preceding or accompanying the disease. She had previously been healthy. There was no family history of neurological disease. She was unmarried and had first grade schooling. She worked at a factory where she controlled the quality and packed material for medical and hospital use. She had been exposed fourteen years to low concentration toluene vapour exhaled from a mixture with silicon. Neurological examination revealed severe cerebellar ataxia, bidirectional horizontal nystagmus, slight dysarthria and difficulty with visual fixation; general muscle strength, tendon reflexes, deep and superficial sensation, visual acuity and optic discs were all normal. Neuropsychological evaluation with Luria's test battery<sup>2</sup> and Folstein's MMSE<sup>3</sup> disclosed tension, poor concentration and impaired visuo-spatial and constructive ability; orientation in time and place, visual and verbal short-term memory, as well as intellectual functions (abstract interpretation of proverbs and problem solving) were unimpaired; she got a score of 30 on MMSE. Field investigation performed by our Division of Occupational Health at the patient's work-place revealed that toluene exposure occurred intermittently, at intensive periods and probably in low concentrations (toluene percentage in the mixture seemed not to have exceeded 5%). A sample of silicon collected was analysed with gas chromatography confirming the presence of toluene. No other neurotoxic substances or drug-addiction could be found. There were no other occupational or psychological factors nor domestic hobby that could explain the patient's complaints.

In May 1989 a computerized tomography (CT) showed severe pancerebellar atrophy. Complete blood count, serum electrophoresis and routine analysis of cerebrospinal fluid (CSF) were normal. CSF electrophoresis (August 1989) showed slight increase of beta<sup>-1</sup> globulin fraction (7.4 mg%), which normalised December 1990. IgG, IgA and IgM were not measured at this time, because these parameters were then not judged to be relevant for the differential diagnosis. No blood, urine or CSF tests for heavy metals were done, since the patient had not had any contact with this kind of toxic material. We did no measurement of toluene metabolites, since the patient came to us a long time after she had been dispensed from work. In February 1991, almost two years after the patient had been removed from her workplace, visuo-spatial and constructive function improved, while ataxia and CT imaging presented no change (Figura 1). Serum and CSF electrophoresis with measurement of immunoglobulins revealed only increase of CSF IgG (4.6 mg/dL; reference value 0.2 to 2.8 mg/dL). IgG index (0.56) and albumin ratio (5.23) were in the normal range.

## COMMENTS

The findings of the neurological examination and CT are pointing to an exclusively cerebellar lesion, although the neurasthenic syndrome and objective neuropsychological deficits could be suggestive of a more diffuse cerebral dysfunction. The visuo-spatial and constructive disability could be, at least partly, secondary to neurasthenia and ataxia of hands and eyes. The results of CT, laboratory testing and epidemiological investigation have practically discarded other possible causal factors such as alcoholism, chronic infection of central nervous system (CNS) and multiple sclerosis. On the other hand, the neurological picture and CT did not show any worsening after the exposure stopped; there was even a neuropsychological improvement.

All these data suggest toluene as the etiologic agent in the present case. As far as silicon is concerned, it is harmless to the nervous system<sup>5</sup>.

Increase of CSF IgG and albumin ratio can occur in individuals chronically exposed to organic solvents, such increase being directly proportional to the degree of exposure<sup>10</sup>.

Concerning possible dose-response curves that look for correlations between toluene concentration and levels of depression of CNS, some epidemiological researches have succeeded in defining concentration levels below which neurotoxic effects of toluene would be unlikely<sup>9</sup>. However, these studies take for granted regular conditions of contamination and short-term follow-up of exposed workers. Moreover, they bring little evidence as concerns safety of long-term exposures, regardless of concentrations.

In a great deal of these reports, cerebellar disturbances are secondary to varied conditions of exposure regarding both toluene concentration and total of inhalation. These cases have in common such characteristics as drug-addiction (nearly daily inhalations), relatively high concentrations (pure toluene in some reports) and duration of exposure varying widely from six months to fourteen years (mean of seven years)<sup>7-9</sup>. There are as many reports of improvement or complete recovery as of irreversible damage; it depends on the dose and total duration of exposure.

This case calls our attention to the possible neurotoxic risk related to chronic intermittent occupational exposure to low toluene doses, so that similar cases should require preventive measures.

**Acknowledgements**-We are grateful to engineers Ivo T. Borges and Luis A. Borges for analysing material collected at the patient's workplace.

## REFERENCES

1. Boor JW, Hurtig HI. Persistent cerebellar ataxia after exposure to toluene. *Ann Neurol* 1977, 2:440-442.
2. Christensen AL. Luria's neuropsychological investigation. Copenhagen: Munksgaard, 1979.
3. Folstein M, Folstein S, McHugh P. The Mini-Mental State Examination. *J Psychiat Res* 1975, 12: 189-198.
4. Fornazzari L, Wilkinson DA, Kapur BM, Carlen PL. Cerebellar, cortical and functional impairment in toluene abusers. *Acta Neurol Scand* 1983, 67:319-329.
5. Frant R. Silicon and organosilicon compounds. In: Ilo, *Encyclopaedia of Occupational Health and Safety*. Geneva, 1985, p 2035-2036.
6. Grabski DA. Toluene sniffing producing cerebellar degeneration. *Am J Psychiat* 1961, 118:461-462.
7. Kelly TW. Prolonged cerebellar dysfunction associated with paint-sniffing. *Pediatrics* 1975, 56:605-606.
8. Malm G, Lying-Tunnel U. Cerebellar dysfunction related to toluene sniffing. *Acta Neurol Scand* 1980, 62:188-190.
9. Utidjian HMD, Weaver NK. Criteria for a recommended standard occupational exposure to toluene. *JOM* 1974, 16:107-109.
10. Wikkelso C, Ekberg K, Lillienberg L, Wetterholm B, Karlsson B, Blomstrand C, Johansson BB. Cerebrospinal fluid proteins and cells in men subjected to long-term exposure to organic solvents. *Acta Neurol Scand* 1984, 70 (Suppl 100): 113-119.