

# BRAINSTEM CYSTICERCOSIS SIMULATING CYSTIC TUMOR LESION

## A CASE REPORT

WALTER O. ARRUDA\*, RICARDO RAMINA\*\*, ARI A. PEDROZO\*\*, MURILO S. MENESES\*\*

---

**SUMMARY** - The authors report the case of a 37 year-old man with a solitary cysticercus cyst in the brainstem (pons) successfully removed through a suboccipital craniectomy. Surgery in neurocysticercosis has been indicated in patients with hydrocephalus and/or large cystic lesions. Cystic lesions in the brainstem and spinal cord may have indication for surgery for two reasons: (1) diagnosis; and (2) treatment. Aspects related to differential diagnosis and therapeutic alternatives are discussed.

**KEY WORDS:** cysticercosis, brainstem, cysts, tumors.

### **Cisticercose simulando lesão cística tumoral do tronco cerebral: relato de caso**

**RESUMO** - Os autores relatam o caso de paciente masculino de 37 anos com cisticercó único no tronco cerebral (ponte) removido cirurgicamente com sucesso. Cirurgia tem sido indicada em neurocisticercose nos pacientes com hidrocefalia e/ou lesões císticas com importante efeito de massa. As lesões localizadas no tronco cerebral ou medula espinhal podem ter indicação cirúrgica por duas razões: (1) diagnóstico; e (2) tratamento. O emprego de drogas cisticidas pode ser considerada uma alternativa terapêutica em certos casos. Contudo, o risco de desenvolvimento de complicações decorrentes da destruição dos cistos situados em áreas críticas do sistema nervoso central deve ser considerado.

**PALAVRAS-CHAVE:** cisticercose, tronco cerebral, cistos, tumores.

---

Cysticercosis is the most common parasitosis affecting the central nervous system (CNS), and it is endemic in many developing countries<sup>2</sup>. It can occur in a single or in multiple locations within the CNS. Due to its pleomorphic clinical presentation, neurocysticercosis (NS) is part of the differential diagnosis with many neurological diseases in countries where it is endemic, as well as in immigrants coming from endemic areas.

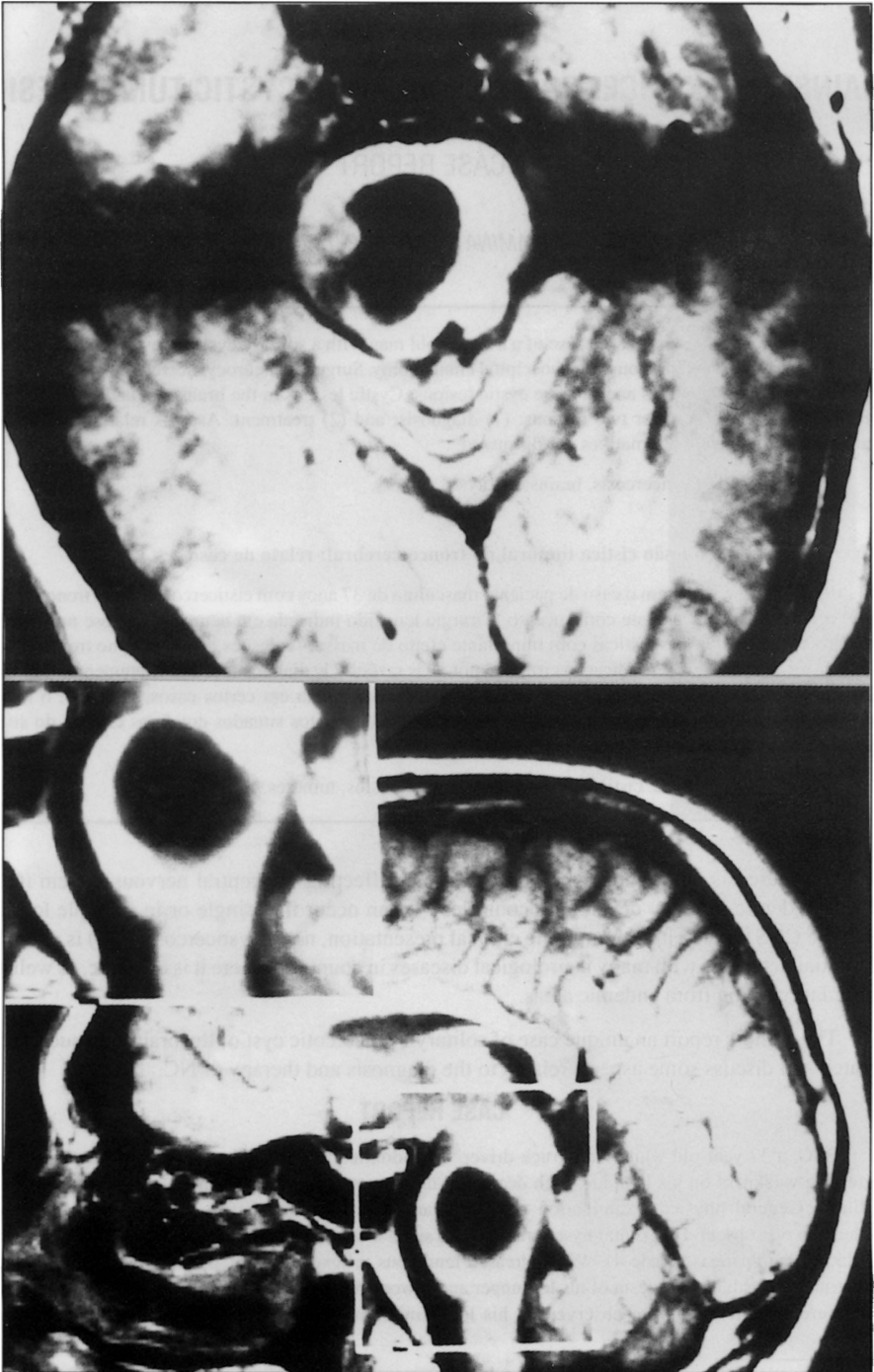
The authors report a unique case of solitary cysticercotic cyst of the brainstem successfully operated and discuss some aspects related to the diagnosis and therapy of NC.

### **CASE REPORT**

BSC, a 37 year-old white man, truck-driver, was admitted to our Clinic with a four months history of progressive weakness on his left side, with decreased tactile sensation and incoordination of upper and lower left limbs. General physical examination was unremarkable except for diffuse subcutaneous lipomatosis. Papilledema was absent. Horizontal nystagmus to both sides was present; all other cranial nerves were normal. Left flaccid hemiparesis (grade 4), with increased tendinous reflexes and left Babinski sign were disclosed. Dysmetria and dysdiadokokinesia of his left upper and lower limb were present. Decreased sensation to touch, temperature and pressure were observed on his left dimidium, including the face. A CT scan disclosed a

---

Unidade de Ciências Neurológicas, Curitiba: \*Neurologista; \*\*Neurocirurgião. Aceite: 24-fevereiro-1994.



*Fig 1. Patient BSC. T1 Gd-DTPA -enhanced MRI in axial (above) and sagittal (below) planes showing a cystic lesion right to the midline in the pons.*

nonenhancing contrast cystic lesion in the pons, right to the midline. There was no hydrocephalus, calcifications or other cystic lesions. A MRI scan examination (Fig 1) showed a cystic lesion within the brainstem, at the pons level, with a mural nodular lesion. Perilesional edema was observed, but no gadolinium contrast enhancement was observed. A spinal tap was performed, and the CSF examination was normal, including negative immunological reactions for cysticercosis.

Under general anesthesia, in supine position with head turned to the left, a retrosigmoidal suboccipital craniectomy was performed. After drainage of the cisterna magna, the right cerebellum hemisphere was retracted and the cerebello-pontine angle inspected. The flocculus and the emergence of seventh, eighth and fifth cranial nerves were identified. In front of the bulbopontine sulcus, between fifth and seventh nerves, a 5 mm incision was performed in the pons and a cyst was entered. It was filled with a clear fluid. The lesion had a very thin capsule, and a scolex was identified in its interior. It could be pulled out intact, measuring 14X8 mm.

The postoperative evolution was uneventful. The patient was discharged with a mild improvement of his neurological deficits. He steadily improved and about five months later was neurologically normal.

### COMMENTS

Neurocysticercosis may manifest clinically in several ways: seizures, headaches, syncope, dementia, diplopia, visual field defects, hydrocephalus (with or without arachnoiditis), stroke, and focal neurological deficits. In patients living in endemic areas, the CT scan examination supported by positive serological tests in the serum and CSF make the diagnosis usually straightforward<sup>2</sup>. CT scans are more sensitive in detecting calcifications, however magnetic resonance imaging (MRI) of parenchymal lesions seems to be superior to plain CT, and has been of great help in the diagnosis of cisternal and intraventricular cystic lesions<sup>10</sup>. Spinal cord cysts, subarachnoid or intraspinal, can be respectively detected by myelography or MRI scans.

Our patient was unique in the following aspects: (1) there was no evidence of NC elsewhere in the CNS that could give us a hint his brainstem lesion could be a cysticercus; and (2) the CSF examination was negative for cysticercosis.

The differential diagnosis of cystic brainstem lesion includes other parasitic lesions than NC (e.g. echinococcosis), CNS neoplasms (astrocytomas, hemangioblastomas, and less likely glioblastoma multiforme), tuberculosis, fungal infections, and benign cystic lesions (epidermoid cyst, simple cyst). Gallani et al.<sup>4</sup> reported a 13 year-old girl with an intraspinal cystic lesion at T11-T12 level, without evidence of other cysticercotic lesions in the CNS and with negative immunological findings in the CSF. The diagnosis was also made only after surgical exeresis of the lesion.

Praziquantel and albendazole have been shown to be effective cysticidal drugs in NC<sup>8,9</sup>. Early CT reevaluation following empiric praziquantel therapy has been proposed as an effective tool in the diagnosis of NC in patients with single parenchymal lesions<sup>7</sup>. In our patient, this approach might be too risky due to size of the lesion and its location. In spite of the associated use of corticosteroids, the inflammatory reaction that follows the cyst destruction may be severe enough to cause damage to the CNS structures and even death, as other authors<sup>9</sup> and we have already observed in patients with multiple or solitary lesions. Surgery of NC cysts has a few indications including hydrocephalus, intraventricular obstructing cysts, and patients with symptoms due to local mass effect<sup>1,5,6</sup>. We recently treated a young man with seizures (focal motor with secondary generalization) and progressive hemiparesis/hemianesthesia, a large solitary cystic lesion within the corona radiata, with albendazole 15mg/Kg/day for 5 days. A control CT scan did not show neither perilesional inflammatory reaction nor change in the cyst size. The cystic lesion was successfully removed through a stereotactic aspiration and the patient had a complete postoperative recovery. Nevertheless, Del Brutto et al.<sup>3</sup> have reported good results treating giant subarachnoid cysticerci with an albendazole daily dose of 15 mg/Kg of body weight for 8 days.

Brainstem lesions are fortunately rare, and should be probably operated on for two reasons: (1) diagnosis, as was shown in this case; and (2) treatment, once the use of cysticidal drugs might be too risky in comparison with a relatively low operative morbidity/mortality.

**REFERENCES**

1. Colli BO, Martelli N, Assirati JA, Machado HR, Forjaz SV. Results of surgical treatment of neurocysticercosis in 69 cases. *J Neurosurg* 1986, 65: 309-315.
2. Del Brutto OH, Sotelo J. Neurocysticercosis: an update. *Rev Infect Dis* 1987, 10: 1075-1081.
3. Del Brutto OH, Sotelo J, Aguirre R, Díaz-Calderon E, Alarcón TA. Albendazole therapy for giant subarachnoid cysticerci. *Arch Neurol* 1992, 49: 535-538.
4. Gallani NR, Zambelli HJL, Roth-Vargas AA, Limoli C Jr. Cisticercose medular: relato de dois casos, revisão da literatura e comentários sobre a patogenia. *Arq Neuropsiquiatr* 1992, 50: 343-350.
5. Ramina R, Hunhevicz SC. Cerebral cysticercosis presenting as mass lesion. *Surg Neurol* 1986, 24: 89-93.
6. Ramina R, Arruda WO, Parolin MKF, Prestes ACF. When and on what to operate in multiple cerebral cysticercosis cysts? *J Neurol Neurosurg Psychiatry* 1988, 51: 1006.
7. Rawlings D, Ferriero DM, Messing RO. Early CT reevaluation after empiric praziquantel therapy in neurocysticercosis. *Neurology* 1989, 39: 739-741.
8. Sotelo J, Escobedo, F, Rodriguez-Carbajal J, Torres B, Rubio-Donnadieu F. Therapy of parenchymal brain cysticercosis with praziquantel. *N Engl J Med* 1984, 310: 1001-1007.
9. Takayanagui OM, Jardim E. Therapy for neurocysticercosis: comparison between albendazole and praziquantel. *Arch Neurol* 1992, 49: 290-294.
10. Zee CS, Segall HD, Boswell W, Ahmadi J, Nelson M, Colletti P. MR Imaging of neurocysticercosis. *J Comput Assist Tomogr* 1988, 12: 927-934.