

EPIDURAL HEMATOMA AFTER VENTRICULOPERITONEAL SHUNT SURGERY

REPORT OF TWO CASES

*CARLOS UMBERTO PEREIRA**, *MARCUS WAGNER DE SOUZA PORTO***,
*RAFAEL RODRIGUES DE HOLANDA****, *WELLINGTON TORRES DE ANDRADE***

ABSTRACT- Ventriculoperitoneal shunt operations represent the most used choice for treating hydrocephalus, although some related complications have been reported. Due to its rarity, potential dangers, and mortality rate, we present two cases of epidural hematoma following ventriculoperitoneal shunt, discussing its pathophysiology and prophylaxis.

KEY WORDS: epidural hematoma, complications, cerebrospinal fluid shunts.

Hematoma epidural após derivação ventriculoperitoneal: relato de dois casos

RESUMO – No tratamento cirúrgico da hidrocefalia, a derivação ventriculoperitoneal é a mais usada, porém ocorrem várias complicações e dentre elas o hematoma epidural. Os autores relatam dois casos de hematoma epidural após cirurgia de derivação ventriculoperitoneal e discutem sua provável fisiopatologia e profilaxia.

PALAVRAS-CHAVE: hematoma epidural, complicações, derivações do líquido cefalorraquidiano.

Occurrence of epidural hematoma (EH) after ventriculoperitoneal shunt operations is a rare condition. It is a catastrophic complication of a relatively minor neurosurgical procedure. EH, as a complication of ventricular drainage, was first mentioned in 1941, by Olivecrona¹; since then other cases have seldom been reported²⁻¹⁵.

We present two cases of EH after ventriculoperitoneal shunt surgery for hydrocephalus management.

REPORT OF THE CASES

Case 1. AJS, 33 year-old woman, was admitted with the complaint of a persistent headache for the last six months. Neurological examination: normal. CT: moderate distended supratentorial ventricle and an intraventricular cystic lesion (Fig 1). Procedure: a ventriculoperitoneal shunt with medium pressure valve. Evolution: 4 months later the patient returned with severe/throbbing headache and dizziness. Neurological examination: normal. CT: a capsulated EH at the posterior left parietal region (corresponding to the area of ventricular catheter) (Fig 2). Evolution: the patient did not accept other surgical treatment. Headache was controlled by the use of analgesics. The patient is asymptomatic nowadays.

Case 2. MS, 39 year-old man, came to the emergency service with the complaint of severe headache, vomits and fever. Neurological examination: confused, nuchal rigidity. Cerebrospinal fluid (CSF) exam revealed an inflammatory process. Procedure: intravenous antibiotics were prescribed with fluids replacement. Evolution:

*Federal University of Sergipe, Department of Neurosurgery of Hospital Cirurgia, Aracaju SE, Brazil;
Federal University of Paraíba, Campus II - Campina Grande PB, Brazil; *Hospital Pedro I, Campina Grande PB - Brazil.

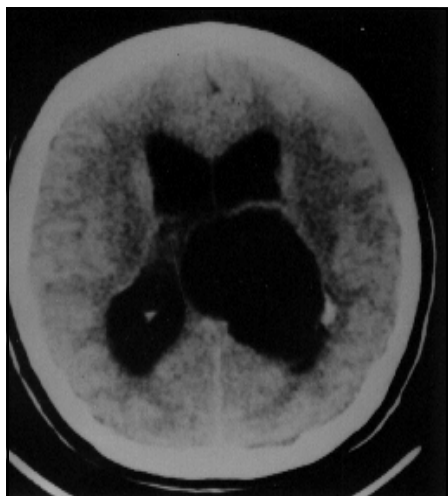

Fig 1. Case 1. Moderate distended supratentorial ventricles and intraventricular cystic lesion.

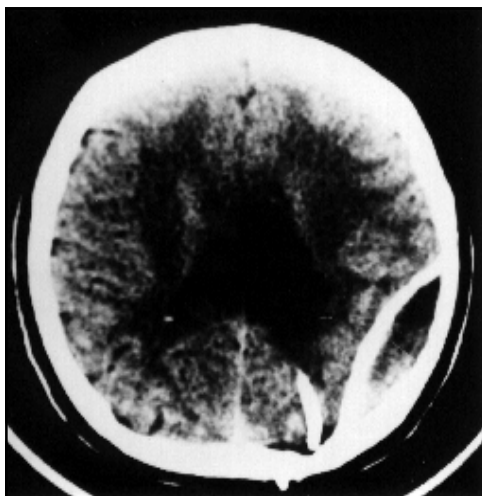


Fig 2. Case 1. A Capsulated EH at the posterior left parietal region.

the patient's conditions markedly improved within 48 hs instead of a persistent headache and bilateral papilloedema. CT-scan: images of intracranial hypertension and a sellar/parasellar lesion with cystic areas (Fig 3). Procedure: ventriculoperitoneal shunt surgery. Evolution: persistence of some neurological alterations (somnolence/left hemiparesis). CT-scan: EH and right to left midline shift (Fig 4). Second procedure: surgical treatment for EH. Evolution: the patient died shortly thereafter.

DISCUSSION

EH, as a complication of ventriculoperitoneal shunt surgery for the management of hydrocephalus, is a rare condition^{3-10,16,19}. It often occurs in young patients^{4,10,16,17,19}, and there are some anatomical regions (parietal and frontal) where the pathology is more frequently found.

Mechanisms of EH formation in these conditions are not well understood. Many authors thought that the traction exerted on the duramater by the many vessels attached to the brain causes a displacement and makes the vessels between the membrane and the skull to be torn. A sudden lowering of intracranial pressure, due to cortex collapse, helps hematomas increasing up to a catastrophic complication if not recognized and treated in time^{3,4,10,16,17,18}.

EH always develops in a matter of days, weeks or months after surgical procedure^{3,12,19}. Patients with very high intracranial pressure or with intensive cortical atrophy, in long standing hydrocephalus, are most at risk. Perhaps the skull-to-duramater adhesion become altered. The mortality of patients with EH is higher than for those with subdural bleeding. It may be explained by the different incidence rates which those processes develop.

We think that the forced introduction of the ventricular catheter through a narrow burr hole displaced the duramater on our Case 1. The second one was due to severe long time hydrocephalus.

CT-scan helps to diagnosis, showing the EH image with other associated lesions^{12,17,19}. Driesen and Elies³ suggested a way of preventing postoperative epidural bleeding by dural fixing stitches in the neighbourhood of the burr hole. To minimize some bleeding complications after ventricular shunting⁹ some precautions are necessary: minimal CSF spillage at the time of ventricular catheter insertion; meticulous surgical technique; use of high or medium pressure valves; slow return to the full upright position and a close follow-up even with post-operative CT-scan.

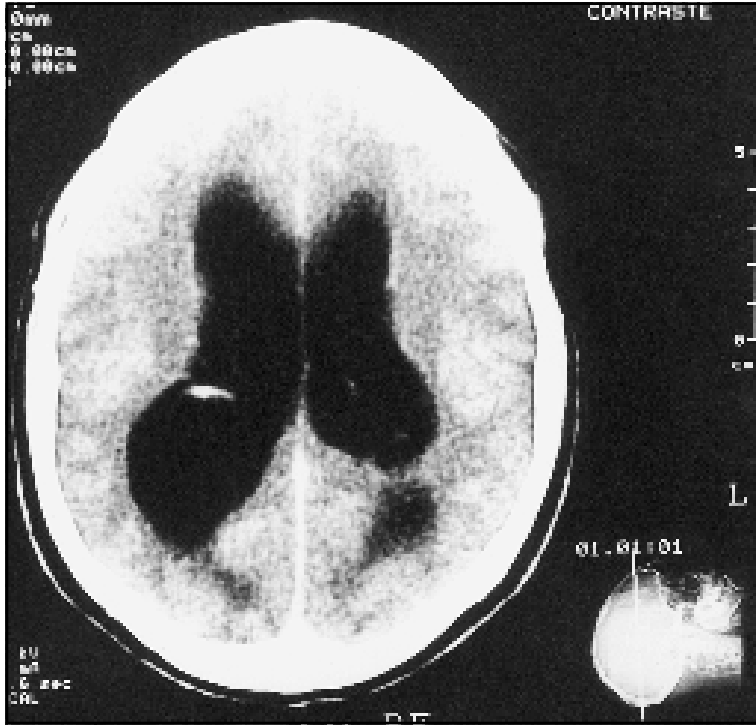


Fig 3. Case 2. Supratentorial ventricular dilatation.

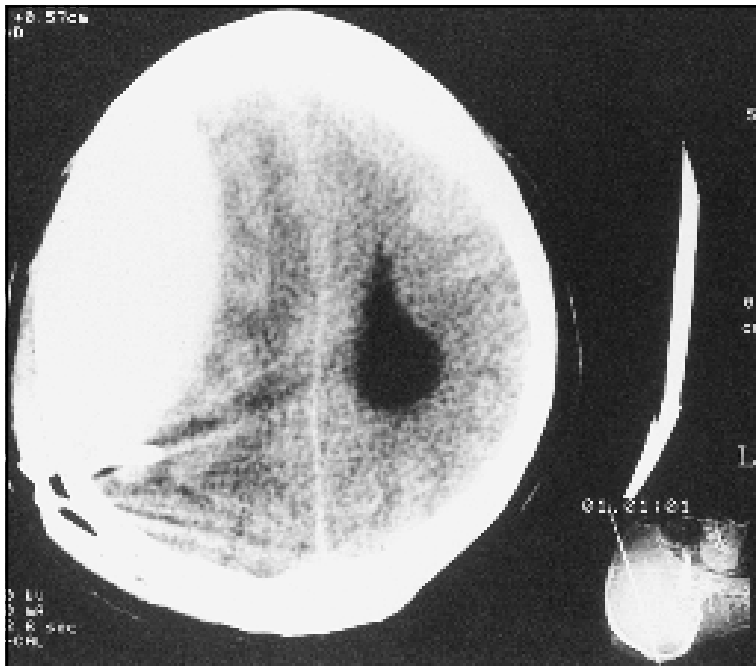


Fig 4. Case 2. EH and right to left midline shift.

The currently available hydrocephalus valves are still far from perfect. Whereas the design principles of differential pressure valves and adjustable devices involve the dangers of overdrainage and related problems such as subdural hygromas/hematomas²⁰⁻²³. Naturally, better understanding and increased surgical team acquired experience will help this complication not to happen. As its prognosis is not so good somehow, this possibility must raise in the mind of those involved in treating hydrocephalus surgically, in order to this condition remains rare.

REFERENCES

1. Olivecrona H. Chirurgische Behandlung der Geschwulsten. In Die spezielle Chirurgie der Gehirnkrankheiten, Vol. 3, Stuttgart. Enke, 1991:465-468.
2. el Vivo RE, Armenrose B. Ematoma epidurale acuto spontaneo dopo decompressione ventricolare in corso de idrocefalo. *Minerva Neurochir* 1961;5:43-48.
3. Driesen W, Elies W. Epidural and subdural haematomas as a complication of internal drainage of cerebrospinal fluid in hydrocephalus. *Acta Neurochir* 1977;36:107-109.
4. Frera C. Supratentorial extradural haematomas secondary to ventricular decompression. *Acta Neurochir* 1977;36:107-109.
5. Gulliksen G, Hasse J. Epidural haematoma as a complication of a ventricular drainage. *Neurosurgery* 1977;36:107-109.
6. Haft H, Liss H, Maount LA. Massive epidural haemorrhage as a complication of ventricular drainage. *J Neurosurg* 1960;17:49-54.
7. Higazi J. Epidural haematoma as a complication of ventricular drainage: report of a case and review of the literature. *J Neurosurg* 1963;20:527-528.
8. Jan M, Gouaze A, Elie A, Lapierre F, Santini JJ. Hematoma extradural après ponction ventriculaire au cours d'une intervention sur la fossa postérieure. *Neurochirurgie* 1978;24:137-139.
9. Kalia KK, Swift DM, Panz D. Multiple epidural hematomas following ventriculoperitoneal shunt. *Pediatr Neurosurg* 1993;19:78-80.
10. Schorstein J. Fatal intracranial venous haematoma following ventricular drainage. *J Neurol Neurosurg Psychiatry* 1942;5:142-147.
11. Strenger L. Complications of ventriculovenous shunts. *J Neurosurg* 1963;20:219-224.
12. Tjan TG, Aarts NJM. Bifrontal epidural haemorrhage after shunt operation and posterior fossa exploration: report of a case with survival. *Neuroradiology* 1980;19:51-53.
13. Weiss RM. Massive epidural haematoma complicating ventricular decompression: report of a case. *J Neurosurg* 1964;17:235-236.
14. Yue C, Mann K. Fluid chronic epidural haematoma: a rare complication of a ventriculoperitoneal shunt. *Br Med J* 1985;48:953-955.
15. Ameli NO, Sodeify N. Anterior fossa extradural haematoma following ventriculography through posterior burr holes. *Acta Neurochir* 1965;13:465-468.
16. Sengputa RP, Hankinson J. Extradural hemorrhage: a hazard of ventricular drainage. *J Neurol Neurosurg Psychiatry* 1972;35:297-303.
17. Pereira CU, Barreto AS, Leão JDB, Silva AD. Non operative management of extradural hematoma (Abstr). Berlin: 10th European Congress of Neurosurgery, 1995.
18. Arias BA, Voris HC. Extradural hemorrhage after ventriculography. *Am J Surg* 1968;116:109-112
19. Sena JC, Grazian N. Hematoma epidural como complicação de uma drenagem ventricular externa. *Arq Bras Neurocirurg* 1992;11:153-158.
20. Shung C, Miethke C, Trost HÁ, Lannsch WR, Stolke D. The dual-switch valve: a new hydrostatic valve for the treatment of hydrocephalus. *Childs Nerv Syst* 1996;12:573-581.
21. Heintelmann M, Platz A, Imhof HG. Outcome after acute extradural haematoma, influence of additional injuries and neurological complications in the intensive care unit. *Injury* 1996;27:345-349.
22. Servadei F, Vergoni G, Staffa G, et al. Extradural haematomas: how many deaths can be avoided? Protocol for early detection of haematoma in minor head injuries. *Acta Neurochir (Wien)* 1995;133:50-55.
23. Iplikcioglu AC, Bayar MA, Kokes F, Yildiz B, Gokcek C, Buharaliz Z. A fluid level in an acute extradural hematoma. *Neuroradiology* 1994;36:31-32.