

# PINEAL METASTASIS AS FIRST CLINICAL MANIFESTATION OF COLORECTAL ADENOCARCINOMA

## CASE REPORT

*RICARDO RAMINA\*, MAURÍCIO COELHO NETO\*\*,  
WAGNER M. MARIUSHI\*\*, WALTER O. ARRUDA\*\*\**

---

**ABSTRACT-** Cerebral metastases from colorectal adenocarcinomas occur in 8% of the cases. Diagnosis is usually made when primary disease and widespread metastases are already known. We report the case of a patient with single metastases in the pineal region as the first clinical manifestation of a colorectal adenocarcinoma. A 48-year-old female with Parinaud's syndrome for 15 days prior her admission was evaluated in our clinic. She had no symptoms or signs of colorectal disease. MRI examination revealed an heterogeneous lesion with peritumoral gadolinium enhancement, located in the pineal region. The tumor was radically resected through an infratentorial/supracerebellar approach. Histology showed metastatic carcinoma and immunohistochemical examination showed gastrointestinal tract adenocarcinoma. Metastases to the pineal region are extremely rare and should be considered in the differential diagnosis of tumors of this region.

**KEY WORDS:** pineal tumors, cerebral metastases, colorectal adenocarcinoma.

### **Metástase pineal como primeira manifestação clínica de adenocarcinoma colorretal: relato de caso**

**RESUMO -** Metástases cerebrais derivadas de adenocarcinomas colorretais ocorrem em 8% dos casos. Geralmente a doença primária e as metástases em outros órgãos já são conhecidas quando do momento das manifestações neurológicas. Descrevemos um caso de metástase única na região pineal que promoveu a primeira manifestação clínica de adenocarcinoma colorretal. Uma mulher de 48 anos de idade apresentava há quinze dias de sua admissão ao nosso serviço diplopia e síndrome de Parinaud. O exame de ressonância magnética revelou lesão heterogênea localizada na região pineal. O tumor foi completamente retirado por acesso infratentorial/supracerebelar. O exame histológico revelou tumor metastático indiferenciado e o exame imuno-histoquímico demonstrou adenocarcinoma do trato gastrointestinal moderadamente diferenciado. Metástases para a região pineal são extremamente raras e devem ser consideradas no diagnóstico diferencial de tumores nesta região.

**PALAVRAS-CHAVE:** tumores da pineal, metástases cerebrais, adenocarcinoma colorretal.

---

Colorectal adenocarcinomas are the fourth cause of central nervous system metastases in frequency. In most cases, the primary disease is already diagnosed when the brain is affected.

We present a case where the first manifestation of a colorectal adenocarcinoma was a solitary pineal metastasis.

## CASE REPORT

A 48-year-old woman, with no previous disease, presented to the Neurosurgical Department of Curitiba Skull Base Foundation with Parinaud's syndrome and nausea. There was no other clinical evidence of neurologic or systemic disease. MRI examination revealed a single heterogeneous hyperintense lesion in T1 sequences with peritumoral gadolinium enhancement (Fig. 1). The patient was operated on using an infratentorial/supracerebellar approach and radical resection was possible. The intraoperative histopathologic diagnosis suggested a metastatic

---

Curitiba Skull Base Foundation - Hospital das Nações, Curitiba - Brazil: \*Neurosurgeon; \*\*Resident in Neurosurgery; \*\*\*Neurologist. Aceite: 25-outubro-1998.

Dr. Ricardo Ramina - Rua Gonçalves Dias 713 - 80240-340 Curitiba PR - Brasil. Fax 55 41 2641238.

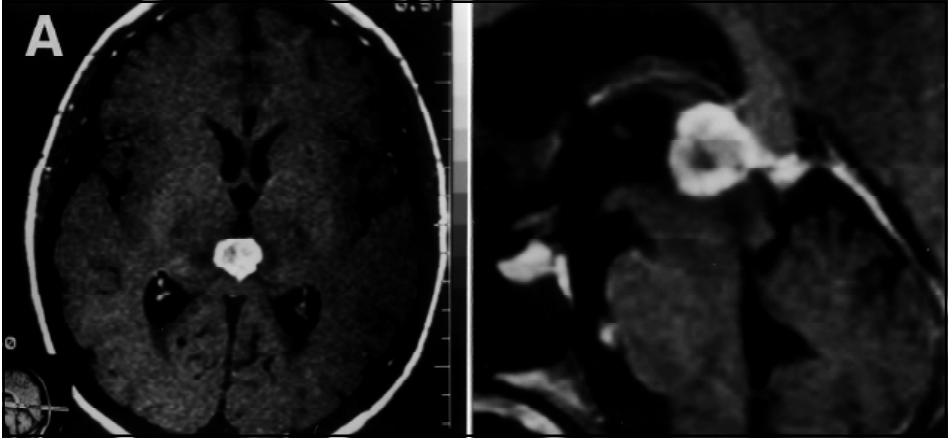


Fig 1. MRI T1-weighted axial (A) and sagittal views after gadolinium injection showing hyperintense lesion compressing mesencephalon and quadrigeminal plate.

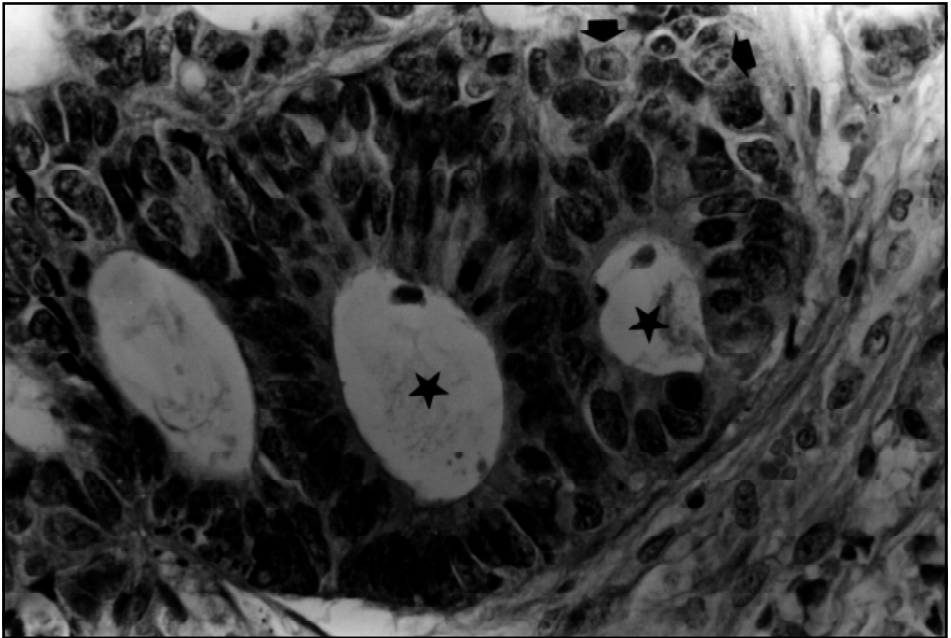


Fig 2. Detail of adenocarcinoma forming tubules (\*) with tumor cells showing pleomorphic nuclei with prominent nucleoli (arrow). HE x 400.

carcinomatous lesion (Fig.2). Immunohistochemical study showed a moderately differentiated adenocarcinoma. Abdominal ultrasound detected multiple hypo and hyperechoic metastatic nodules in the liver. Adjuvant treatment with 5-fluouracil and radiotherapy was started.

On 32nd day of the postoperative course, the patient presented acute abdomen syndrome. Emergency laparotomy showed suppurative appendicitis and a tumor with no inflammatory aspect in the cecum region. Pathological examination of this lesion revealed moderately differentiated adenocarcinoma. The patient died 90 days after resection of the pineal metastasis with other lesions in brain stem and recurrence.

## DISCUSSION

Ninety five per cent of colorectal tumors are adenocarcinomas. Lesions in the cecum and ascending colon may be asymptomatic for a long period of time, what increases the possibility of its first manifestation as metastatic disease.

About 8% of patients with colorectal adenocarcinoma present brain metastases during the late course of the disease, when the primary disease is already diagnosed. Solitary brain metastases is a rare condition and corresponds to 1% of all cerebral metastases<sup>3</sup>. There are 25 cases of colorectal adenocarcinoma with cerebral metastases (including this case) as first sign of the disease reported in the literature<sup>4-8</sup>.

Metastatic tumors in the pineal region represents 1.8 to 4% of all forms of disseminated cancer<sup>9</sup>. The first case was described by Forster in 1858; it is cited by Vaquero et al.<sup>4</sup> in his recent review. Vaquero et al.<sup>4</sup> reviewed 75 cases of pineal region metastases, and approximately half of them were solitary<sup>4,10-14</sup>. The diagnosis of solitary metastatic lesions in the pineal region prior to the identification of the primary disease is an uncommon situation especially when the primary site is a colorectal adenocarcinoma<sup>4,5</sup>.

The literature reports solitary brain metastases from intestinal cancer occurring in 0,5 to 1% of all cerebral metastases<sup>7,8,15</sup>. The neuroradiological findings, including MRI, are not specific for these lesions.

The pineal region is devoided of blood-brain barrier, and thus more prone to hematogenous implantation from distant tumors<sup>16-18</sup>.

Indication for surgery is controversial when the primary lesion is known. According to Sato et al.<sup>19</sup>, surgery would be indicated for improvement of life quality. Vaquero et al.<sup>4</sup> comment that because of metastatic disease, life expectancy of these patients is extremely poor and less aggressive procedures (e.g. biopsies) should be eventually performed. Some authors recommend only radiotherapy for colorectal metastases, for no change in survival rates has been observed in operated patients<sup>1,6</sup>. Patients with extracranial primary disease in progress should receive radiotherapy. In our case, surgical treatment was indicated because no primary disease was known at the time of the neurological manifestations.

In conclusion, pineal region metastases, especially single, are extremely rare. The neuroradiological findings are not typical but, this entity should be considered in the differential diagnosis of tumors of this region. Surgical removal of single pineal metastases confirms diagnosis, decompresses neighbor structures, raises life quality of the patients and indicates adjuvant therapy. When primary disease is already known, only radiotherapy is carried out, as the disease is usually already widespread.

**Acknowledgment** - We thank Dr. Luiz Fernando Bleggi-Torres, M.D., Ph.D. by the histological studies.

## REFERENCES

1. Alden TD, Gianino JW, Saclarides TJ. Brain metastases from colorectal cancer. *Dis Colon Rectum* 1996;39:541-545.
2. Hamann G, Meier T, Schimrigk K. Hirnmetastasen als erst Manifestation einer Tumorerkrankung. *Nervenarzt* 1993;64:104-107.
3. Salvati M, Cervoni L, Paolini S, Delfini R. Solitary Cerebral Metastases from Intestinal Carcinoma. *Acta Neurochir (Wien)* 1995;133:181-183.
4. Vaquero J, Ramiro J, Martínez R, Bravo G. Neurosurgical experience with tumors of the pineal region at Clinica Puerta the Hierro. *Acta Neurochir (Wien)* 1992;116:23-32.
5. Delahunt B, Teoh HH, Balakrishnan V, Nacey J, Clark SP. Testicular germ cell tumor with pineal metastases. *Neurosurgery* 1990;26:688-691.
6. Farnell GF, Buckner JC, Cascino TL, O'Connell MJ, Schomberg PJ, Suman V. Brain metastases from colorectal carcinoma: the long term survivors. *Cancer* 1996;78:711-716.
7. Chyun Y, Hayward E, Lokich J. Metastasis to the central nervous system from colorectal cancer. *Med Pediatr Oncol* 1980;8:305-308.

8. Cascino TL, Leavengood JM, Kemeny N, Posner JB. Brain metastases from colon cancer. *J Neurooncol* 1983;1:203-209.
9. Schreiber von D, Bernstein K, Schneider J. Tumormetastasen im Zentralnervensystem. Eine prospektive Studie. *Zentralbl Allg Pathol* 1982;126:64-73.
10. Izumihara A, Orita T, Tsurutani T, Kajiwara K, Matsunaga T, Hatano M. Pineal and suprasellar metastasis of lung cancer: case report and review of the literature. *Comput Med Imaging Graph* 1995;19:435-437.
11. Suganuma H, Yoshimi T, Kita T, et al.. Rare case with metastatic involvement of hypothalamo-pituitary and pineal body presenting as hypopituitarism and diabetes insipidus. *Intern Med* 1994;33:795-798.
12. Brasseur P, Sukkarieh F, Dupont H, Brohé D. Pineal body metastases. *J Belge Radiol* 1994;77:162-163.
13. Vaquero J, Martinez R, Magallon R, Ramiro J. Intracranial metastases to the pineal region, report of three cases. *J Neurosurg* 1991;35:55-57.
14. Weber P, Shepard KV, Vijayakumar S. Metastases to pineal gland, case report. *Cancer* 1989;63:164-165.
15. Delattre JY, Krol G, Thaler HT, Posner JB. Distribution of brain metastases. *Arch Neurol* 1988;45:741-744.
16. Cohen EM, Duffner PK. Brain tumors in children: principles of diagnosis and treatment, 2.Ed. New York: Raven Press, 1937:329-346.
17. Toner GC, Pike J, Schwarz MA. The blood-brain barrier and response of CNS. metastases to chemotherapy. *J Neurooncol* 1989;7:21-24.
18. Weiss L. Metastatic brain tumors: factors that govern the metastatic process. In De Vita VT, Hellman S, Rosenberg SA (eds). *Cancer: principles and practice of oncology*. Philadelphia: Lippincott:2261-2274.
19. Sato H, Tsuchiya A, Nomizu T, et al.. The neurosurgical management of the brain metastasis from colorectal cancer: a report of three cases. *Jpn J Surg* 1993;23:639-643.