

POSTERIOR FOSSA CRANIOTOMY

TECHNICAL REPORT

*JOSÉ ALBERTO LANDEIRO**, *IGOR DE CASTRO***,
*MARLO STEINER FLORES****, *ORLANDO TEIXEIRA MAIA JÚNIOR*****

ABSTRACT - The use of craniotomy to approach supratentorial lesions is quite well established in the literature. The use of craniotomy for posterior fossa approaches, however, is not well described. The aim of this article is to describe the technical aspects of this approach and to delineate the important landmarks. In our cases, posterior fossa craniotomies have been utilized for treat different pathologies. Additionally, the technique has not added any additional risk, and the cosmetic results have been excellent.

KEY WORDS: posterior fossa craniotomy, surgical technique.

Craniotomia na fossa posterior: relato técnico

RESUMO - O uso de craniotomia para tratamento de lesões supratentoriais se encontra consagrado na literatura. Entretanto, o uso de craniotomia na fossa posterior é pouco descrito. O objetivo deste estudo é descrever os aspectos técnicos dessa abordagem e delinear algumas importantes referências anatômicas. Em nossos casos, as craniotomias na fossa posterior foram utilizadas para tratar patologias diferentes O procedimento provou ser seguro, não trazendo qualquer risco adicional aos pacientes e os resultados estéticos foram excelentes.

PALAVRAS-CHAVE: craniotomia, fossa posterior, técnica cirúrgica.

The use of craniotomy to deal with supratentorial lesions is absolutely well established in the literature. Occasionally some craniectomies are performed in the supratentorial compartment but most of the cases the bone flap is also involved with the intracranial lesion¹. However there is a predilection in the literature about the use of craniectomy in stead of craniotomy to approach lesions within the posterior fossa. Presently few operative neurosurgical techniques books describe the use of posterior fossa craniotomies².

Yasargil and Fox³ described a technique using hand-held instruments to remove a posterior fossa bone flap, which could be replaced and fixed at the conclusion of the operative procedure. Subsequently on Ogilvy and Ojemann⁴ described a similar procedure to access the cerebellopontine angle but they introduced the use of high speed air drills and a craniotome.

The replacement of the bone flap at the end of the procedure has been used successfully by us. We are convinced that this procedure is feasible in virtually every place of the posterior fossa even the transverse sigmoid sinus complex as described in the petrosal approach^{5,6}. However, the surgeon must be familiar with the anatomic landmarks.

We report two examples of posterior fossa craniotomies. We add to the description some details on important anatomic landmarks. Finally we summarize the advantages of this technique over the standard craniectomy.

Serviço de Neurocirurgia do Hospital da Força Aérea do Galeão (HFAG), Rio de Janeiro, RJ: *Chefe do Serviço de Neurocirurgia do HFAG, **Residente do Serviço de Neurocirurgia do Hospital Universitário Antônio Pedro, Niterói, RJ; ***Assistente do Serviço de Neurocirurgia do HFAG; ****Residente do Serviço de Neurocirurgia do HFAG. Aceite: 6-outubro-1999.

Dr. José Alberto Landeiro - Estrada do Galeão 4101, Ilha do Governador - 21941-000 Rio de Janeiro RJ - Brasil.
FAX 21 284 5341. E mail: mstreiner@unisys.com.br

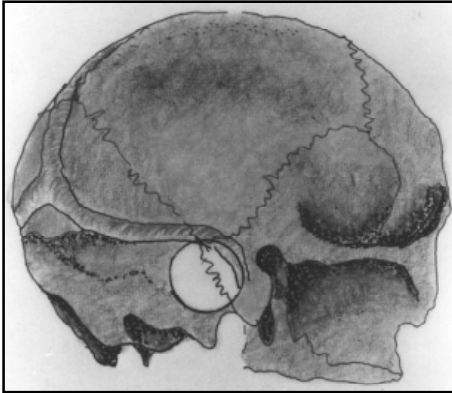


Fig 1a. The retrosigmoid craniotomy for microvascular decompression in trigeminal neuralgia.

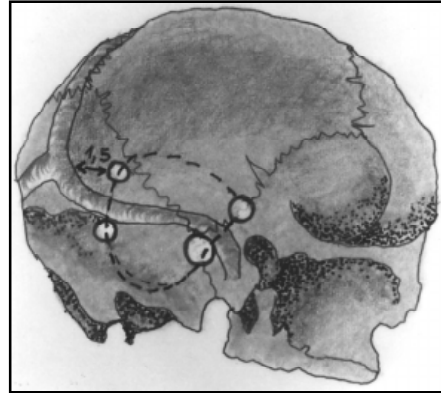


Fig 1b. Surface relationship between the transverse - sigmoid sinus complex and the burr holes to the bone flap used in combined supra and infra tentorial approaches.

METHOD

This report shows two illustrative cases of craniotomy performed approach lesions within the posterior fossa. We review below one patient operated on for trigeminal neuralgia and the other to remove a large tentorial meningioma.

The patients were positioned in $\frac{3}{4}$ prone and the head was fixed with three-point-skeletal fixation device. Both craniotomies were performed with high speed air drills and a craniotome (Ultra Power Drill System-Zimmer). The results were judged on postoperative computerized tomography (CT) scan with bone window and magnetic resonance imaging (MRI).

Case 1. A 44 years old woman, with trigeminal neuralgia was evaluated and subsequently brought to the operative room for decompression. A retrosigmoid craniotomy was performed. For a microvascular decompression a linear incision provides adequate exposure and causes less trauma to the underlying muscles. The incision was placed 5 mm medial to the mastoid notch (a palpable landmark). The key hole was placed inferomedially to the asterion. Follow the placement of the burr holes, a dissector was used to strip the dura carefully from the overlying bone. With the dura stripped we performed a craniotomy of 2 cm diameter with the aid of a craniotome. The limits of the craniotomy are showed in Figure 1.

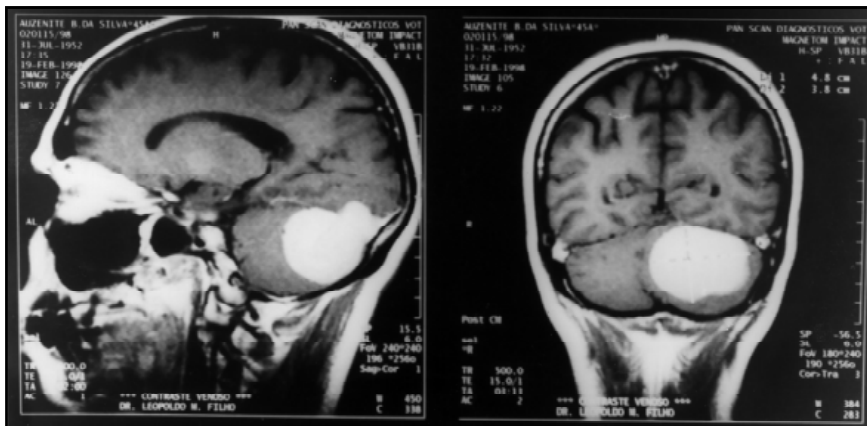


Fig 2. Large tentorial meningioma. The location within the superior part of the cerebellar hemisphere and the relation with the tentorium is demonstrated.

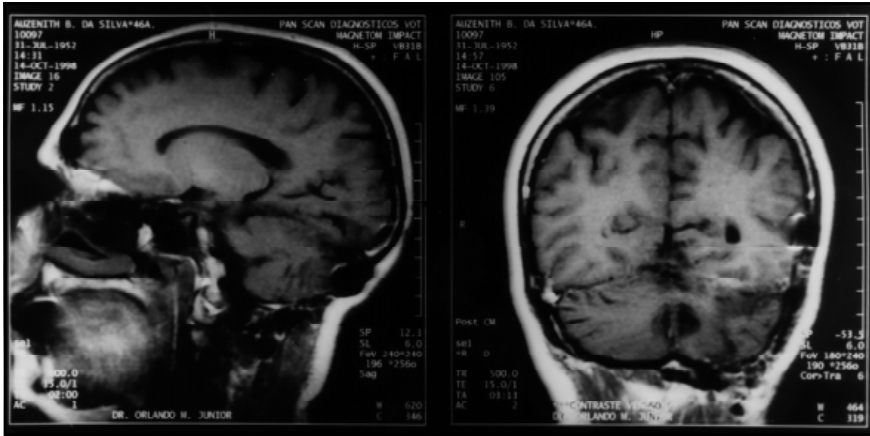


Fig 3. Post-operative MR sagittal and coronal image.

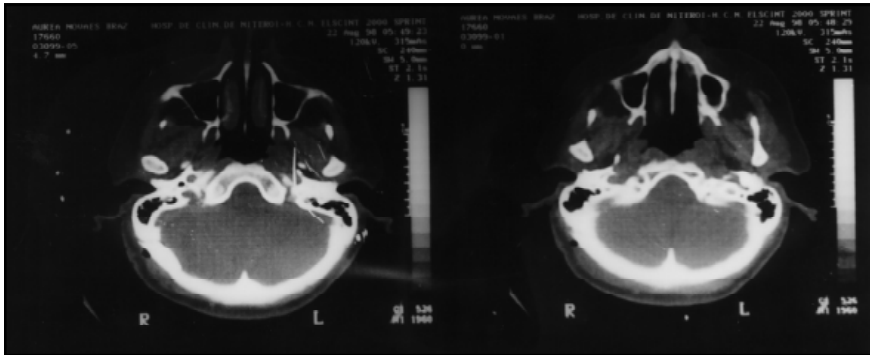


Fig 4a. Post operative CT after retro sigmoid craniotomy for trigeminal decompression on the right side (case 1).

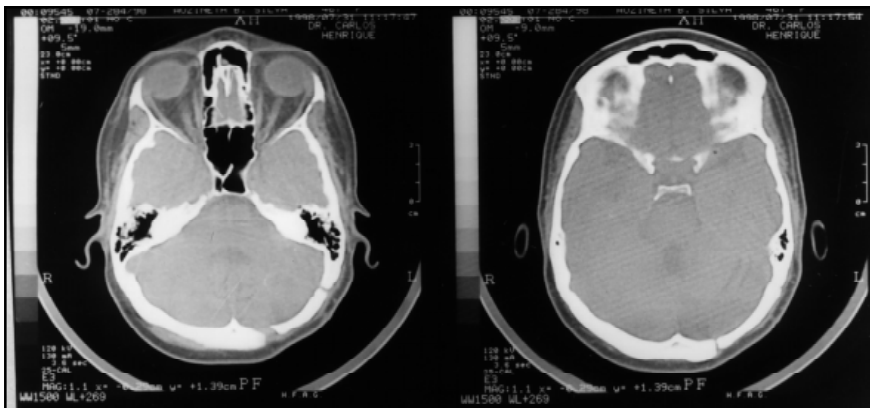


Fig 4b. Postoperative Ct scan showing the repositioned bone flap, after combined supra-infra tentorial approach on the left side (case 2).

Case 2. A 46 years old woman, with a large tentorial meningioma (Fig 2). A linear skin incision was made 3 cm away from the midline. Muscles were dissected away from the bone laterally both sides. Four burr holes were placed. The left superior one was made 1.5 cm above the transverse sinus and 1.5 cm away from the midline to avoid the torcula. The others were placed 5 cm from the first burr hole. Next, the dura was dissected carefully. The four burr holes were then connected, and a craniotomy flap was reflected (Fig 3). At the end of the surgery the dura was closed with running suture and some dura take-ups were placed. The bone was fixed with titanium mini plates. The muscle and the subcutaneous tissue were approximated and the skin was closed with staples.

The postoperative course was uneventful and the postoperative CT scan with bone window showed ideal position of the bone flap in both cases (Fig 4).

DISCUSSION

Satisfactory exposure of posterior fossa has been accomplished for decades using a craniotomy. Available instrumentation did not usually allow consideration of the bone flap. Reports from Yasargil and Fox³, Ogilvy and Ojemann⁴ proved that the replacement of the bone flap at the conclusion of the procedure in the posterior fossa is safe and easy to perform. Any approach relies on consideration of the surface and superficial anatomy for proper placement of opening⁷. This is especially important in posterior fossa approach.

The asterion is defined as the junction of the lambdoid, parietomastoid, and occiptomastoid sutures (Figs 1a and 1b). The asterion has been used as a landmark in lateral approaches to the posterior fossa. Day and Tschabitscher⁸ described that approximately 60% of the asterion are located over the transverse or sigmoid sinus complex in both sides. Indeed the asterion is not necessarily a reliable landmark in terms of location the underlying posterior fossa dura. Burr holes placed at the asterion may often open the bone directly over the sinus, leading to venous bleeding. We placed the first burr hole in the first case posteroinferior to the asterion. According with Mallis⁹ we prefer to drill the first burr hole approximately 2 cm medial to the mastoid or 1 cm medial to occiptomastoid suture. We do not use the asterion as a landmark to place the burr hole.

In the second case we placed four burr holes in the right side of the posterior fossa. The location of the inferior margin of the transverse sinus is quite accurately estimated at two fingers breadths above the mastoid notch (usually just above the superior nuchal line). Another important landmark on the bone is theinion that usually identifies the torcula and a straight line between the inion to the asterion that corresponds to the transverse sinus. Then, we placed two burr holes above the transverse sinus and two below. The four burr holes allow the surgeon to separate the dura from the bone completely and without any tears, and then craniotomy can be performed safely.

In our experience there is no increase in the operative morbidity or mortality when craniotomies (rather than craniectomies) were performed in the posterior fossa.

The literature reports some common complications after surgery of the posterior fossa such as: hematomas, edema, cerebrospinal fluid (CSF) leak and dural sinus tears. However the use of craniotomies do not necessarily increase the rate of these complications. In both cases the craniotomy allowed an excellent visualization but sometimes additional bone removal is performed with a drill to expose the limits of transverse sigmoid sinus complex as describe in the petrosal approach^{5,6}.

The replacement of the bone flap reestablishes normal anatomic planes at the conclusion of the procedure. This is specially important if a subsequent procedure is needed in the same location. The replacement of the bone flap also provides a better protection of the posterior fossa structures and a better cosmetic result. Some patients have complained of discomfort along the margins of the craniotomy. Additionally, replacement of the bone flap reduces this problem by prevention the sear formation between dura and muscles or subcutaneous tissue. A posterior fossa craniotomy can be performed by every neurosurgeon qualified to do a conventional craniotomy. Increased use and familiarity with high-speed air drills make possible this type of modification of standard neurosurgical procedures.

The replacement of the bone flap in the posterior fossa is a simple and safe procedure that represents a significant advance and option to the neurosurgical technical armamentarium.

REFERENCES

1. Al-Mefy O. Operative atlas of meningiomas, Philadelphia: Lipincott-Raven, 1998;425-429.
2. Yasargil MG. Microneurosurgery. Stuttgart: Thieme, 1986;1:238-244.
3. Yasargil MG, Fox JL: The microsurgical approach to acoustic neurinomas. *Surg Neurol* 1974;2:393-398.
4. Ogilvy CS, Ojemann RG. Posterior fossa craniotomy for lesions of the cerebellopontine angle: technical note. *J Neurosurg* 1993;78:508-509.
5. Al-Mefty O, Fox, JL, Smith RP. Petrosal approach: petroclival meningiomas. *Neurosurgery* 1988;22:510-517.
6. Al-Mefty O, Ayoubi S., Smith RP. The petrosal approach: indication, technique and results. *Acta Neurochir*: 1991;53(Suppl):166-170.
7. Day JD, Kellog JX, Tschabitscher M, Fukushima T. Surface and superficial surgical anatomy of the posterolateral cranial base: significance for surgical planning and approach. *Neurosurgery* 1996;38:1079-1084.
8. Day JD, Tschabitscher M. Anatomic position of the asterion. *Neurosurgery* 1998;42:198-199.
9. Mallis L. Anatomic position of the asterion (comments). *Neurosurgery* 1998;42:198-199.