

CEREBRAL ANEURYSMAL DILATATION IN AN INFANT WITH PERINATALLY ACQUIRED HIV INFECTION AND HSV ENCEPHALITIS

Magda Lahorgue Nunes¹, Ana Paula Silveira Pinho², Ana Sfoggia³

ABSTRACT - Although most children with human immunodeficiency virus (HIV) infection have neurological dysfunction, in childhood the incidence of symptomatic cerebrovascular disease is low. Cerebral aneurysmal arteriopathy in childhood AIDS has been reported in the past and considered to have a relatively long latency following the primary infection. We report a 1 month-old infant with congenitally acquired HIV infection, and herpes encephalitis; she presented a sudden cardiorespiratory arrest followed by coma and was found to have a giant saccular aneurysm of the left basilar artery. Literature review showed that cerebral aneurysmal arteriopathy is an unusual manifestation in newborns and infants and this case is possibly the youngest patient reported with aneurysma, herpes encephalitis and AIDS. The role of HIV and herpes simplex infections in the pathogenesis of this lesion is discussed.

KEY WORDS: AIDS, herpes simplex, cerebrovascular disease, infancy.

Aneurisma cerebral sintomático precoce em lactente com infecção congênita por HIV e encefalite herpética

RESUMO - A maioria das crianças com síndrome da imunodeficiência adquirida (SIDA) apresenta complicações neurológicas, mas a incidência de doença cerebrovascular sintomática nesta faixa etária é baixa. Existem relatos prévios de arteriopatía aneurismática em crianças com SIDA, mas a latência entre a infecção primária e o desenvolvimento dos sintomas geralmente é longa. Relatamos lactente com infecção congênita por HIV, que apresentou encefalite herpética e apresentou subitamente parada cardiorespiratória, seguida de coma. A investigação através de neuroimagem demonstrou aneurisma sacular gigante da artéria basilar. A revisão da literatura demonstra ser a arteriopatía aneurismática uma entidade rara no período neonatal e em lactentes, sendo possivelmente este o caso mais jovem até o presente relatado com doença cerebrovascular aneurismática associada a herpes e SIDA. A relação da associação entre SIDA e infecção por herpes vírus na gênese da doença cerebrovascular é discutida.

PALAVRAS - CHAVE: SIDA, herpes, doença cerebrovascular, infância.

The majority of children with human immunodeficiency virus (HIV) infection have neurological dysfunction but the development of symptomatic cerebrovascular disease is low (1.3%)¹. Central nervous system (CNS) involvement in pediatric AIDS may be due to primary HIV infection or to secondary complications of immunodeficiency². The proposed mechanisms for cerebrovascular disease in childhood AIDS include hypoperfusion, septic or thrombotic emboli, and infectious vasculitis of intracranial vessels³. It has been discussed whether the vasculitis is directed related to HIV or secondary to associated

infections such as herpes simplex virus (HSV), cytomegalovirus (CMV), varicella zoster virus (VZV), mycobacteria, or fungi^{1,3,4}. Cerebral artery aneurysms confined to large arteries of the circle of Willis have been previously described in HIV infected children, but a longer latency period following infection was necessary before onset of neurological symptoms. In the literature, the youngest patient reported had 2 years of age at AIDS diagnosis¹. The etiology for vasculitis is unknown, however, as HIV protein was detected in two autopsy cases a possibility of HIV vasculitis was raised^{1,2,5}.

Serviço de Neurologia do Hospital São Lucas e Faculdade de Medicina da Pontifícia Universidade Católica do Rio Grande do Sul (PUCRS). Porto Alegre, RS, Brasil: ¹Professora Adjunta de Neurologia; ²Mestranda do Curso de Pós-Graduação em Neurociências; ³Médica Residente do Departamento de Pediatria, Hospital São Lucas da PUCRS.

Received 23 June 2000, received in final form 5 September 2000. Accepted 14 September 2000.

Dra. Magda Lahorgue Nunes - Serviço de Neurologia do Hospital São Lucas PUCRS - Av. Ipiranga 6690 sala 220 - 90610-000 Porto Alegre RS - Brasil. FAX 51 339 4936. E-mail: magdalahorgue@conex.com.br

Neonatal herpes simplex virus (HSV) infection occurs in 1:2500-5000 deliveries and around 70% of the cases were related to HSV-2. However 95% of HSV encephalitis beyond the neonatal period are due to HSV-1. Central nervous system HSV disease often presents in the second to third week of life; however, only 60% of the newborns will develop skin lesions at any time during the illness⁶. VZV encephalitis is predominantly a vasculopathy involving small and large vessels and can lead to ischemic or hemorrhagic infarcts. The association of AIDS and VZV encephalitis was previously described in both adults and children^{4,7}.

CASE

A 1 month-old white girl, born at 38 weeks' gestation, birth weight adequate for gestational age, uncomplicated vaginal delivery, Apgar score 9 at the fifth minute, third pregnancy. The parents were found to be HIV positive during this pregnancy when their second son has died with respiratory complications secondary to AIDS. The oldest son was seronegative. The mother was started on treatment with zidovudine (AZT) from the 14th week of gestation. Immediately after deliver the newborn received an intravenous (IV) attack dose of AZT (180mg/m²) and prophylactic treatment, also with AZT, was started but not followed regularly.

At age 1 month and 12 days the child required hospitalization for severe gastroenteritis and dehydration followed by shock. Correction of acidosis, fluid therapy, blood transfusion and mechanical ventilation was necessary. Analysis of cerebrospinal fluid (CSF), blood, and urine for bacterial, viral, fungal and mycobacterial infection failed to reveal infection despite a white cell differential count shifted to the left. Antimicrobial therapy with ampicillin and gentamicin was initiated and she improved. Nine days later she presented with fever and in a blood culture grew *Staphylococcus aureus*. Vancomycin and imipenem were instituted. She was tested for HIV and the PCR (polymerase chain reaction) was negative although she had 3 previous positive ELISA and one Western-Blot. CD4⁺ (34.7%) and CD8⁺ (44.7%) lymphocyte counts were normal. AZT (2 mg/kg/dose) and didanosine (100 mg/kg/dose) were started. She persisted with low grade fever but without neurological symptoms.

Thirty-six days after admission she had a cardio-respiratory arrest probably due to milk aspiration, later in the same day she developed a "varicella-like" rash and high temperature persisted, acyclovir (500 mg/m²/dose, IV) was started. The neurological examination revealed coma, right hemiparesis and bilateral pyramidal tract dysfunction, episodes of generalized hypertonia were also described. Computerized tomography (CT) showed dilatation of the ventricles, blood in the occipital horns of the lateral ventricles, subarachnoid hemorrhage and a giant

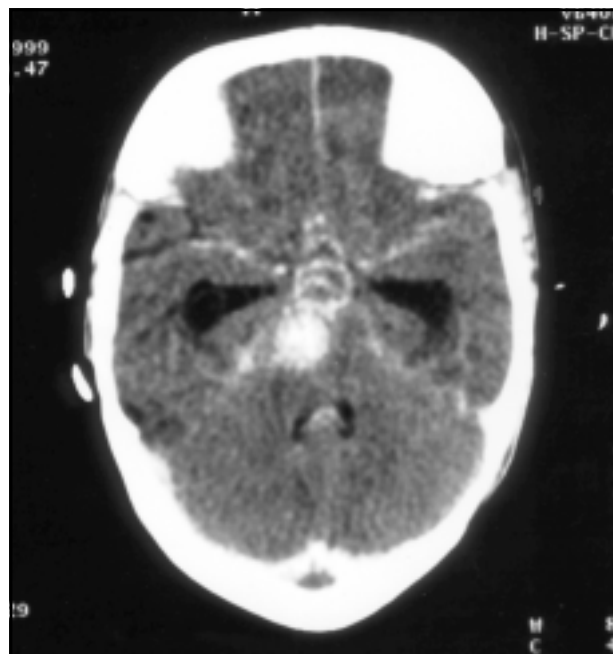


Fig 1. CT scan showing a giant saccular aneurysm possibly emerging from the left basilar artery.

saccular aneurysm (Fig 1). A new hematological, biochemical, infectious and stroke screening was performed with normal results except for an hemorrhagic CSF with elevated HSV titer (1300 UI/ml).

Coma and dependence to mechanical ventilation persisted and she died 12 days later. Permission for an autopsy was denied.

DISCUSSION

The risk of transmission from a HIV-infected pregnant woman to her newborn varies from 14% to 45%. Although the timing of transmission and the early diagnosis of HIV-1 infection during infancy are under active investigation. It seems that the severity of the illness in the mother is related to transmission rate⁸. Peculiarities of the newborn's immune system may influence the ability to distinguish an infected from a non infected infant; therefore, until 18 months of age, the infant's HIV status must be determined by documenting virus in the peripheral blood by culture, PCR or immune complex-dissociated p24 antigen (ICDp24)^{9,10}. In our case the diagnosis of HIV infection was suggested by positive ELISA and Western-Blot, history and clinical complications but was not confirmed by PCR. Nevertheless, it has been reported that before the age of 2 months 50% of congenitally acquired HIV patients can have negative PCR¹¹.

Neurological manifestations in childhood AIDS can be presented in unique features. Although the incidence of symptomatic cerebrovascular disorders

has been described as being low, many authors suggest that stroke should be considered whenever children with HIV infection develop focal neurological signs^{1,2,4}.

In the literature there are 14 pediatric patients reported as having AIDS and cerebral aneurysm. Their age range was 2-13 years, and the latency between diagnosis and neurological symptoms varied from 2 to 11 years^{1,2,5}. These reports suggest that the development of cerebral aneurysmal arteriopathy follows HIV infection. Perhaps the prolonged presence of the virus in an immune depressed CNS can lead to infiltration of cranial vessels and vasculitis appearance. Besides, some other pathogens such as HSV and VZV are also related to important CNS disorders and may also cause vasculitis^{6,7}.

In the present case the mother was already infected since the beginning of pregnancy, so we suppose the infant started the contact with the virus very early. In addition most of the cases previously reported with cerebral aneurysm and AIDS had the infection perinatally acquired¹. The localization of the aneurysms were all reported in the major arteries of the circle of Willis, as in our patient^{1,2}. The CD4 count was usually low suggesting a decline of their immune system¹, in our case the normal count may be explained by the early suspicion and prophylactic treatment started during pregnancy. Although the etiology of cerebrovascular complications of AIDS has not been yet completely understood, this symptomatic manifestations are rare and they can occur at very early ages. Concerning the case reported and other possible etiologies for the aneurysmal arteriopathy we excluded trauma (as the delivery was uneventfully) but we cannot exclude herpes infection. As it has been discussed, HSV may play a role

in the genesis of aneurysmal arteriopathy. However, pathological findings of herpes encephalitis in infants are much more characterized by ischemic and/or hemorrhagic infarcts of cortical and subcortical regions than aneurysmal arteriopathy.

The etiology of the aneurysmal malformation in this case is unknown, as we did not performed an autopsy, but we suggest that the association of CNS herpes infection and congenitally acquired HIV may have determine the beginning of vasculitis and justified the early appearance of the aneurysmal arteriopathy. This is the youngest patient in the literature where the association of these three disorders has been reported.

REFERENCES

1. Dubrovsky T, Curless R, Scott G, et al. Cerebral aneurysmal arteriopathy in childhood AIDS. *Neurology* 1998;51:560-565.
2. Park YD, Belman AL, Kim TS, et al. Stroke in pediatric immunodeficiency syndrome. *Ann Neurol* 1990;28:303-311.
3. Burns DK. The neuropathology of pediatric acquired immunodeficiency syndrome. *J Child Neurol* 1992;7:332-346.
4. Frank Y, Lim W, Kahn E, et al. Multiple ischemic infarcts in a child with AIDS, varicella zoster infection and cerebral vasculitis. *Pediatr Neurol* 1989;5:64-67.
5. Husson RN, Saini R, Lewis L et al. Cerebral artery aneurysms in children infected with human immunodeficiency virus. *J Pediatr* 1992;121:927-930.
6. Annunziato PW, Gershon A. Herpes simplex virus infection. *Pediatric in Review* 1996;17:415-425.
7. Amlic-Lefond C, Kleinnschmidt-De Masters BK, Mahalingam R, et al. The vasculopathy of varicella zoster virus encephalitis. *Ann Neurol* 1995;37:784-790.
8. European Collaborative Study. Risk factors for mother to child transmission of HIV-1. *Lancet* 1992;339:1007-1012.
9. Martin N, Levy J, Legg H. Detection of infection with human immunodeficiency virus (HIV) type 1 in infants by an anti-HIV immunoglobulin A assay using recombinant proteins. *J Pediatr* 1991;118:354-358.
10. Bryson Y, Luzuriaga K, Sullivan J, Wara D. Establishment of a definition of the timing of vertical HIV-1 infection. *N Engl J Med* 1992; 327: 1246-1247.
11. Martin N, Levy J, Legg H. Detection of infection with human immunodeficiency virus (HIV) type 1 in infants by an anti-HIV immunoglobulin A assay using recombinant proteins. *J Pediatr* 1991; 118:354-358.