

# LONG-TERM EVOLUTION OF PAPILLEDEMA IN IDIOPATHIC INTRACRANIAL HYPERTENSION

## Observations concerning two cases

*Elcio Juliato Piovesan, Marcos Cristiano Lange, Liciane do Rocio Maia Piovesan, Sergio Monteiro de Almeida, Pedro André Kowacs, Lineu Cesar Werneck*

**ABSTRACT** - Chronic headaches, associated with papilledema and pulsatile tinnitus without any neuroradiologic, cytochemical or cerebrospinal fluid abnormalities are suggestive of idiopathic intracranial hypertension (IIH). However the absence of the papilledema does not rule out this diagnosis. The reason why some patients do not develop papilledema in IIH is ignored, however there are some hypotheses concerning the structure of the optical nerve. In this study we described two female patients that presented diagnosis of IIH with papilledema, with subsequent resolution of papilledema without the due resolution of intracranial hypertension. The long-term behavior of the optic nerve (ON) facing an increased intracranial pressure was evaluated through repeated measurements of the intracranial pressure. We concluded that the ON submitted to high intracranial pressure for a certain length of time can adapt itself with subsequent disappearance of the papilledema. The presence or not of papilledema in IIH can be related to the period in which the diagnosis is accomplished.

**KEY WORDS:** headache, intracranial pressure, papilledema, pseudotumor cerebri.

### **Avaliação do comportamento do papiledema na hipertensão intracraniana idiopática: a propósito de dois casos**

**RESUMO** - Cefaléias com características crônica, diária, acompanhadas de edema de papila e tinnitus pulsátil, sem nenhum achado neuroradiológico ou citobioquímico no líquido, são altamente sugestivas de hipertensão intracraniana idiopática (HII). Entretanto a ausência do papiledema não invalida o seu diagnóstico. A razão pela qual alguns pacientes não desenvolvem papiledema na HII é desconhecida, porém algumas hipóteses relacionadas com propriedades intrínsecas da bainha do nervo óptico têm sido propostas. Neste estudo relatamos dois pacientes do sexo feminino que apresentaram diagnóstico de HII com papiledema, evoluindo para resolução do papiledema sem a devida resolução da HII. O comportamento do nervo óptico (NO) frente ao aumento da pressão intracraniana foi avaliado neste estudo a partir de um monitoramento intermitente criterioso da pressão intracraniana. Concluímos que o NO submetido a um período de hipertensão intracraniana pode adaptar-se a este ambiente promovendo uma resolução do papiledema para normalidade papilar. A presença ou ausência de papiledema na HII pode estar relacionada ao período no qual seu diagnóstico é realizado.

**PALAVRAS-CHAVE:** cefaléia, pressão intracraniana, papiledema, pseudotumor cerebral.

Idiopathic intracranial hypertension (IIH), also known as pseudotumor cerebri or benign intracranial hypertension, is associated to a group of symptoms in which the headache prevails over the others<sup>1</sup>. This headache is considered not to be associated with vascular intracranial disorders, and is accompanied or not by papilledema<sup>2</sup>. Several mechanisms may lead to the increase of the intracranial pressure, however all break of the dynamics of several intracranial structures leading to nociceptive stimulation and to a headache that presents with peculiar features<sup>3</sup>.

The presence of papilledema makes the diagno-

sis easier, however, its absence, much less frequent, it has been reported in several papers<sup>2</sup>. In this study we have followed-up two patients with the diagnosis of IIH for a period of 36 months. We have demonstrated that papilledema may subside during the course of this disease even without the remission of the intracranial hypertension.

### **METHOD**

#### *Study design*

Two patients with diagnosis of IIH were appraised and accompanied by a period of 36 months. The initial evalu-

---

Headache Section, Neurology Unit, Internal Medicine Department, Hospital de Clínicas da Universidade Federal do Paraná, Curitiba PR, Brazil.

Received 18 September 2001, received in final form 21 January 2002. Accepted 30 January 2002.

Dr. Elcio Juliato Piovesan - Serviço de Neurologia, Hospital de Clínicas - Rua General Carneiro 181/12º andar/sala 1236 - 80060-900 Curitiba PR - Brasil - FAX: 55 41 283 5512. E-mail: piovesan@avalon.sul.com.br

ation consisted of clinical and neurological examination and laboratorial work-up. All the patients were submitted to laboratorial evaluation of serum calcium, thyroid and parathyroid function tests, blood count, glucose, erythrocyte sedimentation rate (ESR), Kvein test and angiotensin-converting enzyme. Both patients underwent computerized axial tomography (CAT) and magnetic resonance imaging (MRI) of the head, cerebral angiography (CA) and fluorescein angiography (FG). To obtain pressure measurements and a sample of the cerebro-spinal fluid (CSF) for cellular, cytological, chemical, and bacteriological examination a lumbar puncture (LP) was carried out. The patients were also appraised by a physician, an ophtalmologist, an endocrinologist and a neurologist.

#### Patients

**Patient 1.** A 31 years-old white female, 155 cm of height and 76 kg of weight, had been seen by the same neurologist because of migraine an year before. Migraine had started when the patient was 13 and increased in intensity, duration and frequency in the preceding 6 months, evolving to a daily chronic headache (transformed migraine). In this occasion the neurological examination and the CAT were normal. For the treatment of the migraine propranolol 40 mg/day was prescribed for 60 days. Amitriptyline 50 mg/day and divalproex sodium (Depakote<sup>®</sup>) 500 mg/day were also tried without results. At he appoitment in which IIH was suspected, the intensity of the headache had increased, associated with transient visual abnormalities (photopsias) and noises in both ears (pulsatile tinnitus). Bilateral papilledema was observed. A second CAT was normal. Intracranial pressure was 430 mmH<sub>2</sub>O (graphic-1) and the cerebrospinal fluid (CSF) was normal. Magnetic resonance imaging (MRI) of the head revealed empty sella, and cerebral angiography (CA) was normal. Blood lab were normal. Fluorescein angiography (FG) revealed bilateral papilledema

(Fig 1-A). Acetazolamide 250 mg b.i.d. was started. Fifteen days later the headache had improved without resolution of the papilledema, but a new LP revealed an intracranial pressure of 530 mmH<sub>2</sub>O (Fig 2). Forty-five days after acetazolamide was started the papilledema had remitted. At this time, the frequency of the throbbing headaches was twice a week. They were bilateral, associated to nausea and vomiting. Six months later the patient presented no papilledema (Fig 1-B), photopsias or headaches. A new LP revealed an intracranial pressure of 320 mmH<sub>2</sub>O (Fig 2). During the following 24 months the patient continued without papilledema but with episodic headaches. Thirty months after the first evaluation the daily headaches had recurred. There was no papilledema and an ophtalmological evaluation was normal. A new LP was carried out, disclosing an intracranial pressure of 460 mmH<sub>2</sub>O (Fig 1-B) without papilledema. The patient refused a lumbo-peritoneal shunting. Currently the patient persists with chronic daily headache, without papilledema.

**Patient 2.** A 40 years-old, white female, 161 cm of height and 70Kg of weight, presented with a six month history of chronic daily headaches with pressing quality, bilateral location, mild to moderate intensity, increasing slowly during the day. Occasionally this headache increased in intensity, becoming throbbing and associated with nausea and/or vomiting. At the time of the appointment the patient also revealed myalgia, pulsatile tinnitus in both ears and low fever in the last five days. Bilateral papilledema was observed. The CAT revealed a left maxillary sinusitis. Intracranial pressure was 330 mmH<sub>2</sub>O (Fig 3) and the cerebrospinal fluid (CSF) revealed 26 leukocytes (95% polymorphonuclear), glucose of 64 mg/ml and 122 mg/ml of protein. Culture for fungus and virus were negative. For fifteen days she received only symptomatic medication for the treatment of viral meningitis. Thirty days after completing therapy the

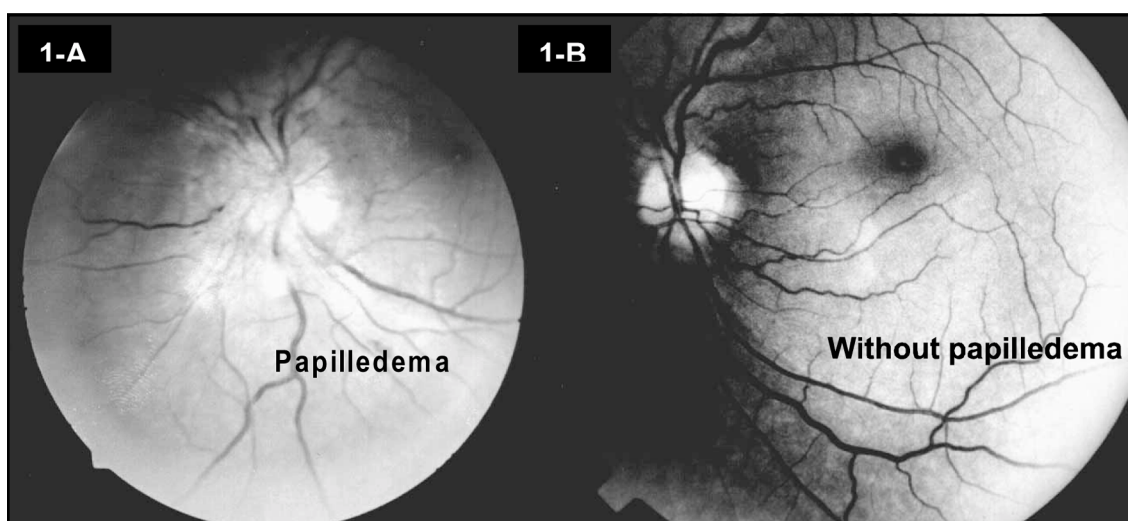


Fig 1. The behavior of the optic nerve during differents phases of the intracranial idiopathic hypertension. During the first phase the patient revelead papilledema, some months later the patient improved and revealed no more papilledema (patient 1).

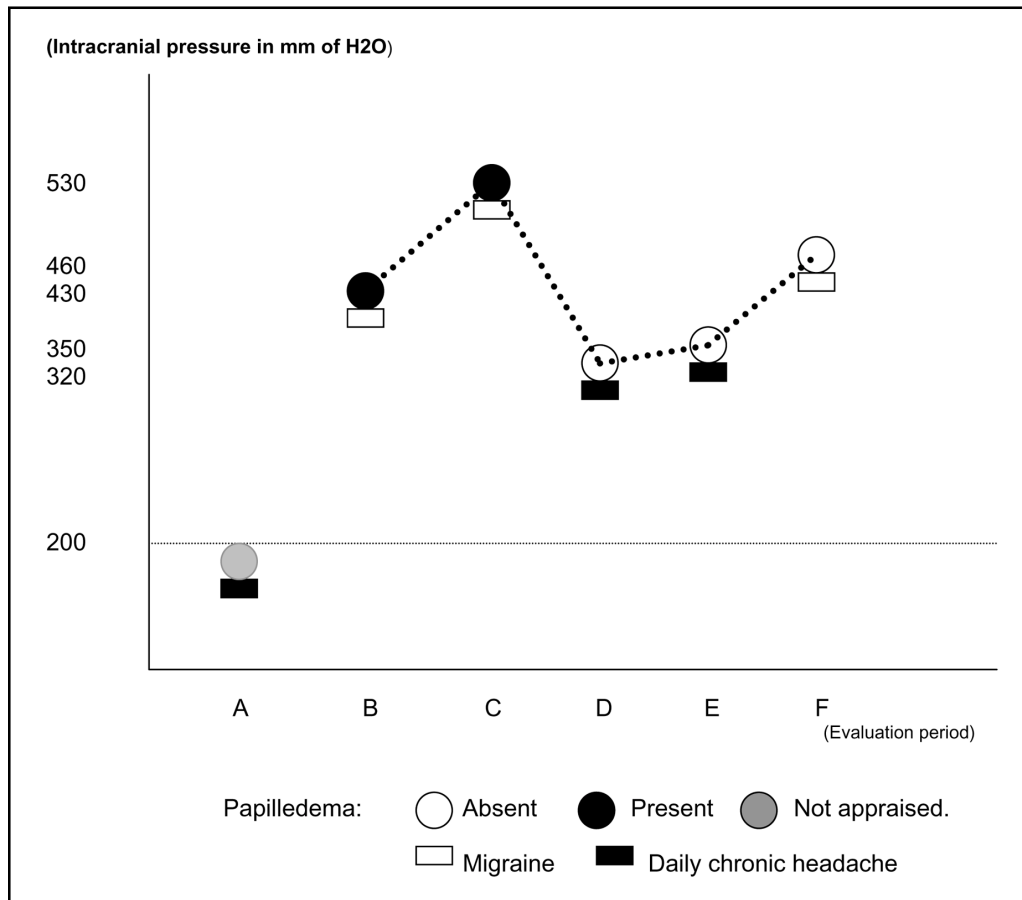


Fig 2. Evolution of the headache, intracranial pressure and papilledema. Patient 1 with the respective analysis period: A - previous to the diagnosis of IIH; B - in the moment of the diagnosis of IIH; C - 15 days later; D - 6 months later; E - 24 months later; F - 36 months later.

patient was still presenting papilledema and pulsatile tinnitus but her headache had improved. A new CSF examination disclosed normal results but intracranial pressure was 350 mmH<sub>2</sub>O (Fig 3). A MRI of the head revealed persistence of the left maxillary sinusitis and a CA was normal. During ten days the patient received floxacilin. The headache disappeared three months later, but not the papilledema. A new CAT of the facial sinus was normal. Another LP was carried out revealing a normal CSF but the intracranial pressure was 420 mmH<sub>2</sub>O (Fig 3). There was an elevated serum thyroid-stimulating hormone (TSH- 12.5yU/m), and reduced triiodothyroine (T3- 30ng/dl) and tetraiodothyronine (T4-2.3g/dl). Synthetic L-thyroxine 100 mg/day was prescribed. Fluorescein angiography (FG) revealed bilateral papilledema. Acetazolamide 250 mg b.i.d. was also prescribed. Six months after the treatment for the IIH and for the hypothyroidism the papilledema and the headache had disappeared. After one year the patient stopped the medication. Fifteen days later the pulsatile tinnitus and the headache reappeared without associated papilledema. The intracranial pressure was 380 mmH<sub>2</sub>O (Fig 3) and the CSF was still normal. Fluorescein angiography (FG) revealed

papillary pallor without papilledema. Again acetazolamide 250 mg b.i.d. was started with improvement of the symptoms after twenty days. A new LP revealed intracranial pressure of 250 mmH<sub>2</sub>O and a normal CSF (Fig 3). For thirty six months we followed up the patient. During this period three new episodes of headache were observed, when the intracranial pressure measurements were 340, 290 and 510 mm H<sub>2</sub>O (Fig 3) respectively. The patient did not agree to be submitted to a lumboperitoneal shunting.

## DISCUSSION

Intracranial pressure can be increased through out different mechanisms and several disorders. Those disorders may be either primary, secondary or atypical<sup>4</sup>. The syndrome of IIH occurs predominantly in obese women of childbearing age. Definitive diagnosis cannot be made without excluding brain tumours and other intracranial mass lesion, infections, hypertensive encephalopathy, pulmonary encephalopathy, and obstruction of the cerebral ventricles<sup>5</sup>.

IIH occurs at a frequency of about 1 case per 100 000

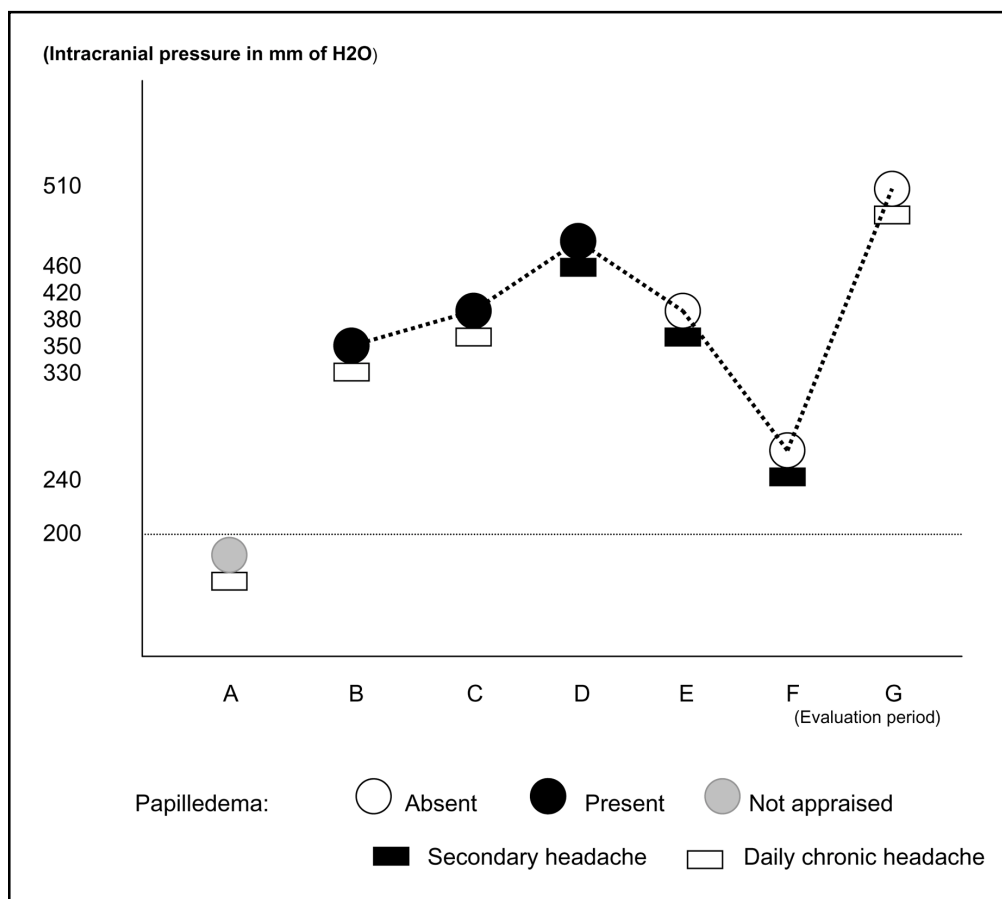


Fig 3. Evolution of the headache, intracranial pressure and papilledema. Patient 2 with the respective analysis period: A - previous to the diagnosis of IIH; B - in the moment of the diagnosis of IIH; C - 30 days later; D - 3 months later; E - 12 months and fifteen days later; F - 13 months and five days later; G - 36 months later.

per year in the general population and of 19.3 cases per 100 000 per year in obese women aged 20-44 years<sup>6</sup>. The pathophysiology of IIH is unknown, but some postulated hypothesized mechanisms are proposed: increase of the volume of the cerebral blood or of the CSF<sup>7</sup>; increase of the cerebral blood flow<sup>8</sup>; intracellular or extracellular edema<sup>9</sup>; abnormalities of the cerebral microvascular structures producing an increase in the amount of tissue water<sup>10</sup>; absorption disturbances of the CSF secondary to an increase of the pressure in the superior sagittal sinus<sup>11</sup>.

The most common symptoms are: headache, otalgia, diplopia, photopsias, vomiting, myalgia, dizziness and pulsatile tinnitus<sup>12,13</sup>. The typical characteristic of headache in the IIH are: severe intensity (93%); pulsating quality (83%); bilateral location (50%); associated to nausea and/or vomiting (57%), photophobia and phonophobia (30%) and photopsias (20%) with a daily frequency (73%) and lasting from four days to three years<sup>2,14-16</sup>. The mechanisms that produce these symptoms can be related to traction of the nociceptors located in the intracranial vessels; transitory

herniation of the hippocampal uncus; traction of cranial nerves (triplet and branches of C1, C2 and C3)<sup>2</sup>.

The pulsatile tinnitus presents a duration of seconds to days being unilateral in 62% of the cases. They are reported by the patients as "falls of a ray", "beat of a breeze", "heart pulsing in the ear" or eventually "blows in the hear"<sup>1,16</sup>. The patients can also present photopsias (presence of sparkles or flashes of light of variable duration, from seconds to hours). Less frequently, the patients refers pain in the shoulders and in the arm (probably due to dilation of the spinal roots)<sup>17</sup>. Bilateral retro ocular pain, occurring during movements of the head, are reported by 20% of the patients<sup>14,17</sup>.

The main abnormality disclosed by examination is papilledema, occasionally with hemorrhagic exudates<sup>13</sup>. However, its absence does not exclude IIH<sup>2,13,18-22</sup>. Paralysis of the abducent nerve, trochlear and facial paralysis<sup>23</sup> are also common findings. Less frequently nystagmus, bilateral intranuclear ophthalmoplegia, dissociation of pupillary reflex<sup>24</sup> and limi-

tation of the upper gaze may occur<sup>13</sup>. Rarely the patient may reveal ataxia<sup>12,13</sup> and the presence of a Babinski sign<sup>12</sup>.

Grant<sup>13</sup>, follow-up 79 children with IIH, showed that papilledema disappeared in 48% of the cases after 2 months, in 54% after 6 months, in 67% after one year, in 75% after two years, in 85% after 3 years and in 86% after 10 years. The optic atrophy was only observed respectively in two patients two and four years after the beginning of the treatment<sup>13</sup>. The most frequent sequelae of IIH is the loss of visual sharpness<sup>25,26</sup>. However many patients even with intracranial hypertension do not present papilledema. Why there is no papilledema in cases of intracranial hypertension is not known. Congenital or acquired optic nerve sheath defects, IIH with resolution of papilledema, or early idiopathic intracranial hypertension are alternative explanations<sup>5</sup>. Unilateral papilledema from IIH is an infrequent and rare situation<sup>27</sup>. The possible mechanisms that have been considered responsible for lack of papilledema in IIH include: an anomaly in the orbital optic nerve sheaths<sup>28</sup>; an abnormality in the venous sinuses; difference in the lamina cribosa between the two optic disc that results in reduced transmission of the intracranial pressure to the optic nerve in the scleral canal<sup>29</sup>; axoplasmic blockage at the level of the lamina cribosa induced by experimental elevated intracranial pressure<sup>30</sup>.

In both patients herein described, improvement of the papilledema was verified even in the presence of intracranial hypertension with daily chronic headache and pulsatile tinnitus. As seen in the first case, the patient presented with symptoms of daily chronic headache and the papilledema that, could had developed during the course of the disease, remitting afterwards. This observation has lead us to hypothesize that the optic nerve can behave in different ways during the evolution of this pathology, beginning without papilledema, with further development of papilledema that resolves later on. We believe that this pattern might be related to the fact that the retrograde axoplasmic flow and anterograde axoplasmic flow of the optic nerve behave distinctly during the different phases of this condition, mainly when oscillations of the intracranial pressure occur.

We believe that the finding or not of papilledema in IIH might reflect only the phase in which diagnosis of IIH is done. In this condition, the presence of the papilledema can be transitory.

## REFERENCES

1. Wall M, George D. Idiopathic intracranial hypertension: a prospective study of 50 patients. *Brain* 1991;114:155-180.
2. Marcellis J, Silbertein SD. Idiopathic intracranial hypertension without papilledema. *Arch Neurol* 1991;48:392-399.
3. Classification and diagnostic criteria for headache disorders, cranial neuralgias and facial pain. *Cephalalgia* 1988;8(Suppl 7):51.
4. Wald SL. Disorders of cerebrospinal fluid circulation and brain edema. In Bradley WG, Daroff RB, Fenichel GM, Marsden CD (eds). *Neurology in clinical practice*. 2.Ed. Boston: Butterworth-Heinemann, 1996: 1431-1458.
5. Silbertein SD, Lipton RB, Goadsby PJ. Headache in clinical practice. Headache associated with non-vascular intracranial disease. Oxford: Isis Medical Media, 1998:143-164.
6. Durcan FJ, Corbett JJ, Wall M. The incidence of pseudotumor cerebri: population studies in Iowa and Louisiana. *Arch Neurol* 1988;45:875-877.
7. Dandy WE. Intracranial pressure without brain tumor: diagnosis and treatment. *Ann Surg* 1937;106:492-513.
8. Foley J. Benign forms of intracranial hypertension "toxic" and "otitic" hydrocephalus. *Brain* 1955;78:1-41.
9. Sahs AL, Joynt RJ. Brain swelling of unknown cause. *Neurology* 1956;6:791-803.
10. Raichle ME, Grubb RL, Phelps ME, Gado MH, Caronna JJ. Cerebral hemodynamics and metabolism in pseudotumor cerebri. *Ann Neurol* 1978;48:740-747.
11. Johnston I, Hawke S, Halmagyim M, Teo C. The pseudotumor syndrome: disorders of cerebrospinal fluid circulation causing intracranial hypertension without ventriculomegaly. *Arch Neurol* 1991;48:740-747.
12. Dhiravibulya K, Ouvrier R, Johnston I, Procopis P, Antony J. Benign intracranial hypertension in childhood: a review of 23 patients. *J Paediatr Child Health* 1991;27:304-307.
13. Grant DN. Benign intracranial hypertension: a review of 79 cases in infancy and childhood. *Arch Dis Child* 1971;46:651-655.
14. Wall M. The headache profile of idiopathic intracranial hypertension. *Cephalalgia* 1990;10:331-335.
15. Weisberg LA. Benign intracranial hypertension. *Medicine* 1975;54:197-207.
16. Schoenen J, Noordhout AM. Headache. In Wall PD, Melzck R. (eds) *Textbook of pain*. 3.Ed. New York: Churchill Livingstone, 1994:511-512.
17. Giuseffi V, Wall M, Siegel PZ, Rojas PB. Symptoms and disease associations in idiopathic intracranial hypertension (pseudotumor cerebri): a case-control study. *Neurology* 1991;41:239-244.
18. Bortoluzzi M, DiLauro L, Marini G. Benign intracranial hypertension with spinal and radicular pain. *J Neurosurg* 1982;57:833-836.
19. Winner P, Bello L. Idiopathic intracranial hypertension in a young child without visual symptoms or signs. *Headache* 1996;36:574-576.
20. Spence JD, Amacher AL, Willis NR. Benign intracranial hypertension without papilledema: role of 24 hour cerebrospinal fluid pressure monitoring in diagnosis and management. *Neurosurgery* 1980;7:326-336.
21. Scanari M, Mingrino S, d'Avella D, DellaCort V. Benign intracranial hypertension without papilledema: a case report. *Neurosurgery* 1979;5:376-377.
22. Lipton HL, Michelson PE. Pseudotumor cerebri syndrome without papilledema. *JAMA* 1972;220:1591-1592.
23. Lessel S. Pediatric pseudotumor cerebri (Idiopathic intracranial hypertension). *Surv Ophthalmol* 1992;37:155-166.
24. Baker RS, Baumann RJ, Bunice JR. Idiopathic intracranial hypertension (pseudotumor cerebri) in pediatric patients. *Pediatr Neurol* 1989;5:5-11.
25. Baker RS, Carter D, Hendrick BE, Buncic RJ. Visual loss in pseudotumor cerebri of childhood: a follow-up study. *Arch Ophthalmol* 1985;103:1681-1686.
26. Rush JA. Pseudotumor cerebri: clinical profile and visual outcome in 63 patients. *Mayo Clin Proc* 1980;55:541-546.
27. Huna-Baron R, Landau K, Rosenberg M, Warren FA, Kupersmith MJ. Unilateral swollen disc due to increased intracranial pressure. *Neurology* 2001;56:1588-1590.
28. Moster ML. Unilateral disk edema in a young woman. *Surv Ophthalmol* 1995;39:409-416.
29. Monteiro MLR, Hoyt WF, Imes RK, Narahara M. Papilledema unilateral na síndrome de pseudotumor cerebral. *Arq Neuropsiquiatr* 1985;43:154-159.
30. Tso MOM, Hayreh SS. Optic disc edema in raised intracranial pressure, IV: axoplasmic transport in experimental papilledema. *Arch Ophthalmol* 1997;95:1458-1462.