

# ORGANOPHOSPHATE-INDUCED DELAYED NEUROPATHY

## Case report

*Luiz Felipe R Vasconcellos<sup>1</sup>, Ana Cláudia Leite<sup>1</sup>, Osvaldo J M Nascimento<sup>2</sup>*

**ABSTRACT** - Organophosphate induced delayed neuropathy (OPIDN) is an uncommon clinical condition. It occurs in association with the ingestion of great amounts of organophosphate after the stimulation of cholinergic receptor. The clinical picture is characterized by a distal paresis in lower limbs associated with sensitive symptoms. Electrodiagnostic studies show a motor axonal neuropathy. Involvement of the central nervous system may occur. We describe a 39 years-old female patient who developed hyperesthesia associated with lower limbs paresis, fourteen days after she had ingested a Dichlorvos-based insecticide. Electrophysiological study was characterized by an axonal polyneuropathy pattern. Pyramidal tract dysfunction was observed later in upper limbs. Considering that both peripheral and central nervous systems are involved we believe that the more appropriated term would be organophosphate induced delayed neuropathy (OPIDN) instead of organophosphate induced delayed polyneuropathy (OPIDP).

**KEY WORDS:** neuropathy, polyneuropathy, organophosphate.

### **Neuropatia tardia por organofosforado: relato de caso**

**RESUMO** - A neuropatia tardia dos organofosforados (NTOF) é condição clínica incomum. Geralmente ocorre após a intoxicação aguda por organofosforados, seguindo-se a fase de hiperestimulação colinérgica. O quadro clínico é caracterizado por déficit motor distal nos membros inferiores associado a sintomas sensitivos. O estudo eletroneuromiográfico tem demonstrado padrão axonal motor na maioria dos casos. Podem ocorrer sinais de comprometimento do sistema nervoso central. Descrevemos o caso de uma paciente de 39 anos que ingeriu inseticida a base de Dichlorvos e quatorze dias após apresentou quadro de hiperestesia associado a paresia distal nos membros inferiores. Realizou eletroneuromiografia que se caracterizou por padrão compatível com polineuropatia axonal. Sinais piramidais, de aparecimento mais tardio, foram observados nos membros superiores. Diante do comprometimento do sistema nervoso periférico e central, também consideramos o termo neuropatia tardia por organofosforado (NTOF) mais adequado do que tão somente polineuropatia tardia por organofosforado (PTOF).

**PALAVRAS-CHAVE:** neuropatia, polineuropatia, organofosforados.

Organophosphate induced delayed neuropathy (OPIDN) is a sensory-motor distal axonopathy which usually occurs after the ingestion of large doses of certain organophosphate insecticides. Most of the patients developed a mixed polyneuropathy, mainly motor<sup>1</sup>. The neurotoxic effects of organophosphates have been well known since the dramatic outbreak of "Ginger Jake Paralysis", which crippled as many as 50 000 in the USA in the 1930's<sup>2</sup>. Since then several other epidemics have occurred in different regions such as in Sri Lanka<sup>3</sup>. In this epidemic area, adolescent Tamil girls attaining menarche or women right after

childbirth were affected and developed polyneuropathy between fourteen and thirty days after gingili oil ingestion, following local customs and tradition. Recovery from OPIDN is considered to be generally poor. It is possible that several other factors such as the age of the patients, the difference in the chemical structure of the organophosphate and the duration of initial intoxication in some way contribute towards a favorable outcome<sup>4</sup>.

Organophosphorus poisoning could be separated in three phases (acute cholinergic effects, intermediate syndrome and organophosphate-induced dela-

Institute of Neurology Deolindo Couto, Federal University of Rio de Janeiro (INDC-UFRJ), Rio de Janeiro RJ, Brasil; and Department of Neurology, Federal Fluminense University (UFF), Niteroi RJ, Brasil; <sup>1</sup>Medical Doctor (INDC-UFRJ), <sup>2</sup>Full Professor (UFF).

Received 17 June 2002, received in final form 4 July 2002. Accepted 18 July 2002.

*Dr. Luiz Felipe Rocha Vasconcellos - Rua Barão da Torre, 209/102 B - 22411-001 Rio de Janeiro RJ - Brasil. FAX: 55 21 2284 3698. E-mail: luizfrv@ig.com.br*

yed neuropathy). Our aim is to relate a case of a patient who showed all the three stages of the intoxication and was admitted to the hospital to investigate a subacute predominantly motor peripheral neuropathy.

### CASE

A female patient, 39 years old, in an attempt to commit suicide, took a large amount of an organophosphate insecticide around three weeks before being admitted to the hospital. She developed a strong abdominal pain, salivation, diarrhea and lacrimation a few hours after the ingestion of the insecticide. At the time of the suicide attempt the patient was showing miotic pupils and received atropine as treatment with partial improvement of symptoms; 24 hours after the appearance of the initial symptoms the patient presented respiratory fatigue followed by respiratory insufficiency, and mechanical ventilation was required. She stayed for 48 hours under assisted ventilation without respiratory drive. After that, she was submitted with success to a discontinuation of the mechanical ventilation. She received hospital discharge without showing any symptoms. However, two weeks after the first discharge she started having cramping calf pain and hyperesthesia in the plantar area followed by distal weakness in the lower limbs and, two days after, in the upper limbs. With those neurological deficits the patient was referred to INDC-UFRJ hospital and admitted. At this time the pa-

tient was already recovering the strength of the upper limbs while keeping a motor deficit in the lower ones. The sensitive complains in any way persisted. The neurological examination revealed hands amyotrophy (Figs 1 and 2), equine gait, distal motor deficit in lower limbs (+/5+) and increased reflex response in the upper limbs with Hoffman sign. The patellar reflexes were present and symmetric whereas the Achilles tendon reflex was absent. Babinski sign was not observed. Cranial nerves were not involved. There was loss of temperature discrimination and nociception in distal lower limbs. Touch pressure, vibratory and joint position senses were not involved.

Electrophysiological examination (Table 1) disclosed positive sharp waves and fibrillation in the four limbs. Reduced amplitudes of the compound muscle action potentials (CMAP) with mildly reduced motor nerve conduction velocity (MNCV) of ulnar nerve in the upper limbs. Sensory nerve action potentials (SNAP) were normal in the upper and mildly reduced in the lower limbs. CMAPs were not elicited in the lower limbs. These findings are consistent with a predominant motor axonal polyneuropathy involving mostly the lower limbs. She was treated with amitriptyline (50mg/d), carbamazepine (600mg/d), capsaicin, thiamin (300mg/d) and physiotherapy, which resulted in a partial control of the hyperesthetic pain.

### DISCUSSION

Organophosphate esters are used as insecticides, petroleum additives, modifiers of plastics, lubricants, antioxidants and flame-retardants. They may be absorbed via skin or respiratory and gastrointestinal tracts<sup>5</sup>. The liposolubility allows a penetration in the central and peripheral nervous systems<sup>6</sup>. The organophosphorus associated with neuropathy are tri-o-cresyl phosphate (TOCP), leptophos, mipafox, chlorphos, trichlorfon, malation, paration, metrifonate and metamidophos<sup>7</sup>. The most dangerous OP ester is TOCP.

The clinical sequence could be divided in three steps:

*Type 1 syndrome:* Excessive stimulation of muscarinic receptors is responsible for intense cholinergic effects, which are always apparent within a day of exposure, often within hours. Cholinergic symptoms include tachycardia or bradycardia, diarrhea, vomiting, fasciculation, sweating, salivation and micturition. Excessive exposure causes emotional irritability, nervousness, fatigue, diminished alertness, cognitive impairment, coma and convulsion. The treatment in all cases is atropine in varying doses depending on the clinical state<sup>5</sup>.

*Type 2 syndrome (intermediate syndrome):* It follows the intense cholinergic crisis of organophosphorus poisoning and occurs in up 20%-50% of cases depending on the severity of poisoning, its duration, and on the type of organophosphorus compound.

Table 1. Electrophysiological study.

	Normal values	Patient 07/11/2000
Motor nerve conduction		
<i>CMAP amplitude (mV)</i>		
R Median	> 4	0.2
R Ulnar	> 4	2.3
R Peroneal	> 2	NR
<i>Muscle NCV (m/s)</i>		
R Median	> 52	54.6
R Ulnar	> 57	53.5
R Peroneal	> 44	NR
<i>Distal latency (ms)</i>		
R Median	< 4	4.2
R Ulnar	< 3.7	4.0
R Peroneal	< 6	NR
Sensory nerve conduction		
<i>SNAP amplitude (µV)</i>		
R Median	> 15	34.8
R Ulnar	> 10	31.2
R Sural	> 6	5.2

R, right; CMAP, compound muscle action potential; NCV, nerve conduction velocity; SNAP, sensory nerve action potential; NR, No response.

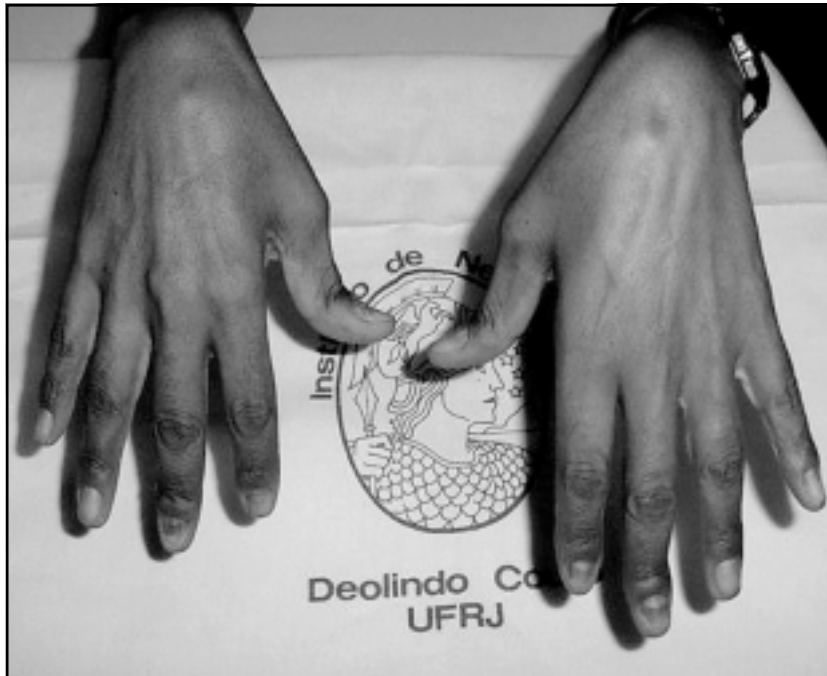


Fig 1. Dorsal surface of hands showing interosseous atrophy.

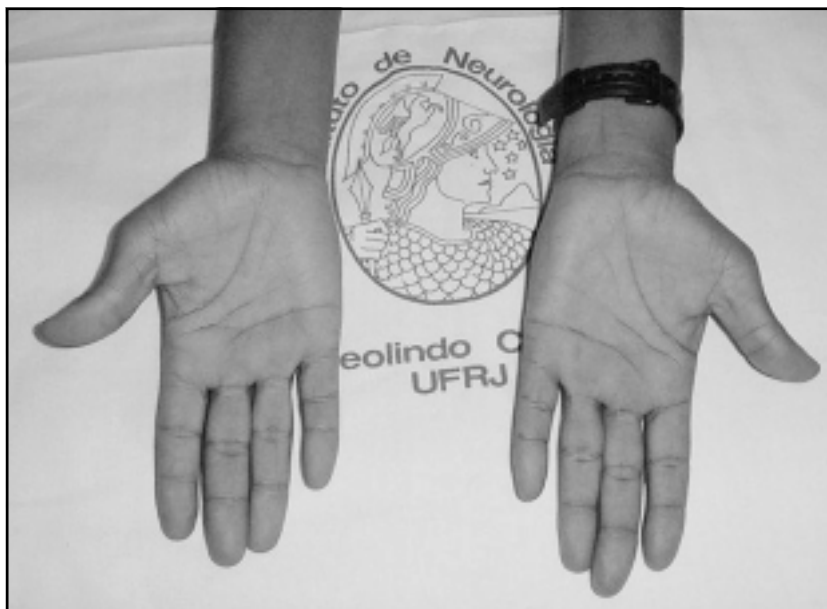


Fig 2. Palmar surface showing tenar and hypotenar atrophy.

There are no associated autoimmune phenomena. Some authors propose that poor regulation of acetylcholine receptors (AChRs) could explain the syndrome and neurophysiological findings<sup>8</sup>. Other symptoms occur usually 24 to 96 hours after the poisoning on the recovery from the cholinergic crisis. The cardinal features comprise muscular weakness, affecting predominantly the proximal limbs muscles and neck flexors. Cranial-nerve palsies are common. Unlike the delayed polyneuropathy, this syndrome carries death

risk due to associated respiratory depression. The clinical courses may last from 5 to 18 days<sup>9</sup>.

*Type III syndrome (organophosphate induced delayed neuropathy-OPIDN):* many organophosphorus esters (OPs) may cause a distal dying back axonopathy characterized by cramping muscle pain in the legs, paresthesia, and motor shortcoming beginning 10 days to 3 weeks after the initial exposure. OPIDN associated signs include foot drop, weakness of the intrinsic hand muscles, absent ankle jerks and weak-

ness of hip and knee flexors. The course is usually subacute and occurs within two weeks after the initial symptoms. The OPIDN is a predominantly motor neuropathy<sup>10</sup>.

After ingesting Dichlorvos, our patient presented all signals and symptoms of the three phases of intoxication by organophosphate, a fact that shows that the quantity ingested was substantial. Rarely, some OPs produce delayed neurotoxicity with the onset of clinical symptoms occurring one or two weeks after the exposure. This delayed effect is the result of phosphorylation of nervous tissue protein with resulting wallerian axonal degeneration.

Fisher described a patient who was exposed to OPs and had no acute manifestations of OPs toxicity but developed polyradiculitis, cranial nerve involvement, elevated cerebral spinal fluid (CSF) protein level, and electromyography (EMG) pattern characteristics of the Guillain-Barré syndrome<sup>11</sup>. Other rare clinical presentation after intense organophosphate poisoning was also described by Bekarovski et al.<sup>12</sup>. These authors presented a complete outline of parkinsonism which persisted after recovery from cholinergic symptoms. The patient ingested an unknown dose of OPs in a suicide attempt and developed all phases of OP intoxication. After two weeks of poisoning he developed tremor and rigidity that disappeared under treatment with Biperiden.

OPIDN is an uncommon cause of polyneuropathy (PNP). Therefore, during investigation of the causes of peripheral neuropathy it is important to review the history of exposure to toxic substances. These intoxications should also be part of the differential diagnostic of paraparesis since the participation of CNS on the intoxication by OPs only becomes evident after several years of exposition to OPs<sup>10</sup>.

The pathogenesis of OPIDN involves the phosphorylation and inhibition of neuropathy target esterase (NTE). This enzyme is present in brain, spinal cord and peripheral nerve, as well as in non-neural tissues and cells such as spleen, muscle and lymphocytes<sup>10</sup>. The function of NTE is unknown. The ability to inhibit NTE does not necessarily characterize an OP as neurotoxic because some OPs inhibit the NTE but do not produce OPIDN<sup>10</sup>.

The OPIDN is predominantly motor. Weakness appears early and initially involves legs muscles before those of the hands. Despite the paucity of sensory complaints, objective evidence of the sensory loss is almost always present. Sensitive symptoms as well as paresthesia and hyperesthesia are frequent. Pro-

ximal weakness may be present in severe cases. In the present case, despite the initial seriousness, we did not observe clinical involvement of the proximal muscles of the four limbs. The installation was subacute with gradual worsening, increased in the second week.

Patients with severe deficits may not recover completely. There may be residual claw hand deformity, persistent atrophy, and foot drop, as well as spasticity and ataxia<sup>5</sup>. The most important differential diagnosis that should be considered in OPIDN include Guillain-Barré syndrome and acute disseminated encephalomyelitis<sup>7</sup>.

Electrodiagnostic studies of OPIDN demonstrate an axonal neuropathy with acute and chronic denervation in distal and occasionally proximal limb muscles. Despite symptoms being predominantly motor, diminished sensory potential amplitudes appear to be more sensitive than motor conduction changes in screening for OPIDN. Motor conduction studies are either normal or minimally slowed. The CSF is usually acellular, and protein levels are either normal or slightly elevated<sup>5</sup>. Consequently, this examination procedure is not relevant for diagnosis. The electrodiagnosis examination carried out in our patient indicated axonal neuropathy, mainly in the lower limbs, involving motor nerves with signs of denervation.

The incidence of pyramidal tract dysfunction is high but the presentation is delayed. In the Senanayake's series<sup>4</sup>, nearly 50% of patients had some evidence of pyramidal tract dysfunction although the signs were relatively mild. In the study carried out by Agapejev et al<sup>6</sup>, in patients with a history of exogenous intoxication, it was proved that the central lesion was more frequent, probably due to the liposolubility of these substances.

For this reason Khurana and Prabhakar<sup>13</sup> suggested that this syndrome, although known as organophosphate-induced delayed polyneuropathy, is inappropriately labeled because pyramidal involvement is usually present; initially, peripheral nerve involvement predominates, while corticospinal tract signs evolve more slowly. Our patient showed hyperreflexia of the upper limbs, with signs of pyramidal tract involvement. Thus, our suggestion of the term Organophosphate Induced Delayed Neuropathy-OPIDN seems more suitable. There is no specific treatment for OPIDN. The use of thiamin is recommended by some authors but it does not alter the appearance of OPIDN<sup>6</sup>. Hyperesthesia can be controlled with the use of amitriptyline, carbama-

zepine and capsaicin, associated or not. Our patient recovered slightly from hyperesthetic pain in plantar areas. Physiotherapy is also indicated in these cases. In a study carried out by Senanayde<sup>4</sup> with twenty patients, the only form of treatment was physiotherapy, mainly walking exercises from two to six weeks during the initial period in hospital. The lower motor neuron signs and sensory findings began to improve and almost completely disappeared at the end of one year.

It is possible that several others factors such as age of patients, the difference in the chemical structure of OPs and the duration of initial intoxication had also, in some way, contributed towards the favorable outcome<sup>4</sup>. The degree of pyramidal tract damage had been a major determinant of the prognosis for functional recovery in previous episodes. After recovering from the acute effects the patients may develop spastic paraparesis. The follow up of these patients should be done over at least four weeks after the acute intoxication<sup>14</sup>. Recovery in most cases is incomplete. Our patient was discharged from the hospital five weeks after initial exposure to the OPs. After three months she presented a partial control of the pain. The motor function improved gradually. There are brisk reflexes in the upper limbs.

Ingestion of organophosphate, either accidental or suicidal should be considered in cases of neuropathy, even if the initial phases of intoxication are not clinically well defined.

**Acknowledgment** - The authors wish to thank Dr. Glória Penque for her help with the electromyography measurements and Dr. João Klescoski for his help with the photos.

## REFERENCES

1. Moretto A, Lotti M. Poisoning by organophosphorus insecticides and sensory neuropathy. *J Neurol Neurosurg Psychiatry* 1998;64:463-468.
2. Morgan JP, Penovich P. Jamaica ginger paralysis: forty-seven year follow-up. *Arch Neurol* 1978;35:530-532.
3. Senanayake N, Jeyaratnam J. Toxic polyneuropathy due to gingili oil contaminated with tri-cresyl phosphate affecting adolescent girls in Sri Lanka. *Lancet* 1981;1:88-89.
4. Senanayake N. Tri-cresyl phosphate neuropathy in Sri Lanka: a clinical and neurophysiological study with a three year follow up. *J Neurol Neurosurg Psychiatry* 1981;44:775-780.
5. Berger AR. Toxic peripheral neuropathies. In Samuels MA, Feske, S, (eds). *Office practice of neurology*. New York: Churchill Livingstone, 1996:538-539.
6. Agapejev S, Vassiliev I, Lima MMF. Neurologic manifestations in 93 patients with exogenous intoxication by non-medicamentous chemical substances. *Arq Neuropsiquiatr* 1986;44:232-242.
7. Araújo AQ-C. Organophosphorus polyneuropathy. *Rev Bras Neurol Psiqu* 1997;1:75-77.
8. Sedgwick EM, Senanayake N. Pathophysiology of the intermediate syndrome of organophosphorus poisoning. *J Neurol Neurosurg Psychiatry* 1997;62:201-202.
9. Senanayake N, Karalliedde L. Neurotoxic effects of organophosphorus insecticide - an intermediate syndrome. *N Engl J Med* 1987;316:761-763.
10. Schaumburg HH, Berger AR. Toxic neuropathy due to industrial agents. In Dyck PJ, Thomas PK, Griffing JW, Low PA, Poduslo JF (eds). *Peripheral neuropathy*. 3.Ed. Philadelphia: W B Saunders; 1993:1541-1548.
11. Fisher JR. Guillain-Barré syndrome following organophosphate poisoning. *JAMA* 1977;238:1950-1951.
12. Bekarovski N, Radulovic S. Parkinsonism after organophosphate poisoning. *J Neurol Sci* 2001;187(Suppl 1):S101(P0286).
13. Khurana D, Prabhakar S. Organophosphorus intoxication. *Arch Neurol* 2000;57:600-602.
14. Senanayake N, Johnson MK. Acute polyneuropathy after poisoning by a new organophosphate insecticide. *N Engl J Med* 1982;306:155-157.