

# HYPERTROPHIC PACHYMENINGITIS

## Case report

*Leonardo de Deus-Silva<sup>1</sup>, Luciano de Souza Queiroz<sup>2</sup>, Verônica de Araújo Zanardi<sup>4</sup>, Enrico Ghizoni<sup>1</sup>, Hoyama da Costa Pereira<sup>1</sup>, George Linard Silva Malveira<sup>1</sup>, Clodoaldo Pirani Jr<sup>1</sup>, Benito Pereira Damasceno<sup>3</sup>, Fernando Cendes<sup>3</sup>*

**ABSTRACT** - Hypertrophic pachymeningitis is an unusual cause of neurological symptoms and is often secondary to infections, carcinomatosis or inflammatory diseases. It may also be idiopathic. We report a case of pachymeningitis which was manifested primarily by psychosis and visual loss with optic atrophy and destruction of nasal septum. The patient, a 45 year old woman was submitted to extensive investigation without evidence of any underlying disease. A meningeal biopsy was performed and showed a mostly unspecific inflammatory process with extensive fibrosis of the dura and few early stage granulomas. These findings suggest either neurosarcoidosis or idiopathic hypertrophic pachymeningitis.

**KEY WORDS:** hypertrophic pachymeningitis, neurosarcoidosis, psychosis, optic neuropathy.

### **Paquimeningite hipertrófica: relato de caso**

**RESUMO** - Paquimeningite hipertrófica é uma causa incomum de sintomas neurológicos, sendo frequentemente secundária a infecções, carcinomatose ou doenças inflamatórias. Pode também ser idiopática. Relatamos um caso de paquimeningite que se manifestou inicialmente por psicose e diminuição da acuidade visual com atrofia óptica e destruição do septo nasal. A paciente, de 45 anos de idade, foi submetida a extensa investigação, não sendo evidenciada nenhuma doença de base. Foi realizada biópsia de meninge, a qual evidenciou um processo inflamatório com intensa fibrose e raros granulomas em estágio inicial. Esses achados sugerem neurosarcoidose ou paquimeningite hipertrófica idiopática.

**PALAVRAS-CHAVE:** paquimeningite hipertrófica, neurosarcoidose, psicose, neuropatia óptica.

Pachymeningitis is an inflammatory process of the dura-mater, which may lead to fibrous thickening. It can be caused by a variety of diseases, including sarcoidosis, tuberculosis and syphilis<sup>1</sup>. In some cases, even after extensive investigation, no specific cause is found and the process is called idiopathic intracranial pachymeningitis<sup>2</sup>.

We report a patient who presented a very heterogeneous clinical picture associated with pachymeningitis and destruction of nasal septum.

### **CASE**

A 45 year-old woman was admitted for assessment of progressive visual loss associated with psychosis. She was previously healthy when four years before admission she presented acute nasal obstruction accompanied by purulent nasal discharge and progressive deformity, with

subsequent destruction of the nasal septum. She was submitted to surgical repair of the nose deformity at another hospital. At that time no specific etiology was found and she was released with a diagnosis of chronic rhinitis. She continued to have episodes of nasal congestion with non-purulent nasal discharge that did not respond to treatment with local corticosteroids and anti-histaminic agents. Three years after the beginning of the symptoms, she was submitted to a CT scan of paranasal sinuses and orbit, which was normal. At this time she started to present psychiatric symptoms, predominantly psychosis, characterized by hyperactivity, euphoria, hallucinations and delirium, when she was admitted to a psychiatric hospital. Simultaneously she started to develop anosmia and progressive visual loss in the left eye. There was no complaints of headache. A magnetic resonance imaging (MRI) was then performed and disclosed a gadolinium-enhanced linear lesion on the left basal frontal lobe and on the interhemispheric fissure

---

University of Campinas (UNICAMP) Campinas SP, Brazil: Resident<sup>1</sup> and Assistant Professor<sup>3</sup>, Department of Neurology; Assistant Professor<sup>2</sup>, Department of Pathology; Assistant Professor<sup>4</sup>, Department of Radiology.

Received 16 April 2002, received in final form 5 August 2002. Accepted 27 August 2002.

Dr. Fernando Cendes - Departamento de Neurologia, FCM - Cx Postal: 6111 - 13083-970 Campinas SP - Brasil. FAX: 55 19 3788 7483. E-mail: fcendes@unicamp.br

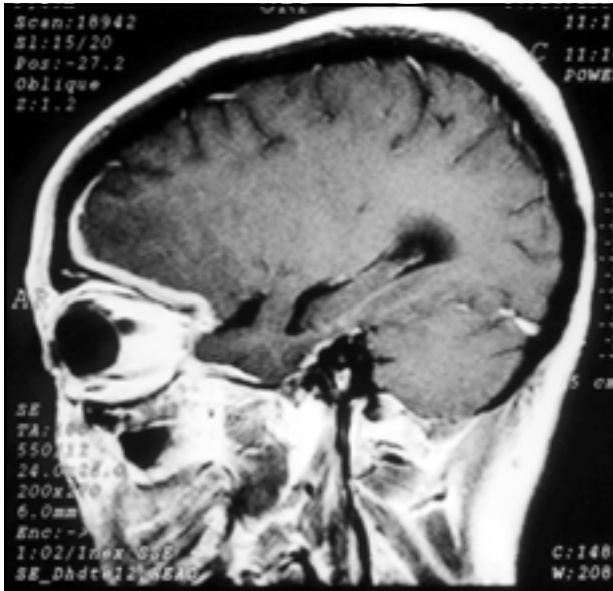


Fig 1. Sagittal gadolinium enhanced T1-WI showing a thick left fronto-basal meningeal enhancement.

consistent with meningeal thickening (Fig 1). Lumbar puncture revealed an opening pressure of 13 cmH<sub>2</sub>O and a clear cerebrospinal fluid (CSF). There were 6 cells/mm<sup>3</sup> (63% lymphocytes, 31% monocytes, 3% neutrophils, 3% plasmocytes). Total protein was 45 mg/dL and glucose was 59 mg/dL. Protein electrophoresis revealed an increase of

gamma globulins. Search for infectious agents by microscopy and culture was negative. Immunological tests for herpes simplex virus, varicella zoster virus, CMV, HTLV, Epstein-Barr virus, rubeola, syphilis, toxoplasmosis, cryptococcosis, cysticercosis, schistosomiasis, tuberculosis, blastomycosis, candidiasis, aspergillosis, were negative.

She was then started on oral corticosteroids because of the visual loss and showed good improvement with therapy. She was also taking anti-psychotic drugs with no improvement of psychic symptoms. She was then transferred to UNICAMP University Hospital. On admission she was very hyperactive presenting clinical features of psychosis and hypersexuality. Her neurological examination was unremarkable except for the mental state and bilateral optic nerve dysfunction. Her left optic disk was atrophic and there was papilledema on the right eye. Another MRI was performed and showed the same pattern of meningeal enhancement seen on the first one. Lumbar puncture revealed a further increase on the protein content (58 mg/dL) and decrease in cell count (2 cells/mm<sup>3</sup>). Systemic investigation was negative for infections, metabolic dysfunction, inflammatory diseases (including rheumatoid disease) or any other medical condition. She was tested for an extensive panel of autoantibodies (ANA, anti-dsDNA, anti-Smab, RF, anti-RO, anti-LA, anti-SCL70, anti-mitochondrial, p-;c-ANCA, anti-RNP, Anti-Jo-1) with no positive findings and the blood level of angiotensin converting enzyme (ACE) was normal.

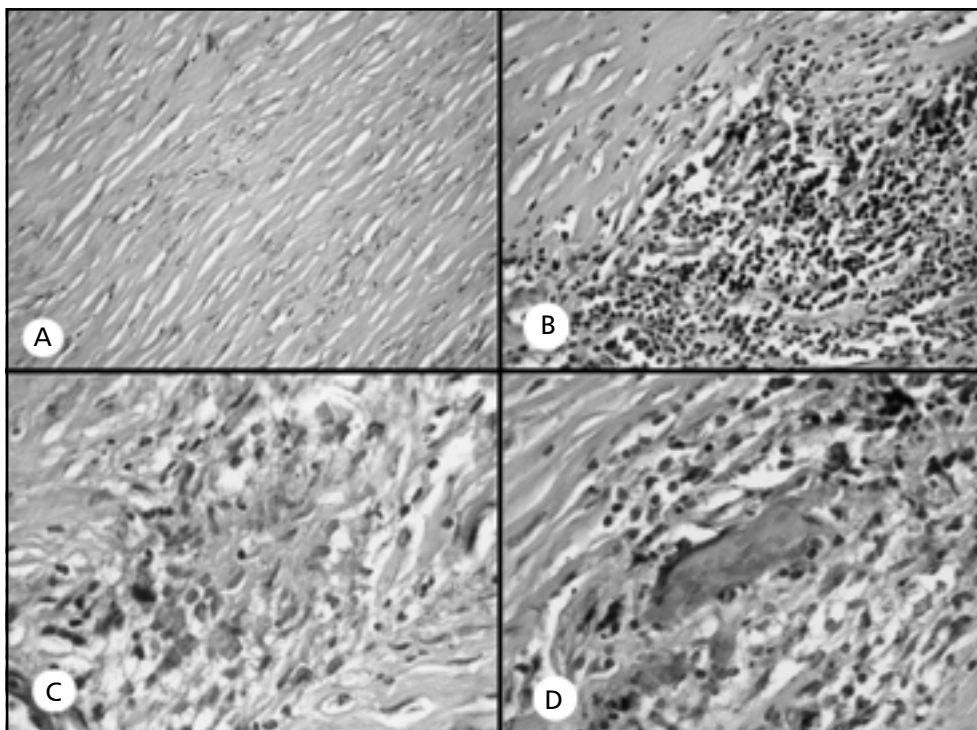


Fig 2. All figures are from a biopsy fragment of frontal basal dura-mater. a) Extensive fibrous thickening of the dura-mater. (Hematoxylin-Eosin (HE) x100); b) Focal nonspecific inflammatory infiltrate in the dura-mater, consisting largely of lymphocytes. (HE x 200); c) Incipient granuloma with few epithelioid cells. (HE x 400); d) Isolated giant cell amid round cell infiltrate. (HE x 400).

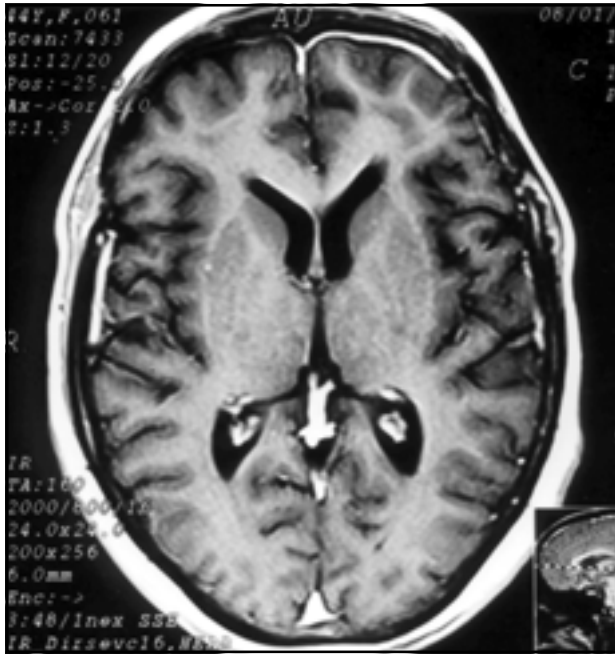


Fig 3. Axial gadolinium enhanced T1-WI showing meningeal enhancement of the left frontal dura-mater and of the anterior inter-hemispheric fissure.

A whole-body gallium-labeled scintigraphy showed accumulation of the radioisotope only in frontal basal and interhemispheric meninges. Kveim test was not performed because the patient was already taking corticosteroids, what could alter the cutaneous response.

She was then submitted to a meningeal biopsy, limited to the dura mater. Surgical appearance of subdural space and leptomeninges were normal. Histopathological examination revealed extensive collagenous fibrosis and a chronic non-specific inflammatory process (Figs 2a and 2b). Two small areas of early-stage non-caseous granuloma were observed (Fig 2c and 2d). Special stains for acid fast bacilli (Ziehl-Neelsen) and for fungi (Grocott) were negative. A new nasal mucous membrane biopsy revealed only chronic rhinitis. She was also investigated for occult neoplasm and nothing was found. A thorax CT scan was also normal. She was then put on azathioprin therapy with good improvement of psychic and visual symptoms.

She was released from the Hospital with a diagnosis of hypertrophic pachymeningitis, probably idiopathic but with a possibility of neurosarcoidosis. Three months later a new MRI was performed and showed persistence of the meningeal enhancement (Fig 3). She is on follow-up and has presented three episodes of visual acuity worsening with partial response to pulse therapy with corticosteroids.

## DISCUSSION

Hypertrophic thickening of the meninges can be caused by a variety of pathological processes. Involvement of the meninges can be diffuse or focal and both cranial and spinal meninges can be affected<sup>3</sup>.

Some diseases selectively involve the dura mater whereas others affect predominantly the leptomeninges. When limited to the dura mater it is called pachymeningitis. When only arachnoid or pia mater is involved, the term is leptomeningitis. This subdivision is important when investigating the patient for a specific cause<sup>4</sup>. The symptoms are related to the topography of the lesions and rarely are disease specific. Masson et al.<sup>1</sup> found that headache was invariably present but did not show any specific pattern, except when there was hydrocephalus. They also found ophthalmoplegia to be common with frequent dysfunction of optic nerve. Other symptoms include hypoacusia, tinnitus, dizziness, trigeminal neuralgia, and dysphagia. Eventually the clinical picture will be that of Tolosa-Hunt or Garcin syndrome<sup>5</sup>. Behavioral or cognitive disorders are unusual, but can be present especially if the frontal lobe is affected. The CSF findings are dependent on the etiology. When infection is not present, CSF frequently shows non-specific pleocytosis, rarely over 100 cells/mm<sup>3</sup>, predominantly lymphocytic. There can be an increase in protein content with raise of immunoglobulins and elevation of IgG index.

MRI is the most useful radiological method in evaluating a patient with suspected thickening of meninges. The MRI aspect is a hypointense meningeal lesion on T1-weighted slices that enhances with paramagnetic contrast injection. In T2-weighted imaging hypo- and hyperintense images can be seen dependent on the degree of fibrosis and active inflammatory process. Peripheral enhancement and T2 hyperintensity are common in the early stages of the disease and correspond to inflammatory activity while hypointensity is attributed to fibrosis. The use of gadolinium is important for evaluation of the pattern of meningeal enhancement, that may differentiate between pachy- and leptomeningitis<sup>6,7</sup>. When the enhancement following contrast injection accompanies the sulci and gyri of the brain the diagnosis is leptomeningitis because the pia mater is closely attached to the brain surface. Pachymeningitis is observed in the interhemispheric fissure, tentorium and basal dura<sup>4</sup>. MRI also demonstrates areas suitable for biopsy and secondary lesions that may accompany the disease<sup>6,8</sup>. Histopathological findings are that of an inflammatory process with lymphomononuclear cell infiltration and a thickened dura mater characterized by a dense hypocellular fibrous tissue<sup>1,8</sup>. Specific patterns such as necrotizing vasculitis and noncaseous epithelioid granulomas can be found depending on the etiology.

Differential diagnoses are extensive. Syphilis and tuberculosis have been described as the main causes of classic secondary pachymeningitis<sup>5</sup>. Although rare in developed countries, they can still be considered the cause of many neurological cases in developing countries. They are also common causes of opportunistic infections in immunocompromised patients. Meningovascular syphilis can cause pachymeningitis, but often associated with other symptoms and signs, particularly of ischemia and infarction. Tuberculosis is an important cause of chronic meningitis, predominantly affecting basal cisterns and obstructing the CSF flow, therefore causing some degree of hydrocephalus. Most cases of neurotuberculosis are consequence of hematogeneous dissemination of tubercle bacilli from another organ and occasionally from a tuberculous lesion in the vertebral column<sup>9</sup>. Other pathogens such as *Candida*<sup>10</sup>, *Aspergillus*<sup>11</sup>, *Pseudomonas*<sup>12</sup> or any other that cause infection of the extra or subdural space, paranasal sinuses or mastoid, can induce thickening of the dura mater.

Neoplasms such as lymphoma, adenocarcinoma, melanoma, meningioma, especially "meningioma en plaque", should be considered whenever there is thickening of the meninges. Meningeal carcinomatosis can cause pachymeningitis but most cases have a progressive course, the CSF may show neoplastic cells and patients usually present symptoms of the primary neoplasm<sup>4,5</sup>. Noninfectious inflammatory diseases can cause meningeal thickening and must be considered in the differential diagnosis of pachymeningitis. Wegener's granulomatosis is a necrotizing granulomatous vasculitis that predominantly affects the upper and lower respiratory tract and the kidneys. It has a higher incidence in the fourth and fifth decade of life, but it can occur at any age. Neurological involvement occurs in 22% to 54% of cases, predominantly manifested as mononeuritis multiplex followed by distal symmetric sensorimotor neuropathy<sup>13</sup>. Brain and meninges are affected in approximately 10% of patients and are manifested by facial weakness, diplopia, hearing and visual loss and sometimes diabetes insipidus due to involvement of hypothalamus-hypophysis. The presence of cANCA, an antineutrophil cytoplasmic antibody, is highly suggestive of Wegener's granulomatosis, but its absence does not exclude this diagnosis<sup>14</sup>. Biopsy of affected tissues is important when the diagnosis is not clarified by non-invasive investigation. Other systemic vasculitis or connective-tissue disorders, such as rheumatoid disease, can cause pachymeningitis, although less frequently<sup>15-18</sup>.

Hypertrophic cranial pachymeningitis is a rare form of granulomatous pachymeningitis that is mostly a diagnosis of exclusion. It presents in a nonspecific pattern mimicking any disease that cause pachymeningitis. It sometimes is accompanied by fibrosclerosis of other organs, including orbital pseudotumor, mediastinal and retroperitoneal fibrosis, Riedel's thyroiditis, sclerosing cholangitis, Dupuytren's contracture, Peyronie's disease, testicular and subcutaneous tissue fibrosis<sup>8</sup>. Tolosa-Hunt syndrome is a 'painful ophthalmoplegia' caused by a nonspecific granulomatous inflammation of the cavernous sinus. Pachymeningitis in this condition is caused by inflammation that extends to the dura that surrounds the sinus. Tolosa-Hunt syndrome may be a focal manifestation of hypertrophic pachymeningitis since they share common pathological features. Anatomical aspects of the cavernous sinus make it more frequently affected than other dural sinuses.<sup>19</sup> Spontaneous intracranial hypotension (SIH) is a rare syndrome of low intracranial pressure and postural headache with CSF opening pressure of 60 mm H<sub>2</sub>O or lower. Other conditions that predispose to low intracranial pressure such as lumbar puncture, back trauma, neurosurgical procedure or medical illness must be ruled out first<sup>20</sup>. MRI in SIH shows diffuse or focal thickening and gadolinium enhancement of the pachymeninges. Histopathological features are lymphomononuclear infiltration and fibrosis of the dura and cannot be differentiated from other idiopathic causes of pachymeningitis. The meningeal lesion in SIH may be caused by disruption of the architectural relation between dural and arachnoidal border cells, which regulates the homeostatic fluid environment<sup>4</sup>.

One very interesting disease that cause meningeal fibrosis is sarcoidosis. We shall discuss it as a possible diagnosis of our patient. Also known as Besnier-Boeck-Schaumann disease, sarcoidosis is a systemic granulomatous disorder of unknown origin, most commonly recognized in young adults between the ages of 20 and 40 years, with predominance in women. It can occur in any tissue or organ of the body but predominantly affects the lungs, the eyes and the lymph nodes<sup>21</sup>. Involvement of the nervous system is infrequent, varying from 2% to 5% of patients with systemic sarcoidosis. This number doubles when considering post-mortem findings, suggesting that at least 10% of patients with systemic sarcoidosis present asymptomatic neurosarcoidosis. The incidence of sarcoidosis strictly confined to the central nervous system is very low, less than 0.2 per 100.000. Neurological manifestations can be the initial presentation in 30% to 50% of patients that

will later be diagnosed as having neurosarcoidosis<sup>22,23</sup>. The clinical presentation is varied and depends on the area affected. The most common intracranial symptoms are cranial nerve deficits, headache and seizures. The facial and optic nerves are the most affected<sup>23,24</sup>. Optic neuritis and papillitis were found in 38% of patients in a recent series<sup>22</sup>. Meningeal involvement in neurosarcoidosis is predominantly leptomeningeal and MRI shows homogeneous or diffuse enhancement of the affected meninges. The basal cisterns and hypothalamic areas are commonly affected<sup>4,23,25</sup>. The origin of the disease remains unknown but there are speculations on the participation of genetic and environmental factors. These theories are supported by the fact that sarcoidosis has been found to be more frequent in some families as well as in some professional groups such as nurses and firefighters<sup>26,27</sup>. Mycobacteria may be involved in the pathogenesis of sarcoid granulomas. This is based on the fact that mycobacterial DNA has been found in lung specimens from patients with pulmonary involvement. A case of neurosarcoidosis that improved when receiving antituberculous drugs was reported. Clinical improvement was correlated with decreasing levels of *Mycobacterium tuberculosis* DNA in the CSF<sup>28</sup>. It has recently been described that activated CD4 + lymphocytes and mononuclear phagocytes play important role in the formation the characteristic noncaseating granuloma of sarcoidosis. What causes the activation of the immune system to form the granulomas is still unknown. Some authors have found specificity to one single antigen while others attribute the process to various sarcoid antigens<sup>23,29</sup>.

This patient is unusual in many aspects. She did not complain of headache, which is the most common symptom of any type of pachymeningitis. Her clinical presentation is uncommon and was characterized by a pseudo Foster-Kennedy syndrome<sup>30</sup>. This can be explained by frontal lobe dysfunction and compressive optic neuropathy caused by the pseudotumoral aspect of the meningeal thickening, which predominantly affected the basal frontal meninge. The relationship among chronic rhinitis, nasal septum destruction and pachymeningitis in our patient is unclear. There was neither sign of infiltrative disease nor of contiguous infection. Her CSF pressure was normal and no signs of fistulae were found, what excluded intracranial hypotension. Infections, carcinomatosis and vasculitis were appropriately excluded by specific tests and pathological findings.

Despite the facts that pachymeningitis is not a common type of meningeal involvement in sarcoidosis and that the ACE level was normal, the histopathological

aspect resembles noncaseous granulomatous in a few areas. This led us to put the diagnosis of isolated neurosarcoidosis in evidence for this case. However we cannot make it definitive since it shares many aspects with idiopathic hypertrophic pachymeningitis.

## REFERENCES

1. Masson C, Hénin D, Hauw JJ, Rey A, Raverdy P, Masson M. Cranial pachymeningitis of unknown origin: a study of seven cases. *Neurology* 1993;43:1329-1334.
2. Hamilton SR, Smith CH, Lessell S. Idiopathic hypertrophic cranial pachymeningitis. *J Clin Neuro Ophthalmol* 1993;13:127-134.
3. Mikawa Y, Watanabe R, Hino Y, Hirano K. Hypertrophic spinal pachymeningitis. *Spine* 1994;19:620-625.
4. Case Records of the Massachusetts General Hospital. Case 2-1998. *N Engl J Med* 1998;338:180-188.
5. Masson C, Boukriche Y, Colombani J.M. Les pachyméningites crâniennes hypertrophiques inflammatoires. *Presse Med* 2001;30:411-416.
6. Bang OY, Kim DI, Yoon SR, Choi IS. Idiopathic hypertrophic pachymeningeal lesions: correlation between clinical patterns and neuroimaging characteristics. *Eur Neurol* 1998;39:49-56.
7. Friedman DP, Flanders AE. Enhanced MR imaging of hypertrophic pachymeningitis. *AJR* 1997;169:1425-1428.
8. Lam BL, Barret DA, Glaser JS, Schatz NJ, Brown HH. Visual loss from idiopathic intracranial pachymeningitis. *Neurology* 1994;44:694-98.
9. Adams JH, Graham DI. An Introduction to Neuropathology. 2<sup>nd</sup> edition. Edinburgh: Churchill Livingstone, 1994:97-98.
10. Gorrel JM, Palutke WA, Chason H. Candida pachymeningitis with multiple cranial nerves palsies. *Arch Neurol* 1979;36:719-720.
11. Murai H, Kira J, Kobayashi T, Goto I, Inoue H, Hasuo K. Hypertrophic cranial pachymeningites due to *Aspergillus flavus*. *Clin Neurol Neurosurg* 1992;94:247-250.
12. Girkin CA, Perry GD, Miller NR, Reich SG. Pachymeningitis with multiple cranial neuropathies and unilateral optic neuropathy secondary to *Pseudomonas aeruginosa*: case report and review of the literature. *J Neuro ophthalmol* 1998;18:196-200.
13. Nishino H, Rubino FA, DeRemee RA, Swanson JW, Parisi JE. Neurological involvement in Wegener's granulomatosis: an analysis of 324 consecutive patients at the Mayo Clinic. *Ann Neurol* 1993;33:4-9.
14. Siva A. Vasculitis of the nervous system. *J Neurol* 2001;248:451-468.
15. Yuh WTC, Drew JM, Rizzo M, Ryals TJ, Sata Y, Bell WE. Evaluation of pachymeningitis by contrast-enhanced MR imaging in a patient with rheumatoid disease. *Am J Neuroradiol* 1990;11:1247-1248.
16. Fujimoto M, Kira J, Murai H, Yoshimura T, Takizawa T, Goto I. Hypertrophic cranial pachymeningitis associated with mixed connective tissue disease: a comparison with idiopathic and infectious pachymeningitis. *Intern Med* 1993;32:510-512.
17. Ly JY, Lai PH, Lam HC et al. Hypertrophic cranial pachymeningitis and lymphocytic hypophysitis in Sjögren syndrome. *Neurology* 1999;52:420-423.
18. Bathon JM, Moreland LW, DiBartolomeo AG. Inflammatory central nervous system involvement in rheumatoid arthritis. *Semin Arthritis Rheum* 1989;18:258-266.
19. Miwa H, Koshimura I, Mizuno Y. Recurrent cranial neuropathy as a clinical presentation of idiopathic inflammation of the dura mater: a possible relationship to Tolosa-Hunt syndrome and cranial pachymeningitis. *J Neurol Sci* 1998;154:101-105.
20. Rando TA, Fishman RA. Spontaneous intracranial hypotension. Report of two cases and review of the literature. *Neurology* 1992;42:481-487.
21. Newman LS, Rose CS, Maier LA. Sarcoidosis. *N Engl J Med* 1997;336:1224-1234.
22. Zajicek JP, Scolding NJ, Foster O et al. Central nervous system sarcoidosis - diagnosis and management. *Q J Med* 1999;92:103-117.
23. Nowak DA, Widenka, DC. Neurosarcoidosis: a review of its intracranial manifestation. *J Neurol* 2001;248:363-372.
24. Delaney P. Neurologic manifestations in sarcoidosis: review of the literature, with a report of 23 cases. *Ann Intern Med* 1977;87:336-345.
25. Khaw KT, Manji H, Britton J, Schon F. Neurosarcoidosis - demonstration of meningeal disease by gadolinium enhanced magnetic resonance imaging. *J Neurol Neurosurg Psychiatry* 1991;54:499-502.
26. Hills SE, Parkes SA, Baker SB. Epidemiology of sarcoidosis in the Isle of Man: evidence for space time clustering. *Thorax* 1987;42:427-430.
27. Kern DG, Neil MA, Wrenn DS, Varone JC. Investigation of an unique time-space cluster of sarcoidosis in firefighters. *Am Rev Respir Dis* 1993;148:974-980.
28. Schick U, May A, Schwarz M. Detection of mycobacterial DNA in a patient with neurosarcoidosis. *Acta Neurol Scand* 1995;91:280-282.
29. Vourlekis J, Sawyer R, Newman L. Sarcoidosis: developments in etiology, immunology and therapeutics. *Adv Intern Med* 2000;45:209-257.
30. Sanvito, WL. *Síndromes neurológicas*. 2.Ed. São Paulo: Atheneu, 1997:180.