

# POSTERIOR FOSSA GANGLIOCYTOMA WITH FACIAL NERVE INVASION

## Case report

*Andrei Koerbel<sup>1</sup>, Daniel Monte-Serrat Prevedello<sup>2</sup>, Cláudio Esteves Tatsu<sup>2</sup>, Luciano Nassar Pellegrino<sup>3</sup>, Ricardo Alexandre Hanel<sup>1</sup>, Luiz Fernando Bleggi-Torres<sup>4</sup>, João Cândido Araújo<sup>5</sup>*

**ABSTRACT** - A 5 year-old boy with a cerebellar gangliocytoma with a peripheral right facial paresis and ataxia is presented. His MRI showed a heterogenous, diffuse lesion, isointense on T1 and hyperintense on T2-weighted sequences, involving the right cerebellar hemisphere with direct extension into the right facial nerve. The present case is the first description of a gangliocytoma with direct facial nerve invasion, as demonstrated for the facial nerve paresis and supported by MRI and surgical inspection.

**KEYWORDS:** gangliocytoma, facial paresis, facial nerve, CNS tumor.

### **Gangliocitoma de fossa posterior com invasão de nervo facial: relato de caso**

**RESUMO** - Um menino de 5 anos de idade com gangliocitoma cerebelar manifestando paralisia facial periférica e ataxia é apresentado. O estudo de ressonância magnética (RM) mostrou lesão difusa e heterogênea isointensa em T1 e hiperintensa em seqüências ponderadas em T2, envolvendo o hemisfério cerebelar direito com extensão direta ao nervo facial direito. O presente caso é a primeira descrição de gangliocitoma com invasão direta do nervo facial, tal como demonstrado por paralisia facial periférica a direita e sustentado por RM e inspeção cirúrgica.

**PALAVRAS-CHAVE:** gangliocitoma, paralisia facial, nervo facial, tumor de SNC.

A case of conventional gangliocytoma involving the cerebellum, brainstem and superior cervical spinal cord with right facial nerve invasion is presented. Gangliocytomas are rare, benign, well differentiated, slowly growing neuroepithelial tumors composed of neoplastic, mature ganglion cells<sup>1</sup>. Cranial nerve invasion by the lesion is extremely rare, with only one case of trigeminal nerve involvement previously reported in the literature<sup>2</sup>. To our knowledge the present case is the first one showing facial nerve invasion.

### **CASE**

A 5 year-old boy was referred to our institution for evaluation of peripheral right facial paresis and ataxia. He started with slowly progressive right facial weakness one year before admission. Three months later, his mother noticed gait disturbance and difficulty with his right arm. Two months before admission, he started with vomiting

and headache. His neurological examination revealed peripheral right facial paresis, ataxia, and right sided dysmetria. A CT scan showed obstructive hydrocephalus caused by a diffuse right sided cerebellar lesion, hypodense in nature, with heterogenous contrast enhancement. He was submitted to a ventriculoperitoneal (VP) shunt, with relief of symptoms due to intracranial hypertension. A cranial MRI performed three days after VP shunt showed a heterogenous, diffuse lesion, isointense on T1-weighted images, hyperintense on T2-weighted sequences, at the right cerebellar hemisphere involving the superior part of cerebellar vermis, right middle cerebellar peduncle, pons and medulla oblongata (Fig 1). The lesion extended inferiorly to upper cervical spinal cord. A direct extension into the right vestibulo-cochlear-facial complex was also detected from brainstem through the internal acoustic meatus (Fig 2).

He was submitted to a right suboccipital craniectomy, with partial resection of lesion, limited to cerebellar tissue. Direct inspection of cranial nerve complex showed diffuse

Divisions of Neurosurgery and Pathology of Hospital Nossa Senhora das Graças, Curitiba PR, Brazil: <sup>1</sup>Neurosurgeon; <sup>2</sup>Resident in Neurosurgery; <sup>3</sup>Medical Student; <sup>4</sup>Pathologist; <sup>5</sup>Neurosurgeon Coordinator of the Residency Program in Neurosurgery.

Received 22 August 2002, received in final form 24 October 20002. Accepted 7 November 2002

Dr. Andrei Koerbel - Rua Alcides Munhoz 433 - 80810-040 Curitiba PR - Brasil. FAX: 055 41-3350191. E-mail: akoerbel@hotmail.com

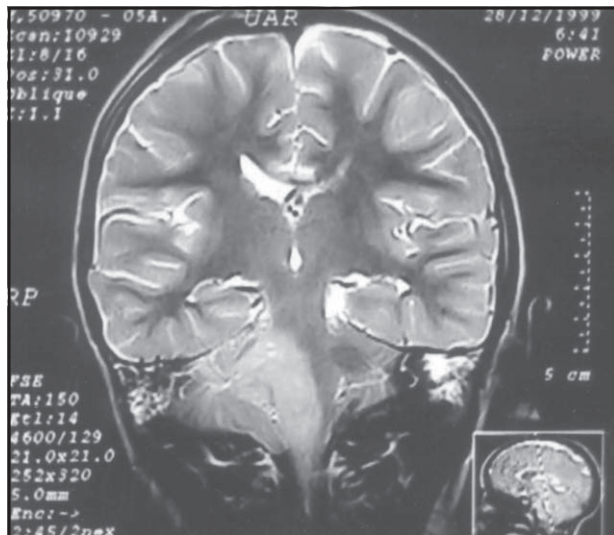


Fig 1. T2-weighted MRI image shows a hyperintense, heterogenous, diffuse lesion, at the right cerebellar hemisphere involving the superior part of cerebellar vermis, right middle cerebellar peduncle, pons and medulla oblongata.

thickening of the facial nerve, from its central origin towards the periphery, entering the internal auditory canal. Histopathological examination was compatible with conventional gangliocytoma, showing diffuse proliferation of mature-looking nerve cells in a disorganized pattern. No necrosis and no mitosis were seen (Fig 3). One week after surgery, some improvement in the degree of ataxia and dysmetria was noted but facial paresis remained unchanged. At one-year follow-up, he showed a stable neurologic condition. MRI obtained at that time demonstrated no further progression of the lesion.

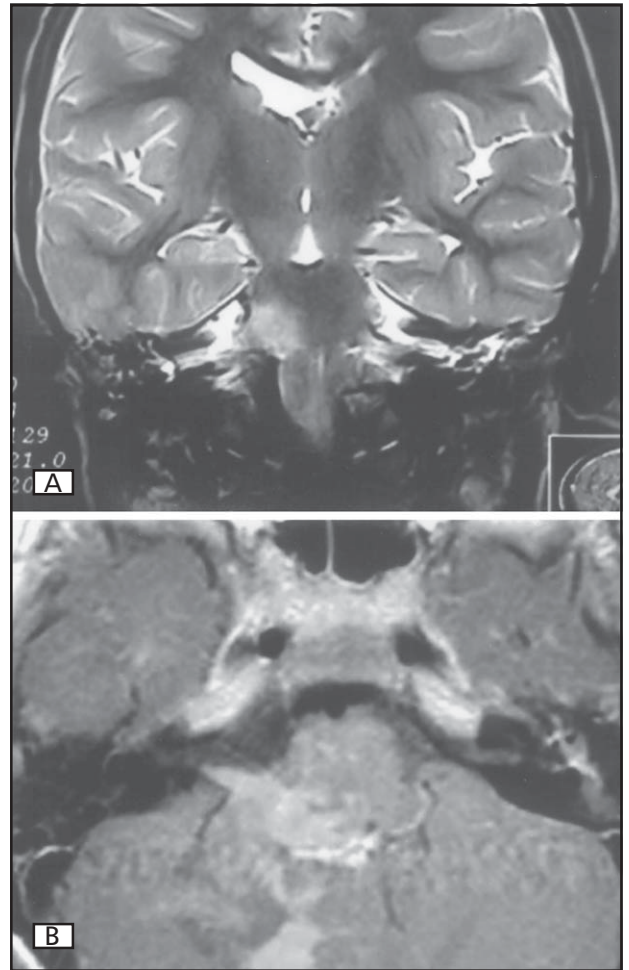


Fig 2. T2-weighted MRI image shows direct extension into the right facial nerve, through the internal acoustic meatus; A. on a MRI coronal scan; B. on a MRI axial scan.

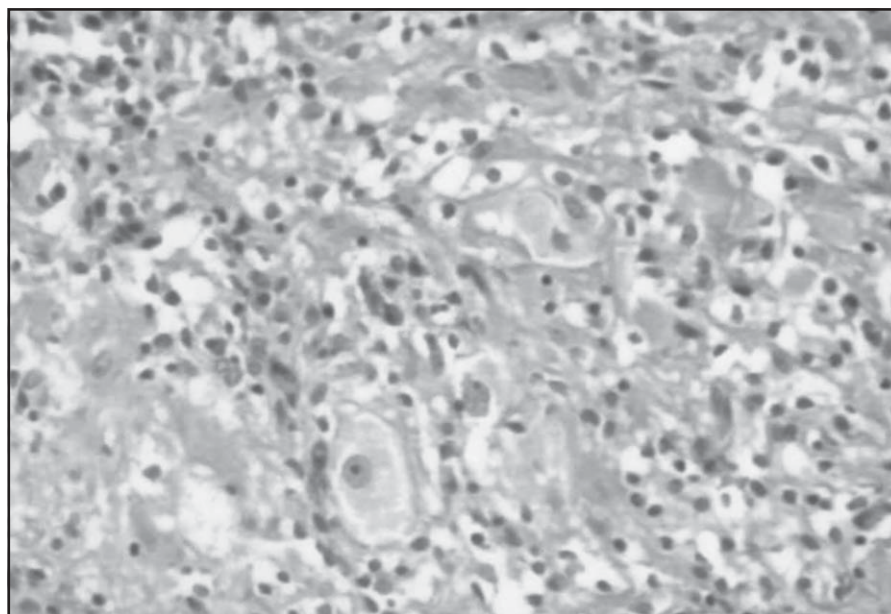


Fig 3. Histopathological examination compatible with conventional gangliocytoma, showing diffuse proliferation of mature-looking nerve cells in a disorganized pattern. No necrosis and no mitoses were seen (H&E x 400).

## DISCUSSION

Neuronal and mixed neuronal-gliial tumors are extremely rare, accounting for 0.1% to 0.5% of all brain tumors<sup>3</sup>. They are mostly seen in children and young people<sup>3</sup>, but the age of incidence ranges from 2 months to 80 years<sup>1</sup>. They include gangliocytoma, dysplastic gangliocytoma of the cerebellum (Lhermitte-Duclos Disease), ganglioglioma, dysembryoplastic neuroepithelial tumor, central neurocytoma, cerebellar liponeurocytoma and paraganglioma. Some authors consider ganglioneuroma as a synonym for gangliocytoma. Such terminology is not accepted by the World Health Organization classification of tumors and its use should be avoided. De Arriba-Vilamor et al. state that their pathogenesis is not fully understood, considering the possibility of being dysplasias or malformations rather than true neoplasias<sup>4</sup>.

The most frequent site for gangliocytomas is the temporal lobe, but they can arise anywhere in the central nervous system, such as in the cerebellum, brainstem, floor of third ventricle and spinal cord.<sup>5</sup> Image findings are not specific. At MRI, the tumor would emit a low-intensity signal on T1-weighted sequences and a high-intensity signal on T2. Contrast enhancement varies in intensity from none to mar-

ked, and it may be solid, heterogeneous, rim or nodular. Differential diagnosis on imaging includes astrocytomas and oligodendrogliomas as well other tumors of neuronal origin<sup>6</sup>. Gangliocytomas are usually radioresistant, therefore surgical removal is the only option with a favorable prognosis, even in those cases of partial resection.

There is only one description of cranial nerve invasion by gangliocytoma in the literature, where Abe et al report a case of trigeminal nerve involvement<sup>2</sup>. To our knowledge the present case is the first description of direct facial nerve invasion by gangliocytoma, as demonstrated clinically and supported by MRI and surgical inspection.

## REFERENCES

1. Nelson JS, Bruner JM, Wiestler OD, Vandenberg SR. Ganglioglioma and gangliocytoma. In Kleihues P, Cavenee WK (eds). Pathology and genetics of tumors of the nervous system. Lyon: IARC Press, 2000:96-98.
2. Abe T, Asano T, Manabe T, Matsura H, Furuta T, Taguchi K. Trigeminal ganglioneuroma. *Brain Tumor Pathol* 1999;16:49-53.
3. Ebina K, Suzuki S, Takahashi T, Iwabuchi T, Takei Y. Gangliocytoma of the pineal body: a case report and review of the literature. *Acta Neurochir (Wien)* 1985;74:134-140.
4. Arriba-Vilamor C, Martinez-Mata A, Espinosa-Mogro H, Rubio-Viguera V. Ganglion cell tumors. *Rev Neurol (Barc)* 1998;27:1008-1011.
5. Atlas SW. Magnetic resonance imaging of the brain and spine. New York: Raven Press, 1991:266-273.
6. Peretti-Viton P, Perez-Castillo AM, Raybaud C, et al. Magnetic resonance imaging in gangliogliomas and gangliocytomas of the nervous system. *J Neuroradiol* 1991;8:189-191.