

PARA-MUSCULAR AND TRANS-MUSCULAR APPROACHES TO THE LUMBAR INTER-VERTEBRAL FORAMEN

An anatomical comparison

Arthur Werner Poetscher¹, Guilherme Carvalho Ribas², Alexandre Yasuda², Koshiro Nishikuni²

ABSTRACT - Foraminal and extra-foraminal disc herniations comprise up to 11.7% of all lumbar disc herniations. Facetectomy, which had been the classic approach, is now recognized as cause of pain and instability after surgery. Otherwise, posterior lateral approaches through a trans-muscular or a para-muscular technique offer no significant damage to key structures for spinal stability. The surgical anatomy of these approaches has already been described, but they were not compared. In order to quantify the angle of vision towards the intervertebral foramen offered by each technique, 12 fresh cadavers were dissected and studied regarding these approaches. The angle presented by trans-muscular approach was wider in all studied lumbar levels. Surgery through the trans-muscular approach is performed with a better working angle, requiring a smaller resection of surrounding tissues. Therefore, minor surgical trauma can be expected. Our measurements support previously published data that point the trans-muscular approach as the best surgical option.

KEY WORDS: intervertebral disc displacement, low back pain, lumbar vertebrae, sciatica, comparative study.

Acessos paramuscular e transmuscular ao forame intervertebral lombar: comparação anatômica

RESUMO - As hérnias de disco lombares apresentam-se como foraminais ou extra-foraminais em até 11,7% dos casos. Seu tratamento cirúrgico através de facetectomias pode causar dor e instabilidade, o que não ocorre com a utilização de acessos cirúrgicos posteriores laterais ao canal central, quer seja por via transmuscular ou paramuscular. Nosso objetivo foi comparar o ângulo de trabalho relativo ao forame intervertebral permitido por cada via e avaliar possíveis implicações cirúrgicas. Dissecções e medidas realizadas em doze cadáveres frescos demonstraram que este ângulo é maior na via transmuscular em todos os níveis lombares estudados. Dado que um ângulo mais favorável permite uma ressecção menor das estruturas envolvidas para que se estabeleça o campo de trabalho, a cirurgia por meio da via transmuscular permitirá, então, um trauma cirúrgico menor. Nossos resultados corroboram publicações prévias que apontam a via transmuscular como a melhor opção cirúrgica.

PALAVRAS-CHAVE: deslocamento do disco intervertebral, dor lombar, vértebras lombares, ciática, estudo comparativo.

Foraminal and extra-foraminal lumbar disc herniations have historically been a challenge in spine surgery due to their particular anatomical relationship with the nerve roots and the facet joints, comprising up to 11.7% of all lumbar disc herniations^{1,2}. Facetectomy used to be the standard technique in treating such herniations for a long time^{1,3,4,5}. Despite the familiar surgical anatomy and the success in relieving root compression in most of the cases,

this approach has been reviewed and criticized. The incidence of back pain after surgery, related to instability, is significant, as pointed out by several authors⁶⁻¹⁰. Hafer also demonstrated that an increase in axial load on the intervertebral disc may occur in this situation, therefore accelerating degenerative process¹¹. Use of posterior lateral approaches, either para-muscular or trans-muscular, both sparing the articular facets, has thus emerged as a better

Faculdade de Medicina, Universidade de São Paulo (FMUSP), São Paulo, SP, Brazil: ¹Department of Neurology, FMUSP and Division of Neurosurgery, Hospital das Clínicas da FMUSP, São Paulo São Paulo SP Brazil; ²Department of Clinical Anatomy, FMUSP.

Received 10 May 2004, received in final form 6 August 2004. Accepted 28 September 2004.

Dr. Arthur W. Poetscher - Avenida Albert Einstein 627/1308 - 05651-901 São Paulo SP - Brasil. E-mail: awpoetscher@terra.com.br

option. The posterior lateral approach was initially developed for lumbar arthrodesis, as described by Watkins¹² and Wiltse¹³. Nevertheless, only in 1985, Recoules-Arche reported his experience with the trans-muscular approach for the surgical treatment of foraminal and extra-foraminal disc herniations¹⁴. Two years later, Reulen⁸ and Fankhauser¹⁵ published their own experience with para-muscular and trans-muscular techniques.

The target of both approaches is the lateral aspect of the inter-vertebral foramen, in between the transverse processes. When using the trans-muscular technique, this space is reached by splitting the para-vertebral muscles, whereas, when performing a para-muscular approach, these muscles are detached from the spinous processes and then retracted beyond the facet articulations. Although some authors have related their experience with both approaches, these techniques were not specifically compared regarding either the surgical anatomy or patients outcome^{2,4}. Despite the fact that Reulen^{8,9} and Schlesinger¹⁰ have suggested that the trans-muscular technique may provide a wider angle towards the intervertebral foramen, no objective measurements have been published yet. A larger angle may permit a better visualization within the intervertebral foramen, therefore saving bone and ligament resection and diminishing the surgical trauma.

Since the difference between these angles may be important to establish the better surgical option, we report the measurements obtained after dissection of 12 fresh cadavers.

METHOD

The "angle of vision" was defined as the one between the sagittal plane of lateral aspect of the intervertebral

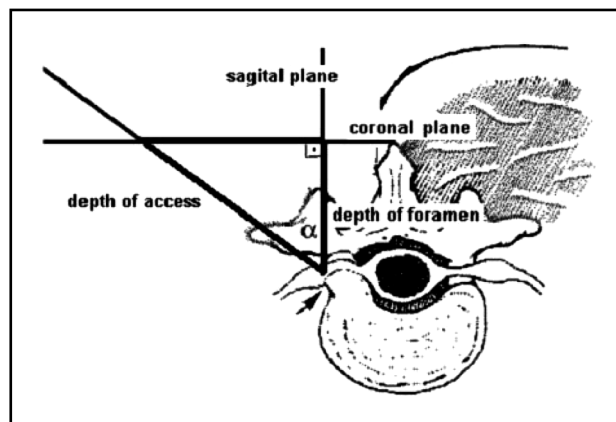


Fig 1. Coronal and sagittal planes, depth of access and depth of foramen.

Table 1. Anthropometric data of dissected cadavers.

Initials	Gender	Age (years)	Weight (kg)	Height (cm)
JG	M	70	70	180
IL	M	66	48	170
OG	M	48	80	190
GFC	M	85	60	170
BFSN	M	67	70	180
RFS	M	48	79	165
JMFS	M	46	68	180
BJG	F	84	56	148
LJV	F	66	59	149
OVR	M	64	66	166
MJS	F	48	61	154
JAS	M	80	73	185

foramen and the line that connects the lateral border of the incision, in the same axial plane, with the intervertebral foramen.

Since this angle is deeply situated, a direct measure is not feasible. In order to overcome this constraint, we defined a right triangle, as shown in Figure 1. One of the cathetus, called "foramen depth" here of, is the distance from the intervertebral foramen to the coronal plane that crosses the apex of the spinous process. The second cathetus is the distance from the apex of the spinous process, in the same sagittal plane, to the point where it intersects the line that begins in the intervertebral foramen and crosses the most lateral point of the incision, in the same axial plane. This line is the hypotenuse, which represents the "access depth". Given that $\cos \alpha = c/h$, where c = foramen depth, and h = access depth, the angle of vision's cosine equals the foramen depth divided by the access depth. This trigonometric relationship allowed us to calculate the angle.

Twelve fresh adult cadavers were dissected and measured. They were randomly selected, having as exclusion criteria either history of spinal disease or findings that suggested so during the dissection. On average, the age was 64 years (range: 46 - 85 years), the height, 169.75 cm. (range: 148 - 190 cm.), and the weight, 56.8 kg (range: 48 - 80 kg). The detailed data are shown in Table 1.

All cadavers were dissected in ventral decubitus, with the arms along the body, in order to maintain the lumbar lordosis.

Skin was incised at three centimeters from the spinous processes, para-median, in a randomly selected side. Once the incision length could be a variable (it changes the muscular retraction), all specimens were incised from L1 to L5. The space between the subcutaneous tissue and the toraco-lumbar aponeurosis was dissected towards the midline. Para-vertebral muscles were then completely detached and retracted as lateral as possible, allowing us to visualize the transverse processes. A re-

tractor was placed and the inter-transversary muscles and ligaments were removed, in order to expose the inter-vertebral foramen. At this moment, we measured the foramen depth and the access depth for the para-muscular approach, as above defined, from L1-L2 to L4-L5.

In sequence, the retractor was removed, allowing the para-vertebral muscles to return to their anatomic position. The para-vertebral muscles were then split through the space between the m. multifidus and the m. iliocostalis. Once the intervertebral foramen was visualized again, the retractors were positioned. At this point, the access depth for the trans-muscular approach was measured, as defined previously, from L1-L2 to L4-L5.

Given the fact that L5-S1 level presents an unique anatomy and is better accessed by a specific approach¹⁶, it was not addressed in this study.

The angles of vision were then calculated and all the values were analyzed for statistical significance. For each approach, at each level, the average, median, standard deviation, and confidence interval were obtained. The values for each approach were then compared using t test study.

This research was approved by the Ethics Committee - Hospital das Clínicas da Faculdade de Medicina da Universidade de São Paulo (CAPPesq, n.21/2000)

RESULTS

At all levels the access depth was longer with the trans-muscular technique (L1-L2: 8.0 cm., L2-L3: 8.3 cm., L3-L4: 8.6 cm, L4-L5: 8.6 cm) than with the para-muscular technique (L1-L2: 6.3 cm., L2-L3: 6.5 cm., L3-L4: 6.9 cm., L4-L5: 7.5 cm.).

The foramen depth increased in the lower lumbar spine (L1-L2: 5.3 cm., L2-L3: 5.8 cm., L3-L4: 6.2 cm., L4-L5: 6.9 cm.).

Detailed values for each level are exposed in the Table 2.

At all studied levels the angle of vision was larger in the trans-muscular approach (trans-muscular - L1-L2: 48°, L2-L3: 45°, L3-L4: 43°, L4-L5: 36°,

para-muscular: L1-L2: 32°, L2-L3: 26°, L3-L4: 25°, L4-L5: 23°), reaching a significant difference (t test, $p < 0.003$).

In both approaches, the angle of vision was smaller at the lower lumbar spine (23° and 36° at L4-L5, 32° and 48° at L1-L2, for para-muscular and trans-muscular, respectively). This difference was also significant (para-muscular: $p < 0.03$, trans-muscular: $p < 0.001$).

DISCUSSION

The essential divergence between the para-muscular and the trans-muscular approaches lays on their relationship with the para-vertebral muscles. When using the para-muscular technique, the whole bundle of muscles is kept laterally to the surgical path, by use of retraction. On the other hand, the trans-muscular technique establishes a path through the natural space in between the m. multifidus and m. iliocostalis. This relationship explains the difference between the angles of vision.

Schlesinger et al. suggested that this angle is larger in the trans-muscular approach, but they did not have the chance to measure it¹⁰. Reulen, describing their technique for the para-muscular access, observed that, in several patients, they had to tilt the surgery table laterally in about 10° to achieve a better visualization inside the inter-vertebral foramen⁸. One can obtain it naturally using the trans-muscular approach.

A larger angle will permit a deeper visualization into the inter-vertebral foramen. Thus, a smaller amount of bone and ligaments from its dorsal wall will have to be removed in order to expose adequately the nerve root and the disc fragments. Therefore, less surgical trauma should be expected.

In the lower lumbar spine, the angles for both approaches are smaller, due to the deeper location of the inter-vertebral foramen and to the smaller muscle retraction possible on this level. In this situation, the gain achieved by the trans-muscular technique may be even more significant. Reulen also noticed this difference and stated that at L4-L5 the trans-muscular approach should be set as the standard technique⁹.

Airaksinen¹⁷ and Sihvonen¹⁸ demonstrated that posterior midline approaches to the lumbar spine may cause atrophy of the para-vertebral muscles and that it correlated with persistent low back pain after surgery. Boelderl¹⁹ studied the para-ver-

Table 2. Average depth of foramen, of each approach, and of angles, with the respective confidence interval (95%).

	Depth of foramen	Depth of para-muscular access	Depth of trans-muscular access	Angle with para-muscular access	Angle with trans-muscular access
L1-L2	5.3±0.46	6.3±0.52	8.0±0.38	32±7.1	48±4.7
L2-L3	5.8±0.59	6.5±0.52	8.3±0.40	26±5.5	45±5.4
L3-L4	6.2±0.51	6.9±0.49	8.6±0.38	25±4.8	43±4.2
L4-L5	6.9±0.66	7.5±0.59	8.6±0.66	23±5.3	36±5.8

Measurements in cm.

tebral innervation and concluded that the correspondent branches may be stretched and damaged if the muscles are retracted laterally to the articular processes, a required procedure in the para-muscular technique. Thus, the trans-muscular approach, besides providing a better angle of vision, is also less likely to endanger the para-vertebral muscles and their innervation. A prospective study comparing patients submitted to surgery with each of these approaches should be conducted in order to establish if there is any impact on outcome.

REFERENCES

1. Abdulah AF, Dito EW III, Byrd EB, Williams R. Extreme lateral lumbar disc herniation: clinical syndrome and special problems of diagnosis. *J Neurosurg* 1974;41:229-234.
2. Porchet F, Cholet-Bornand A, de Tribolet N. Long-term follow up of patients surgically treated by the far-lateral approach for foraminal and extraforaminal lumbar disc herniations. *J Neurosurg* 1999;(Spine 1);90:59-66.
3. Basile R Junior, Mendonça ABF Netto, Napoli MMM, Bonetti CL, Barros TEP Filho. Hérnia de disco lombar lateral: foraminal e extraforaminal. *Rev Hosp Clin. Fac Med S Paulo* 1986;41:177-180.
4. Epstein NE. Evaluation of varied surgical approaches used in the management of 170 far-lateral disc herniations: indications and results. *J Neurosurg* 1995;83:648-653.
5. Mixter WJ, Barr JS. Rupture of the intervertebral disc with involvement of the spinal canal. *N Engl J Med* 1934;211:210-215.
6. Donaldson WF, Star MJ, Thorne RP. Surgical treatment for the far lateral herniated lumbar disc. *Spine* 1993;18:1263-1267.
7. Maroon JC, Kopitnik TA, Schulhof LA, Abla A, Wilberger JE. Diagnosis and microsurgical approach to far lateral disc herniation in the lumbar spine. *J Neurosurg* 1990;72:378-382.
8. Reulen HJ, Pfaunder S, Ebeling U. The lateral microsurgical approach to the "extracanalicular" lumbar disc herniation. I: a technical note. *Acta Neurochir (Wien)* 1987;84:64-67.
9. Reulen HJ, Muller A, Ebeling U. Microsurgical anatomy of the lateral approach to extraforaminal lumbar disc herniations. *Neurosurgery* 1996;39:345-350.
10. Schlesinger SM, Fankhauser H, de Tribolet N. Microsurgical anatomy and operative technique for extreme lateral lumbar disc herniations. *Acta Neurochir (Wien)* 1992;118:117-129.
11. Haher TR, O'Brien M, Dryer JW, Nucci R, Zipnick R, Leone DJ. The role of the lumbar facet joints in spinal stability. *Spine* 1994;19:2667-2671.
12. Watkins MB. Posterolateral fusion of the lumbar and lumbosacral spine. *J Bone Joint Surg. Am* 1953;35-A:1014-1018.
13. Wiltse LL, Bateman JG, Hutchinson RH, Nelson WE. The paraspinous sacrospinalis-splitting approach to the lumbar spine. *J Bone Joint Surg. Am* 1968;50A:919-926.
14. Recoules-Arche D. La chirurgie de la hernie discale du canal de conjugaison lombaire. *Neurochirurgie* 1985;31:61-64.
15. Fankhauser H, de Tribolet N. Extreme lateral disc herniation. *Br J Neurosurg* 1987;1:111-129.
16. Muller A, Reulen HJ. A paramedian tangential approach to lumbosacral extraforaminal disc herniations. *Neurosurgery* 1998;43:854-862.
17. Airaksinen O, Herno A, Kaukanen E, Saari T, Sihvonen T, Suomalainen O. Density of lumbar muscles 4 years after decompressive spinal surgery. *Eur Spine J* 1996;5:193-197.
18. Sihvonen T, Herno A, Paljarvi L, Airaksinen O, Partanen J, Tapaninaho A. Local denervation atrophy of paraspinous muscles in postoperative failed back syndrome. *Spine* 1993;18:575-581.
19. Boelderl A, Daniaux H, Kathrein A, Maurer H. Danger of damaging the medial branches of the posterior rami of spinal nerves during a dorsomedian approach to the spine. *Clin Anat* 2002;15:77-81.