

MULTIPLE MENINGIOMAS WITHIN THE SPINAL CANAL

Case report with 23 tumors

José Alberto Gonçalves da Silva¹, Maurus Marques de Almeida Holanda¹, Antônio Fernandes de Araújo¹, Roberto Vieira de Mello²

ABSTRACT - In most series of neoplasms of the spinal canal, spinal cord and its leptomeninges, the incidence of meningioma group comprises approximately 25%. The incidence of multiple meningiomas is small when compared with the frequency of its single occurrence. In the majority of cases, their multiplicity is intracranial and spinal. Multiple meningiomas confined exclusively to the spinal canal are extremely rare. We report on a 33 years-old man, with 23 tumors located in the spinal thoracic region.

KEY WORDS: meningioma, multiple meningiomas, spinal canal tumors.

Meningiomas intrarraqueanos múltiplos: relato de caso com 23 tumores

RESUMO - Na maioria das casuísticas de neoplasias do canal espinhal, medula espinhal e leptomeninges, os meningiomas compreendem 25%. A incidência de meningiomas múltiplos é pequena quando comparada com sua frequência isolada. Na maioria dos casos, a ocorrência múltipla é intracraniana e espinhal. Meningiomas múltiplos localizados exclusivamente no canal raqueano são extremamente raros. Relatamos o caso de homem de 33 anos com 23 tumores, localizados na região torácica espinhal.

PALAVRAS-CHAVES: meningioma, meningiomas múltiplos, tumores intrarraqueanos.

Isolated spinal canal neurinomas and meningiomas are usually benign and relatively frequent¹⁻⁴. Locat (1753) and Horsley (1877) (apud Gluszczyk et al.⁵) were the first surgeons to resect a neurinoma and a meningioma, respectively. Rand⁶ admits that meningiomas originate from nests of cells of the arachnoid membrane's outer layer, giving rise to the meningothelial type, while the fibrous type originates from the fibrous elements of the arachnoid web.

The occurrence of multiple meningiomas is ordinarily seen inside the cranium⁷⁻¹³ and, in a smaller number of cases, both in the skull and in the spine^{7,8,12}. However, the occurrence of multiple spinal canal meningiomas is extremely rare, as can be observed in the literature, with findings varying between 2 and 3 tumors^{4,6,14-16}. Nevertheless, Chaparro et al.¹⁷ described an unique case with 47 distinctly separate spinal meningiomas in the absence of neurofibromatosis or identified chromosomal ab-

normality. The patient died 37 months later when he developed brain stem meningiomas.

The present study describes a rare case of multiple spinal canal meningiomas, in which 23 tumors were resected within a 15-year period. This study was authorized by the Ethics Committee of the hospital.

CASE

A 33-year-old white man, farmer, developed, on five different occasions, clinical features characterized by a progressive motor deficit of the lower limbs, associated with thoracic sensitive levels varying from T12 to T4, which installed themselves as the disease progressed, as well as with the hypopallesthesia of the lower limbs. The neurological examination showed marked spastic paraparesis, which prevented the patient from walking around, associated with signs of pyramidal deficits. After the fifth operation the patient presented with paraplegia and transitory urinary retention. After each surgery he improved progressively and even managed to walk without any

¹Department of Neurosurgery, Hospital Santa Isabel, João Pessoa PB, Brazil; ²Department of Neuropathology, University of Pernambuco, Recife PE, Brazil. This paper is dedicated to Prof. Dr. med. Hermann Dietz for his 80th birthday

Received 25 March 2004, received in final form 14 July 2004. Accepted 15 September 2004.

Dr. José Alberto Gonçalves da Silva - Avenida Minas Gerais 1150 - 58030-092 João Pessoa PB - Brasil.

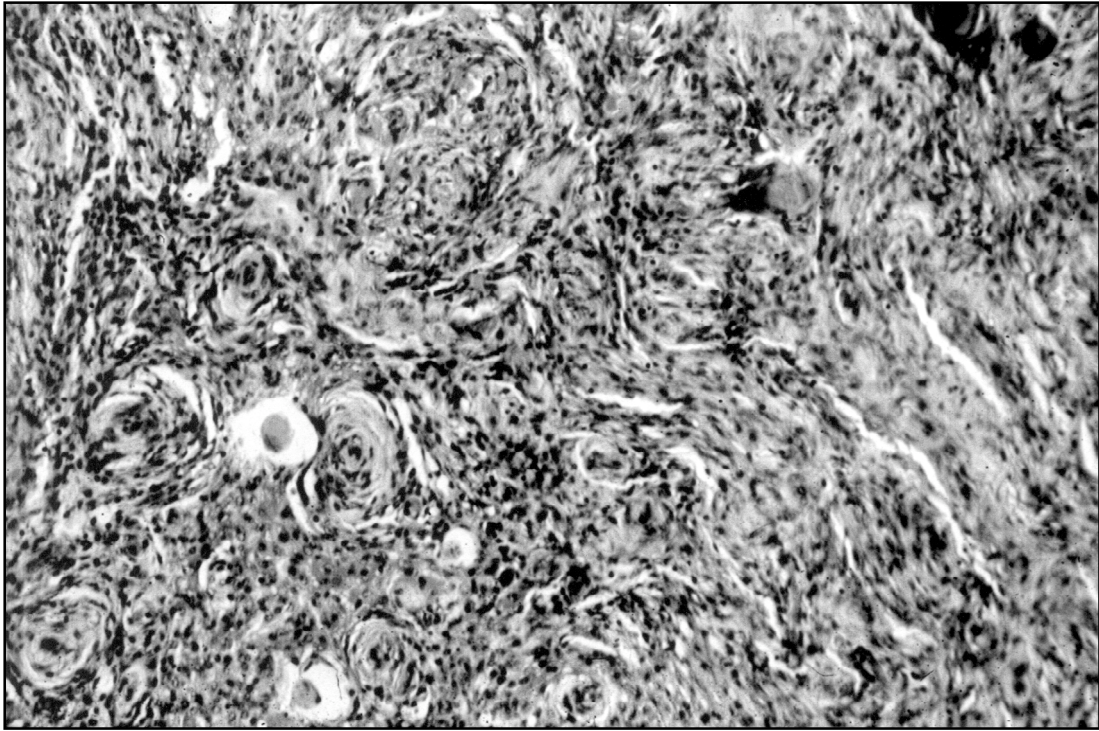


Fig 1. Characteristic pathological pattern of a psammomatous meningioma.

support. The radiological diagnosis was performed by lipiodol contrasted myelography in the first operation and through magnetic resonance image (MRI) in the others, with this latter method revealing the presence of tumors only in the thoracic region. The MRI of the skull and of the cervical and lumbar spine were normal. The histopathological examination of the first surgery was lost, and in the other operations revealed the presence of a meningothelial meningioma, grade I WHO (Fig 1).

The first operation was performed on May 20, 1987, with a laminectomy of T10 and T11, and the total resection of an encapsulated tumor that also dorsally adhered to the spinal cord. The patient returned to work normally until the year 2000.

The second operation was performed on January 12, 2001, when a T8 to T12 laminectomy was performed and 12 tumors of different sizes, varying from 4 mm to 10 mm, situated anterolaterally to the spinal cord were resected (Fig 2).

The third operation was performed on November 22, 2002, through a T6 to T7 laminectomy, with the resection of two tumors, situated laterally to the spinal cord (Fig 3).

The fourth operation was performed on June 18, 2002, through a T4 to T5 laminectomy. One tumor that excessively compressed the spinal cord and 6 smaller ones with diameters of 1.5 mm to 2.5 mm, attached to the dura-mater and easily excised, were resected. They were located anterior and laterally to the spinal cord.

The fifth operation was performed on September 12,

2002, with the exposure of the spinal cord segments from T6 to T9. A tumor, with diameter of approximately 10 mm, which did not compress the spinal cord, was resected. There was an arachnoidal cyst, with a T7 to T9 length, which compressed the spinal cord and closely adhered to it (Fig 4). This cyst was dissected, with the spinal cord becoming free after the dural graft. After this operation we noticed the presence of paraplegia and urinary retention, which subsequently diminished. At the time of discharge, the patient was already able to perform flexion and extension movements of the lower limbs.

DISCUSSION

Spinal canal meningiomas account to about 25% of all spinal cord tumors^{6,11,18}. Helseth and Mark (Apud Roux et al.¹⁹) have reported an annual incidence of spinal canal neoplasms of around 5 cases / million for female and 3 cases / million for male. As a matter of fact, the literature shows a prevalence of 80% to 90% of meningiomas in the female^{1,2,20}. This prevalence would supposedly be related to a dependence on steroid hormones⁴.

The rarity of multiple spinal canal meningiomas may be verified in several publications describing a large number of cases. For instance, the Cohen-Gadol series 21, of 40 cases; Roux et al.¹⁹, 54 cases and Klekamp et Samii³, 117 cases, without the pre-

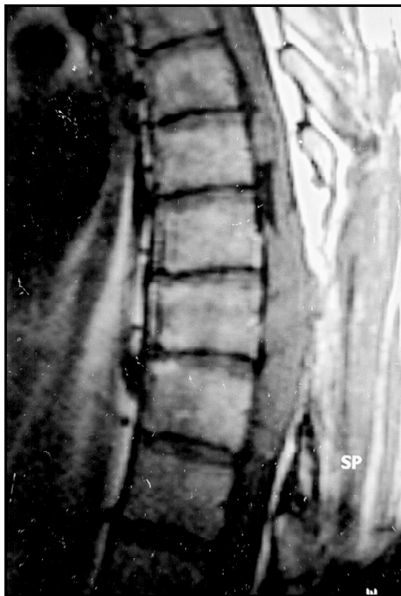

Fig 2. MRI shows a group of tumors that, at first sight, seems to be a stop, but they are really several associated and independent tumors.

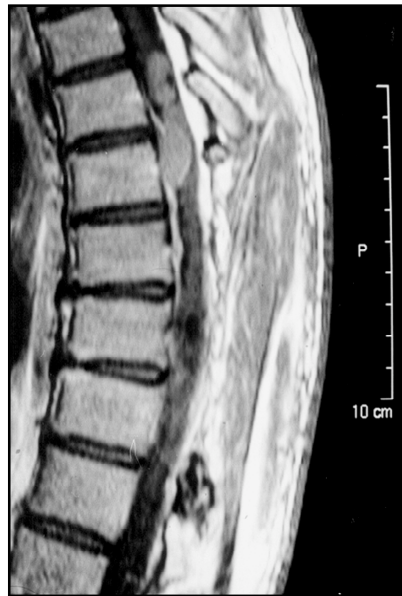

Fig 3. MRI shows two tumors at the T6-T7 level.

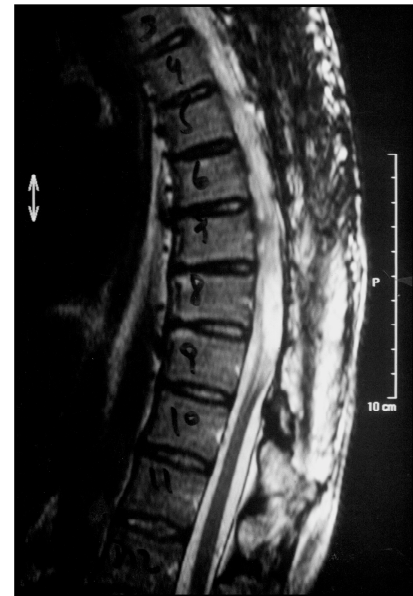

Fig 4. MRI shows the presence of a tumor at the T6 level, and an arachnoid cyst of T7 to T9.

sence of a single case of multiple meningioma, Solero et al.⁴ observed only one case of multiple meningioma among 174 cases of surgery for spinal cord meningiomas.

As a rule, spinal canal meningiomas are benign and occur more frequently in elderly people. Usually they are circumscribed and shows a slow growth and have a good post-surgical prognosis. On the other hand, the meningiomas that occur in younger patients might have an aggressive behavior and an unfavorable prognosis²¹.

The clinical feature is characterized by a motor deficit, varying from a slight impairment to paralysis, with pyramidal liberation signs, sphincter disturbances and signs of funicular or radicular impairment. Ordinarily, the symptomatology is restricted to a root or is associated to several sensitive and motor neurological signs^{1,4,5,16,19,20}.

In the present case, the patient operated on May 20, 1987 showed signs of spastic paraparesis with pyramidal signs, which totally regressed after the resection of a meningioma located at the level of T10 - T11, and remained asymptomatic until the year 2000. At that time, there were four worsening stages of the clinical picture, varying from spastic paraparesis to nearly paraplegia, with successive surgeries aimed at resecting other tumors, always with

a post-operative improvement after each surgery and subsequent worsening. In all, 23 tumors varying from 2-3 mm, 1.7 x 0.8 x 0.5 cm were resected.

The preference location of meningiomas is at the thoracic level^{1,3,4,6,16,19,20}, followed by the cervical region and, finally, the lumbar region^{3,4}. Meningiomas can occur in any point of the spinal canal, especially at the emergence of the sensitive root, in an intradural location, and rarely in an epidural one^{14,15,19,20}.

Meningiomas may be located in the anterior, posterior and lateral regions of the spinal canal. Klekamp and Samii³, in 117 cases of spinal meningiomas, observed that their location was anterior in 27% of the cases, while in 28% of the cases the tumoral matrix was posterior and in 45% the matrix was lateral. On the other hand, Roux et al.¹⁹, in a total of 54 cases observed that the meningioma was implanted in an anterior or anterolateral situation in 21 cases, posterior or posterolateral in 18, lateral in 12 cases and circumferential in 3. Solero et al.⁴ observed in their series of 174 cases of spinal meningiomas that in 90% of the cases they are located intradurally, 5% extradurally and 5% both intra and extradurally, with the tumors being found in the lateral portion of the spinal cord in 68% of the cases, posterior in 18% and anterior in 15%.

In the present case, the tumors were located in the lateral and anterolateral regions of the spinal cord, and in only one case, the tumor was dorsally situated. The tumors were easily resected, specially the smaller ones that were attached to the dura-mater, with the greater part of these small tumors not being identified by MRI.

Surgical treatment is favorable in the majority of the cases with a total resection of the tumors. Klekamp et Samii³ achieved 89% of total resection in 117 cases of spinal meningiomas, while Solero et al.⁴, in 174 cases of spinal meningiomas attained 97% of total resection. Most authors report good results in 74% to 100% of the cases^{1,4,5,8,19}. Meningiomas grow slowly, are easily resectable from the place where they are implanted and from their discrete adherences to the spinal cord. However, resecting calcified meningiomas is a rather difficult process¹⁹.

The post-operative complications mentioned in the literature are rare and transitory. However, one can report cases of paraplegia after the resection of meningiomas located anteriorly to the spinal cord. Klekamp et Samii³ found 11.2% of complications in 117 cases of spinal cord meningiomas, and Solero et al.⁴ found 3.5% in 174 cases. Mortality varies among the consulted authors, with Solero et al.⁴ having found 1.4%, Klekamp et Samii³ 5.1% and Gallo et al.¹ 9%.

The recurrence of spinal cord meningiomas, even after total resection, is reported by several authors. Solero et al.⁴ observed a reincidence in 6% in their series. Scott et al.¹⁵ operated on a case of multiple melanotic meningiomas in the cervical region of C2 to C6, with the recurrence of another melanotic meningioma in C5, 14 years after the first operation, another one tumor 16 years later and, in the fourth operation, another intradural meningioma of the fibroblastic type. According to Klekamp et Samii³, the recurrence of meningiomas is calculated in accordance with the Kaplan-Meier method, in 21% after one year and in 40.3% after 5 years.

Multiple meningiomas are ordinarily found to be associated to von Recklinghausen's disease. However, cases of multiple meningiomas without the stigmata have been observed, thus characterizing type II neurofibromatosis^{6,16,22}. Kernohau (apud Rand⁶), suggested that histological manifestation

of meningiomas simultaneously with von Recklinghausen's disease, may be atypical and resemble neurofibromas. In Rand's case⁶, with two spinal canal meningiomas, as well as in the case under study, with 23 tumors, there were no neurofibromatosis stigmata.

On the other hand, Artunes and Zauk⁷ developed three theories in order to explain the origin of multiple meningiomas: the polycentric theory admits the existence of multiple originating foci, with a predominant hereditary aspect; the venous dissemination theory, mainly through the sagittal sinus, explains the multiple intracranial location; the liquoric dissemination theory does not explain the greater incidence of intracranial meningiomas over the spinal canal ones. An evidence in favor of this theory is based on the liquoric dissemination of malignant meningiomas.

As to the type of meningioma, Roux et al.¹⁹, without any case of multiple meningioma, observed 44% of meningothelial meningioma, 20.5% of psammomatous, with the anaplastic, the fibroblastic, the transitional, the meningopsammomatous, the fibropsammomatous and the meningofibroblastic showing up with lesser frequency. Solero et al.⁴ found in their series of 174 cases involving spinal canal meningiomas, with only one being of a multiple meningioma, 99 cases of psammomatous meningioma, 52 meningotheliomatous, 17 transitional, one hemangioblastic and one anaplastic.

Regarding the cases of spinal canal multiple meningiomas, the psammomatous type predominated^{6,14,16,20,22}, while Scott, et al.¹⁵ reported a case with several melanotic meningiomas. In the present case, with the exception of the meningioma that was resected in the first surgery, whose histopathological examination was lost, all the other 23 meningiomas were classified as meningothelial. Possibly this case is associated to type II neurofibromatosis, which occurs without the stigmata of the disease.

REFERENCES

1. Gallo P, Fabião OM Neto, Soares JMM, Ordovás CA, Gluszczyk P, Krebs CLL. Neurinomas e meningiomas intracraniais: estudo comparativo de 23 casos. *Arq Bras Neurocirurg* 1991;10:131-136.
2. Guidetti B. Removal of extramedullary benign spinal cord tumours. In *Advances and technical standards in neurosurgery*, vol 1. Wien, Springer Verlag, 1974;173-197.
3. Klekamp J, Samii M. Surgical results for spinal meningiomas. *Surg Neurol* 1999;52:552-562.
4. Solero CL, Fornari M, Giobini S, et al. Spinal meningiomas: review of 174 operated cases. *Neurosurgery* 1989;125:153-160.

5. Gluszczyk P, Krebs CLL, Gallo P. Meningioma intracranial: a propósito de 11 casos. *Arq Bras Neurocirurg* 1989;8:101-104.
6. Rand RW. Multiple spinal cord meningiomas. *J Neurosurg* 1952;9:310-314.
7. Antunes ACM, Zauk AD. Meningioma múltiplo: relato de caso e revisão da literatura. *Arq Bras Neurocirurg* 1984;3:95-99.
8. Cushing H, Eisenhardt L. Meningiomas: their classification, regional behaviour, life history, and surgical end results. New York: Hafner, 1964;3:387.
9. Ekong CEU, Paine KWE, Rodilsky B. Multiple meningiomas. *Surg Neurol* 1978;9:181-184.
10. Enam AS, Abdulrauf S, Metha B, Malik GM, Mahmood A. Metastasis in meningioma. *Acta Neurochir (Wien)* 1996;138:1172-1178.
11. O'Neill P, Booth AE. Multiple meningiomas: case report and review of the literature. *Surg Neurol* 1984;21:80-82.
12. Santos JAN, Andrade D, Andrade V, Novaes V. Meningiomas múltiplos: apresentação de três casos. *Arq Bras Neurocirurg* 1995;14:96-104.
13. Suwa T, Kawano N, Oka H, Kameya T. Invasive meningioma: a tumour with high proliferating and recurrence potential. *Acta Neurochir (Wien)* 1995;136:127-131.
14. Rath S, Mathai KV, Chandy J. Multiple meningiomas of the spinal canal: case report. *J Neurosurg* 1967;26:639-640.
15. Scott M, Ferrara VL, Peale AR. Multiple melanotic meningiomas of the cervical cord: case report. *J Neurosurg* 1971;34:555-559.
16. Zervas NT, Shintani A, Kallar B, Berry RG. Multiple meningiomas occupying separate neuraxial compartments: case report. *J Neurosurg* 1970;33:216-220.
17. Chaparro MJ, Young RF, Smith M, Shen V, Choi BH. Multiple spinal meningiomas: a case of 47 distinct lesions in the absence of neurofibromatosis or identified chromosomal abnormality. *Neurosurgery* 1993;32:298-302.
18. Camp JD. Multiple tumors within the spinal canal: diagnosis by means of lipiodol injected into the subarachnoid space (myelography). *Am J Roentgen* 1936;36:775-781.
19. Roux FX, Nataf F, Pinaudeau M, Borne G, Deveaux B, Meder JF. Intraspinal meningiomas: review of 54 cases with discussion of poor prognosis factors and modern therapeutic management. *Surg Neurol* 1996;46:458-464.
20. Haft H, Shenkin HA. Spinal epidural meningioma: case report. *J Neurosurg* 1963;20:801-804.
21. Cohen-Gadol AA, Zikel OM, Koch CA, Scheithauer BW, Krauss WE. Spinal meningiomas in patients younger than 50 years of age: a 21-year experience. *J Neurosurg (Spine 3)* 2003;98:258-263.
22. Patronas NJ, Brown F, Duda EE. Multiple meningiomas in the spinal canal. *Surg Neurol* 1980;13:78-80.