

# TECTAL PLATE TUMORS

Bruno C.R. Lázaro<sup>1</sup>, José A. Landeiro<sup>2</sup>

**ABSTRACT** - Tectal plate is a rare location for a tumor. Many papers have described different types of pathology arising in that location including tumors, vascular lesions, inflammatory and infectious processes. In this paper we describe our experience in treating seven patients with tectal plate lesions, with different ages and types of pathology: five patients presented with low grade gliomas, one with lung cancer metastasis and the last presenting with a tectal plate cavernoma. Open surgery was performed in three cases (due to tumor enlargement or need for the exact diagnosis). In the other cases, the treatment of non-communicating hydrocephalus was the only treatment employed. The prognosis is of course dependent on the underlying pathology. In our series, except in the metastatic tumor case and the cavernoma, the other types of lesion consisted of low grade gliomas. These lesions represent a different type of brain stem tumor sharing a common good prognosis, with a benign behavior. We believe that tectal tumors must be managed case by case. When a patient presents with a benign lesions in the tectal region, treating the main symptom - hydrocephalus - should be the first attempt in management of these lesions.

**KEY WORDS:** brain stem, tectal tumors, brain stem tumors, third ventriculostomy.

## Tumores da região tectal

**RESUMO** - Tumores na região do teto mesencefálico são raros. Vários tipos de lesões como tumores, lesões vasculares, inflamatórias e infecciosas localizam-se nesta região. Nós revimos o tratamento adotado em sete pacientes com diferentes tipos de lesões tectais: cinco pacientes apresentando gliomas de baixo grau, um paciente com lesão metastática proveniente de câncer de pulmão e um com cavernoma. O tratamento cirúrgico com abordagem direta da lesão foi realizado em três casos (devido ao aumento do volume tumoral ou quando houve necessidade da confirmação diagnóstica). Nos demais casos o tratamento para a hidrocefalia não-comunicante foi o método empregado. O prognóstico dessas lesões é baseado no tipo de patologia em questão. Em nossa série, com exceção do caso de metástase e do paciente com cavernoma, as demais lesões foram gliomas de baixo grau. Estas lesões representam um subgrupo diferenciado de tumores de tronco encefálico, apresentando bom prognóstico e tendo comportamento benigno com sobrevida elevada. Acreditamos que tumores da região tectal devam ser avaliados caso a caso. Na hipótese diagnóstica de uma lesão benigna, o tratamento do principal complexo sindrômico - hidrocefalia não-comunicante - é provavelmente a melhor conduta a ser empregada.

**PALAVRAS-CHAVE:** tronco cerebral, tumores da região tectal, ventriculostomia.

Brain stem tumors are a wide described pathology. Most of the papers available in the literature are of interest to the pediatric group. In general, it is accepted that brain stem tumors account for approximately 10-30% of brain tumors in children<sup>1-10</sup>. In these cases, three main groups are identifiable, according to location and prognosis. Diffuse pontine is the largest subgroup carrying a worst prognosis with a median survival of approximately one year; slow growing low grade gliomas comprise the second subgroup, arising at the cervicomedullary junction or from the floor of the 4<sup>th</sup> ventricle bearing a

long survival rate - almost more than 5 years. The third subgroup is represented by focal tectal gliomas<sup>1</sup>.

On the other hand, brain stem tumors in adults - especially gliomas - are poorly understood in terms of low incidence and different pattern of behavior. Over all, it is actually observed that the prognosis of brain stem tumors is better in adults than in children. The peak incidence prevailed in the third and fourth decade in adults and in the first decade in children<sup>2</sup>. Among tumors found in the tectal plate, the most common is the astrocytoma, but other types have been described, such as oligodendroglioma, ependy-

<sup>1</sup>Department of Neurosurgery, Brazilian Air Force Hospital, Rio de Janeiro, RJ, Brazil; <sup>2</sup>M.D., Ph.D, Head of Department.

Received 4 October 2005, received in final form 16 January 2006. Accepted 17 February 2006

Dr. José A. Landeiro - Brazilian Air Force Hospital - Estrada do Galeão 4101 - Rio de Janeiro RJ - Brasil. E-mail: jlandeiro@aol.com

moma, ganglioglioma, medulloblastoma<sup>3</sup>, primitive neuroectodermal tumors, metastasis; as well as lipoma<sup>11</sup>, melanoma<sup>12</sup>, dysembryoplastic neuroepithelial tumor (DNT)<sup>13</sup>, cavernomas, abscess and periaqueductal gliosis.

We present seven cases of tumors arising in the tectal plate managed in our institution.

## METHOD

We present seven cases of patients with mesencephalic tectal plate tumors treated in our institution, in a retrospective analysis, between 1994 – 2005. There are 3 male and 4 female patients in this group with ages comprising 17 to 70 years-old.

Five patients presented Parinaud syndrome; all cases presented with noncommunicating hydrocephalus. Image studies were performed in all cases involving computed tomography scan (CT) and magnetic resonance image (MRI) demonstrating lesions with the aspect of a low grade glioma in five cases, one case of high grade tumor (lung cancer metastasis), and the other presenting a vascular lesion (cavernoma).

The follow up period was over 8 years (1 to 8 years in average); open surgery was performed in 3 cases - 2 cases (see illustrative cases below), cavernoma and the metastasis case - obtaining a definitive diagnosis; third ventriculostomy was performed in the other five cases (Table); in one case two procedures were necessary (see illustrative cases below). There was one death – the metastatic tumor due to progressive disease (Table).

## Illustrative cases

**Case 1** – A 26-year-old woman presented to our hospital with headache, nausea, papilledema and visual blurring. The CT scan revealed a noncommunicating hydrocephalus and a hypodense lesion on the tectal region (Fig 1). MRI demonstrated a tectal plate lesion (Fig 2) with lack of contrast enhancement.

She initially underwent ventricular-peritoneal shunt placement achieving adequate control and improvement of the symptoms, returning to normal activities and work afterwards.

One year later she returned to neurosurgical care presenting with worsening of the symptoms associated with incomplete Parinaud syndrome. A new MRI was performed and showed hydrocephalus and an increase of the lesion size (Fig 3). The shunt appeared to be malfunctioned. The tumor was removed using the semi-sitting position achieving a gross total removal of the lesion, as presented in MRI (Fig 4). She experienced an improvement of the symptoms, being discharged from the hospital one week later.

Histopathological analysis revealed a grade II astrocytoma.

**Case 2** – A 24-year-old man was admitted with a history of somnolence, disorientation, headache and Parinaud syndrome. He had undergone placement of a ventricular-peritoneal shunt 10 years before in another hospital for a diagnosis of “hydrocephalus” (history collected from his mother). A CT scan was performed showing a noncommunicating hydrocephalus. MRI was performed corroborating the diagnosis showing a T1 hypointense lesion located at the tectal plate.

Table 1. tectal tumors case reports.

Patient	Age (years)	Gender	CT	MRI	Surgery	Diagnosis
I	24	Male	Hydrocephalus	Hydrocephalus Tectal mass	Third Ventriculostomy	Low grade glioma (presumed)
II	26	Female	Hydrocephalus Tectal low-density image	Hydrocephalus Tectal mass	CSF shunt Tumor excision	
III	21	Female	Hydrocephalus	Hydrocephalus Tectal mass	Third Ventriculostomy	Low grade glioma (presumed)
IV	16	Female	Hydrocephalus	Hydrocephalus Tectal mass	Third Ventriculostomy	Low grade glioma (presumed)
V	17	Male	Hydrocephalus	Hydrocephalus Tectal mass	Third Ventriculostomy	Low grade glioma (presumed)
VI	60	Female	Hydrocephalus	Enhancement tectal mass	Tumor excision	Cavernoma Metastasis
VII	70	Male	Tectal hyperdense lesion	Hydrocephalus Enhancement tectal mass	Third Ventriculostomy Tumor excision	

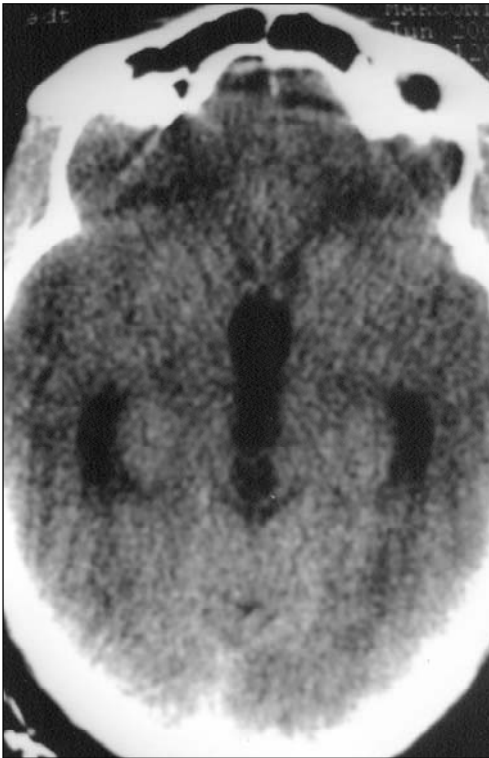

Fig 1. Brain CTscan in axial view presenting a non-communicating hydrocephalus. Note the low-density lesion on the tectal plate.

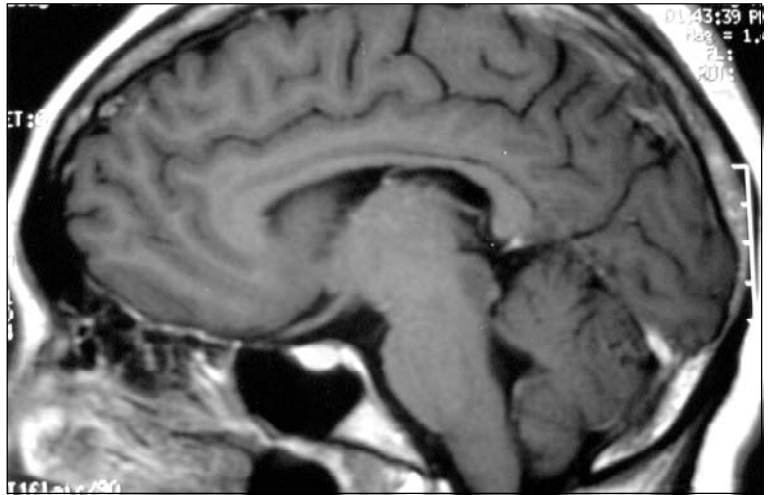


Fig 2. MRI, T1 weighted sagittal view, showing a non-enhanced tectal mass.

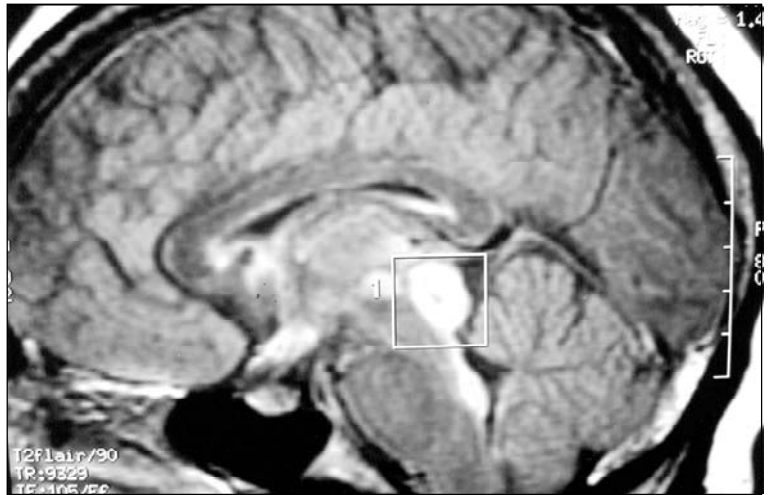


Fig 3. MRI sagittal view, T2 FLAIR, presenting a tectal mass leading to obliteration of the cerebral aqueduct.

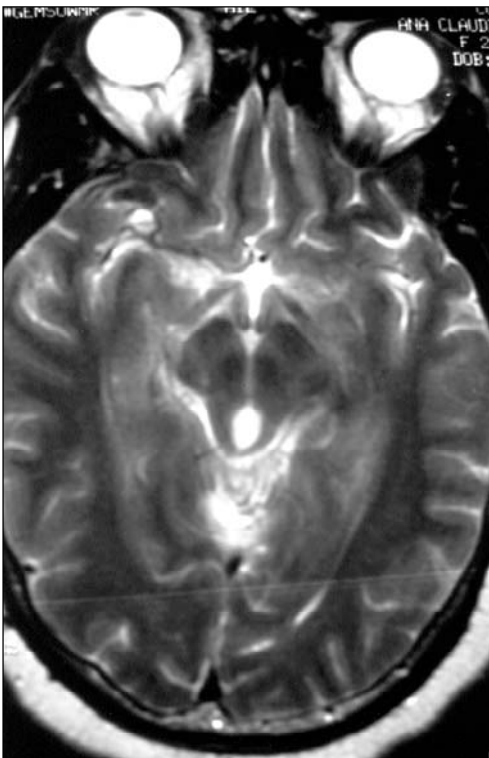


Fig 4. Postoperative MRI, T1 weighted sagittal view, showing no gadolinium enhancement on the tectal plate.

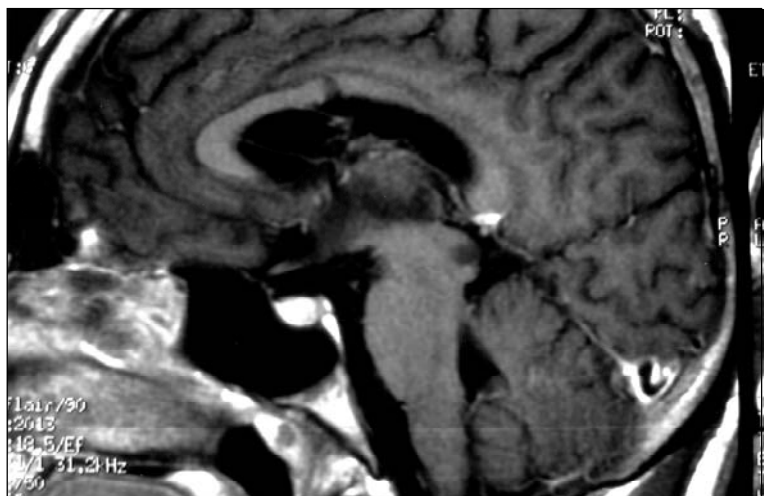


Fig 5. FLAIR T2 MRI, non-enhanced tectal mass leading to obliteration of the cerebral aqueduct. Note the corpus callosum trajectory of the neuroendoscope.

He underwent an endoscopic third ventriculostomy with an immediate post operative improving of the symptoms; the Parinaud syndrome was the last feature to disappear, occurring after one month. One year later he had recurrence of the symptoms. A new radiologic study was performed showing once again a non-communicating hydrocephalus but the average size of the tectal tumor remained the same. A second third ventriculostomy was performed improving the symptomatology. He was discharged from the hospital 5 days after the procedure without symptoms (Fig 5).

## DISCUSSION

In comparison to children, brain stem gliomas in adults is a less understood disease and present a much lower incidence (<2% of gliomas)<sup>1</sup>. The survival rate however can be very much longer with the peak incidence in the third and fourth decades<sup>2</sup>. The duration of symptoms is generally shorter in children while in adults it tends to be longer with tectal tumors, fourth ventricle dorsally exophytic tumors and cervicomedullary gliomas having a more favorable prognosis when compared to diffuse lesions.

Tectal plate gliomas have been reported as a particular indolent lesion often remaining stable in size for many years. The majority of these lesions were described as low grade gliomas, presented with late-onset aqueductal stenosis often without associated brain stem signs<sup>8</sup>. The average age at the time of diagnosis is about 10 years in children, with the majority of cases presenting with raised intracranial pressure secondary to obstruction of the Sylvian aqueduct<sup>14</sup>, with some other cases presented with Parinaud syndrome<sup>15</sup> like the patients observed in our illustrative cases, although this is also an uncommon feature. Even before the development of computed tomography, tectal tumors were an unrecognized because of late onset hydrocephalus<sup>6</sup>, once said that this can be the smallest lesion that can lead to death of the patient.

The radiologic investigation of these tumors have been up graded in the CT scan era with better visualization of the tectal region; but the majority of lesions continue to appear as noncommunicating hydrocephalus alone, although calcification or a hypodense lesion on the tectal plate can be observed. MRI of these tumors reveals tectal distortion or thickening caused by a localized mass, leading to aqueductal compression and hydrocephalus<sup>16</sup>; characteristic T1 hypointensity and T2 hyperintensity<sup>17-21</sup>. MRI is an accurate and noninvasive method of diagnosis that can be indicated in all cases of late onset hydrocephalus and aqueductal obstruction, especially in adults.

Even when present, contrast enhancement after gadolinium injection was an independent factor of tumor grading<sup>17</sup>.

The characteristics of the lesion seen on the MRI is of course dependent on its pathologic basis. In our series we presented 5 cases of patients bearing a tectal low grade glioma, with the typical MRI appearance just as described above. The other two cases – a brainstem metastasis and a tectal plate cavernoma – appeared as an irregular enhancing lesion and a small vascular-like lesion presenting an impregnation of hemosiderin, respectively.

The prognosis of tectal plate lesion is a much debated issue in neurosurgical publications. It is reasonable to expect that a malignant lesion, brain stem metastasis and rapidly infiltrating lesions present a poor prognosis. But even in cases of tectal gliomas some controversies had arise.

Initially the pathology of intrinsic tectal lesions were considered to be similar to other brainstem tumors. In fact this was later discovered as not true. Many papers have oriented the presence of this tumor as a special site of low grade gliomas<sup>4-6,9,10,18</sup>. These tumors appear to present a better prognosis given to a slow growing rate and boundaries displacement instead of an infiltrative behaviour. However, the management of the patients remains controversial. The majority of authors oriented the management including a mandatory histopathological analysis to ascertain the low grade mark, and just afterwards the adequate treatment is traced. We think that the conjunction of history, age, neuro exam and MRI appearance of a tectal lesion can be very suspicious for a low grade tumor. In our cases, there is a tendency for treating the symptom – usually non-communicating hydrocephalus – as the first option, but it is not always possible when there is a high suspicion of another type of tectal lesion, like the cavernoma and the lung cancer metastasis cases in our series.

Surgical treatment consists on tumor resection or open biopsy; generally the surgical approach is that described for pineal region lesions, like the suboccipital-transtentorial or supracerebellar-infratentorial approach, preferred by this paper's senior author and routinely performed in this institution adopting the semi-sitting position.

Ultimately, with the advance of neuroendoscopy, a new perspective in dealing with these lesions had arisen. When the objective is to treat the hydroce-

phalus, a rigid endoscope can be utilized to perform a third ventriculostomy, as we described, with no major technical complications; the visibility of the inner surface of the third ventricle, with all structures involved is very good<sup>22</sup>.

Tectal tumors may extrude from the tectum into the lumen of the cerebral aqueduct and subsequently protrude to the third ventricle, pushing away the posterior commissure and enlarging the orifice. Some authors consider this lesion as intraventricular ones, treating each lesion individually<sup>23</sup>.

With the advent of the flexible neuroendoscope other types of therapy could be performed. Potential treatment options include shunt placement<sup>24</sup> and aqueductal plasty<sup>24,25</sup>. The third ventriculostomy success and failure rate is similar to those cerebral-spinal fluid (CSF) shunts – about 30%<sup>24</sup>.

In conclusion, tectal tumors represent a differentiated category in neuro-oncology. Despite a variety of lesion encountered in this region, most publications indicate that low grade glioma is most prevalent. However, the major difficulty is regarding the adequate treatment of these lesions. A number of articles orient an invasive approach consisting of surgical treatment, given the need for mass reduction or just to obtain histopathological sample<sup>5,27,28</sup>; other authors decline to conservative treatment, justified by the benign behavior and slow growth of this tumors<sup>4,6,8,19,29,30</sup>. In our institution, the decision depends on individual analysis. We give preference in treating the major symptom – hydrocephalus – with CSF shunts or preferably endoscopic third ventriculostomy. Our study demonstrate that surgery should be indicated when there is evidence of tumor enlargement or in cases when the definitive diagnosis is imperative.

**Acknowledgement** – We thank Igor de Castro M.D for editorial assistance and José Francisco Salomão M.D. for his support

## REFERENCES

- Guillamo JS, Monjour A, Taillandier L, et al. Brain stem gliomas in adults: prognostic factors and classification. *Brain* 2001;124:2528-2539.
- Selvapandian S, Rajshekhar V, Chandy MJ. Brain stem glioma: comparative study of clinico-radiological presentation, pathology and outcome in children and adults. *Acta Neurochir* 1999;141:721-727.
- Pollack IF, Hoffman HJ, Humphreys RP, Becker L. The long-term outcome after surgical treatment of dorsally exophytic brain stem gliomas. *J Neurosurg* 1993;78:859-863.
- May PL, Blaser SI, Hoffman HL, et al. Benign intrinsic tectal "tumors" in children. *J Neurosurg* 1991;74:867-871.
- Lapras CI, Bogner L, Turjman E, et al. Tectal plate gliomas. Part I: microsurgery of the tectal plate gliomas. *Acta Neurochir* 1994;126:76-83.
- Yeh DD, Warnick RE, Ernst RJ. Management strategy for adult patients with dorsal midbrain gliomas. *Neurosurgery* 2002;50:740.
- Epstein FJ, Farmer JP. Brain stem glioma growth patterns. *J Neurosurg* 1993;78:408-412.
- Pollack IF, Pang D, Albright AL. The long term outcome in children with late-onset aqueductal stenosis resulting from benign intrinsic tectal tumors. *J Neurosurg* 1994;80:681-688.
- Vandertop WP, Hoffman HJ, Drake JM, et al. Focal midbrain tumors in children. *Neurosurgery* 1992;31:186-194.
- Wang C, Zhang J, Liu A, et al. Surgical treatment of primary midbrain gliomas. *Surg Neurol* 2000;53:41-51.
- Uchino A, Hasuo K, Matsumoto S, Masuda K. MRI of dorsal mesencephalic lipomas. *Clin Imaging* 1993;17:12-16.
- Weiding SM, Press GA, Hasselink JR. *Am J Neuroradiol* 1988;9:214-215.
- Kurtkaya-Yapici O, Elmaci I, Boran B, et al. Dysembryoplastic neuroepithelial tumor of the midbrain tectum: a case report. *Brain Tumor Pathol* 2002;19:97-100.
- Gomez-Gonzalez FA, Menor F, Morant A, et al. Tectal tumors in paediatrics. A review of eight patients. *Rev Neurol* 2001;33:605-611.
- Moffie D, Ongerboer de Visser BW, Stefanko SZ. Parinaud syndrome. *J Neurol Sci* 1983;58:175-183.
- Antunes NL, Tavora L, Souweidane M. Globular glioma of the tectum. *Pediatr Neurol* 1999;21:492-495.
- Bogner L, Turjman F, Villanyi E, et al. Tectal plate gliomas Part II: CT scans and MRI imaging of tectal gliomas. *Acta Neurochir* 1994;127:48-54.
- Ramina R, Neto MC, Fernandes YB et al. Intrinsic tectal low grade astrocytomas. *Arq Neuropsiquiatr* 2005;63:40-45.
- Bowers DC, Georgiades C, Aronson LJ et al. Tectal gliomas: natural history of an indolent lesion in pediatric patients. *Pediatr Neurosurg* 2000; 32:265-271.
- Hamilton MG, Laurusen C, Hagen N. Focal midbrain glioma: long term survival in a cohort of 16 patients and the implications for management. *Can J Neurol Sci* 1996;23:204-207.
- Smith RR, Zimmerman RA, Packer RJ et al. Pediatric brain stem glioma: post-radiation clinical and radiographic follow-up. *Neuroradiology* 1990;32:265-271.
- Oka K, Go Y, Kin Y, Tomonaga M. An observation of the third ventricle under flexible fiberoptic ventriculoscope: normal structure *Surg Neurol* 1993;40:273-277.
- Oka K, Kin Y, Go Y, et al. Neuroendoscopic approach to tectal tumors: a consecutive series. *J Neurosurg* 1999;91:964-970.
- Bulsara KR, Villavicencio AT, Shah AJ, et al. Successful aqueductal plasty and stenting for tectal plate tumor after failed third ventriculostomy: a case report. *Surg Neurol* 2003;59:58-62.
- Oka K, Yamamoto M, Ikeda K, Tomonaga M. Flexible endoneurosurgical therapy for aqueductal stenosis. *Neurosurgery* 1993;33:236-242.
- Schröder HW, Gaab MR. Endoscopic aqueductoplasty. *Neurosurgery* 1999;45:508-517.
- Koziarsky A, Zielinski G, Podgorski JK, Waczynska A. One stage removal of periaqueductal glioma in adult via infratentorial supracerebellar and transaqueductal approaches. *Acta Neurochir* 2004;146:169-173.
- Robertson PL, Muraszko KM, Brumberg JA, Axtell RA, Dauser RC, Turrisi AT. Pediatric midbrain tumors: a benign subgroup of brain stem gliomas. *Pediatr Neurosurg* 1995;22:65-73.
- Squins LA, Allen JC, Abbot R, Epstein FJ. Focal tectal tumors: management and prognosis. *Neurology* 1994;44:953-956.
- Daglioglu E, Cataltepe O, Akalan N. Tectal gliomas in children: the implications for natural history and management strategy. *Pediatr Neurosurg* 2003;38:223-231.