

## CORPUS CALLOSUM INDEX

### A practical method for long-term follow-up in multiple sclerosis

*Fernando Faria Andrade Figueira<sup>1</sup>, Valeria Silva dos Santos<sup>2</sup>,  
Gustavo Medeiros Andrade Figueira<sup>3</sup>, Ângela Correa Marques da Silva<sup>4</sup>*

**ABSTRACT** - Rather than acute inflammation, long-standing multiple sclerosis (MS) course is hallmarked by relentless axonal loss and brain atrophy, both with subtle clinical expression and scarcely visible on conventional MRI studies. Brain atrophy imaging has sophisticated methodological requirements, not always practical and accessible to most centers. Corpus callosum (CC) is a major inter-hemispheric white matter bundle, grossly affected by long term MS and easily assessed by MRI. To determine whether a practical imaging method can reliably follow presumed axonal loss in patients with progressive MS, we designed a 5-year prospective open label study, enrolling 128 consecutive patients (75 relapsing-remitting (RR) and 53 secondary-progressive (SP)), on regular immunomodulatory therapy compared to control group, formed by 23 patients with MRI considered normal. On a conventional best mid-sagittal T1W, CC index (CCI) was obtained by measuring anterior, medium and posterior segments of CC, normalized to its greatest anteroposterior diameter using an orthogonal semi-automated linear system. CCI was measured at baseline and at least once yearly. Results were plotted intra-individually; baseline values were used as reference. At baseline, CCI was able to distinguish SP patients from RR and controls, and on follow-up, despite some overlap, demonstrated a progressive reduction from baseline on both RR and SP groups compared to controls. From the third year on, difference between SP and RR patients reached statistical significance, which did not correlated with disability measured by EDSS. So, a corpus callosum index proved practical and feasible to longitudinally demonstrate morphometric callosal changes with potential to be used as a tool for long-term follow-up, mostly in SP patients.

**KEY WORDS:** multiple sclerosis, MRI, corpus callosum.

#### **Índice de corpo caloso: um instrumento prático para o seguimento a longo prazo de pacientes com esclerose múltipla**

**RESUMO** - Mais do que inflamação aguda, a perda celular e conseqüente atrofia cerebral são os fatos patofisiológicos mais marcantes na fase progressiva da esclerose múltipla (EM). No entanto, relatos clínicos e de imagem por ressonância magnética (IRM) destes eventos, requerem sofisticada tecnologia, nem sempre prática e quase nunca acessível à maioria dos centros de tratamento. Deste modo, considerando a hipótese de que esta perda celular compromete fibras associativas que compõem o corpo caloso (CC), estrutura facilmente acessível à IRM convencional, nosso grupo elaborou um estudo prospectivo aberto, atualmente com 5 anos de duração, e envolvendo 128 pacientes consecutivos, todos em acompanhamento regular em nosso centro de tratamento para a EM. A aquisição do índice de CC se deu através de um "melhor" corte meio-sagital em estudo convencional de imagem ponderada por T<sub>1</sub>, utilizando um sistema linear ortogonal semi-automatizado. Este índice foi obtido no início do seguimento e sua evolução foi acompanhada anualmente. A partir do terceiro ano deste seguimento, sua diferença entre os pacientes com a forma surto-remissiva e aqueles com a forma secundariamente progressiva alcançou significância estatística. Esta diferença não mostrou correlação com o grau de incapacidade medido pelo EDSS. Assim, um índice de CC mostrou-se uma medida prática para o seguimento de alterações morfométricas do corpo caloso, provando assim potencial para ser utilizado no acompanhamento em longo prazo de pacientes com EM, em especial aqueles com a forma progressiva.

**PALAVRAS-CHAVE:** esclerose múltipla, IRM, corpo caloso.

<sup>1</sup>Head, Dept. Neurology, Hospital da Penitência, Rio de Janeiro RJ, Brazil; <sup>2</sup>Assistant, Dept. Neurology, Hospital da Penitência, Rio de Janeiro RJ, Brazil; <sup>3</sup>Post-Graduate, Federal University of State of Rio de Janeiro, Rio de Janeiro RJ, Brazil; <sup>4</sup>Speech Therapist, Dept. Neurology, Hospital da Penitência, Rio de Janeiro RJ, Brazil. Dr. Figueira received eventual support and honoraria for scientific consulting and speaking from Abbott Laboratories, Schering do Brasil, Serono and TRB Pharma. This manuscript has no financial disclosure.

Received 28 February 2007, received in final form 4 June 2007. Accepted 3 August 2007.

Dr. Fernando Faria Andrade Figueira - Dept. of Neurology / Hospital da Penitência - Rua Conde de Bonfim 1033 - 20530-001 Rio de Janeiro RJ - Brasil. E-mail: fernando@ffigueira.net

Multiple sclerosis (MS) is a systemic autoimmune disease with exclusive expression over the central nervous system (CNS), characterized, at least at presentation, in about 85% of cases, by a relapsing-remitting (RR) course. This RR course is the clinical expression of a temporal and spatial dissemination of a focal inflammatory process, clinically represented by relapses, most of them followed by a more or less complete and spontaneous remission<sup>1</sup>. Despite this classical concept, current evidence points to a silent, more widespread and ongoing inflammation, diffusely involving CNS, besides axonal loss, which has been demonstrated to occur early in the course of the disease and to be a key factor for progression of disability<sup>2-5</sup>. So, as time goes by and inflammation tends to slow down, relapses become rarer, giving place to a more relentless secondary progressive (SP) phase, hallmarked by axonal loss and brain atrophy. At this point, conventional measures used as endpoints in most pivotal short-term follow-up MS studies, such as number of relapses and magnetic resonance imaging (MRI) activity, characterized by T1 weighted (T1W) gadolinium enhancement (Gd+) and reflecting inflammation, lose sensitivity. Axonal loss in MS has scarce expression. Clinically, it leads to progressive and insidious changes in cognitive functions, such as memory and speed of mental processing, which impacts daily living activities but lacks specificity and is rarely taken into account on therapeutic decisions. On conventional imaging, its paradigm is based on morphological changes, as intracellular iron deposition, expressed by T2W hypointense sign at subcortical gray matter nuclei<sup>6</sup>, and volume reduction, as formally expressed by changes in brain parenchymal fraction (BPF)<sup>7</sup>, both too complicated to be used on daily practice. Otherwise, as it occurs widely over the CNS, clinical-imaging correlates for axonal loss are poorly specific and require sophisticated methodology, being impractical to be used on bedside basis and inaccessible to most centers<sup>8,9</sup>.

Corpus callosum (CC) is a major white matter bundle which plays an important role in functional inter-hemispheric integration, communicating cognitive information through homotopic, and some heterotopic, interconnections between the hemispheres<sup>10,11</sup>. The CC is usually grossly affected by long-term disease<sup>12</sup> and, because of its functional relevance to inter-hemispheric information transfer, it might be one of the components of the complex pathological process that leads to cognitive changes in MS. Furthermore, it is one of the few white matter tracts that can

be discretely identified by conventional MRI, having sharply demarcated two-dimensional limits on a mid-sagittal T1W imaging. So, as a consequence of these anatomic and functional properties, it is reasonable to assume that CC morphometrics might be a possible marker for the integrity of these associative fibers.

Involvement of associative fibers leads to morphometric changes in CC, affecting inter-hemispheric transfer of information and it is a major pathological substrate for slowing of mental processing on long-term MS<sup>9</sup>.

## METHOD

*Sample* – One-hundred and twenty eight consecutive non-selected patients, with diagnosis of clinically defined MS according to the International Panel criteria<sup>13</sup> and included in our institutional MS treatment program<sup>12</sup>, were followed for five years, in an open-label trial. Sample demographics are shown in Table. All patients were on follow-up according to the standard protocol of our reference center, regularly using one of the available immunomodulatory drugs for at least two years and had no relapses on prior 12-month period. A control group was formed by twenty-three patients, submitted to a normal MRI study, for a non-inflammatory neurological condition, such as epilepsy and headache.

*Imaging* – Patients were submitted to the same conventional brain MRI scanning protocol on baseline using a 1.5T Sigma Magneton scanner (Siemens AG, Germany), according to the Consortium of Multiple Sclerosis Centers Magnetic Resonance Imaging working group standard recommendations<sup>14</sup>, including an axial pre and post Gd T1W, sagittal T1W and FLAIR, axial T2W and FLAIR. Serial imaging was repeated at least annually for a 5-year period, but Gd sequences were used only if clinically indicated. All MRI were analyzed by the same examiner (FF), and, at baseline study, data were compared to those of a blind radiologist, to achieve reproducibility.

Corpus callosum index (CCI) was obtained on a conventional best mid-sagittal T1W image, using a simple orthogonal semi-automated system, by drawing a straight line at greatest anteroposterior diameter of CC and a perpendicular at its midline, owing to points a, b and c (Fig 1). Anterior (aa'), posterior (bb') and medium (cc') segments of CC were

Table. Demographic data.

	RR MS (N=75)	SP MS (N=53)	Control (N=23)
Gender (M/F)	29/46	19/34	9/14
Mean age (SD)	43.5 (8.76)	45.3 (9.32)	41.6 (8.92)
Age at MS onset	32.1 (6.28)	33.6 (9.55)	–
Duration of MS	5.2 (3.33)	14.1 (8.72)	–
Mean EDSS	3.17 (.98)	3.92 (1.37)	–

MS, multiple sclerosis; RR, relapsing-remitting; SP, secondary-progressive.

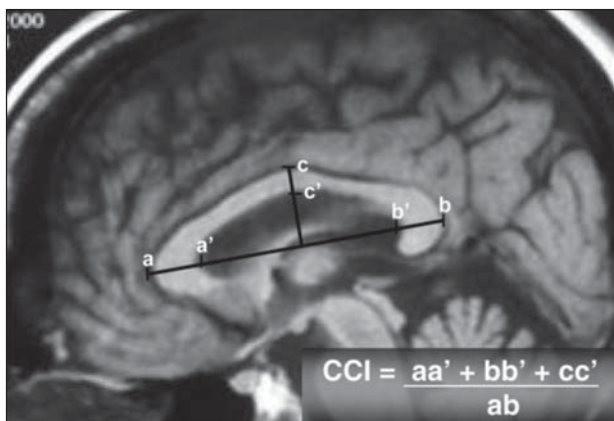


Fig 1. Determination of corpus callosum index, using a "best" midsagittal slice on a T1W brain MRI.

measured and normalized to its greatest anteroposterior diameter (ab). Studies were done at baseline and yearly, and results plotted intra-individually for follow-up, matched to baseline values used as a reference standard<sup>15</sup>. For comparison and validation purposes only, at the beginning of follow-up we obtained brain parenchymal fraction in all exams, using methodology previously described<sup>7</sup>.

*Clinical evaluation* – After a complete baseline study and final diagnosis of MS, patients were introduced to our treatment center standard protocol, with an every three-month routine clinical follow-up, including disability estimates by expanded disability status scale (EDSS)<sup>16</sup>, done at each consultation. A brief neuropsychological test battery, described elsewhere<sup>9</sup>, including memory, verbal fluency, depression task and a paced auditory serial addition

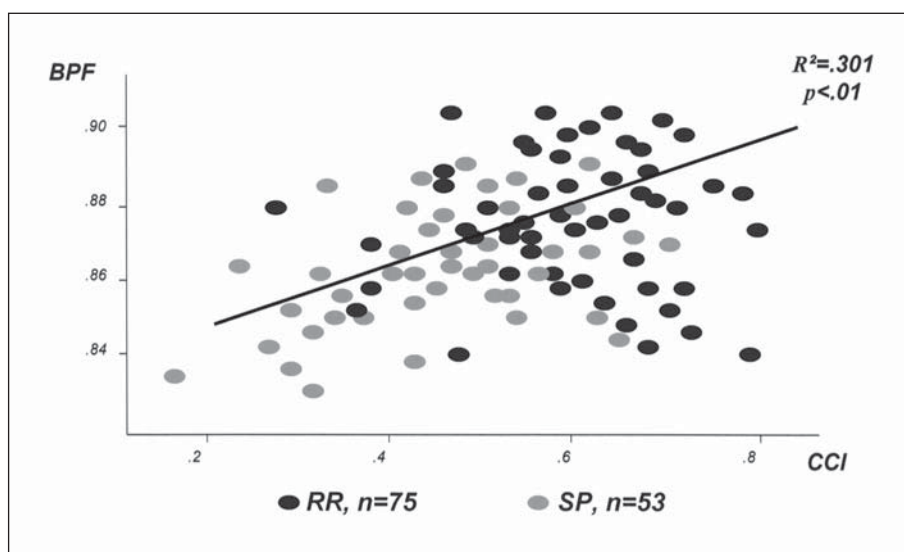


Fig 2. Correlation of corpus callosum index and brain parenchymal fraction, at baseline of the study.

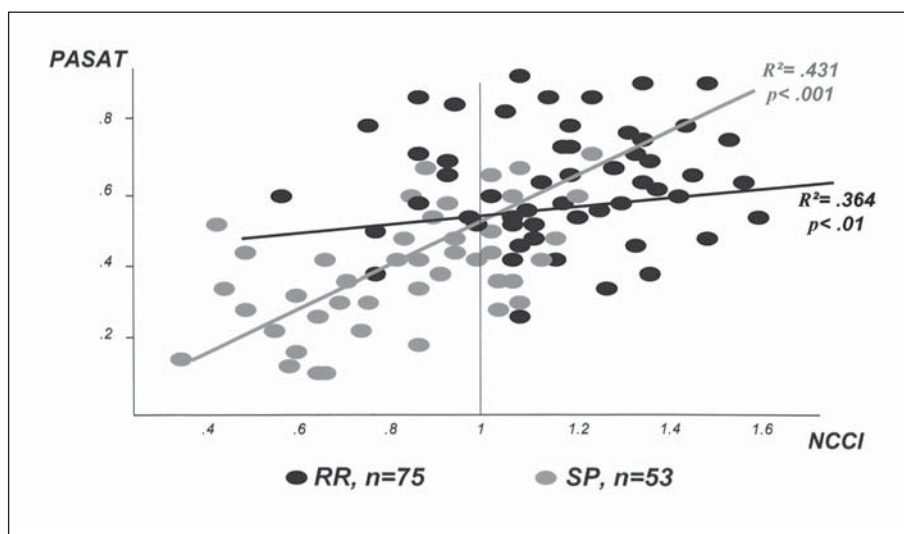


Fig 3. Correlation normalized corpus callosum index and PASAT scores, at baseline of the study.

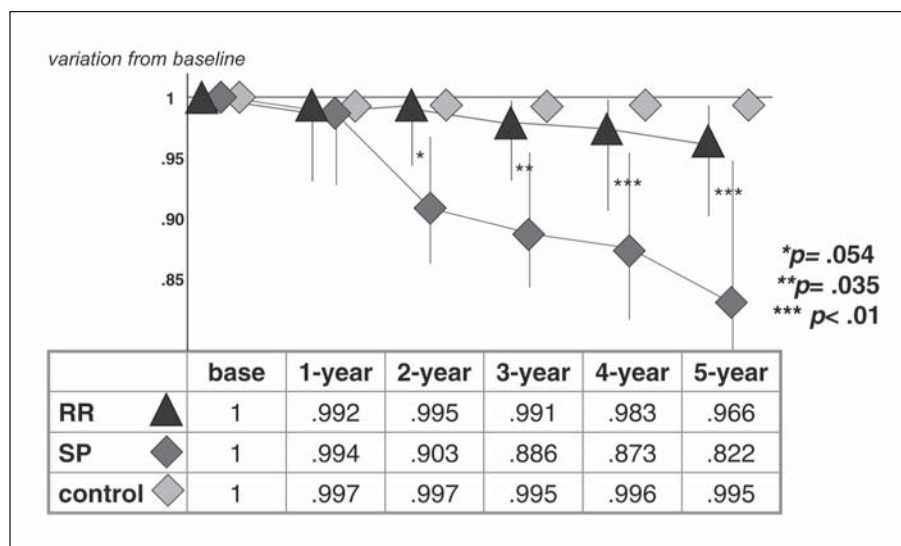


Fig 4. Corpus callosum index variations from baseline scores, over time.

test (PASAT), with rounds of 3, 2.5 and 2 seconds interval, was applied as part of baseline evaluation, always by the same examiner (AS). Scoring on PASAT was obtained by arithmetical mean of the decimal fraction number of correct answers at each round.

**Statistical analysis** – Demographic data values are presented as mean ± standard deviation (SD). Comparison of categorical variables was assessed by Pearson chi-square or the Fisher exact test, as appropriate. A p value of 0.05 or less was considered for statistical purposes of significance.

The study was designed to enroll patients on regular clinical follow-up and treatment. Protocol of the study was analyzed and approved by Ethical Committee of our Hospital and all patients intended to be involved gave informed consent to it.

## RESULTS

**Baseline** – On baseline, when compared to scores of a blind radiologist, CCI determination showed a interobserver disagreement of 0.92% (SD=.32; p=0.003)<sup>12</sup>. At this point, CCI was compared to brain parenchymal fraction (BPF) that, despite being too complicated to be used in daily practice is a widely accepted standardized measure for total brain atrophy (Fig 2). CCI showed a linear correlation with BPF on both groups of patients (R<sup>2</sup>=.301; p<.01), and was able to distinguish SP patients from RR and controls (p=.014 and p=.003, respectively)<sup>12</sup>. Then CCI was normalized to its mean value separately in RR and SP patient groups to study its correlation to PASAT, as a clinical scorer for speed of inter-hemispheric transfer of information, a function at least theoretically linked to callosal fiber integrity. Results showed a linear correlation between PASAT score and normalized CCI mea-

sure both on RR (R<sup>2</sup>=.364; p<.01) and SP (R<sup>2</sup>=.431; p<.001) groups of patients (Fig 3)<sup>12</sup>.

**Follow-up** – The sample was then prospectively followed for a 5-year period, and measures were taken at least yearly. There was a slow progressive reduction in mean CCI, observed on both group of MS patients, markedly in SP group, but also among RR patients, when compared to control. These scores were completely independent from EDSS. After 3 years, the difference between RR and SP patients scores reached statistical significance (p=.035), and after 5 years, there was a clear difference between the groups (p<.01), which was, still, independent of disability status rated by EDSS (Fig 4).

## DISCUSSION

As stated above, the progressive phase of MS is clinically marked by motor disability and cognitive dysfunction, resulting from axonal loss and brain atrophy. Most current tools for imaging and clinical follow-up rely on acute inflammation paradigm, as well as most end-points of pivotal immunomodulatory drug studies. Nevertheless, brain atrophy measures might prove to be important markers of disease progression, as they reflect the irreversible pathological process of cell damage<sup>17</sup>.

The aim of our present study is a search for a measure for follow-up of progressive MS patients, easy to be applied on a bedside basis, feasible to be reproduced by different observers, with some evidence of a clinical correlate to prove its anatomical and functional reliability.



Our present series is composed by 128 patients on regular treatment with any of the available immunomodulatory drugs and has a 5-year prospective ambulatory follow-up. Conventional brain MRI was obtained annually, as part of a routine treatment program. A simple, semi-automated index, that could also be manually obtained, was calculated from a best mid-sagittal T1W slice and showed a fair reproducibility on baseline, as matched to a scored examination of a blind expert radiologist. In spite of the low number of cases, CCI showed good anatomical and functional correlates. Anatomical correlate by matching to BPF, a well recognized and validated measure of whole brain atrophy, and functional by its linear relation to an also well validated cognitive functional measure, PASAT. At this point, CCI was sensitive enough to segregate RR from SP patients, despite the significant overlap between these two populations.

There was considerable overlap between groups, on follow-up, but inter-group CCI scoring analysis showed two distinctive patterns: a slowly progressive reduction, mostly among RR patients group, and a pronounced reduction, more common on SP patients. Initially a trend, after a 3-year follow-up this difference became statistically significant, allowing segregation between the groups.

More impressive information was obtained by intra-patient CCI scoring variation over time: a progressive reduction was observed on both groups, much more expressive among SP patients, from the early beginning of our study.

A particular group of 8 RR patients raises a very intriguing question as they showed what can be called a clinical-imaging mismatch: in spite of being clinically stable, with no relapses and no disability progression after a 5-year period, a relentlessly progressive callosal atrophy is evident, quite a similar behavior to SP patients. This small group might simply be on a transitional stage of the continuum between RR and SP phases. On the other hand, they may represent a "look beyond the clinics", anticipating at image what can be, later, expressed clinically as a progressive deterioration. In this last case, CCI could have a unique predictive value for evolution, impacting on prognosis and treatment strategies. We hope that the long-term follow-up of these patients would help answer these questions.

In conclusion, current paradigms for optimizing primary care in MS patients emphasizes not only reduction of inflammation, leading to a reduction in relapses rate and MRI activity, but also a long-term effi-

cacy, impacting on disability scores, cognitive changes and brain atrophy. Acute changes are widely accessed by conventional MRI while cell loss and brain atrophy, leading to more discrete and insidious changes, are frequently dismissed. Two-dimensional methods for assessing brain atrophy in MS, either by linear or area measures are easy to be obtained and proved very sensitive to longitudinal changes<sup>8</sup>. Otherwise, it seems reasonable to conclude that, in some way, any imaging protocol for long-term follow-up in MS should recommend the inclusion of at least one standardized brain atrophy scoring. In spite of the cross-sectional design of our study, the CCI was practical, with no sophisticated software requirements, and quite sensitive to callosal atrophy. So, it proved to have a potential to be used on long-term follow-up for patients with MS.

**Acknowledgement** – The authors wish to thank Miss Raquel Figueira, B. Biol., for revising the manuscript.

## REFERENCES

1. Lublin FD. Clinical features and diagnosis of multiple sclerosis. *Neurol Clin* 2005;23:1-15.
2. Lassmann H, Bruck W, Lucchinetti C. Heterogeneity of multiple sclerosis pathogenesis: implications for diagnosis and therapy. *Trends Mol Med* 2001;7:115-121.
3. Prineas J. Pathology of multiple sclerosis. In Cook S (Ed.). *Handbook of multiple sclerosis*. Basel: Marcel Dekker, 2001:289-324.
4. Bjartmar C, Trapp BD. Axonal and neuronal degeneration in multiple sclerosis: mechanisms and functional consequences. *Curr Opin Neurol* 2001;14:271-278.
5. Bjartmar C, Wujek JR, Trapp BD. Axonal loss in the pathology of multiple sclerosis: consequences for understanding the progressive phase of the disease. *J Neurol Sci* 2003;206:165-171.
6. Bakshi R, Dmochowski J, Shaikh ZA, Jacobs L. Gray matter T2 hypointensity is related to plaques and atrophy in the brains of multiple sclerosis patients. *J Neurol Sci* 2001;185:19-26.
7. Rudick RA, Fisher E, Lee JC, Simon J, Jacobs L. Use of the brain parenchymal fraction to measure whole brain atrophy in relapsing-remitting multiple sclerosis. Multiple Sclerosis Collaborative Research Group. *Neurology* 1999;53:1698-1704.
8. Bakshi R, Dandamudi, VSR, Neema M, De C, Bermel RA. Measurement of brain and spinal cord atrophy by magnetic resonance imaging as a tool to monitor multiple sclerosis. *J Neuroimaging* 2005;15(Suppl):S30-S45.
9. Figueira F, Santos VS, Silva FC. A cognitive imaging correlate in multiple sclerosis. *Rev Chil Neuropsiquiatr* 2003;41:86-87.
10. Witelson SF. Hand and sex differences in the isthmus and genu of the human corpus callosum: a postmortem morphological study. *Brain* 1989; 112:799-835.
11. Hofer S, Frahma J. Topography of the human corpus callosum revisited. Comprehensive fiber tractography using diffusion tensor magnetic resonance imaging. *NeuroImage* 2006;32:989-994.
12. Figueira F, Santos VS, Silva FC, Silva ACM. Corpus callosum index: a practical measure for long-term follow-up in multiple sclerosis. *Neurology* 2006;66:S10.006, A75.
13. McDonald WI, Compston A, Edan G, and the International Panel. Recommended diagnostic criteria for multiple sclerosis: guidelines from the International Panel on the Diagnosis of Multiple Sclerosis. *Ann Neurol* 2001;50:121-127.
14. Consortium of Multiple Sclerosis Centers. Available at <http://www.ms-care.org/>. June 2003.
15. Figueira F, Santos VS, Silva FC, Silva ACM. Corpus callosum index: a prospective study on progressive MS. *Arq Neuropsiquiatr* 2006;64(Suppl):S164-P552.
16. Kurtzke JF. Rating neurological impairment in multiple sclerosis: an Expanded Disability Status Scale (EDSS). *Neurology* 1983;33:1444-1452.
17. Simon JH, Jacobs LD, Campion MK, and The Multiple Sclerosis Collaborative Research Group (MSSCRG). A longitudinal study of brain atrophy in relapsing multiple sclerosis. *Neurology*, 1999;53:139-148.