

# MENINGIOMAS OF PINEAL REGION IN CHILDREN

Hamilton Matushita<sup>1</sup>, Fernando Campos Pinto<sup>2</sup>, José Píndaro Pereira Plese<sup>3</sup>

**ABSTRACT** - Meningiomas are uncommon tumors in children and either more rarely encountered in the pineal region. We report two cases of meningioma of the pineal region in children. One of these cases was a five years-old girl and the other a one year-old boy. No specific clinical presentation or tomographic examinations findings was identified before treatment, suggestive of a diagnosis of meningioma. The clinical and laboratory features were very similar to the most common tumors of the pineal region. Prior to the surgery, the histology of these tumors was not suspected. Both patients underwent direct surgery and complete removal was achieved by a suboccipital transtentorial approach. The tumors originated from velum interpositum in both cases. At the follow up, one case presented with recurrence six years later, and she underwent a reoperation with total resection without morbidity. Long-term follow up presented no other recurrences.

**KEY WORDS:** meningiomas, meningeal neoplasms, pineal tumors, velum interpositum, falcotentorial junction, children.

## Meningiomas da região da pineal em crianças

**RESUMO** - Meningiomas são tumores poucos frequentes em crianças, e mais raramente encontrados na região da pineal. Relatamos dois casos de meningioma da região da pineal em crianças, uma menina de cinco anos e um menino de um ano de idade. Não foi identificada nenhuma forma de apresentação clínica ou característica tomográfica, antes do tratamento, que sugerisse o diagnóstico de meningioma. As características clínicas e laboratoriais encontradas foram similares às de tumores mais frequentes da região da pineal. Ambos os pacientes foram submetidos ao tratamento cirúrgico e a remoção completa foi obtida por abordagem suboccipital transtentorial. Durante o seguimento, um dos pacientes foi reoperado por recorrência do tumor seis anos após o tratamento inicial. Atualmente, os pacientes encontram-se livres de recorrência tumoral.

**PALAVRAS-CHAVE:** meningioma, neoplasia meníngea, velum interpositum, junção falcotentorial, crianças.

Literature specifically concerning to meningioma of the pineal region in children is scarce. Meningiomas are relatively common tumors in adults and account for approximately 20% of all intracranial tumors<sup>1</sup>. Their incidence ranges from 1.1% to 4.2% of all intracranial tumor in pediatric age and in this corresponds to a proportion varying from 2,8% to 5,9% of meningiomas in all ages<sup>2,3</sup>. Meningiomas in children predominate during the second decade and are extremely uncommon in infancy. In children, meningiomas appear in unusual sites and usually reach enormous sizes, and locations that are rare in adults<sup>2,3</sup>. Meningiomas in the pineal region may originate either from the velum interpositum or from the falcotentorial junction.

We are describing our experience with two cases of meningiomas in the pineal region in children arising within the velum interpositum, with no dural attachment. Lack of dural attachment is one of

the clinical characteristics of meningiomas in children: around 36% are not dural-based tumors<sup>2,3</sup>.

## CASES

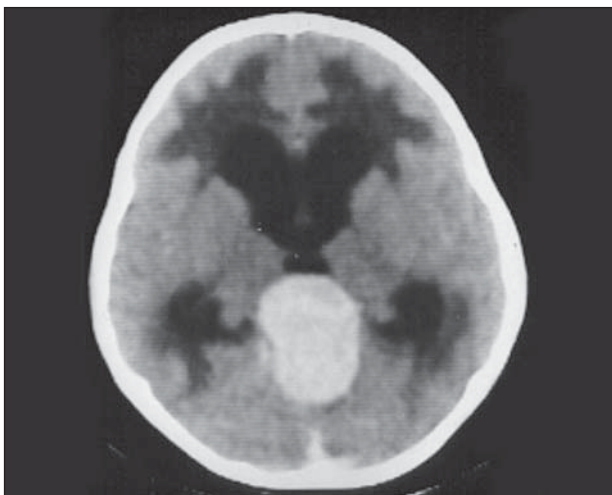
**Case 1** – A 5 years-old girl presented to our hospital in March 1985, with a 1 year history of occasional episodes of vomiting and progressive weakness of her right arm and leg. Her mother had observed that the child had shown some irritability during the past year. Two weeks before admission, her relatives had noted an increase in pubic and axillary hairs.

On examination, the child was calm, cooperative and oriented, with episodes of spontaneous weeping. She demonstrated increased pubic and axillary hairness, but without others signs of virilization. Fundus examination revealed bilateral papilledema. Her stance was unsteady, with evidence of hemiparetic spastic gait. She had global cerebellar and bilateral pyramidal syndrome. Plain skull radiographs revealed sutural diastasis and no calcification. Dosage of tumor markers (alpha fetoprotein (AFP) and beta subunit of human chorionic gonadotropin (HCG) in serum were negative. Ra-

Pediatric Neurosurgery, Division of Neurosurgery, São Paulo University School of Medicine, São Paulo SP, Brazil: <sup>1</sup>Chief of Pediatric Neurosurgery Unit; <sup>2</sup>Staff Member of Pediatric Neurosurgery; <sup>3</sup>Associated Professor of Neurosurgery.

Received 26 February 2007, received in final form 30 May 2007. Accepted 31 July 2007.

Dr. Hamilton Matushita - Rua Barata Ribeiro 237 / 43/44/46 - 01308-000 São Paulo SP - Brasil. E-mail: neurosp@uol.com.br



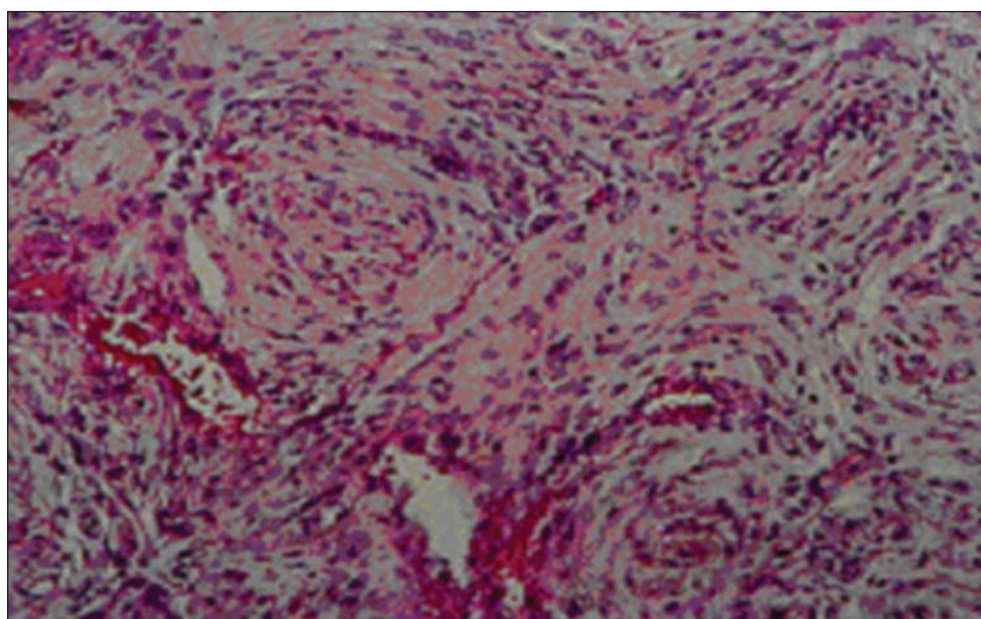
*Fig 1. Case 1. Axial preoperative CT with contrast enhancement shows a round and well delineated mass, with high and homogeneous density, at the pineal region. The lesion is compressing the posterior part of the III ventricle. No peritumoral edema is demonstrated. Sign of acute obstructive hydrocephalus is present.*

diologic bone age was 6 years. Computed tomography (CT) showed a well-defined mass of slightly greater density than the surrounding brain, and uniform enhancement of the tumor was achieved with contrast injection. The tumor occupied the pineal region and compressed the posterior portion of the III ventricle. Marked ventricular enlargement was present (Fig 1). Abdominal ultrasonography study was normal (no suprarenal and ovary lesions were detected). Germi-noma was thought to be the most likely diagnosis.

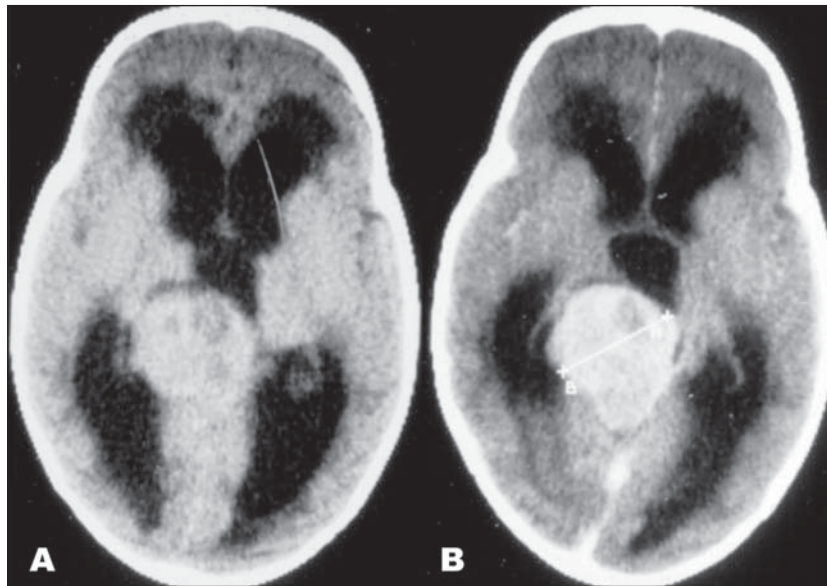
Surgery was performed with the patient positioned in the "three-quarter prone" with the side-down position to minimize retraction of the occipital lobe.

A large and encapsulated mass, with smooth surface , was completely removed through a high occipital craniotomy and occipital transtentorial approach. There was no attachment of the tumor to the dura-mater of the tentorium, but the tumor was displacing the inferior portion of the tentorium, the posterior half of the internal cerebral veins, and the inferior surface of the great vein of Galen. The tumor appeared to originate from the velum interpositum. It was necessary to occlude the precentral mesencephalic veins due to tumor involvement. The basal vein of Rosenthal on the right side needed to be occluded because of bleeding during dissection of the tumor at the proximal portion of the vein, close to the great vein of Galen, while removing the last and small remaining portion of the tumor. The tumor did not invade or occlude the straight venous sinus. Complete macroscopic removal was achieved (Simpson Scale I). The neurological status improved, with gradual disappearance of the right hemiparesis and mental alteration. Histologic examination of the tumor revealed a fibroblastic type of meningioma (Fig 2). The child was discharged on the seventh post- operative day. After 6 years follow-up, a routine CT demonstrated a recurrence of the tumor, which was completely removed with no morbidity. Presently, the patient leads a normal life.

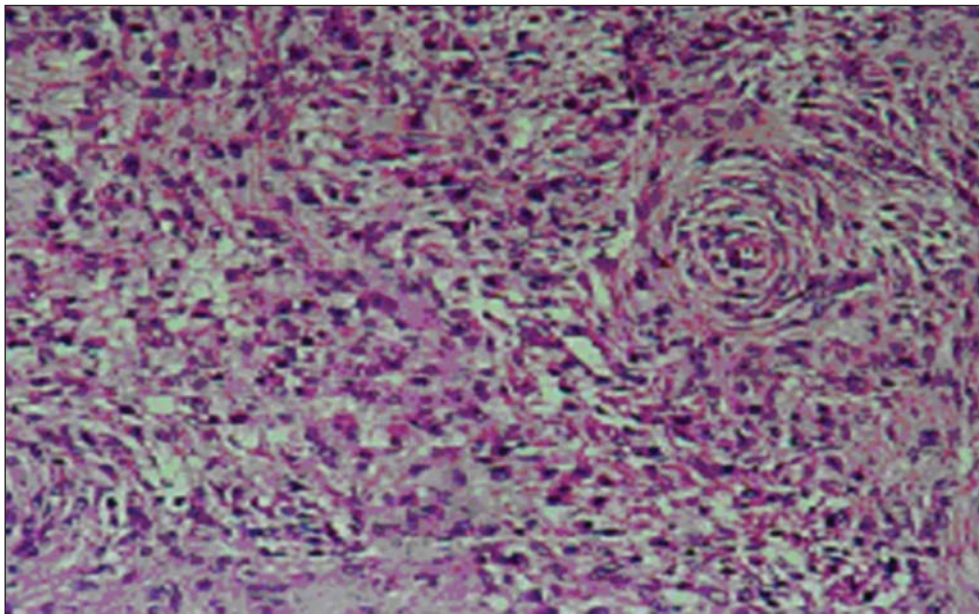
Case 2 – A 13 month-old boy was admitted to another hospital in December 1987 with history of fall at home and minor head trauma. After this accident the child became drowsy, developed vomiting, convergent strabismus and two episodes of generalized tonic-clonic seizures. On examination he had no signs of external head injury. Skull X ray was normal, however, CT revealed enlargement of laterals and III ventricles with a round, well-defined and high density mass in the pineal region, that enhanced homogeneously after injection of contrast (Figs 3A and 3B). The tumor was slightly lateralized to the right, compress-



*Fig 2. Case 1. Histological features of fibroblastic meningioma.*



*Fig 3. (A) Unenhanced CT scan reveals a round and slight high density lesion at the pineal region, compressing the posterior part of the III ventricle and the right pulvinar of the right thalamus. No peritumoral edema was seen. Ventricular dilatation and transependymal edema is demonstrated. (B) The tumor is markedly enhanced with contrast medium. Tumor size was 48 mm at the diameter indicated in the figure.*



*Fig 4. Case 2. Histological features of transitional meningioma.*

ing the posterior portion of the III ventricles and the pulvinar thalamus on the right. In retrospect, his mother denied any abnormality with the child, he was feeding well, and his neurodevelopmental milestones were adequate. On January 8<sup>th</sup> 1988, he underwent a frontal ventriculoperitoneal (VP) shunt, with improvement of the level of consciousness and strabismus.

A week later he was referred to our hospital. On examination he was alert and easily excited to stimuli. Occipito-

frontal circumference was 51 cm (above 98%). The VP shunt was working well, and the anterior fontanel was flat. Fundus examination demonstrated bilateral papilledema. The child had global cerebellar syndrome, pyramidal bilateral signs (hyperreflexia, and Babinski sign), and paralysis of upward conjugate gaze. The child was not walking and his language development was normal. Dosage of tumor markers (AFP and HCG in serum and CSF) was negative. Based on clinical data, neuroradiological examination findings, and

negative tumor markers, the tumor was presumed to be germinoma, pineocytoma, or neuroepithelial tumors.

The patient was operated on the "three-quarters prone" side-down position, through a right occipital craniotomy and suboccipital transtentorial approach. Complete tumor removal was achieved (Simpson Scale I). The tumor was relatively soft, mildly vascular, well circumscribed, encapsulated, with expansion to the III ventricle and posterior fossa, and no attachment of the tumor either to the dura-mater or the veins of the region was observed. After debulking the tumor, and dissecting it away from the deep venous system, it was found that the tumor had an attachment to the tela choroidea on the right side. Only the precentral-cerebellar vein was cauterized and divided during tumor removal without consequences. In the postoperative period the child developed a superficial infection of the scalp with no further complications. He was discharged on February 1988, neurologically intact.

Histological examination demonstrated transitional type meningioma (Fig 4). Follow up course of thirteen years, has shown no recurrence and he has done very well at school during all these years.

## DISCUSSION

*Diagnosis* – Recognition of meningioma among other tumors of the pineal region, despite advances in radiographic imaging, still remains unreliable. The majority of pineal region tumors occur during childhood and adolescence; on the contrary, meningiomas clearly predominate in adults over 40 years of age<sup>4,5</sup>. Additionally, many histological types of tumors arise in the pineal region; more than 17 histologically distinct tumor types have been recognized<sup>6,7</sup>. The most frequent tumors are germ cells tumors, pineal parenchymal tumors, and astrocytomas<sup>4,5</sup>. Other types of tumors are less frequently observed. Meningiomas of the pineal region are extremely rare, especially in children. The incidence of meningiomas varies from 0.5% to 10.1% of all tumors in the pineal region<sup>7</sup>, and of these, only about 8.1% correspond to children<sup>8</sup>. Similar to all other meningiomas, those located in the pineal region predominate in female adults with a mean age of 39.3 years<sup>8</sup>.

Meningiomas may originate at the pineal region, either from the falcotentorial junction or from the velum interpositum. Falcotentorial meningiomas are more frequent than the ones originating from the velum interpositum<sup>8,9</sup>, even though they may constitute less than 1% of all meningiomas<sup>10</sup>. Meningiomas arising from the falcotentorial junction may demonstrate a different direction of growing and according to the extension; they may masquerade a pineal tumor<sup>11</sup>. A review of the literature by Quinones-Hinojosa et al.<sup>12</sup> found fewer than 50 cases of meningiomas of the falcotentorial junction. Typically these tumors also

occur in adults with mean age of 42 years. Only one case of falcotentorial meningioma, a chordoid meningioma, occurring in a child of 15 years was found in the literature<sup>13</sup>. Regarding meningiomas originating from velum interpositum, a review of the literature by Lozier and Bruce<sup>14</sup> collected only 27 cases. These meningiomas, like others, occur mainly in adults, with a presentation mean age of 32.6±19.7 years<sup>14</sup>. Out of 27 cases, only four were reported in children less than 14 years of age. Owing to the rarity of meningioma at the pineal region in children, and relatively higher incidence of germ cell tumors of the pineal region, during the first two decade of life, meningiomas are usually not considered at the first diagnosis.

With very few exceptions, no clinical features can identify a specific tumor type at the pineal region. Usually these tumors present with increased intracranial pressure due to obstruction of CSF drainage, and compression of the mencephalic tectal plate. Although benign tumors usually have a more insidious history these are not specific of meningiomas of the pineal region<sup>10</sup>. Meningiomas of the pineal region may produce a rapid onset of symptoms related to aqueductal obstruction. When anterior, meningiomas from the velum interpositum, tend to occupy the III ventricle, causing obstruction of CSF at the Monro foramen. Posterior meningiomas grow to the pineal region, and compress the quadrigeminal plate, as do all pineal region tumors, and causing obstruction of the aqueduct of Sylvius giving rise to a rapid onset of symptoms. Meningiomas originating from the falcotentorial junction with inferior extension more frequently masquerade, clinically and radiologically, other pineal tumors<sup>11</sup>.

Endocrinological disturbances, as present in our case 1, were unexpected and it was a disorienting point in the diagnosis, since virilization is more related to germ cell tumors, especially choriocarcinoma<sup>15</sup>. Kitay<sup>16</sup> observed that nonparenchymal tumors were three times as likely to produce precocious puberty, as were parenchymal tumors. Neuroophthamologic alterations (impairment of upperward gaze, abnormality of pupils, paralysis or spasm of convergence, and nistagmus retractoris, and upper conjugate palsy) caused by compression of the mesencephalon, is very typical of this region, although not so frequent in children<sup>17</sup>. Patients with meningiomas of pineal region present with only 11% with ocular disturbances<sup>9</sup>.

Currently, the differential diagnosis of pineal tumor is based mainly on CT and MRI. No CT features can be found to differentiate pineal region tumors.

CT is useful in detecting intracranial tumours, but the definite diagnoses depend on the histological examination and /or detection of tumor markers either in the serum or cerebral spinal fluid. Although the tomographic features of pineal tumors are useful in elaboration of presumptive diagnosis, they are not pathognomonic. CT scanning of pineal tumors shows various lesions with almost identical appearance. Many reports address this subject (describing the reliability of the CT) and conclude that although the CT findings are characteristics, the precise diagnosis is not<sup>18</sup>. The majority of tumors of pineal region appear as round mass, well defined, iso or high-density lesion, with homogeneous enhancement after contrast infusion. The CT imaging features of germinomas, pineocytomas e even malignant tumors are very similar to the meningiomas<sup>18,19</sup>. Meningiomas of the pineal region, like many other tumors, present on the CT as a round mild hyperdense lesion, with homogeneous contrast enhancement<sup>20,21</sup>. Lack of surrounding oedema and tentorial attachment are common features of meningiomas of the pineal region<sup>22</sup>. The presence of calcification varies and depends on the type of tumor. Calcification in meningiomas is relatively higher in children than in adults, but the incidence of calcification in pineal region tumors, particularly in pineal parenchyma tumors and germinomas are high<sup>20,23</sup>. Finally, it is usually not possible to make a preoperative diagnosis of a specific histological variety of tumour based on CT characteristics alone.

MRI offers superior anatomical details of tumors over CT scanning, but it has had no advantage in pathological differentiation of tumors of pineal region<sup>21,24</sup>. MRI permits multiple planes for reconstructing the lesion; particularly coronal sections may be useful in detecting the adherence of the meningioma to the tentorium<sup>25</sup>. No enough information is available yet to correlate signal characteristics with histology. Meningiomas of the pineal region are identified as: a round, well-defined, homogenous, isointense or slightly hyperintense on T1-weighted images; tumors displacing the surrounding structures without invasion; tumors with no surrounding oedema of the white matter; and tumors with homogeneous and slight contrast enhancement<sup>21,24,25</sup>. Even all these patterns may be inconsistent<sup>11</sup>. Dural enhancement in case of falcotentorial meningioma may be present, although this feature is not specific to the meningioma<sup>10,26</sup>. The so-called "tail-signs" has not been associated only with meningioma of the pineal region<sup>21,27</sup>. Relationship between the pineal region tumors and adjacent structures may indicate the histological type of the

tumor. Attachments of the meningiomas to the dura mater at the falcotentorial junction, the tela choroidea in the velum interpositum of the third ventricle or the connective tissues of the pineal gland may be clearly delineated on MRI<sup>26</sup>. Posterior compression of the corpus calosum or anterior displacement of the pineal gland may also indicate a meningioma<sup>26,28</sup>.

Angiography may identify meningioma of falcotentorial origin, revealing a homogeneous stain in the capillary phase and feeding by varied arterial supply: tentorial arteries, meningeal branches of the external carotid artery, and choroidal branches or the posterior cerebral artery<sup>10</sup>. Tumor stain although present in the meningiomas this feature is not specific of this tumor<sup>28</sup>. The most important angiographic feature that permits differentiation between meningiomas of falcotentorial region and other pineal tumors is the direction of displacement of the medial choroidal artery. Although the vascular supply to these tumors may derive from different sources, this may be characteristic when the meningo-hypophysial arteries, branch of the internal carotid artery, feeds them<sup>10,11</sup>. Angiography, although is not done routinely in the work up of pineal tumors, may identify meningiomas of pineal region that originate from the falcotentorial region.

Suspicion of meningioma in the pineal region in children is not frequent, because meningiomas are typically tumors of adults, and their extremely rarity at the pineal region. Their imaging features and clinical presentation usually are common to others pineal tumors. Furthermore, angiography study is not routinely recommended in the work up of a child with pineal region tumor.

As certainty of tumor histology is quite impossible in large majority of pineal region tumors, biopsy may be done, by stereotactic or by endoscopy. Biopsy, before the initiation of therapy has been recommended in the more recent literature. In present time, neuroendoscopic approach has been proposed as the first choice in the strategy to achieve the specific diagnosis of pineal region tumours<sup>29</sup>. Neuroendoscopic approach affords a minimally invasive way to treat obstructive hydrocephalus by third ventriculostomy and obtain biopsy specimens and tissue diagnosis.

*Treatment* – Meningiomas of the pineal region are usually treated according to the strategy of all pineal tumors. The use of standard pineal approaches; the occipital transtentorial and supracerebellar infratentorial, depends on the extension of the tumor, and the surgeon's familiarity. There still controversy regarding the best approach to the pineal region. How-

ever, different approaches are required according to the displacement of the great vessels of the pineal region<sup>10</sup>. Meningiomas of the falcotentorial junction with dorsal extension and meningiomas arising from the dorsal leaf of the tela choroidea, displace the great venous vessel inferiorly, are best approached via the posterior interhemispheric corridor<sup>10,13</sup>. The most used surgical approach to remove the meningiomas of falcotentorial junction is the occipital transtentorial approach due to its wide operative field, and additional opening of the posterior falx allows a window to the contralateral side<sup>10</sup>.

Ressectability of meningiomas depends upon the adherence to the vascular structure; deep veins and venous sinus. The deep Galenic system and the anterior part of the straight sinus offer the challenge to remove this tumors totally. Occlusion of both the vein of Galen or the straight and sagittal sinus by the tumors are very frequent<sup>10,11,29-31</sup>. Previous knowledge about the collateral venous drainage is very important to avoid complications. Many combination of collateral may develop, but the most important are: from the basal vein of Rosenthal through the lateral mesencephalic and anterior pontomesencephalic vein to the petrosal vein, and from the galenic system through the internal cerebral vein or enlarged veins on the medial surface of the parietal or occipital lobes<sup>10</sup>.

It is controversial the results of interruption of the Galen system. It must be considered according to the development of collaterals of the deep venous system, and occlusion of a functional venous system, in general, is not recommended, and every effort should be made to keep these vessel and the collaterals without injury<sup>10,32</sup>. Total resections of meningiomas of the velum interpositum seem to be easier than those of falcotentorial junction due to its invasive characteristic in the tentorium or venous sinus of the latter one.

Velum interpositum is the double-layered tela choroidea of the third ventricle, and it results from the overlapping of the third ventricle by the prosencephalon. The velum interpositum is the origin of the arachnoid cells from which meningiomas arise<sup>13</sup>. The internal cerebral veins are located inside the cavum velum interpositum, between the ventral and dorsal tela choroidea. Meningiomas arising from the ventral tela choroidea displace the internal cerebral veins dorsally, and those tumors arising from the dorsal tela choroidea displace the internal cerebral veins ventrally into the third ventricle or to the quadrigeminal cistern. Meningiomas arising from the velum interpositum rarely involve and occlude the deep venous system,

more commonly; the internal cerebral veins are adherent to, but not incorporate into the tumor capsule<sup>13</sup>. Based on 17 cases reviewed by Lozier and Bruce<sup>13</sup> gross total resection was achieved in 13 patients, with operative mortality of two cases (2/17=5.8%).

The long term prognosis for surgically treated meningiomas in children is controversial, but according to the conclusion from the most recent and largest review about intracranial meningiomas in children, made by Caroli et al. in 2006<sup>33</sup>, who collected 440 cases reported in the literature, children like adults, with typical meningiomas and complete resections show good outcome.

Our cases are leading normal live with no recurrence with more than 10 years follow-up.

In conclusion, meningioma of the pineal region is very difficult to be suspected preoperatively. It is a rare tumor in children, and in the pineal group tumor other histologic type of tumor are more predominant. Differential diagnoses criterias based on clinical presentations, imaging findings, and tumors markers of pineal region tumors can identify only a minority of tumors. Regarding meningiomas, only those originated from the falcotentorial junction can offer some clues of its pathology. Meningiomas, although rare, should be considered in the differential diagnosis of the pineal region tumors.

It seems that, in children, meningiomas arising from velum interpositum, with no dural attachment, are more prevalent than those arising from the falcotentorial junction.

## REFERENCES

- Walker AE, Robins H, Wienfield FD. Epidemiology of brain tumors: the national survey of intracranial neoplasms. *Neurology* 1985;32:219-226.
- Drake JM, Hoffman HJ. Meningiomas in children. New York: Raven Press, 1991:145-152.
- Rushing EJ, Olsen C, Mena H, et al. Central nervous system meningiomas in the first two decades of life: a clinicopathological analysis of 87 patients. *J Neurosurg* 2005;103(Suppl Pediatrics):489-495.
- Nomura K, Yoshida J. Epidemiology of germ cell tumors in Asia of pineal region tumor. *J Neurooncol* 2001;54:211-217.
- Edwards MCB, Hudgins RF, Wilson CB, Levin V, Wara WM. Pineal region tumors in children. *J Neurosurg* 1988;68:689-697.
- Herrick MK. Pathology of pineal tumors. Baltimore: Williams & Wilkins, 1984:31-60.
- Chandy MJ, Damaraju SC. Benign tumours of the pineal region: a prospective study from 1983 to 1997. *Br J Neurosurg* 1998;12:228-233.
- Piatt JH Jr, Campbell GA. Pineal region meningioma: report of two cases and literature review. *Neurosurgery* 1983;12:369-376.
- Sach E Jr, Avman N, Fisher RG. Meningiomas of pineal region and posterior part of 3rd ventricle. *J Neurosurg* 1962;19:325-331.
- Okami N, Kawamata T, Hori T, Takakura K. Surgical treatment of falcotentorial meningioma. *J Clin Neurosci* 2001;8:15-18.
- Asari S, Maehiro T, Tomita S, et al. Meningiomas arising from the falcotentorial junction. Clinical features, neuroimaging studies, and surgical treatment. *J Neurosurg* 1995;82:726-738.
- Quinones-Hinojosa A, Chang EF, McDermott MW. Falcotentorial meningiomas: clinical, neuroimaging, and surgical features in six patients. *Neurosurg Focus* 2003;14:1-7.

13. Kobata H, Kondo A, Iwasaki K, Kusaka H, Ito H, Sawada S. Choroid meningioma in a child. Case report. *J Neurosurg* 1998;88:319-323.
14. Lozier AP, Bruce JN. Meningiomas of the velum interpositum: surgical considerations. *Neurosurg Focus* 2003;15:E11.
15. Chan HS, Humphrey RP, Hendrick B, Chuang SH, Fitz CR, Becker LE. Primary intracranial choriocarcinoma: a report of two cases and review of the literature. *Neurosurgery* 1984;15:540-545.
16. Kitay JI. Pineal lesions and precocious puberty: a review. *J Clin Endocrinol Metab* 1954;14:622-625.
17. Rozario R, Adelman L, Prager RJ, Stein B. Meningiomas of the pineal region and third ventricle. *Neurosurgery* 1979;5:489-495.
18. Chang T, Teng MMH, Guo WY, Sheng WC. CT of pineal tumors and intracranial germ-cell tumors. *AJNR* 1989;10:1039-1044.
19. Wood JH, Zimmerman RA, Bruce DA, Bilaniuk LT, Norris DG, Schut L. Assessment and management of pineal region and related tumors. *Surg Neurol* 1981;16:192-210.
20. Konovalov AN, Spallone A, Pitzkhelauri DI. Meningioma of the pineal region: a surgical serie of 10 cases. *J Neurosurg* 1996;85:586-590.
21. Tien RD, Barkovich AJ, Edwards MSB. MR Imaging of pineal tumors *AJNR* 1990;11:557-565.
22. Roda JM, Perez-Hyus A, Olivier B, Alvarez MD, Blasquez MG. Pineal region meningiomas without dural attachment. *Surg Neurol* 1982;17:147-151.
23. Chang CG, Kageyama N, Kobayashi T, Yoshida J, Neguro M. Pineal tumors: clinical diagnosis with special emphasis on the significance of pineal calcification. *Neurosurg* 1981;8:656-668.
24. Muller-Forel W, Schroth G, Egan PJ, Chandy MJ, Damaraju SC. MR imaging in tumors of the benign tumours of the pineal region: a prospective study from 1983 to 1997. *Br J Neurosurg* 1998;12:228-233.
25. Iplikcioglu AC, Bayar MA, Kokes F, et al. Pineal meningioma MRI. *Neuroradiology* 1993;35:539-540.
26. Satoh H, Uozumi T, Kiya K, Kurusi K, Arita S, Sumida M, Ikawa F. MRI of pineal region tumors; relationship between tumours and adjacent structures. *Neuroradiology* 1995; 37:624-630.
27. Gupta S, Gupta RK, Banerjee D, Gujral RB. Problems with the "dural tail" sign. *Neuroradiology* 1993;35:541-542.
28. Yamazaki T, Takajhashi S, Ishii K, et al. Meningioma in the pineal region: preoperative diagnosis with CT, MRI, an angiography. *Radiat Med* 1991; 9:22-25.
29. Goto T, Ohata K, Morino M, et al. Falcotentorial meningioma; surgical outcome in 14 patients. *J Neurosurg* 2006;104:47-53.
30. Otake G. Meningioma of the falcotentorial region: report of two cases and literature review of occlusion of the galenic system. *Neurosurgery* 1992;30:788-93.
31. Raco A, Agrillo A, Ruggieri A, Gagliardi FM, Cantore G. Surgical options in the management of falcotentorial meningiomas: report of 13 cases. *Surg Neurol* 2004;61:157-164.
32. Sakaki S, Shinishi T, Takeda S, Matsuoka K, Sakamoto K. Occlusion of the great vein of Galen associated with meningioma in the pineal region. *J Neurosurg* 1984;61:1136-1140.
33. Caroli E, Russillo M, Ferrante L. Intracranial meningiomas in children: report of 27 new cases and critical analysis of 440 cases reported in the literature. *J Child Neurol* 2006;21:331-36.