

HORNER'S SYNDROME AFTER BLUNT CERVICAL AND CHEST TRAUMA

Case report

Wellingson Silva Paiva¹, Robson Luis Oliveira De Amorim¹, Wagner Malago Tavares¹, Eduardo Joaquim Lopes Alho¹, Brasil Ping Jeng¹, Eberval Gadelha Figueiredo²

ABSTRACT - Horner's syndrome is the triad of miosis, ptosis, and anhidrosis, resulting from disruption of the sympathetic pathways. This article describes an uncommon case of Horner's syndrome in a 22-year-old man after blunt trauma to the neck and chest without carotid artery dissection. The patient was brought to the emergency service after motorcycle fall. Neurologic examination revealed a patient presenting the score 15 at Glasgow Coma Scale. The left eyelid was 1–2 mm lower than the right. Carotid Doppler and angiotomography were undertaken and revealed no abnormalities of the carotid artery. CT disclosed a mediastinal hematoma extending to the left apex, compressing the left sympathetic chain. The understanding of this clinical entity may help the surgeon to make a better differential diagnosis in trauma patients in whom prompt diagnosis is critical to establish the correct treatment.

KEY WORDS: Horner syndrome, trauma, etiology.

Síndrome de Horner após trauma cérvico-torácico fechado: relato de caso

RESUMO - A síndrome de Horner compreende a tríade de miose, ptose e anidrose, resultado de lesão em algum ponto das vias simpáticas. O referido estudo apresenta um caso da referida síndrome em um jovem de 22 anos vítima de queda de moto, com escoriações no tórax e no pescoço, sem dissecação carotídea. Ao exame neurológico, encontrava-se com 15 pontos na Escala de Coma de Glasgow, com miose à esquerda e ptose palpebral ipsilateral. Realizado Doppler de carótidas e angiotomografia dos vasos cérvico-cranianos não sendo evidenciadas anormalidades. A tomografia de tórax mostrou um hematoma no ápice pulmonar esquerdo, comprimindo a cadeia simpática ipsilateral. O conhecimento desta entidade clínica pode ajudar o cirurgião a fazer um diagnóstico diferencial adequado nos pacientes vítimas de traumas, nos quais o diagnóstico correto e eficaz pode ser fundamental para a definição da conduta a ser tomada.

PALAVRAS-CHAVE: síndrome de Horner, trauma, etiologia.

Horner's syndrome consists of a triad of symptoms (miosis, ptosis, and anhidrosis) resulting from disruption of the sympathetic pathways somewhere between the brain and the eyes. In blunt trauma, it is usually associated with carotid artery dissection. Although the individual signs of Horner's syndrome do not constitute an emergency, the internal carotid artery proximity to the sympathetic ganglia makes Horner's syndrome a potential vascular emergency¹⁻³.

We present a case of Horner's syndrome in a 22-year-old man after blunt trauma to the neck and head unrelated to carotid artery dissection.

CASE

A 22-year-old man was brought to the emergency room after motorcycle fall, with history of transitory loss of conscience. In the admission, he was alert and orientated, the carotid pulses were symmetric, regular in rate and rhythm, with no bruits and the chest and the abdomen had no signs of abnormalities. The patient related moderate cervical pain but no neurological deficits were noticed except for the asymmetric pupils that measured 5 mm on the right and 2 mm on the left side, both presenting direct and consensual reflexes. The left eyelid was 1–2 mm lower than the right (Fig 1), the extraocular movements were intact and the cranial nerve examination was normal. The chest X-ray did not re-

¹MD, Neurosurgery Resident Hospital das Clínicas University of São Paulo, São Paulo SP, Brazil; ²MD, Neurosurgeon, Chief of the Cerebrovascular Surgical Team Hospital das Clínicas University of São Paulo, São Paulo SP, Brazil;

Received 29 March 2007, received in final form 18 July 2007. Accepted 25 August 2007.

Dr. Wellingson Paiva - Rua Ovidio Pires de Campos, 171 / 511 - 05403-010 São Paulo SP - Brasil. E-mail: wellingsonpaiva@hotmail.com

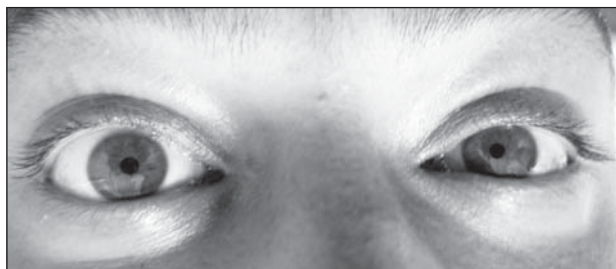

Fig 1. Assymmetric pupils and left semiptosis

veal any rib, sternal fractures or mediastinal enlargement. Skull computed tomography (CT) showed no abnormality so as the carotid ultrasonography Doppler and the angiography of the head and neck. Cervical spine CT showed a fracture of left C7 transverse process and additional investigation with chest CT disclosed a mediastinal hematoma extending to the left lung apex, exhibiting mass effect over surrounding structures without signs of aortic dissection (Fig 2). A conservative management was adopted and the patient left the hospital three days later but still with the neurologic signs. Follow up four weeks after discharge revealed a normal neurologic examination and no complaints.

DISCUSSION

Horner's syndrome is an uncommon occurrence in all age groups (0.08% of blunt trauma patients)². Diagnosis is namely based on clinical findings, and after careful history and examination, the physician must decide whether further investigation is necessary. There is a wide variety of conditions that may cause this syndrome, postsurgical and iatrogenic causes comprise most of the cases³⁻⁸. Penetrating neck injuries, cervical spine dislocation and birth trauma are the major factors that lead to traumatic injury to the oculosympathetic pathway^{7,9}. A history of trauma preceding these findings should prompt the clinician to consider that the carotid artery, which lies directly over the sympathetic chain in the neck, may have been injured, particularly if signs of head or neck trauma are present^{8,10,11}. The investigation of choice considered by some authors is a magnetic resonance imaging and angiography scan of the head and neck¹⁰. Therefore, to exclude carotid injury the authors performed an ultrasonography Doppler and an angiotomography what seems to be less invasive and with a high sensitivity. The carotid dissection diagnosis implies an emergent condition that can lead, if misdiagnosed, to major catastrophes including massive ischemic stroke, even in a patient with minor symptoms at admission¹¹.

In this current case further investigation showed a mediastinal and left lung apical hematoma which probably caused compression of the sympathetic gan-

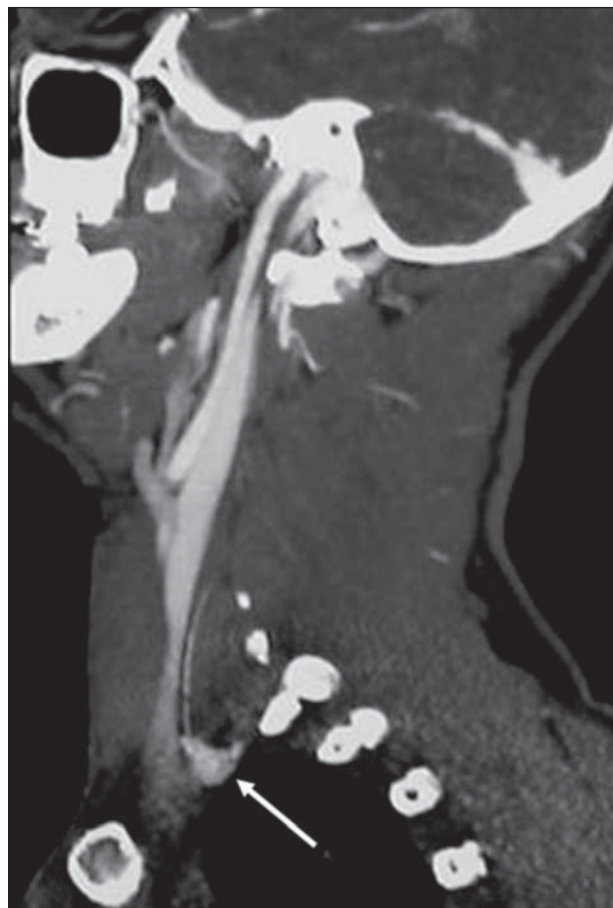


Fig 2. Chest CT scan revealing mediastinal hematoma extending to the left apex (white arrow).

glia, as the clinical findings appeared in first day of trauma. When it comes to blunt chest trauma, there is an association with fractures of the first rib^{7,9}, not seen in this patient. The fracture of the left C7 transverse process could explain the cervical pain, therefore, the correlation of this radiological finding with the hematoma can not be affirmed. Mediastinal hematoma due to trauma is associated with sternal fracture, aortic dissection and extrapericardial cardiac tamponade¹²⁻¹⁴. Before the era of multidetector helicoidal CT, performed in this patient, the gold standard to investigate aortic dissection was angiography¹⁴. Asensio-Sánchez et al.¹⁵, described a case of Horner's syndrome due to an hematoma in the neck which was producing tracheal deformity and stenosis. A chest hematoma causing such syndrome was described by Banks et al.¹⁶ and the signs were caused by a tension hemothorax, a life-threatening condition. In our case, the patient was hemodynamically stable and no surgical intervention was necessary. This report illustrates a condition that can be seen in the trauma emergency department and shows that a

meticulous and sequenced investigation with proper complementary exams is necessary because such signs can be just the "iceberg tip".

In conclusion, Horner's syndrome is a very rare condition after mild neck and chest trauma. The understanding of this clinical entity may help the surgeon to make a better differential diagnosis in trauma patients in whom correct and prompt diagnosis can be lifesaving.

REFERENCES

1. Rudolph A. Rudolph's pediatrics. 20.Ed. Stamford: Appleton & Lange, 1996:112-118
2. Davis JW, Holbrook TL, Hoyt DB, Mackersie RC, Field TO Jr, Shackford SR. Blunt carotid artery dissection: incidence, associated injuries, screening and treatment. *J Trauma* 1990;30:1514-1517.
3. Kaya SO, Liman ST, Bir LS, Yuncu G, Erbay HR. Unusual Horner's syndrome as a complication in thoracic surgical practice. *Eur J Cardiothorac Surg* 2003;24:1025-1028
4. Pearce SH, Rees CJ, Smith RH. Horner's syndrome: an unusual iatrogenic complication of pneumothorax. *Br J Clin Pract* 1995;49:48.
5. Shen SY, Liang BC. Horner's syndrome following chest drain migration in the treatment of pneumothorax. *Eye* 2003;17:785-788.
6. Campbell P, Neil T, Wake PN. Horner's syndrome caused by an intercostal chest drain. *Thorax* 1989;44:305-306.
7. Bell LR, Atweh N, Ivy M, Possenti P. Traumatic and iatrogenic Horner's syndrome: case report and review of the literature. *J Trauma* 2001;51:400-404.
8. Thanvi B, Munshi SK, Dawson SL, Robinson TG. Carotid and vertebral artery dissection syndromes. *Postgrad Med J* 2005;81:383-388.
9. Harris CJ, Soper RT. Pediatric first rib fractures. *J Trauma* 1990;30:343-345.
10. Chan CC, Paine M, O'Day. Carotid dissection: a common cause of Horner's syndrome. *J Clin Exp Ophthalmol* 2001;29:411-415.
11. Liu WP, Ng KC, Hung JJ. Carotid artery injury with cerebral infarction following head and neck blunt trauma: report of a case. *Yale J Biol Med* 2005;78:151-156.
12. Coleman GM, Fischer R, Fuentes F. Blunt chest trauma: extrapericardial cardiac tamponade by a mediastinal hematoma. *Chest* 1989;95:922-924.
13. Sia AT. Cardiac tamponade: an unlikely cause of unexplained hypotension in an isolated "minor" blunt chest injury. *Singapore Med J* 1997;38:35-36.
14. Geusens E, Pans S, Prinsloo J, Fourneau I. The widened mediastinum in trauma patients. *Eur J Emerg Med* 2005;12:179-184.
15. Asensio-Sánchez VM, Sánchez-Rodríguez JC, Macías-Pascual J, Martínez-Rodríguez M. Traumatic Horner's syndrome. *Arch Soc Esp Ophthalmol* 2007;82:171-173.
16. Banks J, Cassidy D, Campbell IA, Ghuman S. Unusual clinical signs complicating tension haemothorax. *Br J Dis Chest* 1984;78:272-274.