

# DURAL ARTERIOVENOUS FISTULA PRESENTING AS THALAMIC DEMENTIA

Mariangela Barbi Gonçalves<sup>1</sup>, Orlando Maia Jr<sup>2</sup>, Jorge Luiz Amorim Correa<sup>3</sup>, Sávio Boechat Primo de Siqueira<sup>4</sup>, Daniel de Holanda Christoph<sup>4</sup>, José Alberto Landeiro<sup>5</sup>

Dementia implies the decline of intellectual abilities or cognitive function. It is also characterized by behavioral abnormalities and changes in personality<sup>1</sup>. One unusual cause of dementia, characterized mainly by amnesic syndrome, apathy, speech and language disturbances, hypersomnia, vigilance disorder and vertical gaze palsy, is due to thalamic lesion that led to the term "thalamic dementia"<sup>2-4</sup>. This is related to the known thalamic connections with cortical nucleus concerned with memory process, cognition and behavior, the thalamo-fronto-limbic loops<sup>5,6</sup>. Intracranial dural arteriovenous fistula (AVF) with venous drainage into internal cerebral veins and consequently venous hypertension is uncommon and may be associated with thalamic injury. Dural AVF consists of abnormal shunting of blood between the meningeal branches or rarely cortical branches of the external, internal carotid or vertebral arteries, and the venous system, embedded in the dural leaflets of a venous sinus to form the nidus<sup>7-10</sup>. Capillary beds usually interposed are lacking<sup>7</sup>. In-

tracranial dural AVF represent approximately 10% to 15% of all intracranial vascular malformations<sup>8,9,11-13</sup>.

Since the posterior fossa dural AVF and subsequent venous hypertension is important to be considered in the different diagnosis of thalamic lesions<sup>14</sup>, we report an unique case of thalamic dementia associated with venous hypertension in the bilateral thalamus due to a dural AVF that was successfully treated by endovascular procedures.

## CASE

A 43-year-old man, air professional, coursing political science master, presented subacute onset of apathy and memory deficit. Initially, the symptoms were stress misdiagnosed. Nevertheless, his symptoms worsened progressively. On admission, the patient was awake but confuse in time. There was neither headache, neither visual impairment nor vomits. The thorough neurological examination revealed critical sense mild compromised and amnesia, predominately of recent events. No significant medical history was related.

The optic fundi were normal. There was no signal of intra-

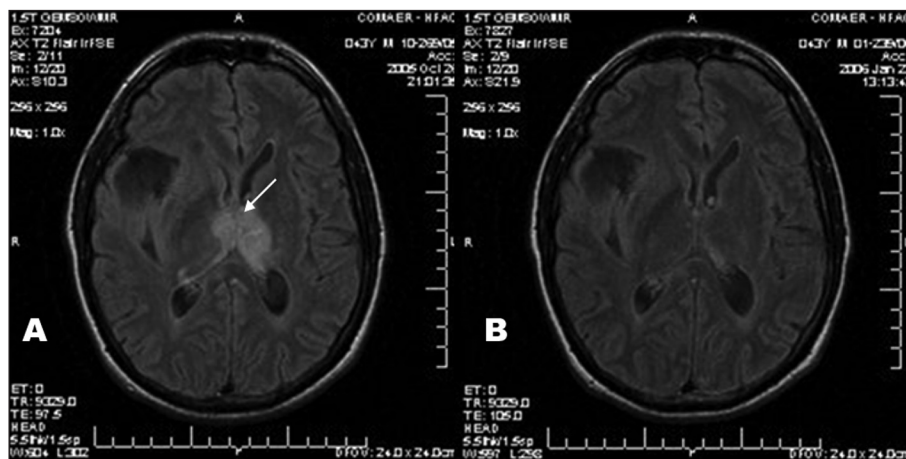


Fig 1. Preoperative axial Flair MRI (A) shows a right temporal arachnoid cyst and an increased signal intensity in both thalami (arrow). Follow-up axial Flair MRI (B) three months after interventional therapy shows normal appearance of both thalami.

## DEMÊNCIA TALÂMICA SECUNDÁRIA A FISTULA ARTERIOVENOSA DURAL

Serviço de Neurocirurgia do Hospital de Força Aérea do Galeão, Rio de Janeiro RJ, Brasil (HFAG); <sup>1</sup>Médica Residente do Serviço de Neurocirurgia do HFAG, Mestre em Neurociências pela Universidade Federal do Estado do Rio de Janeiro, Brasil (UNIRIO); <sup>2</sup>Neurocirurgião Endovascular do Serviço de Neurocirurgia do HFAG; <sup>3</sup>Médico Assistente do Serviço de Neurocirurgia do HFAG; <sup>4</sup>Médico Residente do Serviço de Neurocirurgia do HFAG; <sup>5</sup>Chefe do Serviço de Neurocirurgia do HFAG, Professor Adjunto da Disciplina de Neurocirurgia da Universidade Federal Fluminense, Brasil (UFF).

Received 11 December 2007. Accepted 27 February 2008.

Dra. Mariangela Barbi Gonçalves – Rua Nina Rodrigues 72/602 – 22461-100 Rio de Janeiro RJ – Brasil. E-mail: goncalvesmb@gmail.com

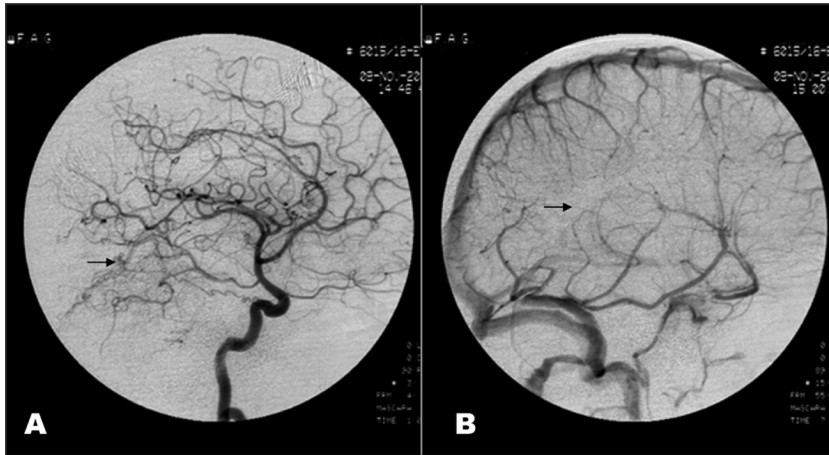


Fig 2. Cerebral angiography of the right internal carotid artery, lateral projection, on the arterial phase (A) shows a dural AVF (arrow), and on the venous phase (B) a poor deep venous drainage (arrow), without visualization of the internal cerebral veins, draining to superficial and petrosal veins.

Fig 3. Cerebral angiography of the right external carotid artery, lateral projection, shows (A) a dural fistula (arrow), feeding a dural venous aneurysm (arrowhead). (B) Selective catheter guide on the occipital artery, with microcatheter ultra flow on the origin of the dural fistula (arrow).

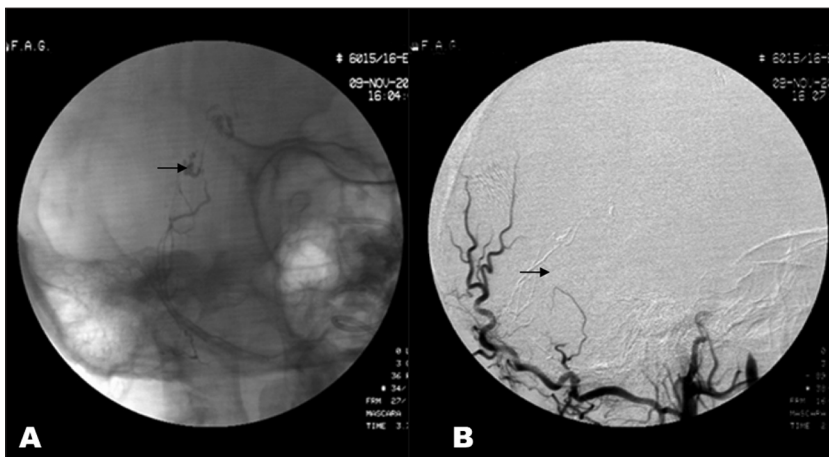
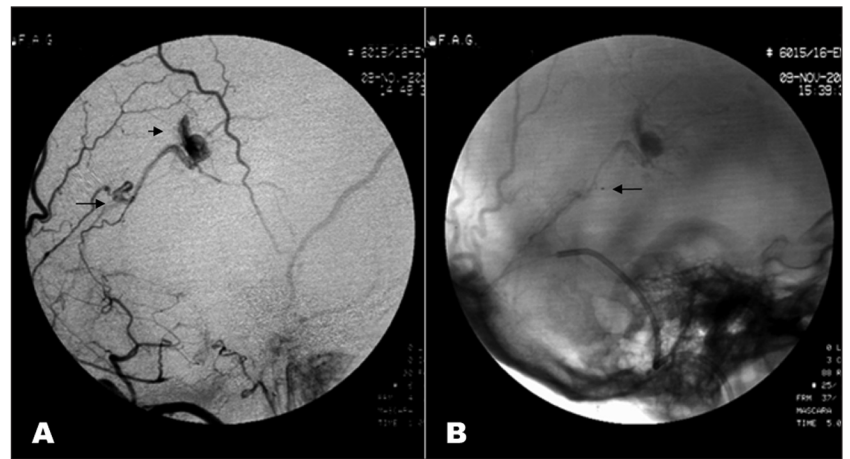


Fig 4. (A) Angiography, oblique view, shows AVF occlusion with embolytic material (arrow). (B) Postoperative angiography with dural AVF occlusion.

cranial hypertension, and the neurological symptoms were restricted to cognitive dysfunction. The blood pressure was normal. Thus, investigation of another cause of dementia began. The laboratory exams such as endocrinology and inflammatory tests, syphilis antibody and complex B vitamin dosage were normal. No infection preceding the onset of symptom was related. A computed tomography (CT) scan of the brain was compatible with a major arachnoid cyst, that involved the right fron-

tal and temporal lobes, with little shift of midline and osseous remodeling.

Magnetic resonance image (MRI) showed FLAIR-high signal lesions in both thalamic areas (Fig 1A), with no alterations on diffusion or perfusion sequences. Cerebral angiography (Fig 2A) showed a tentorial dural AVF, type IIa+IIb according to the Cognard classification and type II according to the Borden classification, fed by the meningo tentorial branches of the right internal

carotid artery and meningeal branches of the occipital artery of the right external carotid artery (Fig 3A). Retrograde flow through the basal cortical veins, the internal cerebral veins and the vein of Galen with straight sinus arterialization was evident (Fig 2B).

Accordingly, the diagnosis of bithalamic venous infarction secondary to increased deep venous pressure around the basal ganglia and consequently difficult of venous drainage due to arteriovenous fistula was done.

Considering the cerebral angiography findings, endovascular embolization was performed as treatment. By means of selective arterial microcatheterism, ultra flow microcatheter was navigated into the right occipital artery and into as many arteries supplying the tentorial dural AVF as possible (Fig 3B). The dural AVF was then completely occluded with a liquid adhesive embolic agent (Onyx™ - MTI) via the right external carotid artery approach (Fig 4A). Post-embolization angiography revealed angiographic occlusion, with marked devascularization of the dural AVF (Fig 4B). The tentorial draining veins immediately reopened, and the flow through deep cerebral venous systems was restored. There was no thrombosis of venous system, but venous congestion.

Three months after the interventional therapy, MRI showed absence of FLAIR-high signal thalamic lesions (Fig 1B). Clinical evaluation revealed a completely improvement of memory and cognitive status. The patient also returned to work and study.

Approval was obtained from the hospital's Ethics Committee and the patient's informed consent for publication of this case report.

## DISCUSSION

Progressive dementia caused by venous congestion in bilateral thalamic areas associated with dural AVF is rare<sup>14</sup>. The so-called thalamic dementia, when secondary to an intracranial dural AVF as in our patient is considered a reversible dementia as symptoms recover after interventional therapy<sup>4,14</sup>.

Dural AVF can be presented through multiple clinical symptoms depending on the location, size of the lesion, flow, and venous drainage of the dural AVF<sup>7,15,16</sup>. Memory or behavior impairment may occur, as shows our patient, due to retrograde flow into the tentorial veins leading to venous hypertension, which can result in cerebral edema and associated neurological deficits due to bilateral thalamic lesions<sup>15,16</sup>.

Venous congestion in the thalamus of our patient may have been caused by tentorial venous reflux to the straight sinus, vein of Galen and consequently to the internal cerebral veins and the basal vein. The thalamic veins from the superior and medial portions of the thalamus drain into the internal cerebral or great veins, and those from the inferior and lateral portions of the thalamus drain into the basal vein or its tributaries<sup>17</sup>. So the drainage of the fistula to the thalamus produces a decrease in the arteriovenous pressure gradient and ischemia<sup>8</sup>. This is explained by

chronic passive congestion following retrograde increase in venous pressure toward the thalamic venous drainage territory<sup>4,14</sup>. If venous thrombosis were the primary disease we should not expect normal sinus blood flow immediately after the occlusion of the dural AVF.

In the setting of subacute cognitive deficit, the diagnosis of deep cerebral vein thrombosis must be considered when neuroimage exams show bilateral thalamic changes. Accordingly, the patient was submitted to a cerebral angiography, gold standard for evaluation of dural AVF<sup>9</sup>, via transarterial approach. This angiography demonstrated tentorial dural AVF fed by the right internal (meningeal tentorial branches) and external carotid artery (occipital artery) and drained by the straight sinus and the internal cerebral veins. The straight sinus originates behind the splenium of the corpus callosum at the union of the inferior sagittal sinus and the great vein. It continues posteriorly and downward in the junction of the tentorium and falx. It may drain into either transverse sinus, but most commonly drains predominantly into the left transverse sinus<sup>17</sup>. Those angiographic findings were correlated with our patient clinical presentation of the tentorial dural AVF and confirm that the thalamic symptoms were related to the venous character and depended on the territory of the draining veins of the dural AVF.

In this case, with arterialization of the straight sinus that becomes dysplastic, increment of venous pressures can promote the formation of venous aneurysms, thereby augmenting the potential for intracranial hemorrhage<sup>7,18</sup>. On the basis of researchers' findings, it is now generally accepted that the venous drainage prototype of dural AVF is the most predictive factor that predispose to the risk of these aggressive dural AVF symptoms, with focal neurologic deficits or hemorrhage<sup>12</sup>.

Although several classification systems have been developed to enable prediction of dural AVF risks with the purpose of better decision about treatment, those devised by Cognard et al.<sup>12</sup> and Borden et al.<sup>19</sup> are the most commonly used<sup>11</sup>. This case, type IIa+IIb according to the Cognard classification and type II according to the Borden classification, was at risk to present potentially devastating venous hypertension due to high flow dural AVF drainage into a sinus with insufficient antegrade venous drainage and reflux.

Pathophysiologic mechanism of the thalamic dementia of this patient is venous hypertension of the thalamus. Retrograde arterial flow into the venous system promotes high pressure that is thought to be a significant cause of venous congestion<sup>8</sup>.

There is a general agreement that embolization have become the first-line treatment<sup>8,15</sup>. Venous drainage is the most important factor in directing the treatment, with

goal is complete occlusion<sup>15</sup>. In that case the strategy of embolization is to catheterize and embolize the origin of the fistula until it is obliterated<sup>20</sup>, as we have done.

Bilateral thalamic lesions have a poorer neurobehavioral prognosis than unilateral one. Persistent dementia and severe amnesia often occurs rather than improvement of cognitive and behavioral functions<sup>21</sup>. Nevertheless, our patient postoperative neurological evaluation revealed an improvement of memory and cognitive status, that is probably correlated to functional outcome of venous better than arterial infarctions<sup>22</sup>. The improvement in clinical symptoms and MRI findings would propose that the thalamic lesions reveal venous hypertension, differing from infarction<sup>16</sup>.

Bilateral lesions of the thalamus characteristically present with specific neurological and neuropsychological patterns, like mood and behavior changes and memory dysfunction<sup>2,6</sup>. Impairment of the thalamus caused by venous hypertension must be differentiating from infarction as the cause of the neurological symptoms. In such cases, while venous occlusion involves anticoagulation treatment, which might lay the patient with dural AVF at considerable complications risk. As a result, the association between thalamic dementia and dural AVF should be considered. Interventional therapy can lead to angiographic occlusion and resolution of the symptoms.

## REFERENCES

- Victor M, Rooper A. Dementia and the amnesic (Korsakoff) syndrome. In Victor M, Rooper A (Eds). *Adams and Victor's principles of neurology*. 7.Ed. New York; McGraw Hill 2001;21:444-461.
- Carrera E, Bogousslavsky J. The thalamus and behavior: effects of anatomically distinct strokes. *Neurology* 2006;66:1817-1823.
- Schmahmann JD. Vascular syndromes of the thalamus. *Stroke* 2003;34:2264-2278.
- Tamamoto F, Nakanishi A, Takanashi T, et al. Unexpected accumulation of thallium-201 in bilateral thalamic venous infarction induced by arteriovenous fistula in the posterior fossa: report of a case. *Ann Nucl Med* 2003;17:239-243.
- Cargioli-Vila MV, Carriquiry-Berner F, Vargas-Cañas A. Demencia secundaria a infarto talámico: comunicación de un caso. *Rev Neurol* 2004;38:443-445.
- Kumral E, Evyapan D, Balkir K, Kutluhan S. Bilateral thalamic infarction: clinical, etiological and MRI correlates. *Acta Neurol Scand* 2001;103:35-42.
- Holland MC, Holland EC, Martin NA. Clinical presentation and diagnostic evaluation of intracranial arteriovenous malformations. In Tindall, Cooper, Barrow (Eds). *The practice of neurosurgery*. Baltimore: Williams & Wilkins 1996;2(6-3):142.
- Li J, Ezura M, Takahashi A, Yoshimoto T. Intracranial dural arteriovenous fistula with venous reflux to the brainstem and spinal cord mimicking brainstem infarction-case report. *Neurol Med Chir (Tokyo)* 2004;44:24-28.
- Tantuwaya LS, Bailes JE. Surgical management of cranial dural arteriovenous fistulas. *Neurosurgical operative atlas* 1997;6:75-83.
- Awad IA. Dural arteriovenous malformations. In Tindall, Cooper, Barrow (Eds). *The practice of neurosurgery*. Baltimore: Williams & Wilkins 1996;2(6-3):144.
- Kiyosue H, Hori Y, Okahara M, et al. Treatment of intracranial dural arteriovenous fistulas: current strategies based on location and hemodynamics, and alternative techniques of transcatheter embolization. *RadioGraphics* 2004;24:1637-1653.
- Cognard C, Gobin YP, Pierot L, et al. Cerebral dural arteriovenous fistulas: clinical and angiographic correlation with a revised classification of venous drainage. *Radiology* 1995;194:671-680.
- Lucas CP, Prandini MN, Caldas JGMP. Analyses of the best therapeutic alternative for intracranial dural arteriovenous malformations. *Arq Neuropsiquiatr* 2005;63:605-613.
- Ito M, Sonokawa T, Mishina H, Sato K. Reversible dural arteriovenous malformation-induced venous ischemia as a cause of dementia: treatment by surgical occlusion of draining dural sinus: case report. *Neurosurgery* 1995;37:1187-1192.
- Kuether TA, Nesbit GM, Barnwell SL. Dural arteriovenous malformations of the transverse and sigmoid sinuses. *Neurosurgical Operative Atlas* 1999;8:57-68.
- Greenough GP, Mamourian A, Harbaugh RE. Venous hypertension associated with a posterior fossa dural arteriovenous fistula: another cause of bithalamic lesions on MR Images. *Am J Neuroradiol* 1999;20:145-147.
- Rhoton AL. The cerebral veins. *Neurosurgery* 2002;51(Suppl 1):S159-S205.
- Troffkin NA, Graham III CB, Berkmen T, Wakhloo AK. Combined transvenous and transarterial embolization of a tentorial-incisural dural arteriovenous malformation allowed by primary stent placement in the associated stenotic straight sinus. *J Neurosurg* 2003;99:579-583.
- Borden JA, Wu JK, Shucart WA. A proposed classification for spinal and cranial dural arteriovenous fistulous malformations and implications for treatment. *J Neurosurg* 1995;82:166-179.
- Purdy PD, Batjer HH, Samson DS. Intracranial arteriovenous malformations: endovascular treatment. In Tindall, Cooper, Barrow (Eds). *The practice of neurosurgery*. Baltimore: Williams & Wilkins 1996;2(6-3):148.
- Krolak-Salmon P, Montavont A, Hermier M, Milliery M, Vighetto A. Thalamic venous infarction as a cause of subacute dementia. *Neurology* 2002;58:1689-1691.
- Boussier MG, Chiras J, Bories J, Castaigne P. Cerebral venous thrombosis-a review of 38 cases. *Stroke* 1985;16:199-213.