

# Endovascular treatment of intracranial pial arteriovenous fistula

Guilherme S. Nakiri<sup>1</sup>, Thiago G. Abud<sup>1</sup>, Ricardo S. Oliveira<sup>2</sup>,  
Antonio Carlos Santos<sup>1</sup>, Hélio R. Machado<sup>2</sup>, Daniel G. Abud<sup>1</sup>

Intracranial pial arteriovenous fistulas (AVFs) are an extremely rare cerebrovascular disease, accounting for 1.6% of all intracranial vascular malformations<sup>1</sup>. It has been recognized as a pathological entity distinct from the arteriovenous malformations (AVMs)<sup>2</sup>, due to the direct connection between the feeder artery and the draining vein, without an intervening true nidus. Pial AVFs differ from dural AVFs in that their arterial supply derive from pial and cortical arteries and they are not involved by the leaflets of the dura-mater<sup>1</sup>. They are in their majority considered to be congenital, but they may also occur sporadically or in association with congenital hereditary vasculopathies<sup>3</sup>. The pial AVFs have a significant morbid-mortality secondary to its rupture when not treated<sup>4</sup>.

We report a case of intracranial pial fistula in a 2 years-old patient presenting seizures since the neonatal period, emphasizing the angiographic findings and the results of the endovascular treatment.

## CASE

A two years-old female child presented seizures since the neonatal period, controlled with antiepileptic drugs. There was no history of head trauma. General and neurological examinations were normal. Magnetic resonance imaging demonstrated an enlarged subarachnoid space containing tortuous and engorged pial vessels in the left temporo-parietal region, revealing a probable venous shunt with distal branch of the middle cerebral artery (MCA). Angiography demonstrated a high-flow pial AVF fed by enlarged post-central branch of the left MCA, with

2 fistulous points, each one draining to a cortical dilated vein, which converted to a single vein before draining to the left sigmoid sinus (Figs 1A, 1B, 1C and 1D). A focal narrowing could be seen right in the junction between the draining vein and the sigmoid sinus (Fig 1C).

The endovascular treatment was carried under general anesthesia, with endovascular access by right percutaneous femoral puncture. A 6 F catheter guide was placed in the left internal carotid artery, and an angiogram was performed to study the pial AVF architecture. Selective catheterization of post-central branch of the left middle cerebral artery was performed with a microcatheter Excelsior 10-18 (Boston Scientific, Natick, Massachusetts), which was navigated until the venous side of the fistula. Embolization was carried out with detachable coils (GDC- Boston Scientific) placed from the venous side of the fistula to the arterial side for each fistulous point (Figs 2A and 2B). Post procedure angiography showed complete closure of the pial AVF (Figs 2C and 2D). The patient was discharged home, on postoperative day 3, completely asymptomatic. On the 6 month follow-up there was no sign of recurrence in the angiography, and no new seizure episode since her treatment.

## DISCUSSION

Since 1970 less than 100 cases of intracranial pial AVF have been reported. They are usually diagnosed during infancy or early childhood and are considered to be congenital in the vast majority of cases. Acquired pial AVF are very rare, and can result of traumatic injury or iatrogen-

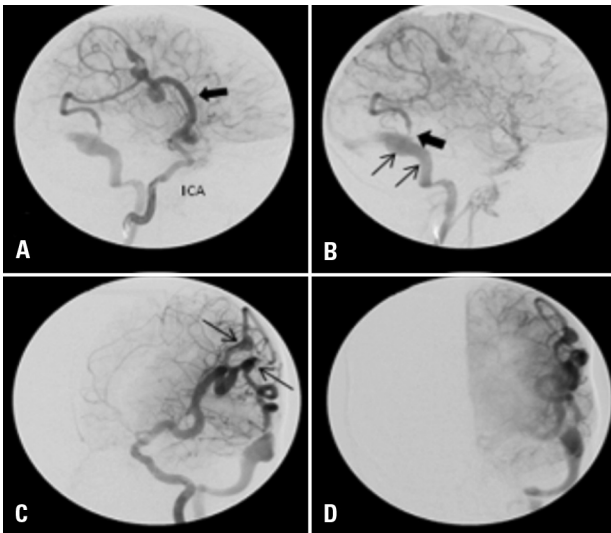
## Correspondence

Daniel Giansante Abud  
Division of Radiology  
Medical School of Ribeirão Preto  
University of São Paulo  
Avenida dos Bandeirantes, 3900  
14048-090 Ribeirão Preto SP - Brasil  
E-mail: dgabud@gmail.com

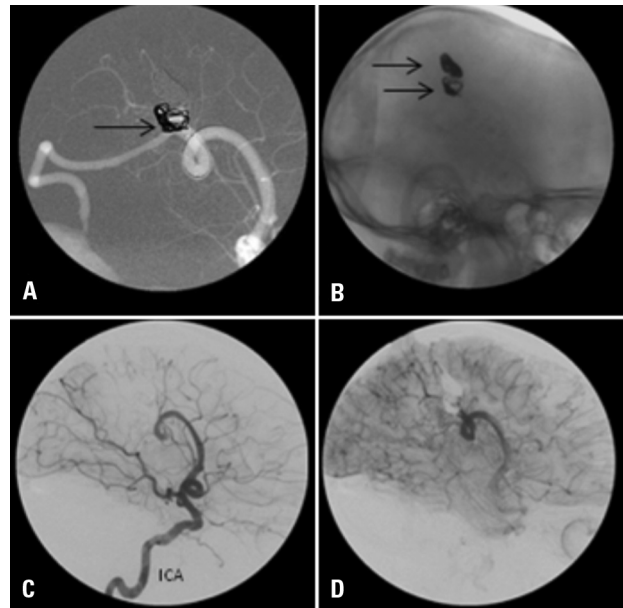
Received 15 June 2009  
Received in final form 25 July 2009  
Accepted 10 August 2009

## TRATAMENTO ENDOVASCULAR DE FÍSTULA ARTERIOVENOSA PIAL

Medical School of Ribeirão Preto, University of São Paulo, Ribeirão Preto SP, Brazil: <sup>1</sup>Department of Internal Medicine, Division of Radiology; <sup>2</sup>Department of Surgery, Division of Pediatric Neurosurgery.



**Fig 1.** Lateral internal carotid artery (ICA) injection in early [A] and late [B] phases showing a high-flow AVF draining to a dilated vein, and then to the sigmoid sinus. [A] High-flow pial AVF fed by enlarged post-central branch of the left MCA (arrow). [B] Focal narrowing (thick arrow) in the junction between the draining vein and the sigmoid sinus (thin arrows). [C] Left anterior oblique view demonstrating the two fistulous points (arrows), each one draining to a cortical dilated vein, which converted to a single vein before draining to the left sigmoid sinus. [D] Posteroanterior view, in late phase after ICA injection.



**Fig 2.** [A] "Road map" angiogram during the deployment of the detachable coils (arrow). [B] Lateral plain film after detachment of the coils in the 2 fistulous points (arrows). [C/D] Postembolization lateral ICA angiogram, in early phase [C] and late phase [D], showing complete closure of the fistula.

ic causes. Others less frequent causes have been reported, as the first case report of a pial AVF secondary to cortical vein thrombosis, described by Constantine et al.<sup>5</sup>. Little is known about the pial AVFs pathophysiological mechanisms. It is believed that an error in the embryological development would be responsible as its etiology. Lasjaunias<sup>6</sup> proposed that structural congenital alterations would be primarily responsible for a vascular remodeling process, affecting the endothelial cells at the venous side of capillaries. These alterations would stay in a quiescent dysfunctional state, and its structural manifestation would depend on triggers such as mechanical, hormonal, hemodynamic, pharmacologic, thermal, radiologic, infective and metabolic factors.

Several case reports have described presence of an aneurysm in the feeder artery of pial AVFs, which could potentially explain the high rate flow in the artery as a hemodynamic trigger in their pathogenesis mechanism<sup>7</sup>. Pial AVFs in Moya-Moya disease and following cerebral vein thrombosis suggest ischemia or hypoxia is an important etiological factor<sup>5-7</sup>, which is reinforced by the fact that hypoxia is a powerful trigger for the up-regulation of angiogenic factors expression<sup>8</sup>.

Pial AVFs can cause seizures, hemorrhage, headache, neurological deficit and symptoms of increased intracranial pressure<sup>3,6,9</sup>. Its diagnosis is usually made between 2 and 5 years-old. In neonates and infants it can induce

cardiac failure, macrocephaly and formation of a palpable mass due to giant varices<sup>3,9</sup>.

The natural history of the pial AVFs remains unclear because of its rarity. Spontaneous closure of the pial AVF cannot be expected, since only one case has been reported in the literature. The high flow and perfusion pressure in pial AVFs due to the direct arteriovenous shunt can lead to formation of giant varices<sup>10</sup>.

Treatment can be performed through shunt disconnection by microsurgery or endovascular intervention, dispensing resection of the vessels involved in the fistula, like demonstrated by Hoh et al.<sup>1</sup>.

At one institution the choice between these two therapies should take in account the personal experience of professionals involved.

The embolic agents used preferentially for endovascular therapy are detachable coils and acrylic glue. In single hole fistula, with single artery-single vein arteriovenous (AV) shunt, the placement of coils is feasible with the advantage of a better controlled positioning of the embolic material, since it can be withdrawn several times before being detached. In complex fistulas, in which there are many AV communications or multiple arterial feeders with single vein outlet, use of liquid glue is preferred due to its capability of filling all the AV connections completely and especially the micro AV connections.

In our case 2 single-hole fistulas were present, each

one draining separately to a single vein before converging to a single venous channel. Two selective microcatheterization were performed with complete closure of both fistulous points. No ischemic or thromboembolic event occurred during the procedure.

In conclusion, because PIAL AVF has a poor natural history and significant morbid-mortality secondary to its rupture and bleeding, a prompt diagnosis followed by appropriate treatment is very important. With the advances of microcatheters and embolic agents, the endovascular approach has been established as an efficient and safe procedure for the treatment of pial AVFs.

## REFERENCES

- Hoh BL, Putman CM, Budzik RF, Ogilvy CS. Surgical and endovascular flow disconnection of intracranial pial single-channel arteriovenous fistulae. *Neurosurgery* 2001;49:1351-1363.
- Lasjaunias P. Angiographic architecture of Intracranial vascular malformation and fistulas: pre therapeutic aspects. *Neurosurg Rev* 1986;9:253-263.
- Garcia-Monaco R, Taylor W, Rodesch G, et al. PIAL arteriovenous fistula in children as presenting manifestation of Rendu-Osler-Weber disease. *Neuroradiology* 1995;37:60-64.
- Nelson K, Nimi Y, Lasjaunias P, Berenstein A. Endovascular embolization of congenital intracranial pial arteriovenous fistulas. *Neuroimaging Clin N Am* 1992;2:309-317.
- Phatouros CC, Halbach VV, Dowd CF, et al. Acquired pial arteriovenous fistula following cerebral vein thrombosis. *Stroke* 1999;30:2487-2490.
- Lasjaunias P. A revised concept of the congenital nature of cerebral arteriovenous malformations. *Intervent Neuroradiol* 1997;3:275-281.
- Carrillo R, Carreira LM, Prada J, Rosas C, Egas G. Giant aneurysm arising from a single arteriovenous fistula in a child. Case report. *J Neurosurg* 1984; 60: 1085-1088.
- Shweiki D, Itin A, Soffer D, Keshet E. Vascular endothelial growth factor induced by hypoxia may mediate hypoxia-initiated angiogenesis. *Nature* 1992; 359:843-845.
- Aoki N, Sakai T, Oikawa A. Intracranial arteriovenous fistula manifesting as progressive neurological deterioration in an infant: case report. *Neurosurgery* 1991; 28: 619-622.
- Giller CA, Batjer HH, Purdy P, Walker B, Matthews D. Interdisciplinary evaluation of cerebral hemodynamics in the treatment of arteriovenous fistulae associated with giant varices. *Neurosurgery* 1994;35:778-784.