

# Microsurgical coil removal after coiling a carotid bifurcation aneurysm

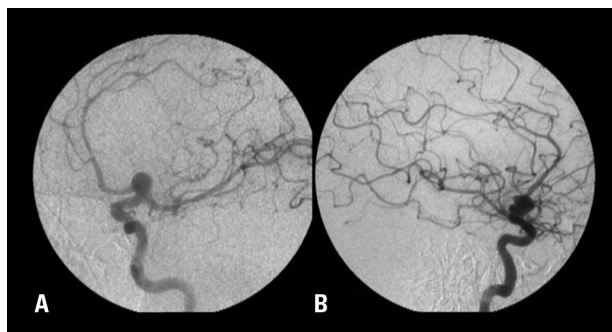
Daniel Holanda Christoph<sup>1</sup>, Igor de Castro<sup>2</sup>,  
Sávio Boechat Primo de Siqueira<sup>3</sup>, Mariangela Barbi Gonçalves<sup>1</sup>,  
Rodrigo Dias Guimarães<sup>1</sup>, João Klescoski<sup>1</sup>, Jorge Luiz Amorim Correa<sup>1</sup>,  
Orlando Maia<sup>1</sup>, José Alberto Landeiro<sup>4</sup>

Endovascular treatments have evolved rapidly in the past decade, and have become established as a treatment option for the management of cerebral aneurysms<sup>1</sup>. Detachable coils represent a major technological advance in aneurysm treatment, although coils are not suitable for the treatment of all aneurysms. As the use of endovascular techniques, especially Guglielmi detachable coils, becomes more widespread, growing numbers of patients will require surgical intervention after endovascular treatment of their intracranial aneurysms<sup>2</sup>. Despite the advances in endovascular technology, all techniques can be associated with treatment failures and serious complications. Increasingly, these patients will present to neurovascular centers for evaluation and further management, including those for whom endovascular treatment was completely unsuccessful, those who have been partially treated, and those who require surgery to deal with a complication of an endovascular treatment. The former group will simply under-

go surgery and present no new challenge to the neurosurgeon. However, the latter two groups will require surgical clipping of aneurysms that were previously coiled. This report describes surgical coil removal in a patient with a large carotid bifurcation aneurysm who had undergone coiling, after which the coil mass protruded into the parent artery, obstructing the middle cerebral artery flow.

## CASE

A 62-year-old woman presented to our institution with a one-year history of left-sided headache and complaining of decreased visual acuity. Cranial magnetic resonance imaging scans showed a mass suggestive of a left carotid artery aneurysm. A digital subtraction angiogram revealed a 10 × 14 mm left carotid artery bifurcation aneurysm (Fig 1). After the angiogram, the patient was offered both surgical and endovascular treatment options, and was informed of the risks and benefits of each procedure. The patient and



**Fig 1.** Cerebral angiographic views showing a left carotid bifurcation aneurysm. Oblique [A] and lateral [B] views.

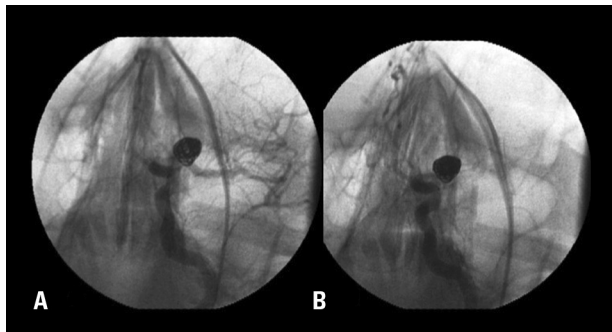
## Correspondence

José Alberto Landeiro  
Avenida Monsenhor Ascânio 501 / 204  
22621-060 Rio de Janeiro RJ - Brasil  
E-mail: jalandeiro@gmail.com

Received 13 June 2009  
Received in final form 7 October 2009  
Accepted 19 October 2009

## MICROCIRURGIA APÓS EMBOLIZAÇÃO DE ANEURISMA DE BIFURCAÇÃO DE ARTÉRIA CARÓTIDA

<sup>1</sup>Department of Neurosurgery, Hospital de Força Aérea do Galeão, Rio de Janeiro RJ, Brazil; <sup>2</sup>Department of Neurosurgery, University of Arkansas for Medical Sciences, Little Rock, USA; <sup>3</sup>Department of Neurosurgery, Hospital São José do Avaí, Itaperuna RJ, Brazil; <sup>4</sup>Chief of Department of Neurosurgery, Hospital de Força de Aérea do Galeão, Rio de Janeiro RJ, Brazil.



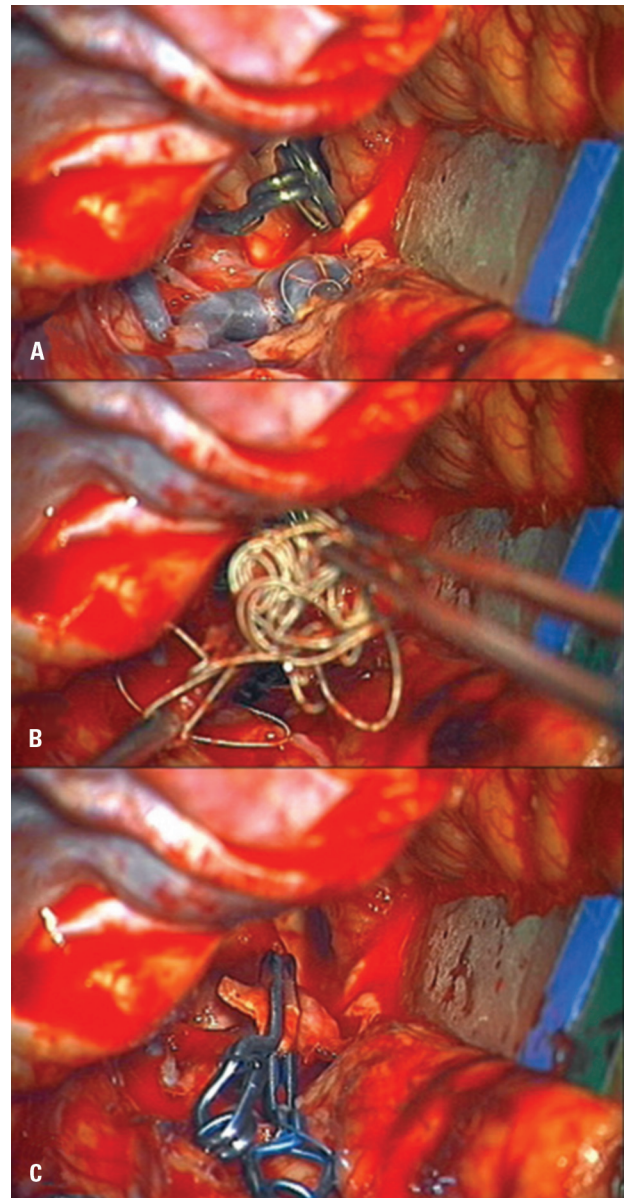
**Fig 2.** [A] Oblique angiographic view after coiling, showing complete occlusion of the aneurysm. [B] Coil mass protrusion from the aneurysm occluding the middle cerebral artery.

her family elected coil embolization of the aneurysm, although the neurosurgical team informed the high risk to coil this wide neck aneurysm.

With the use of local anesthesia, a 7-French guide sheath was inserted into the right common femoral artery. Systemic heparinization was established. The aneurysm was catheterized with a 0.014-inch microcatheter, advanced over a microwire. A combination of complex and helical coils was inserted and packed (Fig 2A). At the end of the procedure, the coil mass protruded into the parent artery of the aneurysm and obstructed the middle cerebral artery (MCA) lumen (Fig 2B). The decision was made to insert a Neuroform stent (Boston Scientific, Natick, MA) to restore the MCA flow, but it was unsuccessful, and angiography showed obstruction of the M1 segment of the MCA. In an attempt to restore the flow, we decided to remove the coil mass with a microsurgical approach.

### Operative procedure

The systemic heparinization was reversed with protamine. Intraoperative mild hypothermia and barbiturate cerebral protection were established. A left pterional craniotomy was performed. Care was taken to preserve the superficial temporal artery. After dural opening, the sylvian fissure was opened and the internal carotid artery (ICA) was exposed for proximal control. The aneurysm was identified at the carotid artery bifurcation. The MCA was clearly occluded, and the coil mass was visible within the aneurysm. Proximal control was established by temporarily clipping the ICA and the anterior cerebral artery, isolating the aneurysm (Fig 3A). The aneurysm dome was incised using a number 11 blade and the coil mass was then removed with gentle traction using microforceps (Fig 3B). Care was taken not to pull too vigorously to avoid tearing the aneurysm sac from the parent artery. After the coils were removed, a permanent clip was applied to the aneurysm neck (Fig 3C).



**Fig 3.** Intraoperative photographs showing the temporary clips on the middle and anterior cerebral arteries and the coils seen through the wall of the aneurysm [A]. The coil mass being removed from the aneurysm [B]. A permanent clip applied to the aneurysm neck, occluding the aneurysm [C].

Postoperatively, the patient developed a left middle cerebral artery infarction, and a decompressive craniotomy was performed. She was discharged with right hemiparesis and aphasia for rehabilitation, with continuous improvement of her neurological deficit. Three months after surgery the patient had mild aphasia and hemiparesis.

### DISCUSSION

Coil embolization has become a common treatment for many intracranial aneurysms, and its safety and efficacy have been demonstrated<sup>3-6</sup>. It is now firmly established as a treatment option for the management of ce-

rebral aneurysms. With advances in coil, stent, and catheter technology, more aneurysms are treated with endovascular techniques. However, detachable coils cannot be used with good results in all aneurysms, particularly those with wide necks, which can allow the herniation of the coils back into the parent vessel.

With endovascular advances, an increasing number of cerebral aneurysms are treated with this technique and, as a consequence, cerebrovascular surgeons will confront an increasing number of complications related to coil embolization. Several authors have reported their experiences in the surgical treatment of subtotally embolized or recanalized aneurysms<sup>2,7</sup>. However, there have been few reports of the surgical techniques used to manage endovascular complications<sup>1,8-10</sup>.

Coil protrusion into the parent artery of an aneurysm is one of the most feared complications of endovascular treatment with detachable coils. The most crucial steps in the management of an untoward event in the angiography suite are the actions taken during the endovascular procedure, the recognition of vessel occlusion and that the flow cannot be restored with endovascular techniques, and rapid transport to the operating room to facilitate a favorable outcome. Barbiturates and mild hypothermia are essential surgical adjuncts, protecting the brain in risk. During the exposure, the superficial temporal artery must be preserved in case a bypass is required. The basic principles of aneurysm surgery are highly relevant in the operative management of these patients, with maximal exposure and early acquisition of proximal and distal control of the afferent and efferent vessels, using temporary occlusion to achieve complete aneurysm trapping, and extracting the coil mass, taking care not to tear the parent vessel during the extraction, allowing satisfactory clipping of the aneurysm, and restoring the vessel flow.

In our patient, microsurgical techniques were used to reverse the occlusion of the MCA by a coil mass, trying to save the ischemic brain penumbra after restoring the flow, mitigating the cerebral damage. The patient improved her neurological deficits, even though she did not present a favorable clinical outcome neither recovered the speaking.

This report emphasizes the importance of having a cerebrovascular team capable of dealing with endovascular treatment failures. As the use of endovascular techniques are becoming more widespread, growing numbers of patients will require surgical intervention.

## REFERENCES

1. Tawk RG, Villalobos HJ, Levy EI, Hopkins LN. Surgical decompression and coil removal for the recovery of vision after coiling and proximal occlusion of a clinoidal segment aneurysm: technical case report. *Neurosurgery* 2006;58:1217.
2. Zhang YJ, Barrow DL, Cawley CM, Dion JE. Neurosurgical management of intracranial aneurysms previously treated with endovascular therapy. *Neurosurgery* 2003;52:283-293.
3. Cognard C, Weill A, Spelle L, et al. Long-term angiographic follow-up of 169 intracranial berry aneurysms occluded with detachable coils. *Radiology* 1999;212:348-356.
4. Henkes H, Fischer S, Weber W, et al. Endovascular coil occlusion of 1811 intracranial aneurysms: early angiographic and clinical results. *Neurosurgery* 2004;54:268-280.
5. Malisch TW, Guglielmi G, Vinuela F, et al. Intracranial aneurysms treated with the Guglielmi detachable coil: midterm clinical results in a consecutive series of 100 patients. *J Neurosurg* 1997;87:176-183.
6. Vinuela F, Duckwiler G, Mawad M. Guglielmi detachable coil embolization of acute intracranial aneurysm: perioperative anatomical and clinical outcome in 403 patients. 1997. *J Neurosurg* 2008;108:832-839.
7. Thornton J, Dovey Z, Alazzaz A, et al. Surgery following endovascular coiling of intracranial aneurysms. *Surg Neurol* 2000;54:352-360.
8. Deshmukh VR, Klopfenstein J, Albuquerque FC, Kim LJ, Spetzler RF. Surgical management of distal coil migration and arterial perforation after attempted coil embolization of a ruptured ophthalmic artery aneurysm: technical case report. *Neurosurgery* 2006;58:379.
9. Short JG, Marx WF, Lanzino G, Ellegala DB, Kassell NF. Surgical salvage of microcatheter-induced aneurysm perforation during coil embolization. *AJNR Am J Neuroradiol* 2002;23:682-685.
10. Thomas JA, Watson VE, McGrail KM. Surgical management of a paraclinoid aneurysm containing a displaced neuroform microstent: technical case report. *Neurosurgery* 2008;63:817.