

Clinical and electroencephalographic characteristics of benign occipital epilepsy of childhood in two tertiary Brazilian hospitals

Soniza Vieira Alves-Leon¹, Renata Gomes Nunes²,
 Maria Emilia Cosenza Andraus³, José Carlos Biagini Junior⁴,
 Marta Hemb⁵, Maria Alice Genofre⁶

ABSTRACT

This study intended to investigate the clinical and electroencephalographic benign occipital epilepsy of childhood (BOEC) characteristics in a population sample of patients from two tertiary Brazilian hospitals. We analyzed retrospectively 4912 electroencephalograms (EEGs) records, and the included patients were submitted to a new clinical and EEG evaluation. Were included 12 (0.92%) patients; 4 (33.3%) with criteria for early BOEC; 6 (50%) for late form and 2 (16.7%) with superimposed early and late onset forms. After new investigation, 2 (16.7%) had normal EEG; 4 (33.3%) had paroxysms over the occipital region; 3 (25%) over the temporal posterior regions and 3 (25%) over the posterior regions. Sharp waves were the predominant change, occurring in 8 (66.6%); spike and slow wave complexes in 1 (8.3%) and sharp and slow wave complexes in 1 (8.3%). Vomiting, headache and visual hallucinations were the most common ictal manifestations, presented in 100% of patients with superimposed forms. Vomiting were absent in the late form and headache was present in all forms of BOEC.

Key words: occipital epilepsy, epilepsy of childhood, benign epilepsy of childhood, benign occipital epilepsy.

Características clínicas e eletrencefalográficas da epilepsia occipital benigna da infância em dois hospitais terciários brasileiros

RESUMO

Este estudo teve como objetivo investigar as características clínicas e eletrencefalográficas da epilepsia occipital benigna da infância (EOBI) em uma amostra populacional de pacientes de dois hospitais terciários brasileiros. Foram analisados retrospectivamente 4912 registros de eletrencefalograma (EEG). Os pacientes incluídos foram submetidos a nova avaliação clínica e eletrencefalográfica. Foram incluídos 12 (0,92%) pacientes; 4 (33,3%), com critérios para EOBI de início precoce; 6 (50%) para a forma tardia e 2 (16,7%), com superimposição de formas de início precoce e tardio. Após nova investigação, 2 (16,7%) apresentaram EEG normal; 4 (33,3%) paroxismos sobre a região occipital; 3 (25%) sobre a região temporal posterior e 3 (25%) sobre as regiões posteriores. Ondas agudas foram a alteração predominante, ocorrendo em 8 (66,6%); complexos espícula e onda lenta em 1 (8,3%) e complexos onda aguda e onda lenta em 1 (8,3%). Vômitos, cefaléia

Correspondence

Soniza Vieira Alves-Leon
 Programa de Epilepsias
 Hospital Universitário
 Clementino Fraga Filho
 UFRJ Unidade de Vídeo-EEG
 Enfermarias 10C2 e 10C4
 Rua Prof. Rodolpho Paulo Rocco 255
 21941-617 Rio de Janeiro RJ - Brasil
 E-mail: sonizavleon@globo.com

Received 29 June 2010
 Received in final form 12 April 2011
 Accepted 19 April 2011

¹Epilepsy Program, Service of Neurology, Hospital Universitário Clementino Fraga Filho, Universidade Federal do Rio de Janeiro (UFRJ), Rio de Janeiro RJ, Brazil. Associate Professor of Neurology and Permanent Professor of *Strictu Sensu* Post Graduation Program in Neurology, Universidade Federal do Estado do Rio de Janeiro (UNIRIO), Rio de Janeiro RJ, Brazil; ²Neurologist and Clinical Neurofisiologist, Doctor in Neurology UFRJ; ³Electroencephalography Section, Department of Neurology, 24th and 25th Infirmaries, Santa Casa da Misericórdia do Rio de Janeiro, Rio de Janeiro RJ, Brazil. Collaborative Professor of *Strictu Sensu* Post Graduation Program in Neurology, UNIRIO; ⁴Neurologist and Clinical Neurofisiologist; ⁵Pediatric Neurologist, Centro Clínico, Pontifícia Universidade Católica do Rio Grande do Sul, Porto Alegre RS, Brazil; Neurologist, Instituto Fernandes Figueira, Fundação Instituto Oswaldo Cruz, Rio de Janeiro RJ, Brazil.

e alucinações visuais foram as manifestações ictais mais comuns, estando presentes em 100% dos pacientes com formas superimpostas de EOBI. Vômitos não foram relatados na forma tardia e cefaléia esteve presente em todas as formas de EOBI.

Palavras-chave: epilepsia occipital, epilepsia da infância, epilepsia benigna da infância, epilepsia occipital benigna.

In 1950, Gastaut¹ described the benign occipital epilepsy of childhood (BOEC), with visual seizures and occipital epileptiform paroxysms reactive to ocular opening and, in 1982, proposed it as a new epileptic syndrome². As a consequence of this fact, there were considerable work done on this subject, some reaffirming Gastaut's idea and others contesting its benign course or even the existence of the syndrome, as well as its specificity to the reactivity of occipital paroxysms and the neuropsychological profile³. In 1989, Panayiotopoulos^{4,5} proposed that the syndrome should be divided in the early and the late onset variants. Again, new reports against and in favor this theory were published. In 1989, The International League Against Epilepsy (ILAE)⁶ recognized BOEC as a syndrome, classifying it in the group of partial epilepsy age and localization-related and, in 2001⁷, admitted that the early variant is different from the late one⁸.

Clinical features

According to the clinical features and the prognosis, the BOEC can be classified in two types: an early one or Panayiotopoulos syndrome and a late one or idiopathic childhood epilepsy of Gastaut⁷.

In the early BOEC, the onset is between 1 and 12 years-old, and the main ictal findings are vomiting and/or deviation of the eyes, which can progress to hemi or generalized seizures. There is also a high occurrence of partial *status epilepticus* that sometimes can be the only clinical event^{4,5,9-22}. Characteristically, even after the most severe seizures and *status*, the child is normal after a few hours of sleep²². Sometimes, this Panayiotopoulos syndrome has eluded recognition because emetic and other ictal autonomic manifestations are dismissed as non-epileptic events of other diseases^{23,24}. Encephalitis is a common example of a misdiagnosis for Panayiotopoulos syndrome²³. The pathophysiology of Panayiotopoulos syndrome is unknown, but it is likely that they are due to diffuse maturation-related epileptogenicity activation susceptible for children emetic centers and the hypothalamus²⁵. Converging evidence from multiple and independent studies has documented Panayiotopoulos syndrome as a model of childhood autonomic epilepsy, which is common and benign²³.

In the late BOEC, the onset is between 3 and 16 years-old, and the main ictal findings are visual seizures,

as elementary visual hallucinations, complex visual hallucinations and visual illusions, blindness or partial visual loss, and non visual seizures, as deviation of the eyes and oculoclonic seizures, forced eyelid closure and eyelid blinking, sensory hallucinations of ocular movements and pain^{1,2,26}. Migraine with visual aura is a common misdiagnosis for this syndrome²³.

There are few studies of inheritance involvement, although Kuzniecky and Rosenblatt found 3 children of a family with early BOEC²⁷. Nagendran et al.²⁸ found different types of benign epilepsies of childhood in the same family, but yet there is still lack of enough studies of the genetic basis of late BOEC.

Sometimes, the same child may present other idiopathic epilepsy of childhood associated with BOEC^{8,29}. These findings suggest a maturation process involvement, and in the case of benign epilepsy with centro-temporal spikes and BOEC, for example, a close genetic relationship, or even a common marker with variable phenotypes (idiopathic partial epilepsies with rolandic and occipital spikes appearing in the same children)^{23,25}.

Electroencephalographic findings

The electroencephalographic findings are similar in both variants, and consist in the majority of high voltage spike-wave complexes in a normal background activity, bilateral and synchronous, over the posterior regions, predominantly in the occipital lobes^{2,4,5,9,12}. Some authors describe the high prevalence of changes on the foci localization as the child is growing-up²⁰.

In the early BOEC, the interictal EEG may show multifocal spikes in 90%, often with occipital predominance²³. This change may not occur in 1/3 of cases²³. A single routine EEG may be normal in 10% of patients²³. The paroxysms are mainly or exclusively seen when the eyes are closed and are totally or partially inhibited when the eyes are open³⁰. There is also the classic, but rare, fixation-off sensitivity phenomena, which consist of disappearing of the paroxysms by elimination of central vision and fixation³⁰. The intermittent photic stimulation and the hyperventilation do not modify the paroxysms occurrence^{2,4,5}. Vigeveno et al.²¹ described the ictal EEG, showing that the entire seizure was dominated by activity of rhythmic or arrhythmic high amplitude slow waves intermixed with spikes or polyspikes localized in the oc-

cipital region. Ictal EEG abnormalities did not change during the different seizure manifestations. The end of the seizure was abrupt²¹.

In the late BOEC, some patients may have only random occipital spikes; others may have occipital spikes only in sleep records and some have a consistently normal interictal EEG²³. The ictal EEG findings were described in the late BOEC during the visual seizure as fast paroxysmic epileptiform activity localized in the occipital regions, with occasional spreading^{2,19}.

Sometimes, because of the frequent EEG occipital spikes in the both variants, the differential diagnosis between them may become difficult, based on the EEG findings²³.

Neuroimaging studies

There are few systematic studies in the literature related to the age and neurologic normality demonstrated by neuroimaging studies in order to discard small organic lesions.

Our purpose was to evaluate the clinical and electroencephalographic characteristics of benign occipital epilepsy of childhood in a sample population of children and adolescents from two tertiary Brazilian hospitals.

METHOD

We performed a bidirectional study. First, we made a retrospective study, analyzing 4029 EEGs of 600 epileptic patients and clinical notes of the requesting physician, from 1995 to 2004, at the Instituto Fernandes Figueira (IFF), a pediatric institute. These EEGs were performed using an analogic EEG, Berger's type. This cohort was associated with another retrospective study of 818 EEG records from 2001 to 2005 of 503 patients at the Hospital Universitário Clementino Fraga Filho, Universidade Federal do Rio de Janeiro (HUCFF/UFRJ). These EEGs were performed using a digital Neurotec® EEG equipment, using especially longitudinal and referential montages and 24 channels. We analyzed EEG records of a total of 1103 patients with epilepsy. Later, we recaptured the patients who met criteria for BOEC and they were submitted to a new clinical, neuroimaging (computed tomography (CT) scan and/or magnetic resonance imaging (MRI) of the brain) and electroencephalographic evaluation, this time at the HUCFF/UFRJ (using the digital 24 channels Neurotec® equipment to perform the EEGs). The EEGs had a minimum duration of 40 minutes, and included records of spontaneous sleep, intermittent photic stimulation and hyperventilation.

The inclusion criteria were clinical and electroencephalographic, as: [1] age of onset of seizures from 1 to 16 years-old; [2] normal development, neurological and mental state; [3] normal brain imaging studies; [4]

normal background EEG, except for postictal records; [5] EEG with posterior discharges; [6] ictal emetic symptoms; [7] visual hallucinations; [8] onset as partial *status epilepticus*; [9] eyes deviation.

We excluded patients with: [1] abnormal neurological development; [2] abnormal brain imaging studies; [3] abnormal background EEG; [4] children with febrile seizures, but without epilepsy development, considering that febrile seizures can be viewed as a syndrome of reactive seizures, and not as a true epileptic syndrome, according Engel⁷.

In the new evaluation, we analyzed age, gender distribution, age onset of the seizure, clinical findings, EEG findings in awake and asleep records and as well as response to antiepileptic drugs. Two neurologists, titular members of the Brazilian Clinical Neurophysiology Society analyzed, together and simultaneously, all EEG records and clinical features.

This study protocol has been approved by the Scientific Investigation Committee (Comitê de Investigação Científica - CIC) and the Research Ethic Committee (Comitê de Ética em Pesquisa - CEP) of the HUCFF/UFRJ. All participants signed an Informed Consent Term.

RESULTS

Analyzing the data of the IFF, we found 81 records from patients with history and EEG findings of occipital epilepsy, but only 14 children met the clinical and EEG criteria for BOEC. Eight of these 14 patients who met the BOEC inclusion criteria in the review of the history, were not traced. Six underwent new clinical, EEG and imaging evaluation, and 1 of these was excluded, due to brain tumor found in the new CT scan investigation.

From 2001 to 2005, out of 503 patients in the HUCFF/UFRJ outcome Epilepsy Unit, 8 met the inclusion criteria, and 1 of them was excluded after the MRI study, due to neurocysticercosis.

So, the total number of patients who met the inclusion criteria for this study was 12. Ten of them were male. Six of these children turned out to fall in the late BOEC category, and 2 turned out to fall with superimposition of early and late onset, all of them having mainly elementary visual hallucinations (Tables 1 and 2). Four children met the criteria for early BOEC with ictal emetic symptoms, in 1 of them accompanied by deviation of the eye and other with elementary visual hallucinations and emetic symptoms (Table 2).

Vomiting, headache and visual hallucinations were presented in 100% of patients with superimposed forms. Vomiting were absent in the late form and headache was present in all forms of BOEC (Table 2).

At the time of the new investigation, 2 patients had normal EEG; paroxysms were restricted to the occip-

Table 1. Results (n=12) of early versus late onset and mixed forms of BOEC patients analysis.

	Early BOEC n=4	Late onset BOEC n=6	Superimposed (mixed) forms n=2
Age onset	4-11 years-old	3-16 years-old	7 years-old
Gender prevalence	Male	Male	Male
Consciousness impairment	3 (75%)	Absent	Absent
Headache	2 (50%)	2 (33.3%)	2 (100%)
Seizures circadian cycles	Night	Day	Day
Seizures duration	Median 5 minutes	Median 5 minutes	Median 5 minutes
Family history	1 (25%)	Absent	Absent
Control and prognosis	Good	Good	Good

BOEC: benign occipital epilepsy of childhood.

Table 2. Results of ictal phenomenology described by patients with early, late and mixed forms of BOEC (n=12).

	Early BOEC n=4	Late onset BOEC n=6	Superimposed (mixed forms) of BOEC n=2
Vomiting	4 (100%)	Absent	2 (100%)
Headache	2 (50%)	2 (50%)	2 (100%)
Tonic deviation of the eyes	1 (25%)	Absent	Absent
Secondarily generalized seizures	Absent	1 (17%)	Absent
Focal status	Absent	Absent	Absent
Visual hallucinations	Absent	6 (100%)	2 (100%)
Amaurosis	Absent	Absent	Absent
Oculo-clonic seizures	Absent	Absent	Absent
Opening and closing sustained eyes	Absent	Absent	Absent

BOEC: benign occipital epilepsy of childhood.

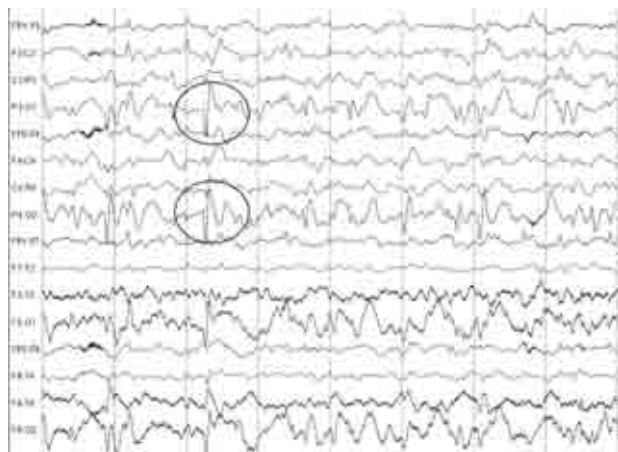


Fig 1. Patient 1, a 5 years-old boy with crisis of visual elementary hallucinations. The EEG shows discharges of occipital bilateral spike and wave complexes, with right predominance (ellipses).




Fig 2. Patient 10, 4 years-old, with crisis of vomiting and headache. The EEG shows interictal epileptiform discharges of bilateral occipital sharp and slow wave complexes, with right predominance (ellipses).

ital region in 4 EEGs (33.3%), with predominance in one side (right or left equally). The temporal posterior regions were involved in 3 (25%) cases, bilateral in 1, on the right in 1 and on the left in 1. The posterior regions (including posterior temporal, parietal and occipital re-

gions) were involved bilaterally in 3 (25%) cases. These results are exposed in the Table 3. Sharp waves were the predominant change, occurring in 8 EEGs (66.6%); spike and slow wave complexes in 1 (8.3%) (Fig 1) and sharp and slow wave complexes in 1 (8.3%) (Fig 2).

Table 3. Results of follow up of the patients (n=12) with BOEC.

Patient no. / Institution	Age of onset (yo)	Clinical findings	EEG	Type of BOEC	Treatment	Prognosis
1 / HUCFF	5	Elementary visual hallucinations	Bilateral occipital SWC with right predominance	Late onset	Valproic acid	Good
2 / HUCFF	11	Ictal vomiting	Normal	Early onset	Carbamazepine	Good
3 / IFF	12	Elementary visual hallucinations	Bilateral posterior temporal sharp waves with left predominance	Late onset	Phenobarbital	Good
4 / HUCFF	16	Elementary visual hallucinations	Bilateral posterior temporal sharp waves	Late onset	Phenobarbital	Good
5 / IFF	5	Ictal headache and vomiting	Right posterior temporal sharp waves	Early onset	Valproic acid	Good
6 / HUCFF	10	Elementary visual hallucinations, headache	Bilateral posterior sharp waves with left predominance	Late onset	Carbamazepine	NCT
7 / IFF	7	Elementary visual hallucinations	Bilateral posterior sharp waves	Late onset	Valproic acid	Good
8 / IFF	8	Ictal vomiting and tonic eye deviation	Bilateral occipital sharp waves with left predominance	Early onset	Valproic acid	Good
9 I IFF	3	Visual hallucinations and headache	Bilateral occipital sharp waves with left predominance	Late onset	Phenobarbital	Good
10 / HUCFF	4	Ictal vomiting and headache	Bilateral occipital sharp-and slow waves with right predominance	Early onset	Carbamazepine	Good
11 / HUCFF	7	Visual hallucinations, vomiting, headache	Normal	SIF	Carbamazepine	Good
12 / HUCFF	7	Visual hallucinations, vomiting, headache	Bilateral posterior sharp waves	SIF	Carbamazepine	Good

YO: years-old; EEG: electroencephalogram; BOEC: benign occipital epilepsy of childhood; HUCFF: Hospital Universitário Clementino Fraga Filho; IFF: Instituto Fernandes Figueira; NCT: noncompliance to the treatment; SWC: spike-wave complexes; SIF: superimposed forms.

The voltage was high in all EEGs.

The paroxysm reactivity was demonstrated in EEGs of 7 patients, where the discharges disappeared with eye opening, and appeared with eye closure.

In our series, the paroxysms improved during sleep. Hyperventilation and intermittent photic stimulation did not show additional abnormalities.

All the patients have normal neuroimaging studies, which was an inclusion criterion.

DISCUSSION

Despite the heterogeneity of the BOEC data in the literature reviewed, it is reasonable to conclude that BOEC exists as an electroclinical entity, being divided in two types: early BOEC or Panayiotopoulos syndrome and late BOEC or Gastaut type. Both types occur at similar age, 1 to 12 years in the early BOEC and 3 to 16 years in the late one. The two types are mainly differentiated by their ictal clinical manifestation, that in the early one is vomiting and tonic deviation of the eyes, during the sleep

and in the late BOEC symptoms are visual seizures (illusions, hallucinations, amaurosis) and non-visual seizures (eye deviation and oculoclonic seizures). Postictal cephalalgia is more frequent in late BOEC. BOEC has a benign course, especially the early one, which frequently appears as a single seizure. According to the literature, the frequency of BOEC is high, representing 20-25% of the benign partial epilepsies of childhood. In our series few cases of BOEC were found²³. We found that the early variant is being super diagnosed in those cases in which it occurs as a single seizure and with normal EEG. It is seeing with the increased number of publications after Panayiotopoulos' articles.

Although some people consider the late BOEC worse than the early one, Caraballo et al.³¹ found, during a prospective study with adolescents, that its course is also benign. As the syndrome occurs in children with age ranging from 1 to 16 years and the prognosis is good, it seems to result from an evolution of the same maturational process which also involves the rolandic and

absence epilepsy, which they sometimes could be associated with. The neurological examination should be normal in BOEC patients, like the neuroimaging studies. In our study all the patients had normal CT scan and three of them had also normal brain MRI studies. In relation to the interictal paroxysms, there is some general agreement about the localization and morphology of the electroencephalographic abnormalities with the reviewed articles. We found the paroxysms localization as the most concordant parameter.

The interictal electroencephalographic findings are similar in the two types of BOEC showing occipital or posterior temporal epileptiform paroxysms that disappear with eye opening although this reactivity is not pathognomonic. In our series, the interictal epileptiform discharges were similar to the rolandic epilepsy discharges, with a predominance of sharp and high voltage waves, which appeared in 77% of the altered EEG.

There is a lot to learn about this syndrome. Possible genetic links with rolandic phenotype may provide further information about the Panayiotopoulos suggestion of an age related continuum of benign childhood seizure susceptibility syndromes²³. Taylor et al.²⁹, exploring the clinical features, classification and clinical genetics of these two BOEC syndromes, using twin and multiplex family studies to determine whether they are indeed distinct, found that BOEC may be an electro-clinical spectrum with Panayiotopoulos and Gastaut syndromes, with many cases showing mixed features, the same described by Genizi et al.⁸. Family studies showed both focal and generalized features, reinforcing that these are not discrete categories of idiopathic epilepsies and are likely to share genetic determinants²⁹. According to Panayiotopoulos et al.²³, benign childhood focal seizures and related epileptic syndromes would need proper multi-disciplinary re-assessment in an evidence-based manner.

This study can contribute to the literature with description of BOEC in a cohort of patients from two tertiary hospitals, adding new cases to other published records and outlining the demographic and electroencephalographic findings of our population. Although few cases have been found and reviewed, their characteristics could be described in details. The benign course of BOEC may have contributed to the patients have been rarely referred to tertiary hospitals.

REFERENCES

- Gastaut H. Electrographic detection of a sub-cortical mechanism in some partial epilepsy; clinical significance of the "areo-thalamic sector". *Rev Neurol (Paris)* 1950;83:396-401.
- Gastaut H. A new type of epilepsy: benign partial epilepsy of childhood with occipital spike-waves. *Clin Electroencephalogr* 1982;13:13-22.
- Germano E, Gagliano A, Magazu A, et al. Benign childhood epilepsy with occipital paroxysms: neuropsychological findings. *Epilepsy Res* 2005;64:137-150.
- Panayiotopoulos CP. Benign childhood epilepsy with occipital paroxysms: a 15-year prospective study. *Ann Neurol* 1989;26:51-56.
- Panayiotopoulos CP. Benign nocturnal childhood occipital epilepsy: a new syndrome with nocturnal seizures, tonic deviation of the eyes, and vomiting. *J Child Neurol* 1989;4:43-49.
- Proposal for revised classification of epilepsies and epileptic syndromes. Commission on Classification and Terminology of the International League Against Epilepsy. *Epilepsia* 1989;30:389-399.
- Engel J Jr. A proposed diagnostic scheme for people with epileptic seizures and with epilepsy: report of the ILAE Task Force on Classification and Terminology. *Epilepsia* 2001;42:796-803.
- Genizi J, Zelnik N, Ravid S, Shahar E. Childhood epilepsy with occipital paroxysms: difficulties in distinct segregation into either the early-onset or late-onset epilepsy subtypes. *J Child Neurol* 2007;22:588-592.
- Ohtsu M, Oguni H, Hayashi K, Funatsuka M, Imai K, Osawa M. EEG in children with early-onset benign occipital seizure susceptibility syndrome: Panayiotopoulos syndrome. *Epilepsia* 2003;44:435-442.
- Martinovic Z. Panayiotopoulos syndrome or early-onset benign childhood occipital epilepsy. *Epilepsia* 2002;43:1270-1271.
- Panayiotopoulos CP. Panayiotopoulos syndrome. *Lancet* 2001;358:68-69.
- Camfield P, Camfield C. Epileptic syndromes in childhood: clinical features, outcomes, and treatment. *Epilepsia* 2002;43(Suppl 3):S27-S32.
- Deonna T, Ziegler AL, Despland PA, van Melle G. Partial epilepsy in neurologically normal children: clinical syndromes and prognosis. *Epilepsia* 1986;27:241-247.
- Panayiotopoulos CP. Vomiting as an ictal manifestation of epileptic seizures and syndromes. *J Neurol Neurosurg Psychiatry* 1988;51:1448-1451.
- Kivity S, Lerman P. Stormy onset with prolonged loss of consciousness in benign childhood epilepsy with occipital paroxysms. *J Neurol Neurosurg Psychiatry* 1992;55:45-48.
- Ferrie CD, Beaumanoir A, Guerrini R, et al. Early-onset benign occipital seizure susceptibility syndrome. *Epilepsia* 1997;38:285-293.
- Panayiotopoulos CP. Benign childhood epileptic syndromes with occipital spikes: new classification proposed by the International League Against Epilepsy. *J Child Neurol* 2000;15:548-552.
- Van den Hout BM, Van der Meij W, Wieneke GH, Van Huffelen AC, Van Nieuwenhuizen O. Seizure semiology of occipital lobe epilepsy in children. *Epilepsia* 1997;38:1188-1191.
- Verrotti A, Domizio S, Guerra M, Sabatino G, Morgese G, Chiarelli F. Childhood epilepsy with occipital paroxysms and benign nocturnal childhood occipital epilepsy. *J Child Neurol* 2000;15:218-221.
- Caraballo R, Cersosimo R, Medina C, Fejerman N. Panayiotopoulos-type benign childhood occipital epilepsy: a prospective study. *Neurology* 2000;55:1096-1100.
- Vigevano F, Lispi ML, Ricci S. Early onset benign occipital susceptibility syndrome: video-EEG documentation of an illustrative case. *Clin Neurophysiol* 2000;111(Suppl 2):S81-S86.
- Panayiotopoulos CP. The benign occipital epilepsies of childhood: how many syndromes? *Epilepsia* 1999;40:1320-1323.
- Panayiotopoulos CP, Michael M, Sanders S, Valeta T, Koutroumanidis M. Benign childhood focal epilepsies: assesment of established and newly recognized syndromes. *Brain* 2008;131:2264-2286.
- Morin I, Smail A, Mercier J-C, Titomanlio L. Clinical reasoning: a child with pulsatile headache and vomiting. *Neurology* 2009;72:69-71.
- Panayiotopoulos CP. Autonomic seizures and autonomic status epilepticus peculiar to childhood: diagnosis and management. *Epilepsy Behav* 2004;5:286-295.
- Di Bonaventura C, Giallonardo AT, Fattouch J, Manfredi M. Symptoms in focal sensory seizures. Clinical and electroencephalographic features. *Seizure* 2005;14:1-9.
- Kuzniecky R, Rosenblatt B. Benign occipital epilepsy: a family study. *Epilepsia* 1987;28:346-350.
- Nagendran K, Prior PF, Rossiter MA. Benign occipital epilepsy of childhood: a family study. *J R Soc Med* 1990;83:804-805.
- Taylor I, Berkovic SF, Kivity S, Scheffer IE. Benign occipital epilepsies of childhood: clinical features and genetics. *Brain* 2008;131:2287-2294.
- Maher J, Ronen GM, Ogunyemi AO, Goulden KJ. Occipital paroxysmal discharges suppressed by eye opening: variability in clinical and seizure manifestations in childhood. *Epilepsia* 1995;36:52-57.
- Caraballo RH, Cersosimo RO, Fejerman N. Benign focal seizures of adolescence: a prospective study. *Epilepsia* 2004;45:1600-1603.