

Unilateral non traumatic vertebral artery dissection with cervical spinal cord infarction

Dissecção unilateral da artéria vertebral não traumática com infarto da medula espinhal cervical

Patricia Gushiken Takahashi, Rubens Gisbert Cury, Camila Galvão Lopes, Mateus Mistieri Simabukuro, Paulo Eurípedes Marchiori

A 45-year old male patient with diabetes presented neck pain with paresthesia and paresis in upper limbs. Physical examination: proximal paraparesis, hyporeflexia and hypoesthesia in the upper limbs. MRI: ischemia in the right hemi-spinal cord (Fig 1), associated to right vertebral artery (VA) dissection (Fig 2).

Although more frequently VA dissection causes transient ischemic attack or stroke¹, there are few reported cases of ischemia of the cervical cord. VA branches may feed the cervical part of the anterior spinal artery on one or both sides and its occlusion by VA dissection may cause hypoperfusion in this territory².

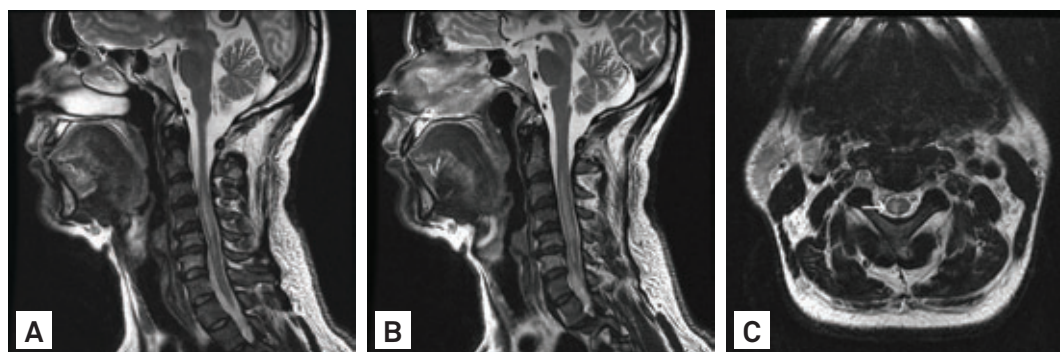


Fig 1. Sagittal T2-weighted MRI with hypersignal in spinal cord at levels C2-C6, without expansion effect (A and B). Axial T2-weighted MRI with hypersignal in right hemi-spinal cord (C).

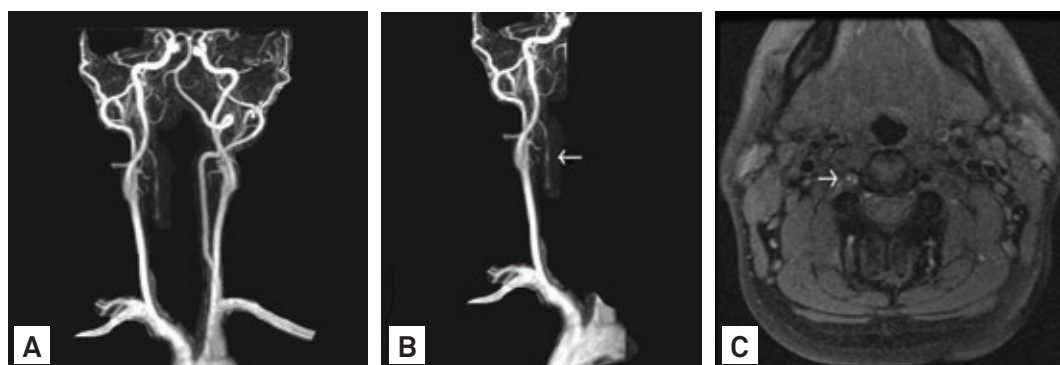


Fig 2. MR angiography showing right vertebral artery not characterized until half of the V2 segment, with sequential stenoses, suggesting arterial dissection (A and B), and axial T1 fat suppression sequence with luminal hypersignal, consistent with thrombus (C).

References

1. Arnold M, Bousser MG. Clinical manifestations of vertebral artery dissection. *Front Neurol Neurosci* 2005;20:77-86.
2. Machnowska M, Moien-Afshari F, Voll C, Wiebe S. Partial anterior cervical cord infarction following vertebral artery dissection. *Can J Neurol Sci* 2008;35:674-677.

Department of Neurology, University of São Paulo Medical School, São Paulo SP, Brazil.

Correspondence: Rubens Gisbert Cury; Rua Dona Adma Jafet 74 / cj. 107; 01308-050 São Paulo SP - Brasil; E-mail: rubens_cury@terra.com.br

Conflict of interest: There is no conflict of interest to declare.

Received 08 September 2011; Received in final form 14 October 2011; Accepted 21 October 2011