

Depression and temporal lobe epilepsy represent an epiphenomenon sharing similar neural networks: clinical and brain structural evidences

Depressão e epilepsia de lobo temporal representam um epifenômeno compartilhando redes neurais similares: evidências clínicas e de neuroimagem estrutural

Kette D. R. Valente^{1,2}, Geraldo Busatto Filho²

ABSTRACT

The relationship between depression and epilepsy has been known since ancient times, however, to date, it is not fully understood. The prevalence of psychiatric disorders in persons with epilepsy is high compared to general population. It is assumed that the rate of depression ranges from 20 to 55% in patients with refractory epilepsy, especially considering those with temporal lobe epilepsy caused by mesial temporal sclerosis. Temporal lobe epilepsy is a good biological model to understand the common structural basis between depression and epilepsy. Interestingly, mesial temporal lobe epilepsy and depression share a similar neurocircuitry involving: temporal lobes with hippocampus, amygdala and entorhinal and neocortical cortex; the frontal lobes with cingulate gyrus; subcortical structures, such as basal ganglia and thalamus; and the connecting pathways. We provide clinical and brain structural evidences that depression and epilepsy represent an epiphenomenon sharing similar neural networks.

Key words: epilepsy, depression, neuroimaging, temporal lobe.

RESUMO

A relação entre depressão e epilepsia é conhecida desde a antiguidade; entretanto, até o momento, não é completamente compreendida. A prevalência de transtornos psiquiátricos nas pessoas com epilepsia é elevada quando comparada à população em geral. A taxa de depressão varia de 20 a 55% nos pacientes com epilepsia refratária, especialmente considerando-se aqueles com epilepsia do lobo temporal causada por esclerose mesial temporal. A epilepsia do lobo temporal é um bom modelo biológico para compreender as bases estruturais comuns entre a epilepsia e a depressão. É relevante ressaltar que a epilepsia do lobo mesial e a depressão apresentam circuitos similares envolvendo: os lobos temporais com o hipocampo, a amígdala, o córtex entorrinal e o neocórtex; os lobos frontais com o giro cíngulo; estruturas subcorticais, como os núcleos da base e o tálamo, e suas vias de conexão. Postulamos por meio de evidências clínicas e estruturais que a depressão e a epilepsia representam um epifenômeno com redes neuronais similares.

Palavras-Chave: epilepsia, depressão, neuroimagem, lobo temporal.

Around 400 BC, Hippocrates wrote: “Melancholics ordinarily become epileptics, and epileptics, melancholics; what determines the preference is the direction the malady takes; if it bears upon the body, epilepsy, if upon the intelligence, melancholy”.

The relationship between depression and epilepsy has been known since ancient times, however, to date, it is not fully understood.

The prevalence of psychiatric disorders (PD) in persons with epilepsy is high compared to general population. Mood disorders occur in 11 to 62%, psychosis in 7 to 10% and personality disorders in 5 to 33%¹⁻⁵.

Depression is the most frequent PD in persons with epilepsy⁹⁻¹¹. It is assumed that the rate of depression ranges from 20 to 55% in patients with refractory epilepsy, especially considering those with temporal lobe epilepsy caused by mesial temporal sclerosis (TLE-MTS). Furthermore, people with epilepsy have a lifetime prevalence of any type of mood disorder higher than that observed in general population or people with other chronic medical disorders. Despite its high prevalence, depression remains underdiagnosed and undertreated in persons with epilepsy, with relevant personal and social costs. The impact of depression in morbidity can be

¹Laboratório de Neurofisiologia Clínica, Instituto de Psiquiatria do Hospital das Clínicas da Faculdade de Medicina da Universidade de São Paulo (USP), São Paulo SP, Brazil;

²Laboratório de Neuroimagem em Neurociências, Departamento de Psiquiatria da Faculdade de Medicina da USP, São Paulo SP, Brazil.

Correspondence: Kette D. R. Valente; Rua Doutor Ovidio Pires de Campos 785; 05403-010 São Paulo SP - Brasil; E-mail: kettevalente@msn.com

Conflict of interest: There is no conflict of interest to declare.

Received 05 March 2012; Received in final form 27 July 2012; Received in final form 03 August 2012

evaluated by some studies of quality of life in patients with refractory epilepsy (9.7 seizures/month; mean duration of epilepsy of 12.7 years)^{12,13}. According to Gilliam et al.¹⁴, quality of life (QOLIE-89) summary score was significantly associated with depression scales, but not with the type or the frequency of seizures, although patients averaged 0.3 to 51 seizures/month. In addition, in a recent population-based study¹⁵, depression was a risk factor for death in epilepsy. Suicide remains as a major cause of death in epilepsy, since 32.5% of all deaths of persons with epilepsy are due to suicide and 13.5% of all registered suicides are committed by these persons¹⁶. Therefore, although complete cessation of seizures remains the paramount goal of therapy in epilepsy, these data clearly clamor for the need to better appreciate the importance of mood disorders in the overall treatment plan of these patients.

Although prevalence of depression in epilepsy, as well as its consequence in terms of mortality and morbidity, have been extensively debated and remains as a major concern for those in charge for these patients, the mechanisms underlying this association — epilepsy and depression — have not been properly explored. For this reason, many clinicians, patients and relatives still believe that epilepsy and depression present a cause and consequence relationship. In this review article, we aimed to provide clinical and brain structural evidences that depression and epilepsy represent an epiphenomenon sharing similar neural networks. In particular, we give emphasis to *in vivo* neuroimaging studies that investigated volumetric abnormalities in samples of individuals with epilepsy compared to control groups.

DEPRESSION AND EPILEPSY: CLINICAL EVIDENCE OF THESE CONDITIONS AS AN EPIPHENOMENA

The hypothesis that epilepsy, as a disabling and stigmatizing disease, may lead to depression has been weakened by some clinical evidences that speaks against the concept of long-lasting epilepsy causing depression. In addition, it has a clinical impact since it keeps clinicians aware for the fact that depression may occur early in the course of epilepsy and even precede its onset.

Depression in children with epilepsy

The same scenario, described in adults, is observed in children with epilepsy that even without the long lasting effect of epilepsy present a high prevalence of PD, especially depression¹⁷. The prevalence of depression ranges from 28% in children with uncomplicated epilepsy to 58% in children with refractory epilepsy¹⁸. A study conducted in a Brazilian tertiary care facility showed that depression was the most frequent PD in children with refractory epilepsy¹⁹. As adults, children

with epilepsy remain undertreated and underdiagnosed, especially those with depression^{3,20}. Suicide rates are high even in children and adolescents with epilepsy²¹.

Bidirectional relationship

Some studies have shown that depression and suicide attempt are independent risk factors for the onset of seizures and epilepsy. The first scientific studies to show the bidirectional view of epilepsy and depression were carried out in the last decade. One study established that a history of depression preceding the onset of epilepsy was seven times more frequent among patients than among age- and sex-matched controls and that a significant number of patients with new-onset epilepsy were already suffering from depression prior to their first seizure²²⁻²⁴. Another study found that people with epilepsy were 3.7 times more likely to have a history of depression preceding their initial seizure than the control group²³, corroborating Hippocrates clinical observations and suggesting a bidirectional relationship between epilepsy and depression.

Therefore, the high prevalence of the comorbidity of these two disorders in children and in patients with new-onset epilepsy associated with the occurrence of depression prior to seizure or epilepsy onset suggests that, although it is naturally assumed that mood disorders are a consequence of seizure disorders, as a normal reaction to the impact of epilepsy, we have data that depression and epilepsy may share common pathogenic mechanisms, manifesting with the involvement of the same neuroanatomic structures, as will be discussed²⁵.

DEPRESSION IN TEMPORAL LOBE EPILEPSY

Temporal lobe epilepsy (TLE) is a good biological model to understand the common structural basis between depression and epilepsy.

Temporal lobe epilepsy can be determined by neocortical lesions (lateral temporal lobe epilepsy) and by mesial temporal sclerosis. Mesial temporal sclerosis (MTS) is a condition characterized by hippocampal atrophy. Hippocampal sclerosis is the most common histological abnormality observed in patients with mesial temporal lobe epilepsy²⁶. It usually presents marked cell loss in Sommer's sector (CA1 and subiculum) and endofolium (hilus and CA4). Between these regions, there was relative sparing in CA3 and CA2²⁷.

In patients with temporal lobe epilepsy caused by mesial temporal sclerosis (TLE-MTS), the frequency of depression is extremely high even when compared to other types of epilepsy (50–60%), including neocortical TLE^{26,27}. Patients with TLE-MTS show significantly higher depression scores than patients with neocortical temporal lesions, independent of the lateralization of the lesion²⁸. The prevalence of suicide in epilepsy ranges from 3–5%, being considered higher in

persons with TLE-MTS. In this group, suicide and suicide attempts in persons with TLE-MTS may be 25 times higher than average population^{4,29}, the highest rate observed in all persons with epilepsy. Moreover, compared to TLE patients without hippocampal sclerosis, patients with TLE-MTS have greater frequency of cognitive side effects and mood disturbances when treated with antiepileptic drugs (AEDs)³⁰.

Despite the known clinical relationship between TLE-MTS and depression, only a few studies have investigated whether patients with this comorbidity display a characteristic pattern of clinical and imaging findings. Interestingly, neurocircuitry involved in both TLE-MTS³¹⁻³⁴ and depression³⁵ include the temporal lobes with hippocampus, amygdala and entorhinal and neocortical cortex; the frontal lobes with cingulate gyrus; subcortical structures, such as basal ganglia and thalamus; and the connecting pathways.

These similarities between TLE-MTS and depression will be discussed.

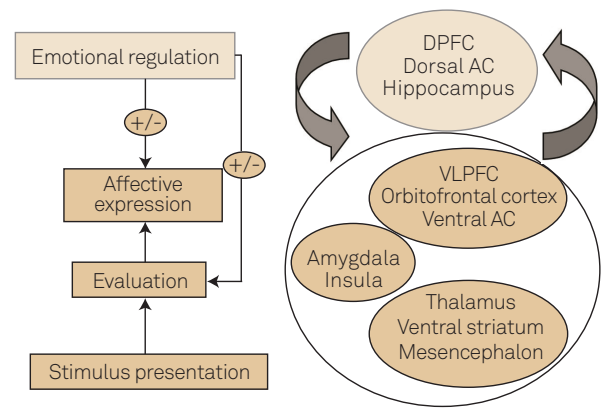
TEMPORAL LOBE EPILEPSY AND DEPRESSION: COMMON BRAIN STRUCTURAL ABNORMALITIES

There are many lines of evidence to support the notion of biological underpinnings of depression and temporal lobe epilepsy as comorbid conditions²⁵. The common brain pathways involved in emotional processing, encompassing the limbic system and its complex connections, constitute one of these pieces of evidence (Fig 1).

NEUROIMAGING STUDIES IN MTLTLE

In *in vivo* neuroimaging methods had advanced dramatically in past decades, with advances both in regard to novel techniques for data acquisition and new models for image processing and analysis. This has allowed increasingly more sophisticated investigations of structural and functional brain abnormalities associated with TLE-MTS.

In morphometric neuroimaging studies using magnetic resonance imaging (MRI), measures of regional brain volumes can be obtained in groups of subjects with TLE in comparison to control groups of healthy individuals, matched for demographic variables. The most widely employed method to perform such between-group comparisons are region-of-interest (ROI) techniques. Such ROI-based methods involve the delineation of selected anatomical structures in sequential brain slices, most often manually, in order to obtain quantitative volumetric indices for such regions. Manual ROI-based methods are time-consuming and subject to observer bias, and the brain areas studied are often circumscribed using variable anatomical borders across different studies of TLE³⁶⁻³⁸. Such



On the left, the steps involved in the perception and evaluation of emotions are shown. On the right, the brain structures involved in the mediation of those emotional processing steps are displayed, including the hippocampus, other limbic structures, cortical regions and subcortical gray matter nuclei. DPFC: dorsal prefrontal cortex; VLPFC: ventrolateral prefrontal cortex; AC: anterior cingulate. Adapted from Phillips ML et al.⁷².

Fig 1. Neural pathways involved in emotional processing.

inconsistencies may limit data comparisons between separate studies and the conduction of meta-analyses of the results obtained. As an alternative to ROI-based measurements, recent morphometric MRI studies have employed automated methods that allow hypothesis-free voxelwise comparisons of regional brain volumes across the entire brain, without requiring the *a priori* selection of anatomical ROI borders and with perfect repeatability. This approach is referred to as voxel-based morphometry (VBM)³⁹. The VBM technique initially involves spatial transformations of the MRI scans of all subjects included in a study onto a common anatomical space, in order to remove inter-individual variations in brain size and shape. In such spatial normalization process, images are conformed by linear and non-linear transformations to a standard template (based on databanks of images normalized to a stereotactic atlas), or to a customized template created specifically for the study (obtained from a pool of images from the population under investigation). Spatially normalized MRI datasets of each subject are then automatically segmented into gray matter, white matter and cerebral spinal fluid compartments, and smoothed with a Gaussian filter. Segmented images are subsequently compared statistically between groups on a voxel-by-voxel basis, and statistical maps are produced in standardized brain space showing the location of voxel clusters where significant between-group volume differences are present, at a predefined statistical level of inference. Because it is fully automated, rather-independent and capable of investigating the presence of morphometric abnormalities across the whole brain (rather than solely on selected brain regions), the VBM has been an important tool in TLE-MTS, substantiating the concept of a more widespread disease, not restricted to the hippocampus.

Keller and Roberts³⁴ reviewed the applications and results of VBM studies that have reported limbic and extralimbic changes associated with TLE considering gray and white matter. A PubMed search yielded 18 applications of VBM to study brain abnormalities in patients with TLE up to May 2007. Across studies, 26 brain regions were found to be significantly reduced in volume relative to healthy controls.

Limbic structures

There was a strong asymmetrical distribution of temporal lobe abnormalities preferentially observed ipsilateral to the seizure focus, particularly of the hippocampus (82.35% of all studies), parahippocampal gyrus (47.06%) and entorhinal (23.52%) cortex. The contralateral hippocampus was reported as abnormal in 17.65% of studies.

EXTRALIMBIC STRUCTURES

There was bilateral distribution of extratemporal lobe atrophy, preferentially affecting the thalamus (ipsilateral=61.11%, contralateral=50%) and parietal lobe (ipsilateral=47.06%, contralateral=52.94%). VBM generally reveals a distribution of brain abnormalities in patients with TLE consistent with the region-of-interest neuroimaging and postmortem literature.

Careful manual and automated morphometrical studies showed that patients with TLE-MTS show significant extrahippocampal atrophy that involves the temporal lobe and extratemporal brain structures⁴⁰⁻⁴⁴. Notably, the distribution of brain atrophy in TLE-MTS preferentially affects a network of regions that are functionally and anatomically connected to the hippocampus³¹⁻³⁴.

Clinical implication

Studies with VBM in TLE-MTS have helped to understand some of the distinct clinical profiles presented by these patients. For instance, Yasuda et al.⁴⁵ showed that gray matter (GM) atrophy with a bilateral and widespread pattern, encompassing the entire ipsilateral temporal lobe, as well as areas in the thalami, cerebellum, occipital, parietal and frontal lobes, was correlated with negative family history for epilepsy.

Patients with a higher seizure frequency and longer period of active epilepsy have also been correlated with more intense gray and white matter reduction over time⁴⁶. Morphometrical MRI studies of patients with epilepsy demonstrated that extrahippocampal gray matter loss likely follows a progressive course⁴⁷. Cognitive deficits commonly exhibited by patients with TLE-MTS, in particular memory impairment, are directly related to the degree of medial temporal and frontal lobe atrophy^{48,49}.

NEUROIMAGING STUDIES IN DEPRESSION: LIMBIC AND EXTRALIMBIC STRUCTURES

Hippocampus

The most robust finding concerns volumetric changes in the hippocampus. High-resolution MRI volumetric studies of individuals with major depressive disorders (MDD) consistently showed decreased volume of hippocampus in adult, as well as in paediatric series⁵⁰⁻⁵². In depression, hippocampal volume is decreased bilaterally⁵⁰⁻⁵² or in the left hippocampus only⁵³. Antidepressants are thought to exert a neuroprotective function, particularly in MDD. Indeed, the work of Sheline et al.⁵², using ROI, showed that the hippocampal volume loss was related with longer duration of untreated disease⁵²⁻⁵⁴. The volume reduction appears to be more pronounced with longer illness duration and in the presence of a positive family history for MDD.

Amygdala

Amygdala, which plays a major role in the processing of fear and related emotions⁵⁵, seems to undergo a two-staged process with initial bilateral enlargement during acute and a subsequent shrinkage during chronic depression. There are several controversies as to amygdala volume, however a recent meta-analysis performed by Hamilton et al.⁵⁶, based on VBM findings, has shown that amygdala enlargement in MDD was associated primarily with antidepressant treatment, whereas unmedicated patients showed volume decrements in this region. Amygdala and parahippocampal gray matter volumes were also significantly reduced in VBM studies including patients with comorbid anxiety disorders, as well as in first-episode/drug free samples⁵⁷.

Therefore, preservation of hippocampal and amygdala volume in MDD has been associated with antidepressant treatment^{52,56}. These findings may be partially explained by the effect of antidepressant treatment that has a number of potentially important effects on multiple biological systems; at present, antidepressant-induced normalization of the serum levels of the neurotrophin brain-derived neurotrophic factor is considered a key modulator of the neurotrophic effect of these drugs on brain structures⁵⁸.

EXTRALIMBIC STRUCTURES – PREFRONTAL CORTEX AND CINGULATE GYRUS

Although hippocampus and amygdala have received the greatest interest, extralimbic structures, such as the prefrontal cortex and the anterior portion of cingulate gyrus, are affected as well (Fig 2).

In depression, smaller volumes of frontal lobes have been found⁵⁹. The work of Lavretsky et al.⁵⁹ used distinct MRI image analyses (cortical surface extraction, tissue segmentation,

and cortical parcellation methods) to measure the gray and white matter volumes in two prefrontal subregions: the anterior cingulate and orbitofrontal cortex showed that the depressed group had smaller orbitofrontal gray matter volumes compared to the age-matched normal comparison group. The severity of apathy was associated with the decreased gray matter volume in the right anterior cingulate gray matter volumes using partial correlation and regression analyses after controlling for age, sex and diagnosis.

Bora et al.⁵⁷, in a systematic search of VBM studies applied in MDD, performed a meta-analysis to data collated from a total of 23 studies comparing regional gray matter volumes of 986 MDD patients and 937 healthy controls. GM was significantly reduced in a confined cluster located in the rostral anterior cingulate cortex (ACC). There were also gray matter reductions in dorsolateral and dorsomedial prefrontal cortex, and decrease in the latter region was evident in patients with multiple-episodes. Gray matter reduction in rostral ACC was the most consistent finding in VBM studies of MDD.

The data reviewed above indicates that there is a substantial degree of similarities in regard to the brain regions that show morphometric abnormalities in TLE-MTS and MDD.

NEUROIMAGING STUDIES IN TLE-MTS AND DEPRESSION

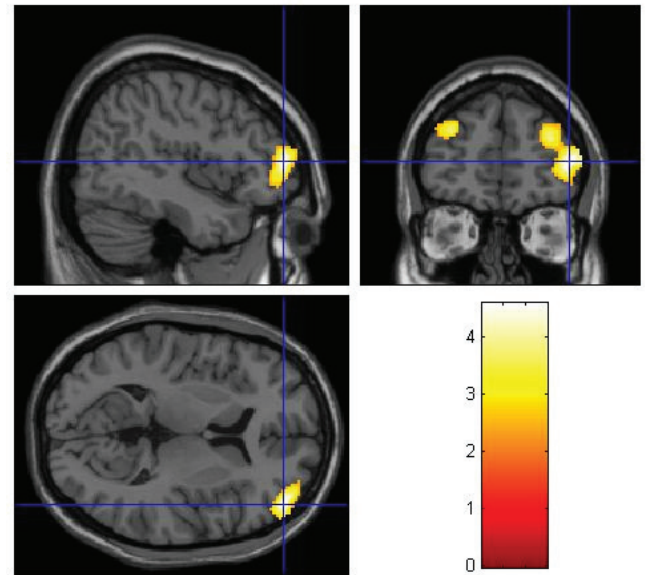
In addition to all the similarities about the regions involved in TLE-MTS and depression, there are some direct evidences based on studies with patients with TLE and depression compared to those TLE subjects without depression.

Limbic structures

MRI volumetric studies of individuals with TLE and depression have found decreased volumes of the hippocampus. Hippocampal volumes loss is expected in TLE-MTS, by definition, especially related to the site of seizure origin – ictal onset zone⁶⁰⁻⁶². However, there are evidences of a more pronounced decrease, or bilateral decrease, in patients with TLE-MTS and depression⁶¹.

Next to the hippocampus, the temporal lobe structure that received greatest attention is the amygdala. Richardson et al.⁶³ examined the relationship between self-reported depression severity and both structural MRI volumetry and [(18)F]fluorodeoxyglucose positron emission tomography (PET)-measured resting metabolism of the amygdala and hippocampus of 18 patients with TLE. Significant positive relationships were noted between right and left amygdala volumes and depression, indicating that both right and left amygdala volumes are associated with depression severity among persons with TLE.

Patients with TLE and depressive symptoms have increasing amygdala volumes measured by MRI⁶³. This



Example of a morphometric magnetic resonance imaging (MRI) study in which patients with severe major depression (MD) with psychotic features (n=20) were found to present reduced gray matter volume bilaterally in the dorsolateral prefrontal cortex compared to a group of healthy controls (n=94), after correction for group differences in demographic variables. Foci of reduced gray matter in MD patients relative to controls ($p < 0.001$) were overlaid on brain slices spatially normalized into an approximation to the Talairach and Tournoux stereotactic atlas, and are in the Figure displayed on the sagittal, coronal and transaxial planes. Data extracted from Azevedo-Marques Périco et al.⁷³.

Fig 2. Findings of extralimbic brain structural abnormalities in patients with major depression.

finding confirmed earlier reports by Tebartz van Elst et al.⁶⁴. Moreover, the latter authors found a significant correlation between left amygdala volume and depression severity^{64,65}. Thus, the amygdala is hyperactive in anxiety and mood disorders and may increase in size during acute depression in patients with TLE^{63,64}. These findings overlie those previously demonstrated in patients with depression without epilepsy⁶⁶, transient amygdala enlargement may be secondary to enhanced regional blood flow and vascular volume as detected by positron emission tomography (PET)⁶⁷ or because of dendritic remodeling with increased branching of amygdaloid neurons⁶⁸. However, as previously mentioned in this text, amygdala and hippocampal volumes decrease in recurrent and chronic untreated depression^{52,62}. Therefore, in this context, there are common characteristics between these findings and those observed in patients with depression without epilepsy.

Extralimbic structures

In TLE, for instance, smaller volumes of frontal lobes have been found⁶².

Woermann et al.⁶⁹ studied patients with TLE and interictal episodes of aggression — intermittent explosive disorder (IED) — that may represent one expression of interictal dysphoric depression in patients with temporal lobe epilepsy. Interictal dysphoric depression, a term coined by

Blumer et al.⁷⁰, to describe the clinical manifestations of depression in epilepsy is characterized by intermittent dysthymia with recurrent episodes of dysphoria. In the work of Woermann et al.⁶⁹, after automated segmentation of cerebral grey matter from T1 weighted MRI, the objective technique of statistical parametric mapping (SPM) was applied to the analysis of 35 control subjects, 24 patients with TLE with a history of repeated, interictal episodes of aggression, and 24 patients with TLE without episodes of aggression. Patients with TLE with aggressive episodes had a decrease of grey matter, most markedly in the left frontal lobe, compared with the control group and with patients with TLE without aggressive episodes, suggesting that a reduction of frontal neocortical grey matter might underlies the pathophysiology of aggression in TLE.

Later on, the elegant study conducted by Salgado et al.⁷¹ with 96 health controls and 48 TLE-MTS (24 with major depression and 24 without major depression) revealed a significant group effect regarding gray matter volume (GMV) in some brain regions. The number of areas of GMV loss was significantly higher in the group with MTLE with depression, with a more widespread distribution of GMV loss in patients with depression.

CONCLUDING REMARKS

In temporal lobe epilepsy, VBM studies showed gray/white matter atrophy extending beyond the atrophic hippocampus. These widespread abnormalities have been associated with higher seizure frequency, longer epilepsy duration and higher incidence of precipitating factors, cognitive impairment and worse surgical outcome. In addition, in this review, we observed that these patients with a more widespread disease, demonstrated by VBM, also have more severe depression. Even though hippocampal and extrahippocampal gray

matter atrophy are related to seizure control and cognitive performance, the mechanisms underlying brain damage in patients with MTLE remain largely unknown. Voxel-based morphometry may provide an important instrument to understand the different clinical profiles presented by patients with the same pathology and perhaps, in the future, to identify those patients with epilepsy who are at-risk for a worse outcome. This may represent an attempt to provide early diagnosis and treatment for these patients. The morphometric MRI studies reviewed in this article, most notably those using VBM, provide strong support to the notion that depression and MTLE represent an epiphenomenon sharing similar neural networks involving several brain regions. It is reasonable to postulate that widespread brain abnormalities may point to a more diseased cortex and consequently to worse outcome in many senses — severity of epilepsy, worse cognition and higher prevalence of depression. It is important to stress that VBM methods were designed to perform mean group comparisons for research purposes and are not suitable for diagnosis of individual cases. Therefore, it is unlikely that VBM has any clinical utility given the lack of robustness for individual comparisons. However, VBM may help elucidate some unresolved important research questions such as how recurrent temporal lobe seizures affect hippocampal and extrahippocampal morphology using serial imaging acquisitions. Furthermore, neuroimaging studies and, in this context, VBM have shown that several structures involved in mesial temporal sclerosis are equally involved in depression and, in a structural level, provide a piece of evidence to better understand this complex puzzle.

ACKNOWLEDGEMENTS

We thank Fabio Luiz de Souza Duran for assistance in the production of the illustrations.

References

1. Gibbs FA. Ictal and non-ictal psychiatric disorders in temporal lobe epilepsy. *J Nervous Mental Dis* 1951;113:522-528.
2. Ettinger A, Reed M, Cramer J, Epilepsy Impact Project Group. Depression and comorbidity in community-based patients with epilepsy or asthma. *Neurology* 2004;63:1008-1014.
3. Ettinger AB, Weisbrot DM, Nolan EE, et al. Symptoms of depression and anxiety in pediatric epilepsy patients. *Epilepsia* 1998;39:595-599.
4. Jones JE, Hermann BP, Barry JJ, Gilliam FG, Kanner AM, Meador KJ. Rates and risk factors for suicide, suicidal ideation, and suicide attempts in chronic epilepsy. *Epilep Behav* 2003;4:S31-S38.
5. Kanner AM, Dunn DW. Diagnosis and management of depression and psychosis in children and adolescents with epilepsy. *J Child Neurol* 2004;19:S65-S72.
6. de Araújo Filho GM, da Silva JM, Mazetto L, Marchetti RL, Yacubian EM. Psychoses of epilepsy: a study comparing the clinical features of patients with focal versus generalized epilepsies. *Epilepsy Behav* 2011;20:655-658.
7. de Araújo Filho GM, Pascalicchio TF, Sousa Pda S, Lin K, Ferreira Guilhoto LM, Yacubian EM. Psychiatric disorders in juvenile myoclonic epilepsy: a controlled study of 100 patients. *Epilepsy Behav* 2007;10:437-441.
8. Moschetta S, Fiore LA, Fuentes D, Gois J, Valente KD. Personality traits in patients with juvenile myoclonic epilepsy. *Epilepsy Behav* 2011;21:473-477.
9. Hermann BP, Seidenberg M, Bell B, Woodard A, Rutecki P, Sheth R. Comorbid psychiatric symptoms in temporal lobe epilepsy: association with chronicity of epilepsy and impact on quality of life. *Epilepsy Behav* 2000;1:184-190.
10. Kanner AM. Depression in Epilepsy is much more than a reactive process. *Epilepsy Curr* 2003;3:202-203.
11. Boylan KR, Bieling PJ, Marriott M, Begin H, Young LT, MacQueen GM. Impact of comorbid anxiety disorders on outcome in a cohort of patients with bipolar disorder. *J Clin Psychiatry* 2004;65:1106-1113.

12. Gilliam F. Optimizing health outcomes in active epilepsy. *Neurology* 2002;58:S9-S20.
13. Boylan LS, Flint LA, Labovitz DL, Jackson SC, Starner K, Devinsky O. Depression but not seizure frequency predicts quality of life in treatment-resistant epilepsy. *Neurology* 2004;62:258-261.
14. Gilliam F. Optimizing epilepsy management: seizure control, reduction, tolerability, and co-morbidities. Introduction. *Neurology* 2002;58:S1.
15. Ridsdale L, Charlton J, Ashworth M, Richardson MP, Gulliford MC. Epilepsy mortality and risk factors for death in epilepsy: a population-based study. *Br J Gen Pract* 2011;61:271-278.
16. Pompili M, Girardi P, Tatarelli R. Death from suicide versus mortality from epilepsy in the epilepsies: a meta-analysis. *Epilepsy Behav* 2006;9:641-648.
17. Hoare P. The development of psychiatric disorder among schoolchildren with epilepsy. *Dev Med Child Neurol* 1984;26:3-13.
18. Rutter ML. Psycho-social disorders in childhood, and their outcome in adult life. *J R Coll Physicians Lond* 1970;4:211-218.
19. Thome-Souza S, Kuczynski E, Assumpção F Jr., et al. Which factors may play a pivotal role on determining the type of psychiatric disorder in children and adolescents with epilepsy? *Epilepsy Behav* 2004;5:988-994.
20. Ott D, Siddarth P, Gurbani S, et al. Behavioral disorders in pediatric epilepsy: unmet psychiatric need. *Epilepsia* 2003;44:591-597.
21. Baker GA. Depression and suicide in adolescents with epilepsy. *Neurology* 2006;66:S5-S12.
22. Hesdorffer DC, Hauser WA, Olafsson E, Ludvigsson P, Kjartansson O. Depression and suicide attempt as risk factors for incident unprovoked seizures. *Ann Neurol* 2006;59:35-41.
23. Hesdorffer DC, Hauser WA, Annegers JF, Cascino G. Major depression is a risk factor for seizures in older adults. *Ann Neurol* 2000;47:246-249.
24. Jones JE, Hermann BP, Woodard JL, et al. Screening for major depression in epilepsy with common self-report depression inventories. *Epilepsia* 2005;46:731-735.
25. Kanner AM. Depression in epilepsy: a neurobiologic perspective. *Epilepsy Curr* 2005;5:21-27.
26. Victoroff JI, Benson F, Grafton ST, Engel J Jr., Mazziotta JC. Depression in complex partial seizures. Electroencephalography and cerebral metabolic correlates. *Arch Neurol* 1994;51:155-163.
27. Mendez MF, Grau R, Doss RC, Taylor JL. Schizophrenia in epilepsy: seizure and psychosis variables. *Neurology* 1993;43:1073-1077.
28. Quiske A, Helmstaedter C, Lux S, Elger CE. Depression in patients with temporal lobe epilepsy is related to mesial temporal sclerosis. *Epilep Res* 2000;39:121-125.
29. Barraclough BM. The suicide rate of epilepsy. *Acta Psychiatr Scand* 1987;76:339-345.
30. Mula M, Trimble MR, Sander JW. The role of hippocampal sclerosis in topiramate-related depression and cognitive deficits in people with epilepsy. *Epilepsia* 2003;44:1573-1577.
31. Spencer SS. Neural networks in human epilepsy: evidence of and implications for treatment. *Epilepsia* 2002;43:219-227.
32. Bonilha L, Rorden C, Castellano G, Cendes F, Li LM. Voxel-based morphometry of the thalamus in patients with refractory medial temporal lobe epilepsy. *Neuroimage* 2005;25:1016-1021.
33. Riederer F, Lanzenberger R, Kaya M, Prayer D, Serles W, Baumgartner C. Network atrophy in temporal lobe epilepsy: a voxel-based morphometry study. *Neurology* 2008;71:419-425.
34. Keller SS, Roberts N. Voxel-based morphometry of temporal lobe epilepsy: an introduction and review of the literature. *Epilepsia* 2008;49:741-757.
35. Price JL, Drevets WC. Neurocircuitry of mood disorders. *Neuropsychopharmacology* 2010;35:192-216.
36. King D, Spencer SS, McCarthy G, Luby M, Spencer DD. Bilateral hippocampal atrophy in medial temporal lobe epilepsy. *Epilepsia* 1995;36:905-910.
37. Watson C, Jack CR Jr., Cendes F. Volumetric magnetic resonance imaging. Clinical applications and contributions to the understanding of temporal lobe epilepsy. *Arch Neurol* 1997;54:1521-1531.
38. Watson C, Cendes F, Fuerst D, et al. Specificity of volumetric magnetic resonance imaging in detecting hippocampal sclerosis. *Arch Neurol* 1997;54:67-73.
39. Ashburner J, Friston KJ. Voxel-based morphometry--the methods. *Neuroimage* 2000;11:805-821.
40. Keller SS, Mackay CE, Barrick TR, Wiesmann UC, Howard MA, Roberts N. Voxel-based morphometric comparison of hippocampal and extrahippocampal abnormalities in patients with left and right hippocampal atrophy. *Neuroimage* 2002;16:23-31.
41. Keller SS, Wiesmann UC, Mackay CE, Denby CE, Webb J, Roberts N. Voxel based morphometry of grey matter abnormalities in patients with medically intractable temporal lobe epilepsy: effects of side of seizure onset and epilepsy duration. *J Neurol Neurosurg Psychiatry* 2002;73:648-655.
42. Bernasconi N, Duchesne S, Janke A, Lerch J, Collins DL, Bernasconi A. Whole-brain voxel-based statistical analysis of gray matter and white matter in temporal lobe epilepsy. *Neuroimage* 2004;23:717-723.
43. Bonilha L, Rorden C, Castellano G, et al. Voxel-based morphometry reveals gray matter network atrophy in refractory medial temporal lobe epilepsy. *Arch Neurol* 2004;61:1379-1384.
44. Butler T, Blackmon K, McDonald CR, et al. Cortical thickness abnormalities associated with depressive symptoms in temporal lobe epilepsy. *Epilepsy Behav* 2012;23:64-67.
45. Yasuda CL, Morita ME, Alessio A, et al. Relationship between environmental factors and gray matter atrophy in refractory MTL. *Neurology* 2010;74:1062-1068.
46. Coan AC, Appenzeller S, Bonilha L, Li LM, Cendes F. Seizure frequency and lateralization affect progression of atrophy in temporal lobe epilepsy. *Neurology* 2009;73:834-842.
47. Bonilha L, Rorden C, Appenzeller S, Coan AC, Cendes F, Li LM. Gray matter atrophy associated with duration of temporal lobe epilepsy. *Neuroimage* 2006;32:1070-1079.
48. Bonilha L, Alessio A, Rorden C, et al. Extrahippocampal gray matter atrophy and memory impairment in patients with medial temporal lobe epilepsy. *Hum Brain Mapp* 2007;28:1376-1390.
49. Focke NK, Thompson PJ, Duncan JS. Correlation of cognitive functions with voxel-based morphometry in patients with hippocampal sclerosis. *Epilepsy Behav* 2008;12:472-476.
50. Sheline YI, Wang PW, Gado MH, Csernansky JG, Vannier MW. Hippocampal atrophy in recurrent major depression. *Proc Natl Acad Sci USA* 1996;93:3908-3913.
51. Sheline YI, Sanghavi M, Mintun MA, Gado MH. Depression duration but not age predicts hippocampal volume loss in medically healthy women with recurrent major depression. *J Neurosci* 1999;19:5034-5043.
52. Sheline YI, Gado MH, Kraemer HC. Untreated depression and hippocampal volume loss. *Am J Psychiatry* 2003;160:1516-1518.
53. Bremner JD, Narayan M, Anderson ER, Staib LH, Miller HL, Charney DS. Hippocampal volume reduction in major depression. *Am J Psychiatry* 2000;157:115-118.
54. Sheline YI. Neuroimaging studies of mood disorder effects on the brain. *Biol Psychiatry*. 2003;54:338-52.
55. Phelps EA, LeDoux JE. Contributions of the amygdala to emotion processing: from animal models to human behavior. *Neuron* 2005;48:175-187.
56. Hamilton JP, Siemer M, Gotlib IH. Amygdala volume in major depressive disorder: a meta-analysis of magnetic resonance imaging studies. *Mol Psychiatry* 2008;13:993-1000.

57. Bora E, Fornito A, Pantelis C, Yücel M. Gray matter abnormalities in Major Depressive Disorder: a meta-analysis of voxel based morphometry studies. *J Affect Disord* 2012;138:9-18.
58. Brunoni AR, Lopes M, Fregni F. A systematic review and meta-analysis of clinical studies on major depression and BDNF levels: implications for the role of neuroplasticity in depression. *Int J Neuropsychopharmacol* 2008;11:1169-1180.
59. Lavretsky H, Ballmaier M, Pham D, Toga A, Kumar A. Neuroanatomical characteristics of geriatric apathy and depression: a magnetic resonance imaging study. *Am J Geriatr Psychiatry* 2007;15:386-394.
60. Cascino GD, Jack CR Jr., Parisi JE, et al. Magnetic resonance imaging-based volume studies in temporal lobe epilepsy: pathological correlations. *Ann Neurol* 1991;30:31-36.
61. Baxendale SA, Thompson PJ, Duncan JS. Epilepsy & depression: the effects of comorbidity on hippocampal volume-a pilot study. *Seizure* 2005;14:435-438.
62. Mueller SG, Laxer KD, Schuff N, Weiner MW. Voxel-based T2 relaxation rate measurements in temporal lobe epilepsy (TLE) with and without mesial temporal sclerosis. *Epilepsia* 2007;48:220-228.
63. Richardson EJ, Griffith HR, Martin RC, et al. Structural and functional neuroimaging correlates of depression in temporal lobe epilepsy. *Epilepsy Behav* 2007;10:242-249.
64. Tebartz van Elst L, Woermann FG, Lemieux L, Trimble MR. Amygdala enlargement in dysthymia-a volumetric study of patients with temporal lobe epilepsy. *Biol Psychiatry* 1999;46:1614-1623.
65. Tebartz van Elst L, Woermann F, Lemieux L, Trimble MR. Increased amygdala volumes in female and depressed humans. A quantitative magnetic resonance imaging study. *Neurosci Lett* 2000;281:103-106.
66. Frodl T, Meisenzahl EM, Zetzsche T, et al. Hippocampal changes in patients with a first episode of major depression. *Am J Psychiatry* 2002;159:1112-1118.
67. Drevets WC. Neuroimaging studies of mood disorders. *Biol Psychiatry* 2000;48:813-829.
68. Vyas A, Mitra R, Shankaranarayana Rao BS, Chattarji S. Chronic stress induces contrasting patterns of dendritic remodeling in hippocampal and amygdaloid neurons. *J Neurosci* 2002;22:6810-6818.
69. Woermann FG, van Elst LT, Koeppe MJ, et al. Reduction of frontal neocortical grey matter associated with affective aggression in patients with temporal lobe epilepsy: an objective voxel by voxel analysis of automatically segmented MRI. *J Neurol Neurosurg Psychiatry* 2000;68:162-169.
70. Blumer D, Montouris G, Davies K. The interictal dysphoric disorder: recognition, pathogenesis, and treatment of the major psychiatric disorder of epilepsy. *Epilepsy Behav* 2004;5:826-840.
71. Salgado PC, Yasuda CL, Cendes F. Neuroimaging changes in mesial temporal lobe epilepsy are magnified in the presence of depression. *Epilepsy Behav* 2010;19:422-427.
72. Phillips ML, Drevets WC, Rauch SL, Lane R. Neurobiology of emotion perception II: Implications for major psychiatric disorders. *Biol Psychiatry* 2003;54:515-528.
73. de Azevedo-Marques Périco C, Duran FL, Zanetti MV, et al. A population-based morphometric MRI study in patients with first-episode psychotic bipolar disorder: comparison with geographically matched healthy controls and major depressive disorder subjects. *Bipolar Disord* 2011;13:28-40.