

The extracisternal approach in vestibular schwannoma surgery and facial nerve preservation

A abordagem extracisternal na cirurgia de schwannoma vestibular e preservação do nervo facial

Eduardo A. S. Vellutini^{1,2}, André Beer-Furlan^{1,3}, Roger S. Brock^{1,3}, Marcos Q. T. Gomes^{1,3}, Aldo Stamm^{1,4}, Oswaldo Laercio M. Cruz^{1,5}

ABSTRACT

The classical surgical technique for the resection of vestibular schwannomas (VS) has emphasized the microsurgical anatomy of cranial nerves. We believe that the focus on preservation of the arachnoid membrane may serve as a safe guide for tumor removal. **Method:** The extracisternal approach is described in detail. We reviewed charts from 120 patients treated with this technique between 2006 and 2012. Surgical results were evaluated based on the extension of resection, tumor relapse, and facial nerve function. **Results:** Overall gross total resection was achieved in 81% of the patients. The overall postoperative facial nerve function House-Brackmann grades I-II at one year was 93%. There was no recurrence in 4.2 years mean follow up. **Conclusion:** The extracisternal technique differs from other surgical descriptions on the treatment of VS by not requiring the identification of the facial nerve, as long as we preserve the arachnoid envelope in the total circumference of the tumor.

Keywords: arachnoid membrane, facial nerve, surgery, vestibular schwannoma, acoustic neurinoma.

RESUMO

A técnica cirúrgica clássica para ressecção de schwannomas vestibulares enfatiza a anatomia microcirúrgica dos nervos cranianos. Acreditamos que o foco na preservação da membrana aracnóide pode servir como parâmetro seguro para a remoção do tumor. **Método:** A abordagem extracisternal é descrita em detalhe. Analisamos o prontuário de 120 pacientes tratados com esta técnica entre 2006 e 2012. Os resultados cirúrgicos foram baseados em extensão de ressecção, recorrência tumoral e função do nervo facial. **Resultados:** Ressecção total foi obtida em 81% dos pacientes. O resultado global da função do nervo facial (House-Brackmann graus I-II) após um ano da cirurgia foi de 93%. Não houve recidiva em um seguimento médio de 4,2 anos. **Conclusão:** A técnica extracisternal difere de outras descrições cirúrgicas no tratamento de schwannoma vestibular pois não requer a identificação do nervo facial, contanto que o plano de aracnóide seja preservado em toda circunferência do tumor.

Palavras-chave: membrana aracnóide, nervo facial, cirurgia, schwannoma vestibular, neurinoma do acústico.

Facial nerve injury is a common complication in the treatment of vestibular schwannomas (VS) and its associated facial muscle palsy has a great impact in patients' quality of life¹. This is the reason why functional preservation of the facial nerve is sought when managing VS with either radiosurgery or microsurgery. Several factors have been correlated with worse facial nerve function outcomes, including older patients, large tumors, and preoperative facial nerve

function^{2,3,4}. Although careful facial nerve dissection is pursued, anatomical preservation of the facial nerve is not synonymous of normal function^{5,6,7}. Intraoperative monitoring of the facial nerve is the key for optimal facial nerve preservation, even though not all patients' clinical courses correlate with their intraoperative electrophysiological result^{6,8}.

The classical descriptions of the surgical technique for VS removal has constantly emphasized the microsurgical

¹Clínica DFVneuro, Sao Paulo SP, Brazil;

²Departamento de Neurocirurgia, Hospital do Servidor Público Estadual, Sao Paulo SP, Brazil;

³Departamento de Neurocirurgia, Hospital das Clínicas, Faculdade de Medicina, Universidade de São Paulo, Sao Paulo SP, Brazil;

⁴Centro de Otorrino e Fonoaudiologia de São Paulo, Sao Paulo SP, Brazil;

⁵Universidade Federal de São Paulo, Sao Paulo SP, Brazil.

Correspondence: André Beer-Furlan; Rua Alves Guimaraes, 643 / ap.132; 05410-001 São Paulo SP, Brasil; E-mail: beerfurlan@uol.com.br

Conflict of interest: There is no conflict of interest to declare.

Received 08 June 2014; Received in final form 06 August 2014; Accepted 26 August 2014.

anatomy in order to ease the identification of the cranial nerves and its relationship to the tumor capsule at the cerebellopontine angle (CPA). There are four classical steps in the surgical removal of acoustic tumors: (1) intracapsular tumor removal; (2) identification of the facial and cochlear nerves at the internal auditory canal (IAC); (3) nerve identification and dissection medially next to the brainstem; and (4) complete removal of the tumor under direct vision of those structures.

In the present study, we describe the technical nuances of the extracisternal approach for removal of VS, discuss its advantage, and report our results. Based on the relationship of the tumor with the complex arachnoid membranes at the CPA, we propose a change of the paradigm of the surgery. Instead of identifying and using the facial nerve as a surgical anatomical landmark, we perform the dissection inside the tumor preserving an arachnoid envelope that protects facial and cochlear nerves during tumor removal. The goal is to obtain an arachnoid veil at the CPA after the tumor removal, where the facial nerve is barely seen through it. The lesser exposure of the facial nerve the better is the functional result.

METHOD

The extracisternal approach was described in detail in a retrosigmoid craniotomy. We retrospectively reviewed charts from 120 patients treated for VS with this technique by the same neurosurgeon (EASV) at private hospitals in Sao Paulo (Brazil) between 2006 and 2012. Patients with documented neurofibromatosis type II, preoperative facial nerve palsy and any previous treatment with microsurgery or radiosurgery were excluded from the analysis.

Preoperative evaluation included complete neurological examination, brain magnetic resonance imaging (MRI) and audiometry. Tumor size was designated based on the maximum extra-meatal diameter. Surgery was indicated in patients with tumor size greater than 20 mm independently of age, patients younger than 50 years old with any tumor size, and in patients with age greater than 50 years old with increasing tumor size while on the “wait and scan” management. The retrosigmoid suboccipital craniotomy was the preferred approach and routine intraoperative neurophysiologic monitoring was performed.

We divided patients in five grades according to the extra-meatal tumor size (0-10 mm, 11-20 mm, 21-30 mm, 31-40 mm and >40mm)⁹. Surgical results were evaluated based on the extension of resection, tumor relapse, and facial nerve function.

Gross total resection (GTR) was designated when no tumor was knowingly left behind; near-total resection (NTR) was applied when a tumor remnant smaller than 5x5x2 mm was intentionally left in situ to lessen neurological morbidity; and subtotal removal (STR) was used

when anything more was left behind¹⁰. The tumor relapse was evaluated with follow up brain MRI at two months, one year, two years and five years after the surgery. Significant regrowth was defined as residual tumor fragment expansion of at least 5 mm from the postoperative size. Not all patients had a five years follow up due to the recent procedures, however all patients have at least one-year follow up for the evaluation of tumor recurrence and facial nerve function. Any postoperative complications were noted.

Facial nerve function was analyzed at the immediate and at one-year postoperative period according to the House-Brackmann (HB) classification¹¹. HB I-II were defined as good outcome, HB III as regular outcome and HB IV-V-VI as poor outcome.

RESULTS

Surgical technique

The principles of the extracisternal dissection are reproducible in any surgical approach for VS (suboccipital retrosigmoid or translabyrinthine). As the retrosigmoid craniotomy was the most commonly used, it is the chosen approach for the technique description.

The patient is positioned in supine with rotated shoulders 30 degrees and the head tilted 45 degrees to the contralateral side. After a classical suboccipital craniotomy limited laterally by the sigmoid sinus and superiorly by the transverse sinus, the dura is opened in a laterally convexed “C” shape. Drainage of cerebrospinal fluid (CSF) from basal cisterns facilitates tumor exposure in the CPA and visibility of the posterior wall of IAC with only mild cerebellar retraction.

The IAC is initially opened with a cutting burr after displacing of the dura, then a diamond burr is used to extent it laterally to the limit of the tumor. In order to prevent hearing loss, the limits of the vestibular duct are respected. When the patient’s anatomy is not favorable for an extensive bone removal without entering the bone labyrinth, a 70 degrees oto-endoscope is used to visualize the fundus of the IAC. During removal of posterior lip of the IAC, one should be aware of a high jugular bulb that sometimes disturbs the exposition. An arterial loop of the AICA can also be adherent to the dura and must be dislocated with the dural flap in order to have a complete tumor exposure.

Tumor removal may be initiated at either the CPA or at the ICA, depending on the tumor size and its extension into the IAC. It is important to postpone to the end of the surgery the removal of the portion near the porus acusticus, where there is greater adherence between the tumor and the cranial nerves.

After opening of the dura and complete the tumor exposition in the IAC, a gentle debulking with an ultrasonic surgical aspirator allows better handling of the VS in the narrow space. With a dissector, tumor is separated from the

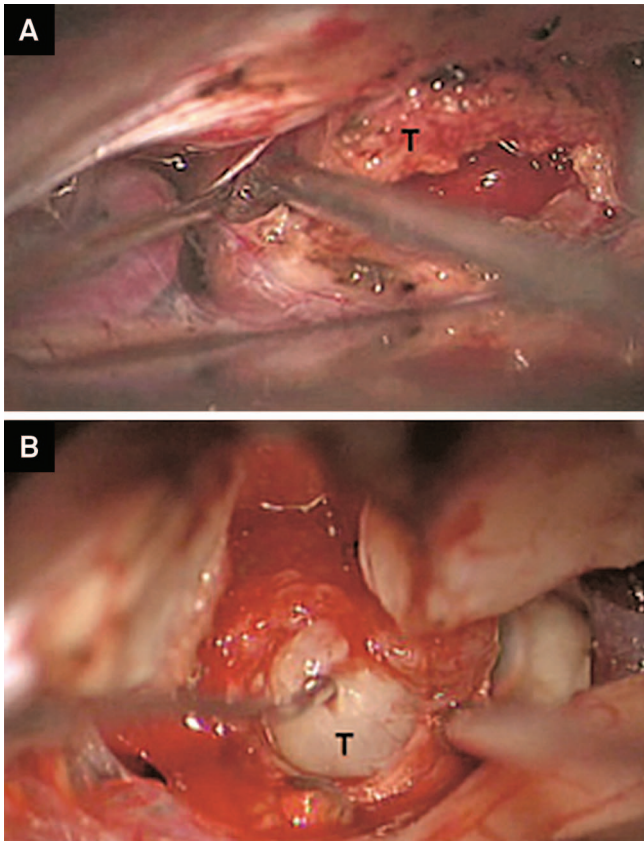


Figure 1. (A) The dissection begins near the porus, where the arachnoid is thicker and the dissection plane between tumor (T) and the arachnoid membrane is easier found; (B) The tumor capsule remains opaque and devascularized due to the displacement of the vessels with the arachnoid membrane.

arachnoid that involves the nerves, and pulled in lateral to medial direction towards the porus acusticus.

Once the IAC portion of the VS is removed, the dissection takes part in the CPA. This is an important surgical step of the extracisternal approach and depends on the identification of the correct arachnoid plane of dissection. Exposure of the posterior capsule is achieved retracting the arachnoid that continues with the cerebellar parenchyma. It must be noted that the capsule, at this moment,

is still covered with a glittering membrane that represents the arachnoid that follows the tumor in the CPA. If we remove the tumor lateral to this membrane, we will come across the neural structures in the CPA cistern, with no arachnoid protection.

We proceed with tumor debulking to ease the dissection in its whole circumference from the arachnoid membrane. The goal is to obtain a thin capsule that can be bended and separated from the correct arachnoid plane. Electrophysiological monitoring and surgical ultrasound aspirator are used to avoid traction of the nerves during tumor manipulation.

In our experience, it is easier to find the dissection plane between tumor and arachnoid at the posterior region near the porus, in the superior or inferior portions, where the arachnoid is thicker or the vestibular nerves may be used as a guide. Part of this membrane is formed by the vestibular nerves that can be identified in smaller tumors. Vessels are normally displaced anteriorly with the arachnoid membrane, in a way that the tumor capsule remains opaque and devascularized (Figure 1). Once the correct plane is achieved, a blunt dissection with a micro-suction tube with low power aspiration is performed until there is only a small residual tumor anterior to the porus. In large VS, the same strategy is used and progressed in a stepwise manner around the tumor, focusing on keeping the plane of dissection. Specifically in large tumors, the membrane can be disrupted during removal due to tight adhesions in some parts of the capsule. Changing the direction of dissection and continuing with the same technique prevents from losing the correct plane. A sharp dissection is recommended near the porus acusticus, due to an arachnoid duplication and greater adherence of the tumor.

In the classical technique, the dissection is done in an inferior to superior direction to not cross with the facial nerve. In our technique, the dissection is easier performed and focused where the membrane is looser. The tumor relationship with the facial nerve is not our main concern and is not the focus of the procedure. In most cases the nerve is displaced anteriorly with the arachnoid membrane and protected by it (Figure 2).

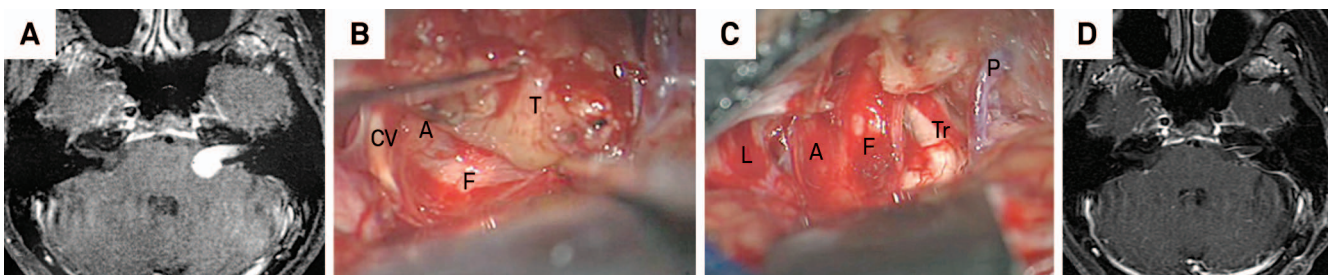


Figure 2. (A) VS in the left CPA; (B) The tumor (T) is dissected from the arachnoid (A) and the facial (F) and cochleo-vestibular (CV) nerves are barely seen through the membrane; (C) end result with the nerves protected by the arachnoid; and (D) Postoperative MRI demonstrating no residual tumor. F: Facial nerve; Tr: Trigeminal nerve; A: Arachnoid, P: Petrosal vein; L: Lower cranial nerves.

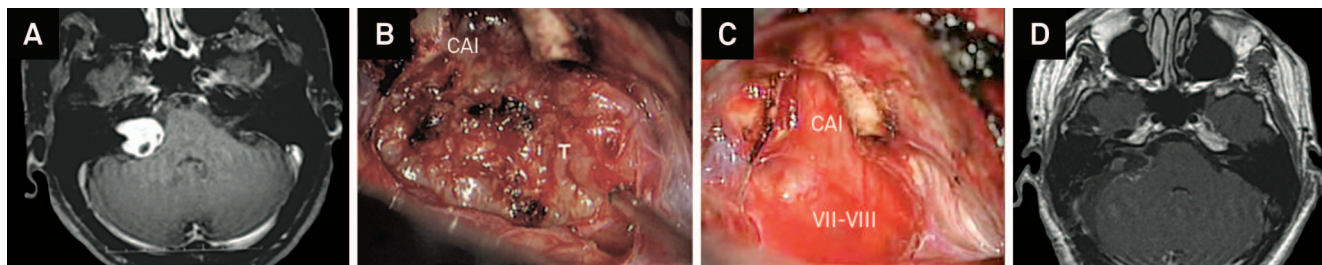


Figure 3. (A) VS in the right CPA; (B) Exposure of the posterior portion of the tumor (T) after opening of the internal auditory canal (CAI); (C) The arachnoid envelop that protects the cranial nerves during dissection seen after total tumor removal; and (D) Postoperative MRI demonstrating no residual tumor.

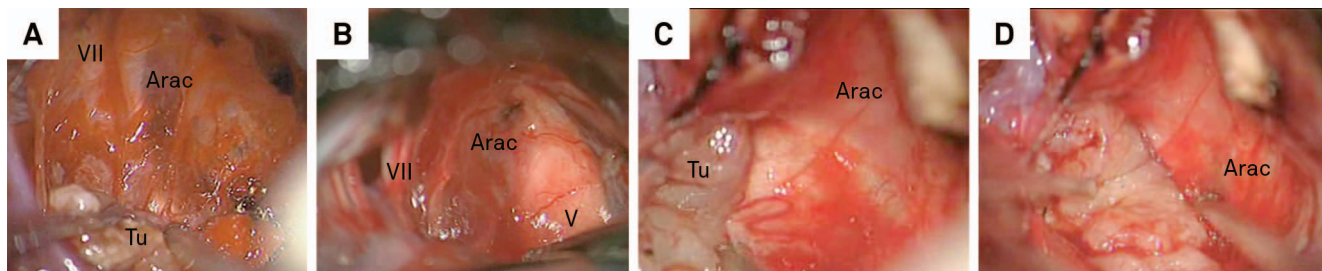


Figure 4. Some examples of arachnoid dissection in vestibular schwannoma surgery. Arac: Arachnoid; Tu: Tumor; VII: Facial nerve; V: Trigeminal nerve.

After total removal, an envelope of arachnoidal sheath covering the nerves in the CPA cistern can be identified (Figures 3 and 4). In order to check for any residual tumor or any opening of mastoid air cells, the fundus of the IAC is inspected with a 70-degree oto-endoscope and filled with muscle and fibrin glue. After dural closure, a vascularized flap from sternocleidomastoid muscle is used to close mastoid air cells that were opened during craniotomy in order to prevent CSF fistula.

Patients characteristics

Of the 120 patients treated, 8 patients were excluded based on criteria: four patients with neurofibromatosis type II, one patient previously treated with radiosurgery, and three patients previously operated by other surgeons with facial nerve palsy.

The extracisternal microsurgical resection was the first treatment of the remaining 112 patients. The age range was 16-80 years at the time of surgery (average 46 years), extrameatal tumor sizes ranged from 5 to 45 mm (average

22 mm), and follow-up durations ranged from 1.0 to 7.4 years (average 4.2 years).

Tumor removal

The 112 patients treated with surgery as first therapy were divided according to the extra-meatal tumor size: Class 1 (0-10 mm) with 9 patients (8.04%), Class 2 (11-20 mm) with 52 patients (46.43%), Class 3 (21-30 mm) with 33 patients (29.46%), Class 4 (31-40 mm) with 11 patients (9.82%) and Class 5 (>40 mm) with 7 patients (6.25%).

The extent of tumor resection was classified as GTR, NTR or STR. In Class 1, GTR was achieved in 100% of the patients. In Class 2, 96% of GTR and 4% of NTR was achieved. Class 3 consisted in 79% of GTR, 18% of NTR and 3% of STR. Class 4 patients had a 55% of GTR, 36% of NTR and 9% of STR. There were no GTR in Class 5 patients, with 86% of NTR and 14% of STR. Overall GTR was achieved in 91 (81%) patients, NTR obtained in 18 (16%) patients and STR in 3 (3%) patients (Table 1).

Table 1. Extent of tumor resection reported in percentages and number of patients of each tumor class.

	Class 1	Class 2	Class 3	Class 4	Class 5	Overall
GTR	100% (9)	96% (50)	79% (26)	55% (6)	-	81% (91)
NTR	-	4% (2)	18% (6)	36% (4)	86% (6)	16% (18)
STR	-	-	3% (1)	9% (1)	14% (1)	3% (3)

GTR: gross total resection; NTR: near-total resection; STR: subtotal removal.

Table 2. Facial nerve outcomes at one year, based on the House-Brackmann classification.

	Class 1	Class 2	Class 3	Class 4	Class 5	Overall
Good (I-II)	100% (9)	100% (52)	88% (29)	100% (11)	43% (3)	93% (104)
Regular (III)	-	-	9% (3)	-	29% (2)	4% (5)
Poor (IV-V-VI)	-	-	3% (1)	-	29% (2)	3% (3)

Facial nerve function

At the immediate postoperative period, good outcomes (HB I-II) of facial nerve function were present in all Class 1 patients, 87% of Class 2, 64% of Class 3, 82% of Class 4 and 29% of Class 5 patients. Regular outcomes (HB III) were present in 10% of Class 2, 24% of Class 3, 9% of Class 4 and 29% of Class 5. Poor outcomes (HB IV-V) were present in 4% of Class 2, 12% of Class 3, 9% of Class 4 and 43% of Class 5 patients. There were 4 cases of postoperative delayed facial paralysis (onset usually at 8 days after surgery) that improved uneventfully. None of the patients presented with HB VI facial nerve dysfunction

One year after the surgery, facial nerve function improved in all groups and presented good outcomes in 100% of the cases in Classes 1 and 2 VS, 88% in Class 3, 100% in Class 4 and 43% in Class 5. Regular outcomes were present in 9% of Class 3 and 29% of Class 5. Poor outcomes were present in 3% of Class 3 and 29% of Class 5 patients. Overall, facial nerve function HB grades I and II at one year was 93% (Table 2).

Complications

We observed a few complications with variable causes ranging from incision infection to pulmonary embolism, but no deaths (Table 3). The overall CSF fistula rate was 8,9%. Since 2008, a systematic closure is performed with a sternocleidomastoid muscle flap. If we analyze the CSF fistula after the implementation of this closure technique, the rate drops to 2,7%.

DISCUSSION

The dramatic evolution of results in the VS surgery in the past decades has been credited to early diagnosis, improvement in neuro-anesthesiology, intraoperative cranial nerve monitoring and development of microsurgical techniques^{12,13,14}. However, surgeons still pursue the ideal management of VS

due to the importance of facial nerve function in the patients' quality of life¹⁵.

The knowledge of microsurgical anatomy played an important role decreasing morbidity and mortality rates. The classical surgical technique of tumor debulking and individualization of the neural structures in its most lateral and medial portions was based on the anatomical descriptions of the nerves in the internal auditory canal and on the brainstem surface. Many anatomical reports described important intraoperative references in order to facilitate the identification of the cranial nerves proximal and distal to the tumor, allowing its removal under direct vision of neural structures^{12,13,14}. Despite good anatomical knowledge, finding the proximal facial nerve may be difficult, particularly in large tumors.

The technical nuance described in this article permits removal of the tumor without a direct visualization of the facial nerve, as long as the arachnoid plane in the whole circumference of the tumor is respected. The avascular dissection plane was identified in all cases. Even in large VS, the strategy of dissection was the same but performed in a step-wise manner around the tumor. The importance of the preservation of arachnoid around the nerves in acoustic neuroma surgery has been established since Olivecrona in 1949¹⁶. However, the cisternal arachnoid membranes anatomy and its relationship with cranial nerves are controversial, especially because of the difficulty preserving the membranes on cadaveric specimens. The epiarachnoid or subarachnoid origin of VS has been subject of discussion and the presence of an arachnoid surgical plane between tumor and cranial nerves questioned by some authors^{17,18,19,20,21,22,23,24,25}. This is not what we have experienced during the surgical procedures, where the arachnoid membrane is used as a protection to preserve the facial nerve anatomically and functionally. We believe in a more complex arachnoid anatomy at CPA with multiple layers and different extension into the IAC, which needs to be further studied.

It is known that the results on VS surgery depend more on the individual surgeon's experience than on the advantages or disadvantages of a particular approach²⁶. However, it is our hypothesis that the application of the extracisternal technique may reduce the surgeons' learning curve and improve VS surgical results. The results achieved by our team with overall GTR in 81% and good facial nerve function in 93% of the patients are among the best reported in the recent literature^{6,26,27,28,29,30}. We believe that the technical

Table 3. Complications.

Complications (number)	
Class 1	none
Class 2	bulbar nerve paresis (1) - pulmonary embolism (1) - incision infection (1) - cerebellar edema (1)
Class 3	pulmonary embolism (1) - incision infection (1) - cerebellar edema (1) - hematoma (1)
Class 4	fibular nerve dysfunction (1)
Class 5	cerebellar venous infarct (1)

nuance described has a major role on the outcome due to the minimal facial nerve manipulation and mobilization.

In conclusion, the extracisternal technique differs from others, as we do not have to expose the facial nerve at the medial part of the tumor, as long as we can preserve a whole envelop of arachnoid in the total circumference of the

tumor. The best results we experienced are the cases that we cannot directly see the facial nerve after tumor removal. Better anatomical studies are required to understand the complex anatomy of the arachnoid membranes at CPA, however, this technical nuance has improved our surgical results.

References

1. Martin HC, Sethi J, Lang D, Neil-Dwyer G, Lutman ME, Yardley L. Patient-assessed outcomes after excision of acoustic neuroma: postoperative symptoms and quality of life. *J Neurosurg.* 2001;94(2):211-6. <http://dx.doi.org/10.3171/jns.2001.94.2.0211>
2. Gerganov VM, Klinge PM, Nouri M, Stieglitz L, Samii M, Samii A. Prognostic clinical and radiological parameters for immediate facial nerve function following vestibular schwannoma surgery. *Acta Neurochir (Wien).* 2009;151(6):581-7. <http://dx.doi.org/10.1007/s00701-009-0288-3>
3. Marouf R, Noudel R, Roche PH. Facial nerve outcome after microsurgical resection of vestibular schwannoma. *Prog Neurol Surg.* 2008;21:103-7. [10.1159/000156714](http://dx.doi.org/10.1159/000156714)
4. Yang I, Sughrue ME, Han SJ, Fang S, Aranda D, Cheung SW et al. Facial nerve preservation after vestibular schwannoma Gamma Knife radiosurgery. *J Neurooncol.* 2009;93:41-8. [10.1007/s11060-009-9842-3](http://dx.doi.org/10.1007/s11060-009-9842-3)
5. Carlson ML, Van Abel KM, Schmitt WR, Driscoll CL, Neff BA, Link MJ. The anatomically intact but electrically unresponsive facial nerve in vestibular schwannoma surgery. *Neurosurgery.* 2012;71(6):1125-30. <http://dx.doi.org/10.1227/NEU.0b013e318271bce3>
6. Samii M, Matthies C. Management of 1000 vestibular schwannomas (acoustic neuromas): the facial nerve: preservation and restitution of function. *Neurosurgery.* 1997;40(4):684-95. <http://dx.doi.org/10.1097/00006123-199704000-00006>
7. Tamura M, Murata N, Hayashi M, Roche PH, Régis J. Facial nerve function insufficiency after radiosurgery versus microsurgery. *Prog Neurol Surg.* 2008;21:108-18. <http://dx.doi.org/10.1159/000156718>
8. Youssef AS, Downes AE. Intraoperative neurophysiological monitoring in vestibular schwannoma surgery: advances and clinical implications. *Neurosurg Focus.* 2009;27(4):E9. <http://dx.doi.org/10.3171/2009.8.focus09144>
9. Kanzaki J, Tos M, Sanna M, Moffat DA, Monsell EM, Berliner KI. New and modified reporting systems from the consensus meeting on systems for reporting results in vestibular schwannoma. *Otol Neurotol.* 2003;24(4):642-8. <http://dx.doi.org/10.1097/00129492-200307000-00019>
10. Bloch DC, Oghalai JS, Jackler RK, Osofsky M, Pitts LH. The fate of the tumor remnant after less-than-complete acoustic neuroma resection. *Otolaryngol Head Neck Surg.* 2004;130(1):104-12. [http://dx.doi.org/10.1016/s0194-5998\(03\)01598-5](http://dx.doi.org/10.1016/s0194-5998(03)01598-5)
11. House JW, Brackmann DE. Facial nerve grading system. *Otolaryngol Head Neck Surg.* 1985;93(2):146-7.
12. Ciric I, Zhao JC, Rosenblatt S, Wiet R, O'Shaughnessy B. Suboccipital retrosigmoid approach for removal of vestibular schwannomas: facial nerve function and hearing preservation. *Neurosurgery.* 2005;56(3):560-70. <http://dx.doi.org/10.1227/01.neu.0000154059.34990.b8>
13. Gharabaghi A, Samii A, Koerbel A, Rosahl SK, Tatagiba M, Samii M. Preservation of function in vestibular schwannoma surgery. *Neurosurgery.* 2007;60(2 Suppl 1):124-7. <http://dx.doi.org/10.1227/01.neu.0000249245.10182.0d>
14. Malis LI. Nuances in acoustic neuroma surgery. *Neurosurgery.* 2001;49(2):337-41. <http://dx.doi.org/10.1227/00006123-200108000-00015>
15. Haque R, Wojtasiewicz TJ, Gigante PR, Attiah MA, Huang B, Isaacson SR et al. Efficacy of facial nerve-sparing approach in patients with vestibular schwannomas. *J Neurosurg.* 2011;115(5):917-23. <http://dx.doi.org/10.3171/2011.7.jns101921>
16. Olivercrona H. Acoustic tumours. *J Neurol Psychiat.* 1940;3(2):141-6. [10.1136/jnnp.3.2.141](http://dx.doi.org/10.1136/jnnp.3.2.141)
17. Kohno M, Sato H, Sora S, Miwa H, Yokoyama M. Is an acoustic neuroma an epiarachnoid or subarachnoid tumor? *Neurosurgery.* 2011;68(4):1006-16. <http://dx.doi.org/10.1227/NEU.0b013e318208f37f>
18. Kuo TC, Jackler RK, Wong K, Blevins NH, Pitts LH. Are acoustic neuromas encapsulated tumors? *Otolaryngol Head Neck Surg.* 1997;117(6):606-9. [http://dx.doi.org/10.1016/s0194-5998\(97\)70040-8](http://dx.doi.org/10.1016/s0194-5998(97)70040-8)
19. Lescanne E, Francois P, Bakhos D, Velut S, Robier A, Pollak A. Vestibular schwannoma dissection of the tumor and arachnoid duplication. *Otol Neurotol.* 2008;29(7):989-94. <http://dx.doi.org/10.1097/MAO.0b013e3181845812>
20. Lescanne E, Velut S, Lefrancq T, Destrieux C. The internal acoustic meatus and its meningeal layers: a microanatomical study. *J Neurosurg.* 2002;97(5):1191-7. [10.3171/jns.2002.97.5.1191](http://dx.doi.org/10.3171/jns.2002.97.5.1191)
21. Luetje CM, Whittaker CK, Callaway LA, Veraga G. Histological acoustic tumor involvement of the VIIIth nerve and multicentric origin in the VIIIth nerve. *Laryngoscope.* 1983;93(9):1133-9. <http://dx.doi.org/10.1288/00005537-198309000-00004>
22. Neely JG. Gross and microscopic anatomy of the eighth cranial nerve in relationship to the solitary schwannoma. *Laryngoscope.* 1981;91(9):1512-31. <http://dx.doi.org/10.1288/00005537-198109000-00015>
23. Ohata K, Tsuyuguchi N, Morino M, Takami T, Goto T, Hakuba A et al. A hypothesis of epiarachnoidal growth of vestibular schwannoma at the cerebello-pontine angle: surgical importance. *J Postgrad Med.* 2002;48(4):253-8.
24. Rhoton A L Jr. The posterior fossa cisterns. *Neurosurgery* 2000;47(Suppl):S287-97.
25. Yasargil MG, Smith RD, Gasser JC. Microsurgical approach to acoustic neurinoma. In Kraysenbuhl H, editor. *Advances and technical standards in neurosurgery.* Wien: Springer; 1977. p. 94-129.
26. Samii M, Gerganov V, Samii A. Improved preservation of hearing and facial nerve function in vestibular schwannoma surgery via the retrosigmoid approach in a series of 200 patients. *J Neurosurg.* 2006;105(4):527-35. <http://dx.doi.org/10.3171/jns.2006.105.4.527>
27. Brackmann DE, Cullen RD, Fisher LM. Facial nerve function after translabrynthine vestibular schwannoma surgery. *Otolaryngol Head Neck Surg.* 2007;136(5):773-7. [10.1016/j.otohns.2006.10.009](http://dx.doi.org/10.1016/j.otohns.2006.10.009)
28. Briggs RJ, Luxford WM, Atkins JS Jr, Hitselberger WE. Translabrynthine removal of large acoustic neuromas. *Neurosurgery.* 1994;34(5):785-90. <http://dx.doi.org/10.1227/00006123-199405000-00001>
29. Bruzzo M, Broder L, Chays A, Magnan J. Our current results with acoustic neurinoma surgery. *Ann Otolaryngol Chir Cervicofac.* 2000;117(2):110-7.
30. Colletti V, Fiorino FG. Retrosigmoid-transmeatal en bloc removal of small to medium-sized acoustic neuromas. *Otolaryngol Head Neck Surg.* 1999;120(1):122-8. [http://dx.doi.org/10.1016/s0194-5998\(99\)70382-7](http://dx.doi.org/10.1016/s0194-5998(99)70382-7)