

Is transcranial sonography useful for diagnosing Parkinson's disease in clinical practice?

O ultrassom transcraniano é útil para o diagnóstico da doença de Parkinson na prática clínica?

Talyta Cortez Grippe^{1,2}, Nasser Allam², Pedro Renato de Paula Brandão^{2,3}, Danilo Assis Pereira⁴, Francisco Eduardo Costa Cardoso⁵, Ana Carolina Rodrigues Aguiar², Iruena Moraes Kessler¹

ABSTRACT

Transcranial sonography (TCS) is an emerging ancillary examination for diagnosing Parkinson's disease (PD). **Objective:** To evaluate TCS features in patients with PD and its mimics, and establish their accuracy in predicting the final clinical diagnosis after follow-up. **Methods:** We retrospectively studied 85 patients with an initial clinical suspicion of PD, atypical parkinsonism or essential tremor, all of whom underwent TCS. Two specialists reviewed the follow-up clinical visit records and determined the final clinical diagnosis. The accuracy analysis of the TCS was determined using Bayesian statistical methods. **Results:** The finding of substantia nigra hyperechogenicity (> 20 mm²) showed high sensitivity (93.4%) and specificity (86.6%). The positive likelihood ratio showed 6.93-fold greater odds for diagnosing PD than an alternative condition when this finding was present. **Conclusions:** This study revealed the practical usefulness of TCS in differentiating PD from its prevalent mimics when the clinical diagnosis was initially unclear.

Keywords: Parkinson's disease; parkinsonian disorders; essential tremor; ultrasonography; diagnostic techniques and procedures.

RESUMO

A ultrassonografia transcraniana (UTC) é um exame complementar para diagnóstico de doença de Parkinson (DP). **Objetivo:** Avaliar as características da UTC em pacientes com DP e seus diagnósticos diferenciais e estabelecer a precisão desse exame para o diagnóstico clínico de DP após seguimento. **Métodos:** Avaliou-se retrospectivamente 85 pacientes com suspeita clínica inicial de DP, parkinsonismo atípico (PA) ou tremor essencial (TE), todos submetidos a UTC. Um consenso de dois especialistas determinou o diagnóstico clínico final após revisar os registros médicos das consultas de seguimento. A precisão do UTC foi calculada usando métodos estatísticos Bayesianos. **Resultados:** O achado de hiperecogenicidade da substância negra (> 20 mm²) mostrou alta sensibilidade (93,4%) e especificidade (86,6%). A razão de verossimilhança positiva mostra 6.93 vezes mais chances de diagnosticar DP do que uma condição alternativa, se o achado estiver presente. **Conclusões:** Este estudo demonstra a utilidade prática do UTC na diferenciação de DP de condições clínicas similares quando o diagnóstico clínico é inicialmente pouco claro.

Palavras-chave: doença de Parkinson; transtornos parkinsonianos; tremor essencial; ultrassonografia; técnicas e procedimentos diagnósticos.

The diagnosis of idiopathic Parkinson's disease (PD) remains a challenge. Although the clinical opinion of experts remains the gold standard¹, only 53-75% of their diagnoses agree with the definite pathological diagnosis; the major misdiagnoses being essential tremor (ET) and atypical parkinsonism (AP)^{2,3}.

As suggested by the European Federation of Neurological Societies/Movement Disorder Society – European Section recommendations, ancillary examinations should be effective

in establishing the differential diagnosis of PD⁴. Imaging and biomarkers are urgently required to improve the certainty of the current unsatisfactory clinical parameters⁵.

Transcranial sonography (TCS) is used to evaluate the echogenicity of the midbrain and basal ganglia. The sensitivity of TCS is high (90%) in discriminating PD cases from not only a healthy control group^{6,7,8} but also major PD mimics, such as ET^{9,10} and AP¹¹. The TCS parameters have been standardized in diverse

¹Universidade de Brasília, Faculdade de Medicina, Brasília DF, Brasil;

²Hospital de Base do Distrito Federal, Centro de Referência em Parkinson e Distúrbios do Movimento, Brasília DF, Brasil;

³Câmara dos Deputados, Departamento Médico, Brasília DR, Brasil;

⁴Instituto Brasileiro de Neuropsicologia e Ciências Cognitivas, Brasília DF, Brasil;

⁵Universidade Federal de Minas Gerais, Departamento de Clínica Médica, Unidade de Distúrbios do Movimento, Belo Horizonte MG, Brasil.

Correspondence: Talyta Cortez Grippe; SQS 103, Bloco K, apto 210; 70342-110 Brasília DF, Brasil; E-mail: talytagrippe@gmail.com

Conflicts of Interest: There is no conflict of interest to declare.

Received 30 January 2018; Received in final form 06 April 2018; Accepted 20 April 2018.



ultrasound models¹², replicated with good inter-investigator reproducibility^{7,13}, and reproduced in distinct populations^{14,15}. The association between substantia nigra (SN) hyperechogenicity detected by TCS and the subsequent development of PD^{8,16,17} suggests that TCS might enable early diagnosis^{16,18}.

Thus, we aimed to evaluate the diagnostic performance of TCS, specifically in patients with an initially-undefined etiology for parkinsonian motor symptoms under real clinical practice conditions, i.e., in a less-controlled setting than that of a clinical trial protocol.

METHODS

Study population

We retrospectively studied 126 patients who were consecutively evaluated in the outpatient clinic of our Movement Disorders reference center between January 2015 and June 2016. These patients presented with parkinsonian features (resting tremor, bradykinesia, postural instability or rigidity), but did not fulfill all criteria for the diagnosis of PD (the UK Brain Bank) at the initial visit. Due to the uncertainty of the diagnosis, patients were referred for a TCS examination to exclude or confirm the suspicion of idiopathic PD. Among all patients who underwent the examination during the study period, we excluded 21 patients due to suspicion of other clinical diagnoses that we did not want to evaluate in this study, such as cerebellar ataxia, Huntington's disease, dystonic tremor, and metabolic or toxic tremor¹². We also excluded 20 patients who were not able to be evaluated with TCS due to insufficient temporal bone windows, which technically limited the visualization of the midbrain contour. The local ethical standards committee approved the study.

First diagnostic hypothesis

An initial clinical suspicion was defined for each patient in order to compare the first clinical impression of the neurologist with the final diagnosis after follow-up. This initial clinical suspicion was based on the initial clinical data acquired by the physician before the TCS was performed. None of the patients had a defined clinical diagnosis at the time they underwent TCS. However, all patients had an initial clinical suspicion of PD, AP (including multiple system atrophy and progressive supranuclear palsy) or ET. We selected these groups of patients because previous studies have shown that TCS can reliably distinguish these diagnoses from PD^{9,11}. These patients would thus be the best candidates for the TCS examination in a real clinical scenario.

Clinical assessment and diagnosis

Two movement disorder experts reviewed all clinical records from at least six months of follow up after the TCS examination to determine the definitive clinical diagnosis by consensus. In addition to the UK Brain Bank criteria,

nonmotor symptoms, levodopa response, persistent asymmetry, unilateral start, hyposmia, and REM sleep behavior disorder, but not the TCS result, were used to define a patient as having PD. Medical records were also examined for general clinical criteria for Lewy body dementia, progressive supranuclear palsy, multiple system atrophy and ET^{19,20,21,22}. After the follow-up period, the patients were labeled as having ET, PD or AP if a clinical diagnosis was achieved. If clinical uncertainty regarding the diagnosis remained, the clinicians labeled the patients as having an "undefined diagnosis". In addition, if the exclusion criteria for PD (UK Brain Bank) were met and no established clinical criteria for AP or ET were present, the patients were labeled as "excluded PD". To perform between-group comparisons, the data analysis procedures combined patients with Lewy body dementia and PD into the same category - PD - as Lewy body dementia and PD are believed to be distinct clinical presentations of the same disease with the same pathological substrate but distinct anatomical distribution²⁰. The cases that certainly did not represent PD cases (namely, the AP, ET and "excluded PD" groups) were labeled altogether as the "non-PD" group for some of the analyses. The methodological process is outlined in Figure 1.

Acquisition and assessment of TCS images

We performed the TCS examinations according to the guidelines of the European Society of Neurosonology and Cerebral Hemodynamics²³. An Esaote MyLab25Gold ultrasound machine (Genoa, Italy) was used along with a 2-3.5MHz phased array transducer. The transtemporal acoustic bone window was used to assess the midbrain bilaterally, and after a 10-degree tilt of the ultrasound beam, the examiner also scanned the thalamic axial plane. The tissue equalization function and gain adjustments were used if necessary²³. Characteristic findings are shown in Figure 2.

Based on the published consensus, the SN-TCS was scored as "positive" (SN+) if the SN displayed an increased echo intensity on at least one side relative to the surrounding brainstem tissue with an area value $> 20 \text{ mm}^2$ ¹⁸; and scored as "markedly positive" with an area value $> 25 \text{ mm}^2$ ¹⁸. The largest SN planimetric value for each patient was chosen for analysis regardless of the side of the measurement. The examiner qualitatively classified the lentiform nucleus as isoechogenic (LN-) or hyperechogenic (LN+) compared with the surrounding tissues. In addition, the third ventricle (V3) and lateral ventricle widths were measured.

Statistical analysis

Due to the limited number of participants, we used Bayesian methods to analyze our data in order to improve the veracity of the results. We applied t-distribution, the Bayesian one-way ANOVA²⁴, receiver operating characteristic (ROC) curve analysis and the Bayesian test of accuracy as required by each situation and as described in the results section.

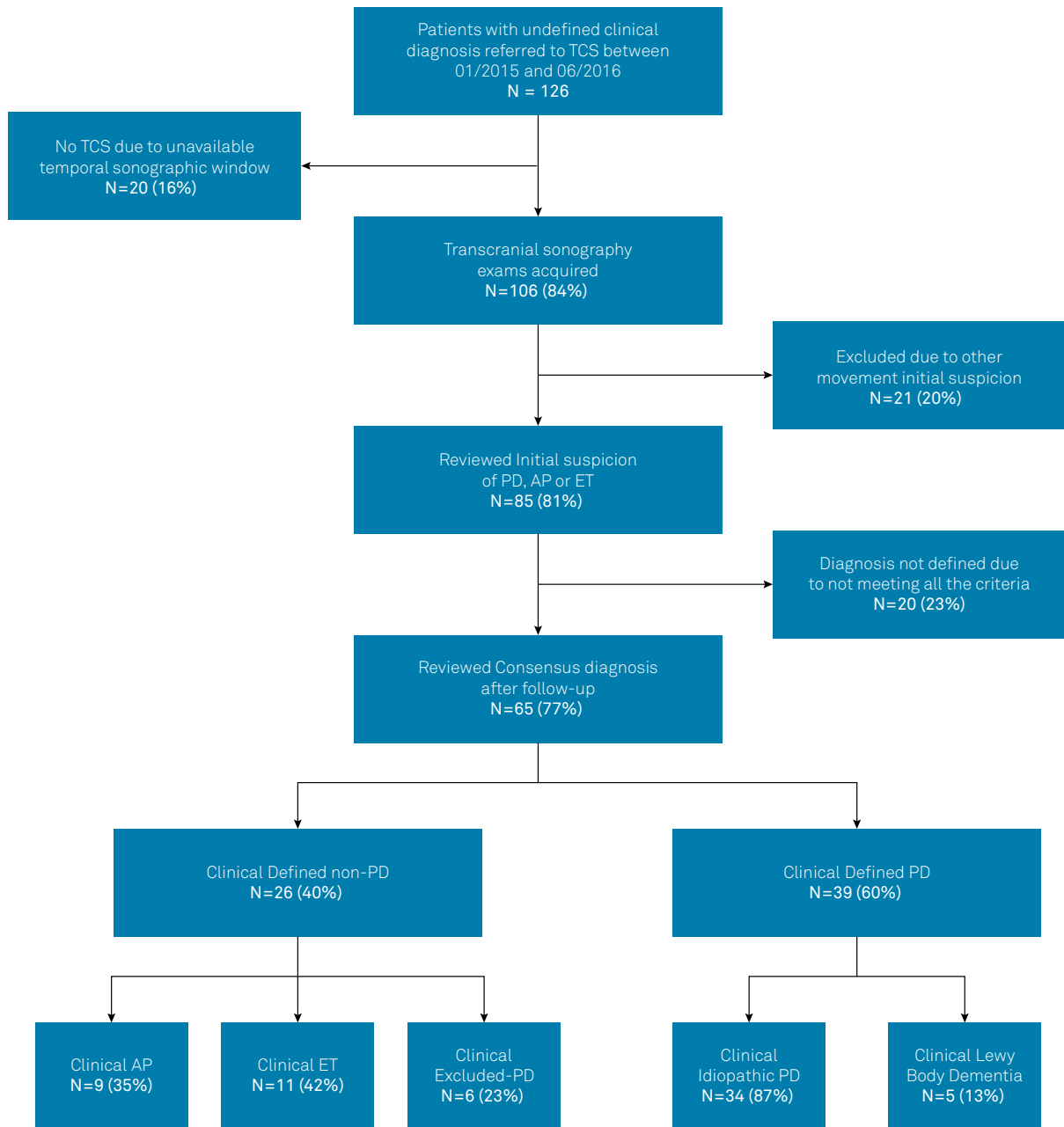


Figure 1. Trial schematic. Detailed schematic showing the patient inclusion process.

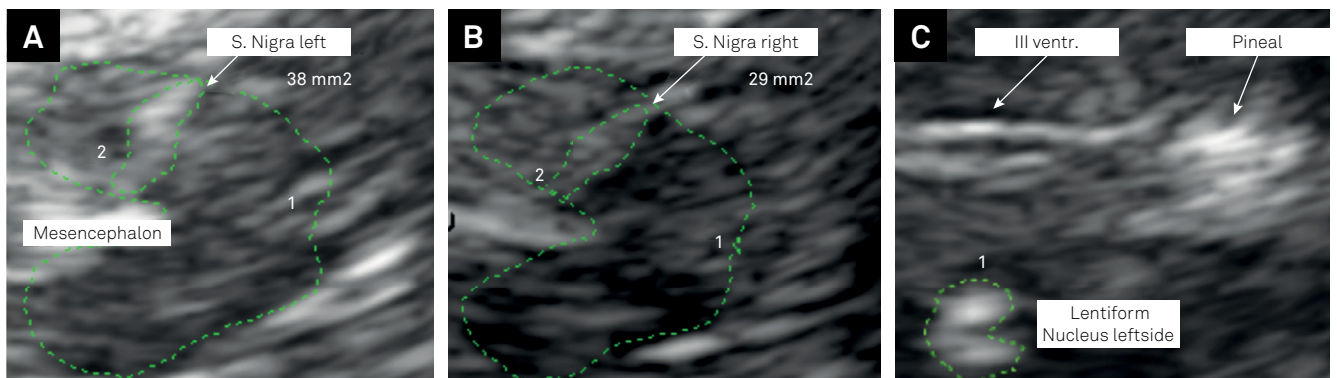


Figure 2. TCS images. (A) Delineation of the hyperechogenic SN in the left hemisphere and mesencephalic plane. (B) Delineation of the hyperechogenic SN in the right hemisphere and mesencephalic plane. (C) Delineation of the hyperechogenic LN in the thalamic plane. III Ventr: Third ventricle; and S. Nigra: substantia nigra.

RESULTS

We assessed 85 patients (51 men and 34 women) with a mean age of 67 (17-88) years (Table 1). The average clinical follow-up time after the TCS exam was 17 months. A definitive clinical diagnosis was determined for 65 (76%) of the recruited patients (Figure 1).

The initial clinical suspicion was AP in 18 (21%), ET in 15 (18%) and PD in 52 (61%) considering all the evaluated patients. A definitive diagnosis was achieved in 65 of these patients. Regarding the 65 patients with a final diagnosis, the initial diagnostic hypothesis was confirmed in 55 of them, representing a diagnostic consistency of 85% (Table 2). Twenty-one percent (n = 7) of the patients who were initially suspected to have PD had a different final diagnosis, including ET (n = 2) and “excluded PD” (n = 5). Moreover, two (18%) of the patients initially classified as ET were later diagnosed as PD.

We applied Bayesian statistics using a robust (t-distribution) one-way ANOVA to compare the demographic characteristics among the groups with definitive clinical diagnoses, and the results did not show statistically significant differences in the mean ages.

The posterior median of the SN area robust mean was defined as the central measure. With the intent of comparing the PD and non-PD groups, a difference in the distributions of

the central tendencies was obtained. Compared to all other clinically diagnosed groups, PD patients had the highest SN hyperechogenicity area values, which were significantly different compared with those of the other groups. The value of the SN hyperechogenic area among all groups that comprised the non-PD group did not differ in the between-group comparisons (Table 3).

The distribution of the frequencies of SN hyperechogenicity (area > 20 mm²) in patients with a final diagnosis of PD and in patients who were not diagnosed with PD (non-PD) is shown in Table 4. The Bayesian proportions test was applied to evaluate the chances of SN hyperechogenicity (> 20 mm²) occurrence in the PD and non-PD groups. The PD group had an estimated relative frequency of SN hyperechogenicity of 0.93 [0.85, 0.99], and the non-PD group of 0.13 [0.03, 0.27]. The estimated group difference (PD minus non-PD) was statistically significant (-0.79 [-0.92, -0.63]), showing that the relative frequency of SN hyperechogenicity was higher for patients diagnosed with PD.

Lentiform nucleus hyperechogenicity (LN+) was observed in 10% (n = 4) of patients diagnosed with PD and 22% (n = 2) of patients diagnosed with AP. Moreover, enlargement of the V3 was observed in 11% (n = 1) of patients in the AP group and 5% (n = 2) of patients in the PD group. These features have been used in other studies to help distinguish between PD and AP²⁴. However, when the Bayesian proportions test was used to assess the association of LN+ or V3 enlargement with the diagnoses of AP and PD, a between-group difference was not observed.

The Bayesian accuracy test was applied to evaluate the diagnostic accuracy of TCS based on the following central question: “Is SN hyperechogenicity a finding that could predict a clinical diagnosis of PD in this cohort after follow-up?”. Using the cut-off value of 20 mm², the finding of SN hyperechogenicity showed robust positive likelihood ratios (6.93) for a prospective PD clinical diagnosis when the group with a definitive clinical diagnosis of PD was compared with the group diagnosed with alternative clinical disorders (non-PD group). When using the cut-off value of

Table 1. Epidemiological data.

Variable	Frequency (n)	Percentage (%)
Gender		
Women	34	40.0
Men	51	60.0
Initial suspicion		
Atypical parkinsonism	18	21.2
Parkinson's disease	52	61.2
Essential tremor	15	17.6
Final diagnosis		
Atypical parkinsonism	9	10.6
Undefined	20	23.5
Excluded Parkinson's disease	6	7.1
PD or Lewy body dementia	39	45.9
Essential tremor	11	12.9
Symptom side		
Right side	45	52.9
Left side	23	27.1
Both sides	17	20.0
Family history		
Positive	14	16.4
Negative	29	34.1
Unknown	42	49.5

Table 2. Diagnosis distribution.

Initial clinical suspicion	Final clinical diagnosis
	Parkinson's disease (n = 37), 71%
Parkinson's disease (n = 52), 61%	Essential tremor (n = 2), 4%
	Excluded Parkinson's (n = 5), 10%
	Undefined (n = 8), 15%
Atypical parkinsonism (n = 18), 21%	Atypical (n = 9), 50%
	Undefined (n = 9), 50%
	Essential tremor (n = 9), 60%
Essential tremor (n = 15), 18%	Parkinson's disease (n = 2), 13%
	Excluded Parkinson's (n = 1), 7%
	Undefined (n = 3), 20%

Table 3. Post hoc analysis of the robust Bayesian t-test and one-way ANOVA.

Group	Posterior median of the SN area robust mean [HDI – 95% and σ]	Difference between posterior medians of the SN area robust mean [HDI – 95% and η]
Non-PD	$\mu = 16.6$ [15.4, 17.8], $\sigma = 2.7$ [1.6, 4.1]	vs. PD = -18^* [-22, -15]; $\eta = -2.80$ [-3.7, -1.8]
PD	$\mu = 34.6$ [31.6, 37.9], $\sigma = 9.4$ [7.1, 12.0]	vs. AP = 15.3 [9.5, 20.5]; $\eta = 0.66$ [-0.4, 1.8]
AP	$\mu = 19.2$ [14.9, 24.0], $\sigma = 5.9$ [2.6, 10.4]	vs. ET = -2.7 [-7.5, -1.8]; $\eta = -0.60$ [-1.5, 0.4]
ET	$\mu = 16.6$ [15.0, 18.1], $\sigma = 2.2$ [1.3, 3.8]	vs. PD = 18^* [14.2, 21.3]; $\eta = 2.61$ [1.8, 3.5]
EPD	$\mu = 14.7$ [11.9, 17.8], $\sigma = 2.9$ [1.3, 6.0]	vs. PD = 19.8^* [15.5, 24.1]; $\eta = 2.84$ [1.9, 3.5]

EPD: excluded PD; PD: Parkinson's disease; AP: atypical parkinsonism; ET: essential tremor; non-PD: AP+ET+EPD; HDI: high-density interval; σ : posterior median of the robust standard deviation; η : posterior median of the effect size. *Significant between-group difference in the posterior medians. Note: The results from the Bayesian statistical analysis were considered to be statistically significant if the highest density intervals (HDI) did not cross the value zero.

Table 4. Results of TCS and the definitive clinical diagnoses.

Variable	SN+	SN-
Parkinson's disease	37 (32)	2 (6)
Non-PD	3 (1)	23 (24)

The numbers in parentheses represent data calculated using the alternative cut-off value of 25 mm².

25 mm², as suggested by other studies¹¹, SN hyperechogenicity revealed an even higher positive likelihood ratio (LR) (12.87). Moreover, the positive predictive value, sensitivity, and specificity of this measure for PD diagnosis were also high (greater than 90%), as shown in Table 5.

In addition, when applying the same accuracy test, hyperechogenic LN or V3 enlargement displayed high sensitivity for identifying AP (0.884 [0.764, 0.958] and 0.934 [0.830, 0.984], respectively) with low specificity (0.163 [0.025, 0.445] and 0.258 [0.066, 0.556], respectively).

The Bayesian estimate for a ROC curve²⁵ revealed an area under the curve of 0.945 [0.867, 0.982], implying that SN hyperechogenicity exhibited reasonable accuracy for a prospective PD diagnosis. In addition, the optimal SN planimetry cut-off value to distinguish between the PD and non-PD groups using our equipment and methods was estimated to be 21.4 mm² (Figure 3). The values regarding the diagnostic values for PD x ET and PD x AP are shown in Table 6.

DISCUSSION

Even in specialized movement disorder clinics, approximately 10–25% of PD patients may be misdiagnosed using standard clinical diagnostic criteria when compared with autopsy findings^{2,5}. This rate of misdiagnosis emphasizes the need for complementary methods and biomarkers for diagnosing PD. A similar demand exists for reliable statistical approaches, such as Bayesian methods, to enable more accurate measurements of the power of these markers for diagnosing PD²⁶.

Currently, TCS is consolidated as a practical diagnostic tool that can discriminate between PD and PD mimics in late clinical stages^{9,11}. However, in clinical practice, one of the

Table 5. Bayesian accuracy of the diagnostic tests (Parkinson's disease vs. alternative diagnosis).

Parameters	SN (cut-off = 20 mm ²)	SN (cut-off = 25 mm ²)
	Median [HDI – 95%]	Median [HDI – 95%]
LR negative	0.078 [0.02, 0.20]	0.18 [0.08, 0.33]
LR positive	6.93 [3.15, 22.15]	12.87 [4.16, 89.45]
Negative predictive value	0.90 [0.75, 0.98]	0.79 [0.63, 0.90]
Positive predictive value	0.91 [0.80, 0.98]	0.95 [0.85, 0.99]
Sensitivity	0.93 [0.83, 0.98]	0.83 [0.70, 0.93]
Specificity	0.87 [0.71, 0.96]	0.94 [0.80, 0.99]

LR: likelihood ratio.

difficulties in a movement disorder clinic is distinguishing between PD, AP and ET in early clinical stages. Likewise, TCS also seems to be valid in the differential diagnosis of PD even in the early stages. If the patient presents with an incomplete clinical syndrome, the finding of a hyperechogenic SN suggests a diagnosis of PD, whereas the absence of this result suggests a diagnosis of an alternative condition^{16,18}. In this retrospective cohort study, we have confirmed that TCS can be helpful in distinguishing between PD and AP at the first diagnostic evaluation as well as between the prospective diagnoses of PD and ET in a practical clinical scenario.

Although the clinical follow-up period in our study was a minimum of six months, most of the patients had complained of symptoms for more than three years. However, not all patients in the definitively-diagnosed group had a five-year follow-up period, and some patients had not received a final diagnosis by the end of this study (n = 20) because they still did not fulfill all the diagnostic criteria. The rate of disagreement between the first clinical suspicion and the definitive diagnosis was 14% (n = 9), which is consistent with the rates previously described for this scenario⁵.

The TCS results considering the SN > 20mm² agreed with the final clinical diagnosis in all of the cases in which the clinical diagnosis had to be changed from PD to non-PD (n = 7) or from ET to PD (n = 2). Although the TCS results were not considered when these final clinical diagnoses were

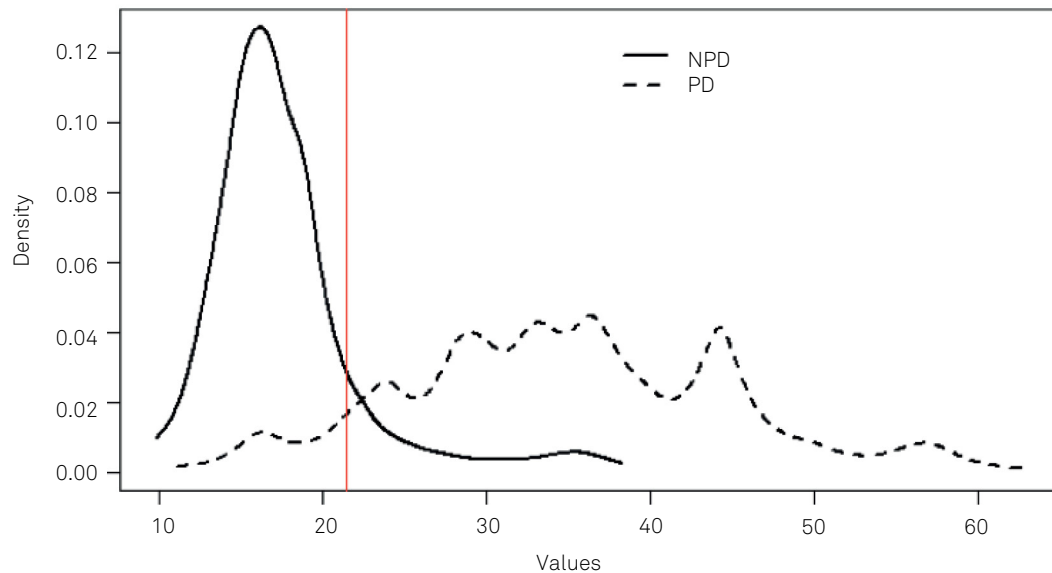


Figure 3. Graphic representation of the optimal SN planimetry cut-off value for our population when comparing PD and alternative diagnoses. PD: Parkinson's disease; NPD: non-Parkinson's disease; and SN: substantia nigra.

Table 6. Bayesian ROC curve.

Group	N	ROC area	Cut (mm ²)	Sensitivity	Specificity
ET x PD (n = 11 x n = 39)	50	0.963	20.0	0.939	0.952
AP x PD (n = 9 x n = 39)	48	0.858	21.9	0.910	0.691
Non-PD x PD (n = 26 x n = 39)	65	0.928	21.4	0.896	0.890

PD: Parkinson's disease; AP: atypical parkinsonism; ET: essential tremor; non-PD: non-Parkinson's disease.

determined, our study results highlight the suitability of TCS in enabling clinicians to reach the proper diagnosis earlier, as SN hyperechogenicity was highly predictive of the subsequent fulfillment of the UK Brain Bank criteria. Likewise, the absence of SN hyperechogenicity predicted the subsequent clinical characterization of a non-PD clinical diagnosis.

The high positive predictive value reported in the present study (91.2%) is consistent with the results from a study using a prospective methodology and preselected patients (92.9%). It is also a plausible argument for the early use of this test in clinical practice, namely, when most of the motor and nonmotor symptoms have not yet manifested¹⁶. Besides being a study carried out in a clinical practice scenario, our results (89.9%) also reproduced a high negative predictive value (85.7%), revealing the efficacy of TCS in excluding a PD diagnosis based on negative results¹⁸.

The LR is a measure of how the test would influence the diagnostic decision, and considers sensitivity and specificity, but is not affected by the disease prevalence²⁷. Although underused, the LR can refine the clinical diagnosis²⁸. The

LR considers the probability that the patient will present the characteristic of interest before the test (in our case, a PD diagnosis) and the extent to which the test can increase the probability of the characteristic occurrence²⁷. The LR has been simplified by an estimate that can be used regardless of the pretest probability value. A positive likelihood ratio (LR+) value of 6, for example, represents an increase of 35% over the pretest probability that the characteristic will occur based on the test results²⁷. A positive LR ranging from 2-5 represents a small increase in post-test probability that the characteristic will occur, whereas values from 5-10 indicate a moderate increase in the post-test probability, and values greater than 10 indicate a large increase in the post-test probability²⁸. In this study, a significant increase (6.93 times) was observed in the odds that an undiagnosed case of parkinsonism would receive a subsequent PD diagnosis (based on UK Brain Bank criteria) if a hyperechogenic SN (> 20 mm²) was observed. This finding reflects an increase of approximately 35% from the previous post-test probability of diagnosis. With findings of SN > 25 mm², the LR+ is even higher (12.87) and represents an increase of more than 45% for the probability of receiving a PD diagnosis. Similar positive LR values have also been described when evaluating the odds of an asymptomatic subject prospectively developing specific PD symptoms when SN hyperechogenicity was observed²⁵. These data reveal how a clinician can apply the results of SN hyperechogenicity evaluation in a simple and accurate manner when assessing a possible case of PD.

In the present study, most likely due to our small sample size, the isolated finding of LN hyperechogenicity in the TCS examination was not a unique feature that could differentiate PD from AP, as already described in other studies¹¹. However, in LN hyperechogenicity, this feature, when combined with the

absence of SN hyperechogenicity, which occurred in two cases, was identified only in patients with a final clinical diagnosis of AP. This finding supports previous reports claiming that the combination of LN without SN hyperechogenicity is a good predictor of an AP diagnosis¹¹. In addition, also probably due to the sample size, the combination of V3 enlargement and LN hyperechogenicity (applied here with the intent to predict a diagnosis of PD or AP) showed low sensitivity and high specificity, which is inconsistent with published data, showing that the association of LN+ and V3 enlargement has a sensitivity and specificity of 77% in distinguishing between AP and PD^{11,29}.

Regarding the weaknesses of the method, patients with corticobasal syndrome and Lewy body dementia, two other relevant PD mimics, also typically show SN hyperechogenicity; thus, TCS is not a useful tool for differentiating among diagnoses of PD, Lewy body dementia, and corticobasal syndrome²³. Nevertheless, some authors consider PD and Lewy body dementia as two entities on the same spectrum of Lewy body disorders²¹. Furthermore, corticobasal syndrome has clinical features (e.g., myoclonus, asymmetric dystonia, apraxia, and alien hand phenomenon) that are distinguishable from those of PD solely on a clinical basis, which minimizes the issue from this limitation of TCS. The clinical use of TCS might also be limited by the need for operator experience and training in addition to the technical difficulties in imaging through the temporal window. When trained operators use the correct technique, the proportion of inaccessible bone windows does not exceed 20%²³. In our sample, this proportion was 16% (n = 20).

Other neuroimaging methods, such as MRI (nigrosome-1 and neuromelanin imaging, DTI, and SWI), dopamine transporter brain SPECT, MIBG cardiac SPECT or¹⁸F-DOPA PET, are expensive and not readily available and may involve exposure to radiation²³. The absence of an accurate, economical and practical method (or biomarker) for early confirmation of a PD diagnosis is a current medical issue; meaning that a significant proportion of patients with early-stage PD are not diagnosed until specific milestones of the natural history of the disease are reached³⁰.

We recognize that the present study is a retrospective cohort study with a small sample size and relatively short follow-up time. Despite these limitations, the strength of the association between SN hyperechogenicity and the prediction of the clinical diagnosis of PD suggests that TCS is an ancillary technique that can be used, particularly in countries with limited resources. This was the first Brazilian study to use TCS to distinguish PD from AP and ET in a clinical practice scenario. In addition to the other case series of PD patients evaluated with TCS in Brazil^{14,15}, our study highlights TCS as a nonradiation-dependent, accessible and safe diagnostic tool that can be utilized in Brazilian reality.

In conclusion, our results reinforce the previously-reported power of TCS in hastening the diagnosis of PD. This retrospective cohort study suggests that TCS is suitable for use in a real-world clinical scenario and provides supporting evidence for the use of TCS as a complementary diagnostic tool in the initial neurological evaluation of patients who present with bradykinesia, rigidity, and tremor³¹.

Acknowledgments: We thank Dr. Daniela Berg for her suggestions and for reviewing the manuscript.

References

1. Postuma RB, Berg D, Stern M, Poewe W, Olanow CW, Oertel W et al. MDS clinical diagnostic criteria for Parkinson's disease. *Mov Disord*. 2015 Oct;30(12):1591-601. <https://doi.org/10.1002/mds.26424>
2. Tolosa E, Wenning G, Poewe W. The diagnosis of Parkinson's disease. *Lancet Neurol*. 2006 Jan;5(1):75-86. [https://doi.org/10.1016/S1474-4422\(05\)70285-4](https://doi.org/10.1016/S1474-4422(05)70285-4)
3. Adler CH, Beach TG, Hentz JG, Shill HA, Caviness JN, Driver-Dunckley E et al. Low clinical diagnostic accuracy of early vs advanced Parkinson disease: clinicopathologic study. *Neurology*. 2014 Jul;83(5):406-12. <https://doi.org/10.1212/WNL.0000000000000641>
4. Berardelli A, Wenning GK, Antonini A, Berg D, Bloem BR, Bonifati V et al. EFNS/MDS-ES/ENS [corrected] recommendations for the diagnosis of Parkinson's disease. *Eur J Neurol*. 2013 Jan;20(1):16-34. <https://doi.org/10.1111/ene.12022>
5. Rizzo G, Copetti M, Arcuti S, Martino D, Fontana A, Logroscino G. Accuracy of clinical diagnosis of Parkinson disease: A systematic review and meta-analysis. *Neurology*. 2016 Feb;86(6):566-76. <https://doi.org/10.1212/WNL.0000000000002350>
6. Becker G, Seufert J, Bogdahn U, Reichmann H, Reiners K. Degeneration of substantia nigra in chronic Parkinson's disease visualized by transcranial color-coded real-time sonography. *Neurology*. 1995 Jan;45(1):182-4. <https://doi.org/10.1212/WNL.45.1.182>
7. Loo S, Walter U, Behnke S, Hagenah J, Lorenz M, Sitzer M et al. Reproducibility and diagnostic accuracy of substantia nigra sonography for the diagnosis of Parkinson's disease. *J Neurol Neurosurg Psychiatry*. 2010 Oct;81(10):1087-92. <https://doi.org/10.1136/jnnp.2009.196352>
8. Berg D, Seppi K, Behnke S, Liepell I, Schweitzer K, Stockner H et al. Enlarged substantia nigra hyperechogenicity and risk for Parkinson disease: a 37-month 3-center study of 1847 older persons. *Arch Neurol*. 2011 Jul;68(7):932-7. <https://doi.org/10.1001/archneurol.2011.141>
9. Budisic M, Trkanjec Z, Bosnjak J, Lovrencic-Huzjan A, Vukovic V, Demarin V. Distinguishing Parkinson's disease and essential tremor with transcranial sonography. *Acta Neurol Scand*. 2009 Jan;119(1):17-21. <https://doi.org/10.1111/j.1600-0404.2008.01056.x>
10. Alonso-Cánovas A, López-Sendón JL, Buisán J, Felipe-Mimbrera A, Guillán M, García-Barragán N et al. Sonography for diagnosis of Parkinson disease—from theory to practice: a study on 300 participants. *J Ultrasound Med*. 2014 Dec;33(12):2069-74. <https://doi.org/10.7863/ultra.33.12.2069>
11. Walter U, Niehaus L, Probst T, Benecke R, Meyer BU, Dressler D. Brain parenchyma sonography discriminates Parkinson's disease and atypical parkinsonian syndromes. *Neurology*. 2003 Jan;60(1):74-7. <https://doi.org/10.1212/WNL.60.1.74>
12. Walter U. Transcranial sonography of the cerebral parenchyma: update on clinically relevant applications. *Perspect Med*. 2012;1(1-12):334-43. <https://doi.org/10.1016/j.permed.2012.02.014>

13. Skoloudík D, Fadrná T, Bártová P, Langová K, Rössner P, Zapletalová O et al. Reproducibility of sonographic measurement of the substantia nigra. *Ultrasound Med Biol*. 2007 Sep;33(9):1347-52. <https://doi.org/10.1016/j.ultrasmedbio.2007.03.013>
14. Bor-Seng-Shu E, Pedrosa JL, Felício AC, Andrade DC, Teixeira MJ, Braga-Neto P et al. Substantia nigra echogenicity and imaging of striatal dopamine transporters in Parkinson's disease: a cross-sectional study. *Parkinsonism Relat Disord*. 2014 May;20(5):477-81. <https://doi.org/10.1016/j.parkreidis.2014.01.015>
15. Fernandes RC, Rosso AL, Vincent MB, Silva KS, Bonan C, Araújo NC et al. Transcranial sonography as a diagnostic tool for Parkinson's disease: a pilot study in the city of Rio de Janeiro, Brazil. *Arq Neuropsiquiatr*. 2011 Dec;69(6):892-5. <https://doi.org/10.1590/S0004-282X2011000700008>
16. Vlaar AM, Nijs T, Kroonenburgh MJ, Mess WH, Winogrodzka A, Tromp SC et al. The predictive value of transcranial duplex sonography for the clinical diagnosis in undiagnosed parkinsonian syndromes: comparison with SPECT scans. *BMC Neurol*. 2008 Nov;8(1):42. <https://doi.org/10.1186/1471-2377-8-42>
17. Li DH, He YC, Liu J, Chen SD. Diagnostic accuracy of transcranial sonography of the substantia nigra in Parkinson's disease: a systematic review and meta-analysis. *Sci Rep*. 2016 Feb;6(1):20863. <https://doi.org/10.1038/srep20863>
18. Gaenslen A, Unmuth B, Godau J, Liepelt I, Di Santo A, Schweitzer KJ et al. The specificity and sensitivity of transcranial ultrasound in the differential diagnosis of Parkinson's disease: a prospective blinded study. *Lancet Neurol*. 2008 May;7(5):417-24. [https://doi.org/10.1016/S1474-4422\(08\)70067-X](https://doi.org/10.1016/S1474-4422(08)70067-X)
19. Gilman S, Low PA, Quinn N, Albanese A, Ben-Shlomo Y, Fowler CJ et al. Consensus statement on the diagnosis of multiple system atrophy. *J Neurol Sci*. 1999 Feb;163(1):94-8. [https://doi.org/10.1016/S0022-510X\(98\)00304-9](https://doi.org/10.1016/S0022-510X(98)00304-9)
20. McKeith IG, Galasko D, Kosaka K, Perry EK, Dickson DW, Hansen LA et al. Consensus guidelines for the clinical and pathologic diagnosis of dementia with Lewy bodies (DLB): report of the consortium on DLB international workshop. *Neurology*. 1996 Nov;47(5):1113-24. <https://doi.org/10.1212/WNL.47.5.1113>
21. Bain P, Brin M, Deuschl G, Elble R, Jankovic J, Findley L et al. Criteria for the diagnosis of essential tremor. *Neurology*. 2000;54(11 Suppl 4):S7.
22. Litvan I, Agid Y, Jankovic J, Goetz C, Brandel JP, Lai EC et al. Accuracy of clinical criteria for the diagnosis of progressive supranuclear palsy (Steele-Richardson-Olszewski syndrome). *Neurology*. 1996 Apr;46(4):922-30. <https://doi.org/10.1212/WNL.46.4.922>
23. Walter U, Behnke S, Eydung J, Niehaus L, Postert T, Seidel G et al. Transcranial brain parenchyma sonography in movement disorders: state of the art. *Ultrasound Med Biol*. 2007 Jan;33(1):15-25. <https://doi.org/10.1016/j.ultrasmedbio.2006.07.021>
24. Broemeling LD. Bayesian methods for medical test accuracy. *Diagnostics (Basel)*. 2011 May;1(1):1-35. <https://doi.org/10.3390/diagnostics1010001>
25. Bajaj NP, Gontu V, Birchall J, Patterson J, Grosset DG, Lees AJ. Accuracy of clinical diagnosis in tremulous parkinsonian patients: a blinded video study. *J Neurol Neurosurg Psychiatry*. 2010 Nov;81(11):1223-8. <https://doi.org/10.1136/jnnp.2009.193391>
26. Berg D, Postuma RB, Adler CH, Bloem BR, Chan P, Dubois B et al. MDS research criteria for prodromal Parkinson's disease. *Mov Disord*. 2015 Oct;30(12):1600-11. <https://doi.org/10.1002/mds.26431>
27. McGee S. Simplifying likelihood ratios. *J Gen Intern Med*. 2002 Aug;17(8):646-9. <https://doi.org/10.1046/j.1525-1497.2002.10750.x>
28. Grimes DA, Schulz KF. Refining clinical diagnosis with likelihood ratios. *Lancet*. 2005 Apr;365(9469):1500-5. [https://doi.org/10.1016/S0140-6736\(05\)66422-7](https://doi.org/10.1016/S0140-6736(05)66422-7)
29. Pilotto A, Yilmaz R, Berg D. Developments in the role of transcranial sonography for the differential diagnosis of parkinsonism. *Curr Neurol Neurosci Rep*. 2015 Jul;15(7):43. <https://doi.org/10.1007/s11910-015-0566-9>
30. Berg D, Jabs B, Mershdorf U, Beckmann H, Becker G. Echogenicity of substantia nigra determined by transcranial ultrasound correlates with severity of parkinsonian symptoms induced by neuroleptic therapy. *Biol Psychiatry*. 2001 Sep;50(6):463-7. [https://doi.org/10.1016/S0006-3223\(01\)01190-8](https://doi.org/10.1016/S0006-3223(01)01190-8)
31. Skoloudík D, Walter U. Method and validity of transcranial sonography in movement disorders. *Int Rev Neurobiol*. 2010;90:7-34. [https://doi.org/10.1016/S0074-7742\(10\)90002-0](https://doi.org/10.1016/S0074-7742(10)90002-0)