

# Brazilian consensus for diagnosis, management and treatment of transthyretin familial amyloid polyneuropathy

Consenso Brasileiro para o diagnóstico, manejo e tratamento da Polineuropatia Amiloidótica Familiar associada à Transtirretina

Marcus Vinicius Pinto<sup>1</sup>, Amilton Antunes Barreira<sup>2</sup>, Acary Souza Bulle<sup>3</sup>, Marcos Raimundo Gomes de Freitas<sup>1</sup>, Marcondes Cavalcante França Jr<sup>4</sup>, Francisco de Assis Aquino Gondim<sup>5,6</sup>, Carlo Domenico Marrone<sup>7</sup>, Wilson Marques Jr<sup>2</sup>, Osvaldo J. M. Nascimento<sup>8</sup>, Francisco Tellechea Rotta<sup>9</sup>, Camila Pupe<sup>8</sup>, Márcia Waddington-Cruz<sup>1</sup>

## ABSTRACT

Transthyretin familial amyloid polyneuropathy is an autosomal dominant inherited sensorimotor and autonomic polyneuropathy, which if untreated, leads to death in approximately 10 years. In Brazil, liver transplant and tafamidis are the only disease-modifying treatments available. This review consists of a consensus for the diagnosis, management and treatment for transthyretin familial amyloid polyneuropathy from the Peripheral Neuropathy Scientific Department of the Brazilian Academy of Neurology. The first and last authors produced a draft summarizing the main views on the subject and emailed the text to 10 other specialists. Relevant literature on this subject was reviewed by each participant and used for the individual review of the whole text. Each participant was expected to review the text and send a feedback review by e-mail. Thereafter, the 12 panelists got together at the city of Fortaleza, discussed the controversial points, and reached a consensus for the final text.

**Keywords:** amyloid neuropathies, familial; polyneuropathies.

## RESUMO

Polineuropatia amiloidótica familiar é uma polineuropatia sensitivo-motora e autonômica de herança autossômica dominante, que caso não seja tratada leva a morte em aproximadamente 10 anos. O transplante de fígado e o tafamidis são os únicos tratamentos disponíveis no Brasil. Essa revisão consiste em um consenso do Departamento Científico de Neuropatias Periféricas da Academia Brasileira de Neurologia. O primeiro e último autores produziram um texto resumindo os principais aspectos sobre o tema e enviaram para os outros 10 especialistas por email. A literatura relevante sobre o assunto foi revisada por cada participante e utilizada para revisão individual do texto. Foi esperado que cada participante revisasse o texto e enviasse suas sugestões por e-mail. Finalmente, os 12 panelistas se encontraram na cidade de Fortaleza para discutir os pontos controversos e chegar a um consenso sobre texto final.

**Palavras-chave:** neuropatias amiloides familiares; polineuropatias.

<sup>1</sup>Universidade Federal do Rio de Janeiro, Hospital Universitário Clementino Fraga Filho, Centro de Estudos em Paramiloidose Antônio Rodrigues de Mello, Rio de Janeiro RJ, Brasil;

<sup>2</sup>Universidade de São Paulo, Faculdade de Medicina de Ribeirão Preto, Ribeirão Preto SP, Brasil;

<sup>3</sup>Universidade Federal de São Paulo, Escola Paulista de Medicina, São Paulo SP, Brasil;

<sup>4</sup>Universidade de Campinas, Faculdade de Ciências Médicas, Campinas SP, Brasil;

<sup>5</sup>Universidade Federal do Ceará, Faculdade de Medicina, Fortaleza CE, Brasil;

<sup>6</sup>Centro Universitário Unichristus, Fortaleza CE, Brasil;

<sup>7</sup>Clínica Marrone e Ambulatório de Doenças Neuromusculares do Hospital São Lucas da PUCRS, Porto Alegre RS, Brasil;

<sup>8</sup>Universidade Federal Fluminense, Niterói RJ, Brasil;

<sup>9</sup>Hospital Moinhos de Vento e Santa Casa de Misericórdia de Porto Alegre, Porto Alegre RS, Brasil.

**Correspondence:** Márcia Waddington-Cruz; Centro de Estudos em Paramiloidoses Antônio Rodrigues de Mello, UFRJ; Rua Rodolpho Paulo Rocco s/n / 7º andar; 21941-913. Rio de Janeiro RJ, Brasil. E-mail: mwaddingtoncruz@gmail.com

**Conflict of interest:** Márcia Waddington Cruz received an honorarium from NHI, Prothema, FoldRx, Ionis, Pfizer, Alnylam and Genzyme for travel expenses related to presentations at medical meetings, for acting as a principal investigator in clinical trials and as a consultant member. The other authors report no conflict of interest to declare.

**Support:** Pfizer indirectly supported this consensus meeting, being one of the sponsors of the "1º Encontro Brasileiro de Neuropatias Periféricas" (First Brazilian Symposium on peripheral neuropathies) hosted in Fortaleza, Brazil, June 1-4, 2017.

Received 21 December 2017; Received in final form 25 August 2018; Accepted 30 August 2018.

Transthyretin familial amyloid polyneuropathy (ATTR-FAP) is an inherited neuropathy, with over 120 mutations identified in the *TTR* gene<sup>1</sup>. Transthyretin (TTR) is a tetrameric transport protein that carries vitamin A and thyroxin. Mutated TTR disaggregates, forming monomers that, after misfolding, aggregate as amyloid fibrils and cause toxicity to tissues<sup>2</sup>. The most common form of inherited amyloidosis is ATTR-FAP, characterized by a severe length-dependent sensorimotor/autonomic neuropathy, which if untreated, leads to death in approximately 10 years<sup>3-5</sup>.

The prospects for ATTR-FAP have changed in the last decades, as it has become a treatable neuropathy. The first disease-modifying treatment was a liver transplant, in 1990<sup>6</sup>. Tafamidis, a potent selective TTR stabilizer, was the first drug to show reduction of disease progression<sup>7</sup> and was the first approved by European and Latin American health agencies for the treatment of ATTR-FAP<sup>8</sup>. Diflunisal, an old non-steroidal anti-inflammatory drug, is a non-selective TTR stabilizer and is another therapeutic option (off label)<sup>9,10</sup>. Recently, two gene silencing drugs had very favorable results in large international randomized clinical trials<sup>11,12</sup>.

In Brazil, there is one referral center completely devoted to ATTR-FAP—the Brazilian National Amyloid Referral Center [*Centro de Estudos em Paramiloidose Antônio Rodrigues de Mello* (CEPARM)]—and a few neuromuscular centers with expertise in ATTR-FAP care. The CEPARM is located in the city of Rio de Janeiro. It was founded in 1984<sup>13</sup> and is recognized by the Ministry of Health. It is currently directed by one of the authors (MWC).

The aim of this study was to provide a consensus from the Peripheral Neuropathy Scientific Department of the Brazilian Academy of Neurology for the diagnosis, management and treatment of ATTR-FAP.

## METHODS

After identifying the need to generate a text to discuss the diagnosis, management and treatment of ATTR-FAP, a group was formed, comprising 12 Brazilian neurologists, who are members of the Peripheral Neuropathy Scientific Department of the Brazilian Academy of Neurology and considered to be representative experts on the subject. The first and last authors produced a draft summarizing the main views on the subject and emailed the text to 10 other specialists. Relevant literature on this subject was reviewed by each participant and used for the individual review of the whole text. Each participant was expected to review the text and send a feedback review by e-mail. Thereafter, the 12 panelists got together at the city of Fortaleza, discussed the controversial points, and reached a consensus for the final text.

## RESULTS

### Epidemiology

Transthyretin familial amyloid polyneuropathy is considered to be endemic in Portugal, Japan, Sweden, and Brazil<sup>14</sup>. The most-common mutation worldwide, especially in endemic regions, is Val30Met<sup>15</sup>. The prevalence of ATTR-FAP in northern Portugal (Póvoa de Varzim and Vila do Conde) is estimated to be 1:1,108 individuals<sup>16</sup>. In endemic areas of northern Sweden, the prevalence of Val30Met mutation is 4%, with a penetrance of only 11% by 50 years of age<sup>17</sup>. In contrast, penetrance is high in Portugal (80% by 50 years)<sup>18</sup> and Brazil (83% by 63 years)<sup>19</sup>. The prevalence of ATTR-FAP in Brazil is still unknown, but it is estimated that Brazil has more than 5,000 cases<sup>20</sup>.

### Pathophysiology

Transthyretin is synthesized in the liver (98%), choroid plexus, and retina pigmented epithelium. Amyloidogenic mutations destabilize the tertiary and quaternary structure of TTR, causing thermodynamic instability and inducing conformational changes. The dissociation of TTR tetramers into monomers, followed by monomer misfolding, produces fibrils that aggregate and deposit on tissues as amyloid<sup>2</sup>. Autopsy studies found TTR amyloid deposited in almost every tissue, but the most affected are peripheral nerves, heart, gastrointestinal tract, kidneys, eyes and central nervous system<sup>21,22</sup>. The TTR amyloid deposit causes tissue damage by direct compression, obstruction, local blood circulation failure and enhanced oxidative stress. In the peripheral nerves, the disease affects first autonomic and small sensory fibers, causing axonal degeneration, followed by large sensory and motor fibers<sup>1</sup>.

### Genetic aspects

The inheritance of ATTR-FAP is autosomal dominant with variable penetrance. The *TTR* gene is located in the chromosome 18q11.2-12<sup>23</sup>. Maternal inheritance seems to have higher penetrance than paternal<sup>24</sup>. The most-common mutation worldwide is a substitution of methionine for valine in position 30 (Val30Met/p.Val50Met). Recently, in a review of the literature of genetically-confirmed cases of ATTR ever reported, Val30Met was observed in 48.9% of patients, followed by Ser77Tyr in 13.9%<sup>25</sup>. At CEPARM, the frequency of Val30Met is 91.9%<sup>26</sup>. The origin of Val30Met mutation of Brazil and Japan was in Portugal, and Sweden had its own origin<sup>27,28</sup>. Other mutations in the *TTR* gene, like Val122Ile and Leu111Met, can cause a different phenotype of TTR amyloidosis with predominantly cardiac dysfunction, called TTR familial amyloid cardiomyopathy (ATTR-FAC). This cardiac phenotype may be associated (or not) with neuropathy<sup>29</sup>, which tends to be mild. The Val122Ile mutation prevalence in African Americans is 3-3.9%, with most individuals developing late-onset cardiac amyloidosis<sup>30</sup>.

**Table 1.** Coutinho stages of ATTR-FAP.

<b>Stage I</b>	Sensory and motor neuropathy limited to the lower limbs. Pain and thermal sensation severely impaired with light touch and proprioception relatively spared (sensory dissociation). Mild motor impairment. Ambulation without any gait aids.
<b>Stage II</b>	Gait aid required. Neuropathy progress to upper limbs and trunk. Amyotrophy in upper and lower limbs. Moderate motor impairment.
<b>Stage III</b>	Terminal stage, bedridden or wheelchair bound. Severe sensory, motor and autonomic neuropathy in all limbs.

<sup>31</sup>. The origin of the Val122Ile mutation was in West Africa. A few patients with Val122Ile mutations have been identified in Brazil<sup>32</sup>. This is likely to be due to the African ancestry present in Brazil and there are most likely several groups of unidentified patients with this mutation in Brazil.

## Clinical characteristics of ATTR-FAP

### Age of onset

The onset of ATTR-FAP varies from the second to the ninth decade of life, with a variable age of onset in different populations. Based on the age of symptom onset, ATTR-FAP patients can be divided into early onset (< 50 years old) and late onset (≥ 50 years old). In endemic countries, excluding Sweden, the majority of patients have an early onset, with a mean age of onset between 30-33 years<sup>3-5,33</sup>. In nonendemic regions, late-onset patients predominate, and most of them have a non-Val30Met mutation and no family history of ATTR-FAP<sup>34-38</sup>.

### Sensorimotor and autonomic findings

Since the original description by Corino de Andrade, ATTR-FAP has been known as a length-dependent polyneuropathy with a predilection for involvement of small sensory and autonomic fibers<sup>39</sup>. The disease usually starts with pain and paresthesias in the feet, associated with distal lower limb pain and thermal sensory loss followed by light touch loss and ankle hypo/areflexia. Other common initial symptoms are weight loss, impotence, diarrhea/constipation, orthostatic intolerance/hypotension, and/or dry eyes and mouth. Usually, patients start with motor symptoms after a two-year history of sensation loss, and four to five years after symptom onset, sensory symptoms start in the hands. Amyloid focal deposition in the wrists frequently causes bilateral carpal tunnel syndrome and, rarely, other focal neuropathies may occur<sup>1</sup>. Untreated cases inexorably progress to severe motor, sensory and autonomic impairment, cachexia, imbalance, gait disturbances and limb ulcerations. Death occurs approximately 10 years after symptom onset in untreated patients<sup>3,23,40</sup>.

The classical ATTR-FAP phenotype or “Portuguese” phenotype is characterized by a small fiber-predominant neuropathy, with sensory dissociation, early prominent autonomic involvement, and a positive family history. This is the most common phenotype in early-onset patients, especially from Brazil, Portugal and Japan<sup>3-5, 39</sup>. Late-onset patients more frequently have other phenotypes,

**Table 2.** Peripheral neuropathy disability score.

I. Sensory disturbances but preserved walking capacity (no motor impairment)
II. Difficulties in walking but without the need for a walking stick
IIIa. One stick or one crutch required for walking
IIIb. Two sticks, two crutches or a walker required for walking
IV. Patient confined to a wheelchair or bed

characterized by pan-modality sensory loss, mild autonomic features, severe cardiac involvement, and no family history<sup>22, 34, 36, 41</sup>. This latter phenotype predominates in patients from nonendemic areas<sup>1, 42, 43</sup>. At CEPARM, 26% of the patients have a late onset and these patients have more severe sensorimotor loss and cardiac dysfunction than early-onset patients (MVP and MWC, unpublished data). Also, ATTR-FAP has atypical phenotypes, and can present as an ataxic neuropathy, upper-limb predominant multiple mononeuropathies and motor predominant neuropathy<sup>42</sup>.

Coutinho et al.<sup>3</sup>, in a classical manuscript, described the largest series of ATTR-FAP and classified the disease into three stages. This is known as the Coutinho stages of ATTR-FAP (Table 1). Another classification frequently used is the modified peripheral neuropathy disability score<sup>14</sup> (Table 2).

### Cardiomyopathy

Cardiomyopathy occurs in the late stages of early-onset Val30Met patients, but early in late-onset Val30Met and several non-Val30Met mutations. It is the main clinical picture of ATTR-FAC<sup>29</sup>. Hereditary ATTR cardiomyopathy is characterized by bundle branch, atrioventricular and/or sinoatrial blocks and increased thickness of ventricular walls, especially in the interventricular septum. The accumulation of amyloid in the heart can lead to restrictive cardiomyopathy and heart failure. Most patients need a pacemaker during the course of the disease<sup>44</sup>. In the Brazilian population, the most common cardiac abnormalities are nonspecific ventricular repolarizations, ventricular conduction disturbances, atrial tachycardia, valve thickening and increased myocardium echogenicity<sup>45</sup>.

### Eyes

Vitreous opacity, glaucoma, ocular amyloid angiopathy and dry eyes are common and occur in most of the patients during the course of the disease<sup>46</sup>.



## Renal

Renal disturbances are variable in ATTR-FAP, and proteinuria seems to be the first finding. Patients can progress to nephritic or nephrotic syndrome and renal failure. It is estimated that one third of Portuguese ATTR-FAP patients develop nephrotic syndrome and renal failure<sup>47</sup>.

## Central Nervous System

Stroke and TIA-like episodes, aura-like and epileptic seizures are possible long-term complications of ATTR-FAP, especially in patients treated by liver transplant. It seems to occur because of amyloid cerebral angiopathy, often after 15 years of disease<sup>48</sup>.

## Diagnosis

Diagnosis of ATTR-FAP is challenging. It is important to improve neurologists' awareness of ATTR-FAP, to reduce the long delay in diagnosis. In Brazil, the mean time from symptom onset to diagnosis is 5.9 years<sup>49</sup>. Also, after clinical suspicion, pathologic confirmation of amyloid deposits and genetic diagnosis are highly recommended.

## Symptoms and signs

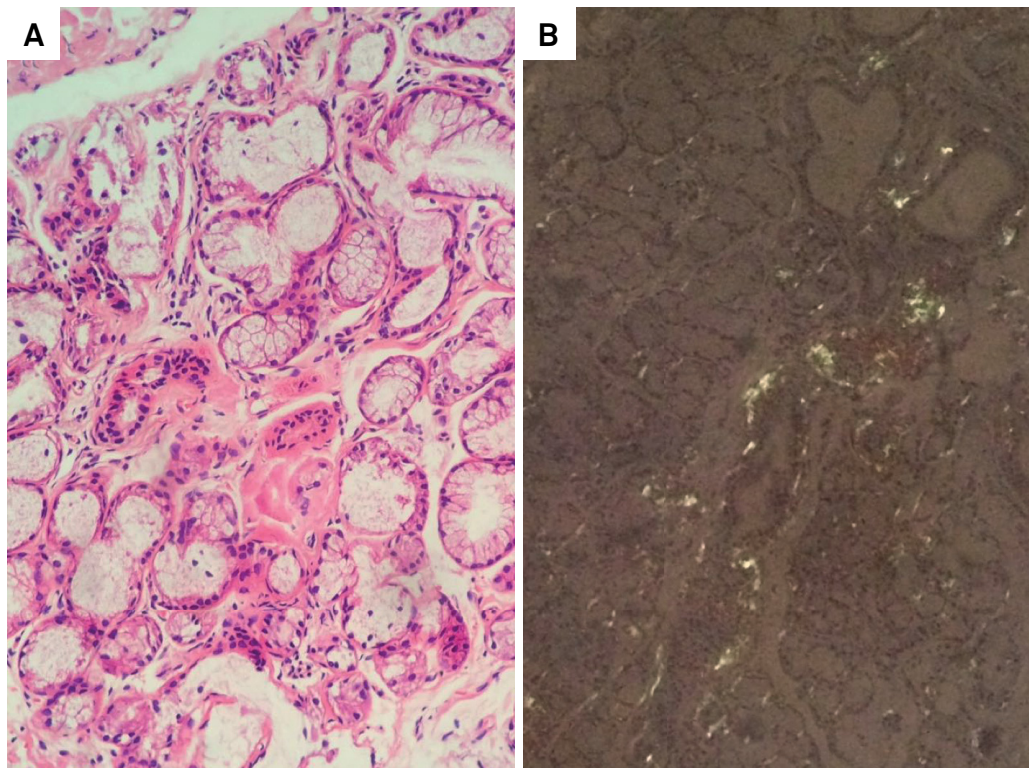
The clinical picture of ATTR-FAP is not unique. It is very important for the clinician to know the red flags for the suspicion of ATTR-FAP, and to consider biopsy and genotyping. In patients with progressive undetermined sensorimotor polyneuropathy, one or more of the following features should raise the suspicion of ATTR-FAP<sup>50</sup>:

1) Family history of neuropathy;

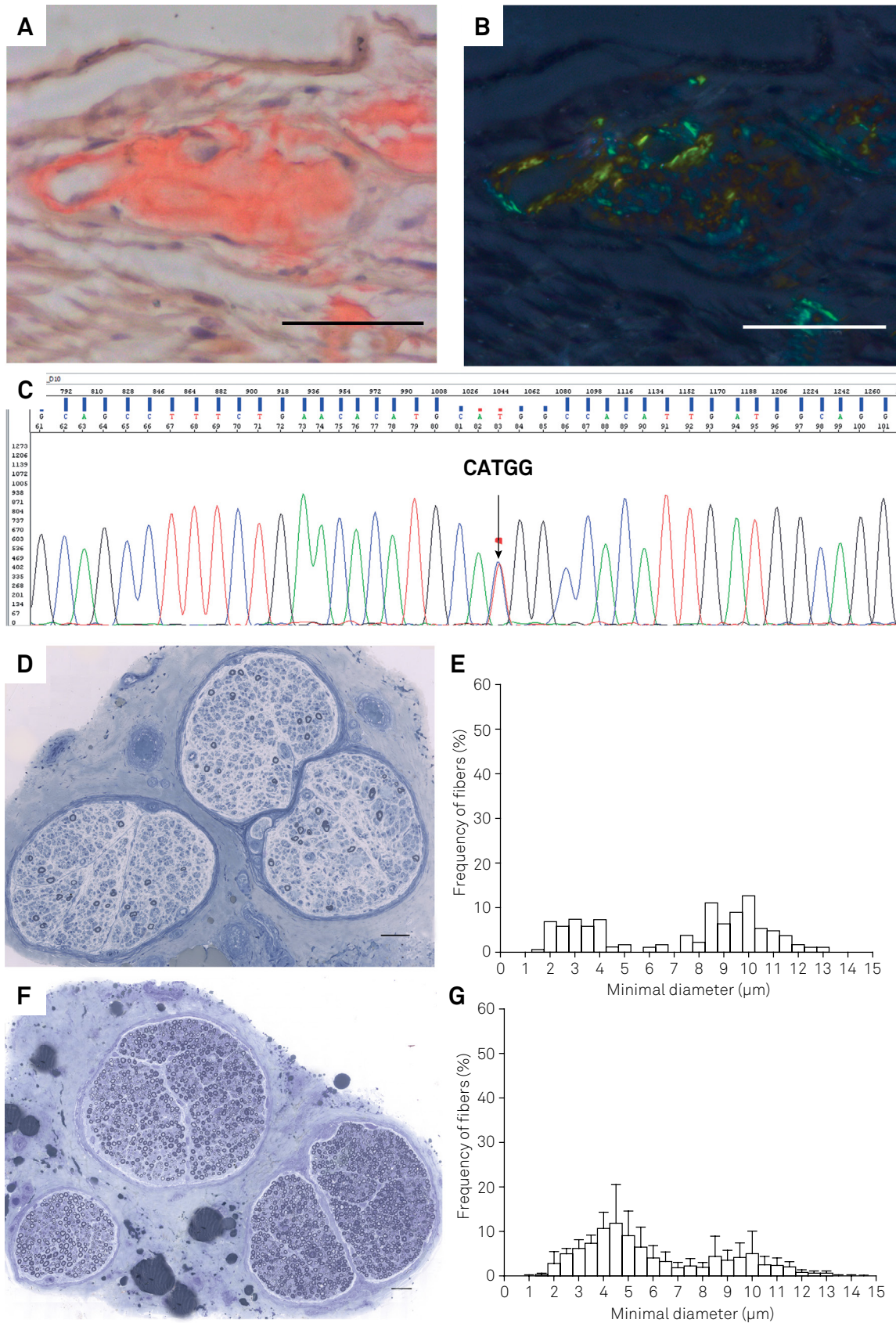
- 2) Orthostatic hypotension;
- 3) Sexual dysfunction (erectile dysfunction);
- 4) Unexplained weight loss;
- 5) Arrhythmias, conduction blocks, cardiac hypertrophy and cardiomyopathy;
- 6) Bilateral carpal tunnel syndrome;
- 7) Renal abnormalities (proteinuria or azotemia);
- 8) Vitreous opacities;
- 9) Gastrointestinal complaints (chronic diarrhea, constipation or diarrhea/constipation);
- 10) Rapid progression; and
- 11) Prior treatment failure.

## Tissue biopsy

Confirmation of amyloid deposition via tissue biopsy is recommended but not mandatory. Labial salivary gland, peripheral nerve, and abdominal subcutaneous fat are usually the sites of choice. Other tissues can be biopsied, like rectum, carpal flexor retinaculum, skin or endo/myocardium<sup>14</sup>. In Brazil, the preferred sites are the labial salivary gland (Figure 1) and peripheral nerve (Figure 2)<sup>26</sup>. It is important to note that a negative biopsy does not exclude the diagnosis of ATTR-FAP. If the suspicion is still high, another tissue biopsy and genotyping need to be planned. On nerve biopsy, amyloid deposits are scattered in the endoneurium and around blood vessels and have a round, amorphous, and orange appearance on Congo red staining, with characteristic apple-green birefringence under polarized light<sup>51</sup> (Figure 2). The sensitivity of labial salivary gland biopsy in ATTR-FAP patients with



**Figure 1.** Salivary gland biopsy. A. Amorphous eosinophilic material deposition around some acini and stroma on H&E staining. B. Apple-green birefringence under polarized light on Congo red staining. High power (200x).



**Figure 2.** A. Amyloid material deposition in a vessel wall (left) and in the adjacent endoneurial space on Congo red staining (sural nerve biopsy). B. The section A under polarized light shows the amyloid material birefringence appearing here as apple-green and golden-yellow colors. C. Electropherogram of TTR gene shows the c.148G>A (Val30Met) mutation. D. Semithin section stained with Toluidine Blue shows axonal loss. F. Normal sural nerve for comparison with D. E. Percentage histograms of the myelinic fibers seen in D demonstrate the predominance of thin myelinated fiber (7  $\mu$ m or less diameter) loss in comparison with the normal histogram represented in G. Scale bars = 50  $\mu$ m. Images A-E are from the same patient specimens.



Val30Met mutation is high, and varies between 75-91%<sup>52,53</sup>. In our review of the literature, despite salivary gland biopsy, we did not find any other good quality pathology study designed to evaluate the sensitivity of tissue biopsy for the diagnosis of amyloid in ATTR-FAP. Also, to identify whether the amyloid deposit comprises TTR, TTR immunolabeling can be performed, but it does not differentiate mutated from wild-type TTR. Mass spectrometry-based proteomics of the amyloid deposit can identify the misfolded protein, and even differentiate mutated from wild-type TTR<sup>1</sup>.

Tissue confirmation helps management of selective cases, especially in oligosymptomatic TTR mutation carriers with normal/borderline neurological examination and/or neurophysiological tests. Recently, soluble non-native TTR oligomers were identified using peptide probes in plasma of patients with ATTR-FAP. These non-native oligomers were also present in patients with early-stages of the disease, and were significantly decreased after tafamidis treatment, and were not found after liver transplant and in ATTR-FAC. Perhaps, in the near future, this blood test will help confirm the disease in oligosymptomatic ATTR-FAP carriers and be able to monitor response to treatment<sup>54</sup>.

### Genetic test

Genetic confirmation of a TTR mutation is mandatory for the diagnosis of ATTR-FAP. Based on the Brazilian experience, different genetic tests can be performed for the specific diagnosis. In families with a known mutation, direct genetic tests for that mutation should be performed. Patients with an unknown mutation or no family history must have *TTR* gene full sequencing for identification of the mutation and description of new mutations<sup>10,14</sup>. It is important to note that whole-exome or whole-genome sequencing can provide false negative results.

### Differential diagnosis

Toxic, metabolic, inflammatory, infectious, and other inherited neuropathies must be ruled out. Chronic inflammatory demyelinating polyradiculoneuropathy (CIDP)

is a common misdiagnosis, especially in late-onset patients without a family history; ATTR-FAP rarely causes proximal and distal weakness (which is very common in CIDP) and seldom fulfills the European Federation of Neurological Societies/Peripheral Nerve Society nerve conduction criteria for CIDP<sup>55,56</sup>. Immunoglobulin light chain amyloidosis is another important differential of ATTR-FAP. Serum and urine immunofixation help to differentiate these disorders, but ATTR-FAP patients may also have monoclonal gammopathy and this is not unusual in late-onset cases. Mass spectrometry-based proteomics of the amyloid deposit can differentiate which type of misfolded protein is deposited on tissues, and DNA analyses should always be requested in ATTR-FAP-suspected cases<sup>14</sup> (Table 3).

### Management

Transthyretin familial amyloid polyneuropathy is a complex multi-organ disease that requires comprehensive multidisciplinary care. Symptomatic treatment should be provided to every patient, as a huge number of patients do not have access to anti-amyloid therapy, especially in Brazil. This symptomatic treatment will not be addressed in this review, and can be found in other good reviews<sup>14,23</sup>. Neurologists, cardiologists, internists, nephrologists, ophthalmologists, nutritionists, nurses and physical therapists need to work together to improve patient care and quality of life. International guidelines encourage countries to create amyloidosis referral centers, building a national and international network for collaboration and exchange of experiences and information about new therapies and clinical trials<sup>14,57</sup>.

### Disease modifying treatments

#### Liver transplant

The liver produces virtually all the TTR circulating in the blood (98%), and it was thought that a liver replacement in ATTR-FAP stopping mutated TTR production would also stop amyloid deposition. Liver transplant emerged as a potential cure for the disease<sup>58</sup>. The first orthotopic liver transplant in ATTR-FAP was carried out in Stockholm, Sweden, in 1990<sup>59</sup>.

**Table 3.** Differential diagnosis of transthyretin familial amyloid polyneuropathy.

Differential diagnosis	Clues for the differential diagnosis
Diabetic neuropathy	Poor glycemic control and mild motor involvement
Chronic inflammatory demyelinating polyradiculoneuropathy	Proximal and distal weakness and non-uniform demyelination on nerve conduction studies
Leprosy	Multiple mononeuropathies/asymmetric neuropathy, typical skin lesions
Toxic neuropathies	Bortezomib, thalidomide, vincristine, alcohol abuse
Fabry	Angiokeratomas, stroke, and alpha-galactosidase A deficiency
Charcot-Marie-Tooth	Mild sensation loss and no autonomic involvement
Hereditary sensory and autonomic neuropathies	No or mild motor involvement
Immunoglobulin light-chain amyloidosis	Monoclonal gammopathy in the serum and/or urine, abnormal kappa/lambda ratio, mass-spectrometry, bone marrow biopsy

In South America, the first liver transplant performed for this purpose was in São Paulo, Brazil, in 1993<sup>60</sup>. The first series of orthotopic liver transplants showed a decrease in the amyloid load and improvement of symptoms in some patients. This suggested that the procedures were successful, and the cure for this fatal disease was finally achieved<sup>61</sup>. However, subsequent studies showed that the results were not good in old patients, those who were malnourished, with advanced disease and/or had non-Val30Met mutations<sup>6,62</sup>. Also, cardiomyopathy continued to progress in several patients, probably by wild-type TTR amyloid deposition<sup>63,64</sup>.

Bittencourt et al.<sup>60</sup> published the first Brazilian series of orthotopic liver transplants in 24 ATTR-FAP Val30Met patients who were studied from 1993 to 1999. The mean survival rate after one and five years was 70% and 58%, respectively, and independent factors for survival were disease duration and serum albumin levels<sup>60</sup>. After 20 years of liver transplant experience for the treatment of ATTR-FAP, 2,127 liver transplants have been done in 1,940 patients in 77 centers in 19 countries, according to the Familial Amyloid Polyneuropathy World Transplant Registry. The survival rate was 55.8%, and independent risk factors for good prognosis were: early-onset, Val30Met mutation, modified body mass index before transplant, and a short disease duration<sup>65</sup>. However, a liver transplant does not interfere with eye and central nervous system amyloid deposition, as the retina and the choroid plexus continue secreting mutated TTR<sup>48,66</sup>. Since the development of TTR stabilizers, liver transplant rates are decreasing around the globe<sup>65</sup>. The combination of liver transplant and TTR stabilizers has never been well studied, and although it theoretically seems a good treatment option, clinical trials addressing this question are needed. The role of liver transplant in this new era of ATTR-FAP treatment is yet to be defined.

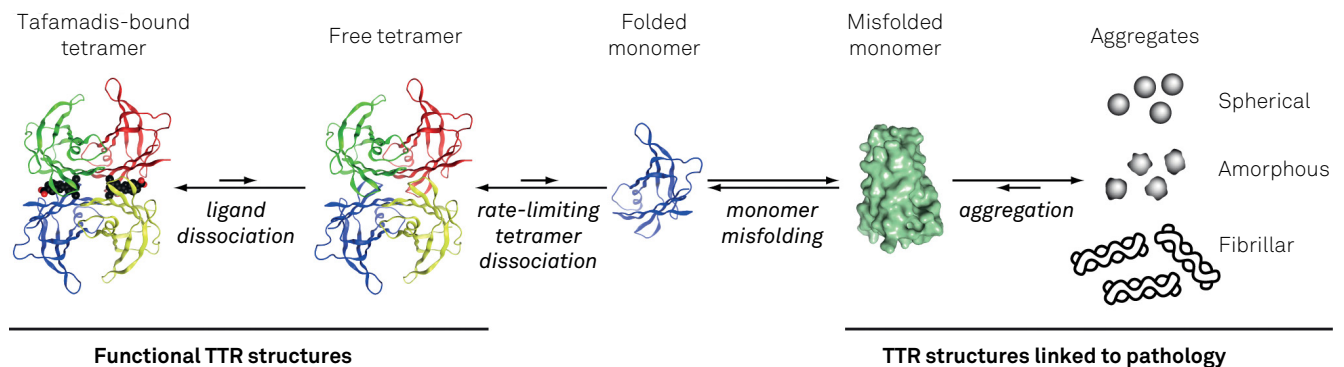
## TTR stabilizers

### Tafamidis

Tafamidis binds with selectivity, high affinity and negative cooperativity to wild-type or mutated TTR, increasing

TTR stability and impeding TTR dissociation, the rate-limiting step of amyloid formation<sup>67</sup> (Figure 3). A tafamidis Phase II/III trial, FX-005, evaluated the efficacy and safety of tafamidis (20 mg once daily) in an 18-month randomized, double-blind, international multicenter, placebo-controlled trial that enrolled 128 patients. The primary outcome measures were a Neuropathy Impairment Score of the Lower Limbs (NIS-LL) response to treatment (responders were defined as having a < 2 points increase in the NIS-LL) and a Least-Square mean change from baseline in the Norfolk QOL-DN at 18 months. Secondary outcome measures were composite scores of large and small fiber function and the modified body mass index. Primary efficacy endpoints were analyzed in the intention-to-treat (all patients randomized) population and the efficacy-evaluable population (population that completed the study) that was prespecified, assuming a dropout of patients for liver transplant, as many of them were on the transplant waiting list. The greater proportion of patients in the tafamidis group was NIS-LL responders, who had better quality of life. In the intention-to-treat analysis, the difference was not statistically significant for NIS-LL responders (45.3% vs. 29.5%;  $p = 0.068$ ) or for the treatment group differences in the Least-Square Norfolk QOL-DN (-5.2-point difference,  $p = 0.116$ ). However, the efficacy-evaluable analysis showed significantly more NIS-LL responders (60.0% vs 38.1%,  $p = 0.041$ ) and a significantly better quality of life in the tafamidis group (Least-Square Norfolk QOL-DN -8.8-point difference,  $p = 0.045$ ). Analysis of secondary outcome measures showed that tafamidis reduced the deterioration of neurological functions and improved the nutritional status of the patients<sup>7</sup>.

This trial faced a higher than anticipated dropout rate due to liver transplants (21% observed vs. 10% estimated), equally distributed in both arms. The choice of patients who underwent a liver transplant as non-responders influenced the analyses of NIS-LL in the intention-to-treat population, possibly under-powering the effect on the NIS-LL progression. In spite of the limitation to demonstrating statistical significance in primary outcomes, the totality of the results



**Figure 3.** Tafamidis and TTR amyloid cascade. This figure is modeled after a figure published in Johnson, S.M.; Connelly, S.; Fearn, C.; Powers, E.T.; Kelly, J.W.J. *Mol. Biol.* 2012 421, 185-203.

demonstrated the potential of tafamidis to slow neurologic deterioration and maintain nutritional status<sup>8</sup>.

After completion of FX005, all 91 patients were invited to the open label phase of the study, FX006, and 86 were enrolled to receive 20 mg of tafamidis qid for 12 months. This study showed that the benefits of tafamidis were sustained for 30 months. In addition, patients who were in the placebo arm even after starting tafamidis progressed faster compared to patients who were in the first trial treatment group, and early initiation of tafamidis was associated with a better outcome<sup>68</sup>. Tafamidis provided long-term (up to six years) delay in neurological deterioration and nutritional status in Val30Met patients<sup>69</sup>, which again seemed to be greater when it was started in the early stages of the disease<sup>70</sup>.

In addition, the study Fx1A303 showed that tafamidis was also effective in stabilizing serum TTR in non-Val30Met patients<sup>71</sup>. Tafamidis did not slow disease progression in an open label trial in late-onset ATTR-FAP with advanced disease<sup>72</sup>. Recently, a *post hoc* multifaceted analysis of the intention-to-treat population in the pivotal trial provided further support for the benefits of tafamidis in delaying disease progression in ATTR-FAP<sup>73</sup>. There is strong evidence that the drug is safe, has good tolerability and few side effects (diarrhea and urinary infection). Recently, tafamidis was approved by Brazil's Health Agency (ANVISA) for the treatment of ATTR-FAP. The benefit of tafamidis in amyloid cardiomyopathy is being studied in an ongoing ATTR-FAC trial that will have results in 2018.

### Diflunisal

Diflunisal is an NSAID, developed more than 30 years ago, that non-selectively stabilizes TTR<sup>74</sup>. The diflunisal Phase II/III trial was a 24-month randomized, double-blind, international multicenter, placebo-controlled trial that enrolled 130 patients with Val30Met and non-Val30Met mutations, enrolling patients in all Coutinho stages. The primary end points were stabilization on the Neuropathy Impairment Score plus seven neurophysiological tests (NIS+7). After two years, diflunisal had reduced the disease progression with a good tolerability profile. The dropout rate was 50% in the placebo group and 25% in the treatment group. Most of the patients dropped out because of disease progression, liver transplant, and side effects<sup>9</sup>. Although the study did not show high rates of side effects in the diflunisal group, there is a big concern about the long-term complications of this NSAID in the kidneys, heart and gastrointestinal tract<sup>10</sup>. A retrospective analysis of diflunisal off-label use showed that 57% of the patients discontinued therapy, mostly because of gastrointestinal disorders<sup>75</sup>. Also, it is important to note that patients with renal dysfunction were excluded from the diflunisal trial<sup>9</sup>, and that diflunisal has not been approved for the treatment of ATTR-FAP by any health agency (off-label use only).

### TTR gene silencing

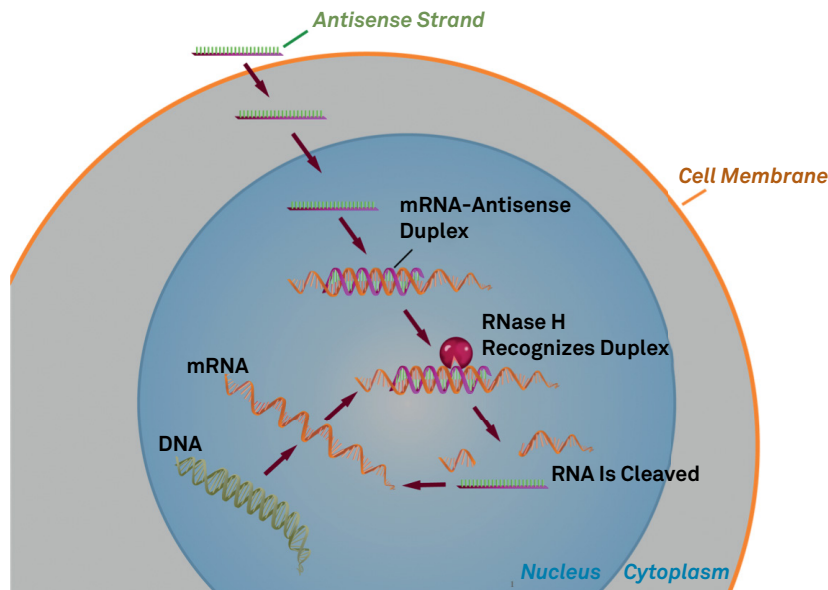
#### Inotersen

Inotersen is an anti-sense oligonucleotide that binds to TTR messenger RNA (mRNA) impeding transcription by inducing its cleavage (Figure 4). Animal and human studies have shown a robust suppression (> 80%) in TTR serum levels<sup>76,77</sup>. The Phase 3 Study IONIS-TTR Rx was a randomized, double-blind, international multicenter placebo-controlled trial, with weekly subcutaneous injections of the study drug<sup>11</sup>. Primary end-points were modified NIS+7<sub>ionis</sub> and Norfolk QOL-DN. A total of 172 patients (112 in the inotersen group and 60 in the placebo group) were included, and 139 (81%) completed the trial. For NIS+7<sub>ionis</sub> the least-squares mean change from baseline to week 66 between the two groups (inotersen minus placebo) was -19.7 points ( $p < 0.001$ ) and for the Norfolk QOL-DN -11.7 points ( $p < 0.001$ ). There were five deaths in the inotersen group and none in the placebo group. The most common serious adverse events in the inotersen group were glomerulonephritis (3 patients) and thrombocytopenia (3 patients), with one death associated with one case of severe thrombocytopenia. The other deaths in the inotersen group were due to cachexia (2), intestinal perforation (1) and congestive heart failure (1). Inotersen slowed the course of neurologic disease and improved quality of life in patients with ATTR-FAP. Recently, inotersen was approved by the European Medicines agency for treatment of patients with ATTR-FAP.

#### Patisiran

Patisiran is a small interfering RNA that binds to specific coding regions of TTR mRNA suppressing TTR production (Figure 5). Preliminary studies showed that patisiran inhibited more than 80% of TTR production<sup>79</sup>. A Phase II open label extension studied 29 patients with intravenous infusion every three weeks, and found that the optimal dose was 0.3 mg/kg, and there was potent TTR knockdown, with no difference between mutation or current use or not of TTR stabilizers. Minor-to-moderate infusion side effects were seen in a few patients and no one had an increase of liver enzymes<sup>80</sup>. After 24 months of this open-label extension, patients had a mean 6.7-point decrease in NIS+7<sub>Alnylan</sub> ( $n = 24$ ) and a significant increase in sweat gland nerve fiber density in the distal leg ( $n = 17$ ;  $p = 0.007$ )<sup>81</sup>. The APOLLO Phase 3 study was a randomized, double-blind, international multicenter placebo-controlled trial, with intravenous infusion of the study drug every three weeks<sup>12</sup>. The primary end-point was modified NIS+7<sub>Alnylan</sub>. A total of 225 patients were randomized (148 to the patisiran group and 77 to the placebo group). The least-squares mean change from baseline to 18 months between groups (patisiran minus placebo) for NIS+7<sub>Alnylan</sub> was -34.0 ( $p < 0.001$ ) and for Norfolk QOL-DN was -22.1 ( $p < 0.001$ ). Approximately 20% of the patients who received patisiran and 10% of those who received placebo had mild or moderate





RNase H: RNase helicase.

Figure 4. Inotersen proposed mechanism of action.

infusion-related reactions; the frequency and types of adverse events were similar in the two groups. Death occurred in 7 patients in the patisiran group and six patients in the placebo group. In this trial, patisiran improved numerous clinical manifestations of ATTR-FAP. Recently, patisiran was approved by the United States Food and Drug Administration agency for treatment of patients with ATTR-FAP.

### Emerging drugs

#### Clearance of amyloid deposits

There are huge expectations with these drugs as other treatments only reduce or halt progression of ATTR-FAP, and these drugs may improve symptoms and signs by amyloid removal from tissues. There is promising animal data with the combination of doxycycline and tauroursodeoxycholic acid<sup>83</sup> and there are ongoing clinical trials trying to extend these good results to humans<sup>84, 85</sup>. Another two studies are evaluating monoclonal antibodies that specifically bind to deposited amyloid, producing a local inflammatory response and amyloid removal from tissues<sup>86, 87</sup>.

### CONCLUSIONS

We hope this set of recommendations made by Brazilian neurologists will foster knowledge about ATTR-FAP and include this as an important differential diagnosis of progressive polyneuropathies, especially when patients have one or more of the red flags presented above. It is, therefore, very likely (and actually seen in our daily practices) that a considerable (yet unknown) number of ATTR-FAP patients are being treated as leprosy, CIDP or other diagnoses. With the

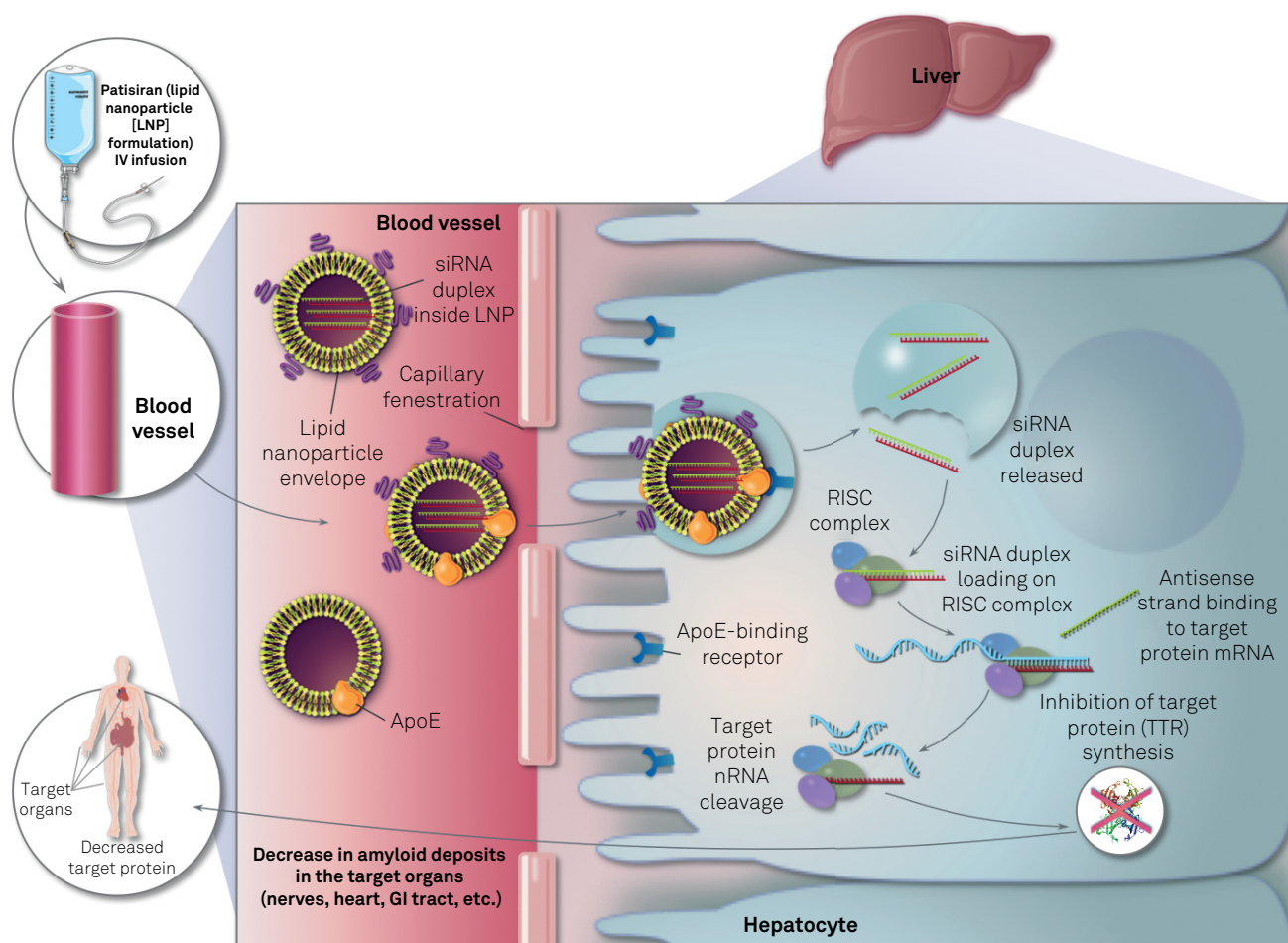
development of new therapies, approval of tafamidis by the Brazilian Health Agency (ANVISA), and long-standing liver transplant experience, early diagnosis is even more important, and we aim to shorten the delay to diagnosis and treatment.

### ACKNOWLEDGMENTS

The authors thank Professor Nathalie Canedo (Universidade Federal do Rio de Janeiro, Rio de Janeiro, RJ, Brazil) for providing the salivary gland biopsy figure; Professor Luciano Neder, Professor Luis Lamberti Pinto da Silva, Renato Meirelles e Silva, Maria Cristina Lopes Schiavoni and Elizabete Rosa (Universidade de São Paulo, Ribeirão Preto, SP, Brazil) for the nerve biopsy epoxy sections, nerve histograms and electropherogram of the *TTR* gene figure, which were coordinated by two of the authors (AAB and WMJ); Professor Jeffery Kelly (The Scripps Research Center, La Jolla, CA, USA), for the tafamidis and TTR amyloid cascade figure; IONIS pharmaceuticals (Carlsbad, CA, USA) for the inotersen mechanism of action figure; and Sanofi Genzyme (Cambridge, MA, USA) for the patisiran mechanism of action figure.

### NOTE

Due to recent publication of two randomized clinical trials (RCTs) in ATTR-FAP<sup>11, 12</sup> the authors agreed to add the results of these studies in this manuscript, which were published after the consensus. A consensus was reached for the final text, and all authors approved the final version of the manuscript.



siRNA: small interfering RNA; ApoE: apolipoprotein E; RISC: RNA-Induced Silencing Complex.

**Figure 5.** Patisiran proposed mechanism of action.

## References

1. Sekijima Y. Transthyretin (ATTR) amyloidosis: clinical spectrum, molecular pathogenesis and disease-modifying treatments. *J Neurol Neurosurg Psychiatry*. 2015 Sep;86(9):1036-43. <https://doi.org/10.1136/jnnp-2014-308724>
2. Benson MD, Kincaid JC. The molecular biology and clinical features of amyloid neuropathy. *Muscle Nerve*. 2007 Oct;36(4):411-23. <https://doi.org/10.1002/mus.20821>
3. Coutinho PD, Lima JL, Barbosa AR. Forty years of experience with type I amyloid neuropathy: review of 483 cases. In: Glenner GG, de Freitas AF, editors. *Amyloid and amyloidosis*. Amsterdam: Excerpta Medica; 1980. pp. 88-98.
4. Cruz MW. Regional differences and similarities of familial amyloidotic polyneuropathy (FAP) presentation in Brazil. *Amyloid*. 2012 Jun;19(suppl 1):65-7. <https://doi.org/10.3109/13506129.2012.673183>
5. Koike H, Misu K, Ikeda S, Ando Y, Nakazato M, Ando E et al. Type I (transthyretin Met30) familial amyloid polyneuropathy in Japan: early- vs late-onset form. *Arch Neurol*. 2002 Nov;59(11):1771-6. <https://doi.org/10.1001/archneur.59.11.1771>
6. Adams D, Samuel D, Goulon-Goeau C, Nakazato M, Costa PM, Feray C et al. The course and prognostic factors of familial amyloid polyneuropathy after liver transplantation. *Brain*. 2000 Jul;123(Pt 7):1495-504. <https://doi.org/10.1093/brain/123.7.1495>
7. Coelho T, Maia LF, Silva AM, Waddington Cruz M, Planté-Bordeneuve V, Lozeron P et al. Tafamidis for transthyretin familial amyloid polyneuropathy: a randomized, controlled trial. *Neurology*. 2012 Aug;79(8):785-92. <https://doi.org/10.1212/WNL.0b013e3182661eb1>
8. Waddington Cruz M, Benson MD. A review of tafamidis for the treatment of transthyretin-related amyloidosis. *Neurol Ther*. 2015 Dec;4(2):61-79. <https://doi.org/10.1007/s40120-015-0031-3>
9. Berk JL, Suhr OB, Obici L, Sekijima Y, Zeldenrust SR, Yamashita T et al. Repurposing diflunisal for familial amyloid polyneuropathy: a randomized clinical trial. *JAMA*. 2013 Dec;310(24):2658-67. <https://doi.org/10.1001/jama.2013.283815>
10. Adams D, Suhr OB, Hund E, Obici L, Tournev I, Campistol JM et al. First European consensus for diagnosis, management, and treatment of transthyretin familial amyloid polyneuropathy. *Curr Opin Neurol*. 2016 Feb;29 Suppl 1:S14-26. <https://doi.org/10.1097/WCO.0000000000000289>
11. Benson MD, Waddington-Cruz M, Berk JL, et al. Inotersen Treatment for Patients with Hereditary Transthyretin Amyloidosis. *New England Journal of Medicine* 2018;379:22-31.
12. Adams D, Gonzalez-Duarte A, O'Riordan WD, et al. Patisiran, an RNAi Therapeutic, for Hereditary Transthyretin Amyloidosis. *New England Journal of Medicine* 2018;379:11-21.
13. Gomes MM. [Principles of the Familial transthyretin amyloidosis TTR Val30Met and the beginning of the Paramyloidosis Center of Antonio Rodrigues de Mello]. *Rev Bras Neurol*. 2011 abr-jun;47(2):7-21. Portuguese.

14. Ando Y, Coelho T, Berk JL, Cruz MW, Ericzon BG, Ikeda S et al. Guideline of transthyretin-related hereditary amyloidosis for clinicians. *Orphanet J Rare Dis.* 2013 Feb;8(1):31. <https://doi.org/10.1186/1750-1172-8-31>
15. Schmidt H, Cruz MW, Botteman MF, Carter JA, Chopra A, Stewart M et al. Global epidemiology of transthyretin hereditary amyloid polyneuropathy: a systematic review. *Amyloid.* 2017 Mar;24 sup1:111-2. <https://doi.org/10.1080/13506129.2017.1292903>
16. Sousa A, Coelho T, Barros J, Sequeiros J. Genetic epidemiology of familial amyloidotic polyneuropathy (FAP)-type I in Póvoa do Varzim and Vila do Conde (north of Portugal). *Am J Med Genet.* 1995 Dec;60(6):512-21. <https://doi.org/10.1002/ajmg.1320600606>
17. Hellman UAFB-P C, Lundgren HE, Planté-Bordeneuve V, Suhr O. Heterogeneity of penetrance in familial amyloid polyneuropathy, ATTR Val30Met, in the Swedish population. *Amyloid.* 2008 Sep;15(3):181-6. <https://doi.org/10.1080/13506120802193720>
18. Planté-Bordeneuve V, Carayol J, Ferreira A, Adams D, Clerget-Darpoux F, Misrahi M et al. Genetic study of transthyretin amyloid neuropathies: carrier risks among French and Portuguese families. *J Med Genet.* 2003 Nov;40(11):e120. <https://doi.org/10.1136/jmg.40.11.e120>
19. Saporta MA, Zarus C, Cruz MW, André C, Misrahi M, Bonaïti-Pellié C et al. Penetrance estimation of TTR familial amyloid polyneuropathy (type I) in Brazilian families. *Eur J Neurol.* 2009 Mar;16(3):337-41. <https://doi.org/10.1111/j.1468-1331.2008.02429.x>
20. Schmidt H, Waddington-Cruz M, Botteman MF, Carter JA, Chopra AS, Stewart M et al. Global prevalence estimates of transthyretin familial amyloid polyneuropathy (ATTR-FAP): a systematic review and projections. In: *The 19th Annual European Congress of International Society for Pharmacoeconomics and Outcomes Research, 2016, Vienna, Austria.*
21. Sobue G, Nakao N, Murakami K, Yasuda T, Sahashi K, Mitsuma T et al. Type I familial amyloid polyneuropathy. A pathological study of the peripheral nervous system. *Brain.* 1990 Aug;113(Pt 4):903-19. <https://doi.org/10.1093/brain/113.4.903>
22. Misu K, Hattori N, Nagamatsu M, Ikeda S, Ando Y, Nakazato M et al. Late-onset familial amyloid polyneuropathy type I (transthyretin Met30-associated familial amyloid polyneuropathy) unrelated to endemic focus in Japan. Clinicopathological and genetic features. *Brain.* 1999 Oct;122(Pt 10):1951-62. <https://doi.org/10.1093/brain/122.10.1951>
23. Planté-Bordeneuve V, Said G. Familial amyloid polyneuropathy. *Lancet Neurol.* 2011 Dec;10(12):1086-97. [https://doi.org/10.1016/S1474-4422\(11\)70246-0](https://doi.org/10.1016/S1474-4422(11)70246-0)
24. Bonaïti B, Olsson M, Hellman U, Suhr O, Bonaïti-Pellié C, Planté-Bordeneuve V. TTR familial amyloid polyneuropathy: does a mitochondrial polymorphism entirely explain the parent-of-origin difference in penetrance? *Eur J Hum Genet.* 2010 Aug;18(8):948-52. <https://doi.org/10.1038/ejhg.2010.36>
25. Cruz MW, Schmidt H, Botteman MF, Carter JA, Chopra AS, Stewart M et al. Epidemiological and clinical characteristics of persons with transthyretin hereditary amyloid polyneuropathy: a global synthesis of 532 cases. *Amyloid.* 2017 Mar;24 sup1:109-10. <https://doi.org/10.1080/13506129.2017.1292902>
26. Cruz MW, Foguel D, Berensztejn AC, Pedrosa RC, Mundayat R, Ong ML. The demographic, genetic, and clinical characteristics of Brazilian subjects enrolled in the Transthyretin Amyloidosis Outcomes Survey. *Amyloid.* 2017 Mar;24 sup1:103-4. <https://doi.org/10.1080/13506129.2017.1291423>
27. Zarus C, Genin E, Hellman U, Saporta MA, Languille L, Waddington-Cruz M et al. On the origin of the transthyretin Val30Met familial amyloid polyneuropathy. *Ann Hum Genet.* 2008 Jul;72(Pt 4):478-84. <https://doi.org/10.1111/j.1469-1809.2008.00439.x>
28. Ohmori H, Ando Y, Makita Y, Onouchi Y, Nakajima T, Saraiva MJ et al. Common origin of the Val30Met mutation responsible for the amyloidogenic transthyretin type of familial amyloidotic polyneuropathy. *J Med Genet.* 2004 Apr;41(4):e51. <https://doi.org/10.1136/jmg.2003.014803>
29. Rapezzi C, Quarta CC, Riva L, Longhi S, Gallelli I, Lorenzini M et al. Transthyretin-related amyloidosis and the heart: a clinical overview. *Nat Rev Cardiol.* 2010 Jul;7(7):398-408. <https://doi.org/10.1038/nrcardio.2010.67>
30. Jacobson DR, Pastore R, Pool S, Malendowicz S, Kane I, Shivji A et al. Revised transthyretin Ile 122 allele frequency in African-Americans. *Hum Genet.* 1996 Aug;98(2):236-8. <https://doi.org/10.1007/s004390050199>
31. Yamashita T, Hamidi Asl K, Yazaki M, Benson MD. A prospective evaluation of the transthyretin Ile122 allele frequency in an African-American population. *Amyloid.* 2005 Jun;12(2):127-30. <https://doi.org/10.1080/13506120500107162>
32. Cruz MW, Barroso F, González-Duarte A, Mundayat R, Ong ML. The demographic, genetic, and clinical characteristics of Latin American subjects enrolled in the Transthyretin Amyloidosis Outcomes Survey. *Amyloid.* 2017 Mar;24 sup1:107-8. <https://doi.org/10.1080/13506129.2017.1292239>
33. Bittencourt PL, Couto CA, Clemente C, Farias AQ, Palácios SA, Mies S et al. Phenotypic expression of familial amyloid polyneuropathy in Brazil. *Eur J Neurol.* 2005 Apr;12(4):289-93. <https://doi.org/10.1111/j.1468-1331.2004.00941.x>
34. Conceição I, De Carvalho M. Clinical variability in type I familial amyloid polyneuropathy (Val30Met): comparison between late- and early-onset cases in Portugal. *Muscle Nerve.* 2007 Jan;35(1):116-8. <https://doi.org/10.1002/mus.20644>
35. Mariani LL, Lozeron P, Théaudin M, Mincheva Z, Signate A, Ducot B et al. Genotype-phenotype correlation and course of transthyretin familial amyloid polyneuropathies in France. *Ann Neurol.* 2015 Dec;78(6):901-16. <https://doi.org/10.1002/ana.24519>
36. Koike H, Tanaka F, Hashimoto R, Tomita M, Kawagashira Y, Iijima M et al. Natural history of transthyretin Val30Met familial amyloid polyneuropathy: analysis of late-onset cases from non-endemic areas. *J Neurol Neurosurg Psychiatry.* 2012 Feb;83(2):152-8. <https://doi.org/10.1136/jnnp-2011-301299>
37. Dohrn MF, Röcken C, De Bleeker JL, Martin JJ, Vorgerd M, Van den Bergh PY et al. Diagnostic hallmarks and pitfalls in late-onset progressive transthyretin-related amyloid-neuropathy. *J Neurol.* 2013 Dec;260(12):3093-108. <https://doi.org/10.1007/s00415-013-7124-7>
38. Swiecicki PL, Zhen DB, Mauermann ML, Kyle RA, Zeldenrust SR, Grogan M et al. Hereditary ATTR amyloidosis: a single-institution experience with 266 patients. *Amyloid.* 2015;22(2):123-31. <https://doi.org/10.3109/13506129.2015.1019610>
39. Andrade C. A peculiar form of peripheral neuropathy; familiar atypical generalized amyloidosis with special involvement of the peripheral nerves. *Brain.* 1952 Sep;75(3):408-27. <https://doi.org/10.1093/brain/75.3.408>
40. Ando Y, Nakamura M, Araki S. Transthyretin-related familial amyloidotic polyneuropathy. *Arch Neurol.* 2005 Jul;62(7):1057-62. <https://doi.org/10.1001/archneur.62.7.1057>
41. Coelho T, Sousa A, Lourenço E, Ramalheira J. A study of 159 Portuguese patients with familial amyloidotic polyneuropathy (FAP) whose parents were both unaffected. *J Med Genet.* 1994 Apr;31(4):293-9. <https://doi.org/10.1136/jmg.31.4.293>
42. Adams D, Lozeron P, Theaudin M, Mincheva Z, Cauquil C, Adam C et al. Regional difference and similarity of familial amyloidosis with polyneuropathy in France. *Amyloid.* 2012 Jun;19(sup1 Suppl 1):61-4. <https://doi.org/10.3109/13506129.2012.685665>
43. Ikeda S, Hanyu N, Hongo M, Yoshioka J, Oguchi H, Yanagisawa N et al. Hereditary generalized amyloidosis with polyneuropathy. Clinicopathological study of 65 Japanese patients. *Brain.* 1987 Apr;110(Pt 2):315-37. <https://doi.org/10.1093/brain/110.2.315>
44. Maurer MS, Hanna M, Grogan M, Dispenzieri A, Witteles R, Drachman B et al. Genotype and phenotype of transthyretin cardiac amyloidosis: THAOS (Transthyretin Amyloid Outcome Survey). *J Am Coll Cardiol.* 2016 Jul;68(2):161-72. <https://doi.org/10.1016/j.jacc.2016.03.596>



45. Queiroz MC, Pedrosa RC, Berensztejn AC, Pereira BB, Nascimento EM, Duarte MM et al. Frequency of cardiovascular involvement in familial amyloidotic polyneuropathy in Brazilian patients. *Arq Bras Cardiol.* 2015 Nov;105(5):503-9.
46. Ando E, Ando Y, Okamura R, Uchino M, Ando M, Negi A. Ocular manifestations of familial amyloidotic polyneuropathy type I: long-term follow up. *Br J Ophthalmol.* 1997 Apr;81(4):295-8. <https://doi.org/10.1136/bjo.81.4.295>
47. Lobato L, Rocha A. Transthyretin amyloidosis and the kidney. *Clin J Am Soc Nephrol.* 2012 Aug;7(8):1337-46. <https://doi.org/10.2215/CJN.08720811>
48. Maia LF, Magalhães R, Freitas J, Taipa R, Pires MM, Osório H et al. CNS involvement in V30M transthyretin amyloidosis: clinical, neuropathological and biochemical findings. *J Neurol Neurosurg Psychiatry.* 2015 Feb;86(2):159-67. <https://doi.org/10.1136/jnnp-2014-308107>
49. Cruz MW, Foguel D, Berensztejn A, Pedrosa R, Silva PF. The phenotypical expression of an European inherited TTR amyloidosis in Brazil. *Orphanet J Rare Dis.* 2015;10( Suppl 1):O7. <https://doi.org/10.1186/1750-1172-10-S1-O7>
50. Conceição I, González-Duarte A, Obici L, Schmidt hh, Simoneau D, Ong ML et al. "Red-flag" symptom clusters in transthyretin familial amyloid polyneuropathy. *Journal of the Peripheral Nervous System* 2016;21(1):5-9. <https://doi.org/10.1111/jns.12153>
51. Vital C, Vital A, Bouillot-Eimer S, Brechenmacher C, Ferrer X, Laguery A. Amyloid neuropathy: a retrospective study of 35 peripheral nerve biopsies. *J Peripher Nerv Syst.* 2004 Dec;9(4):232-41. <https://doi.org/10.1111/j.1085-9489.2004.09405.x>
52. Amaral B, Coelho T, Sousa A, Guimarães A. Usefulness of labial salivary gland biopsy in familial amyloid polyneuropathy Portuguese type. *Amyloid.* 2009 Dec;16(4):232-8. <https://doi.org/10.3109/13506120903421850>
53. Eduardo FP, Bezinelli LM, Carvalho DLC, Della-Guardia B, Almeida MD, Maris LV et al. Minor salivary gland biopsy for the diagnosis of familial amyloid polyneuropathy. *Neurological sciences : official journal of the Italian Neurological Society and of the Italian Society of Clinical Neurophysiology* 2017;38:311-318. <https://doi.org/10.1007/s10072-016-2760-1>
54. Schonhoft JD, Monteiro C, Plate L, Eisele YS, Kelly JM, Boland D et al. Peptide probes detect misfolded transthyretin oligomers in plasma of hereditary amyloidosis patients. *Sci Transl Med.* 2017 Sep;9(407):9. <https://doi.org/10.1126/scitranslmed.aam7621>
55. Cortese A, Vegezzi E, Lozza A, Alfonsi E, Montini A, Moglia A et al. Diagnostic challenges in hereditary transthyretin amyloidosis with polyneuropathy: avoiding misdiagnosis of a treatable hereditary neuropathy. *J Neurol Neurosurg Psychiatry.* 2017 May;88(5):457-8. <https://doi.org/10.1136/jnnp-2016-315262>
56. Planté-Bordeneuve V, Ferreira A, Lalu T, Zaros C, Lacroix C, Adams D et al. Diagnostic pitfalls in sporadic transthyretin familial amyloid polyneuropathy (TTR-FAP). *Neurology.* 2007 Aug;69(7):693-8. <https://doi.org/10.1212/01.wnl.0000267338.45673.f4>
57. Gertz MA, Benson MD, Dyck PJ, Grogan M, Coelho T, Cruz M et al. Diagnosis, Prognosis, and Therapy of Transthyretin Amyloidosis. *J Am Coll Cardiol.* 2015 Dec;66(21):2451-66. <https://doi.org/10.1016/j.jacc.2015.09.075>
58. Carvalho A, Rocha A, Lobato L. Liver transplantation in transthyretin amyloidosis: issues and challenges. *Liver Transpl.* 2015 Mar;21(3):282-92. <https://doi.org/10.1002/lt.24058>
59. Holmgren G, Steen L, Ekstedt J, Groth CG, Ericzon BG, Eriksson S et al. Biochemical effect of liver transplantation in two Swedish patients with familial amyloidotic polyneuropathy (FAP-met30). *Clin Genet.* 1991 Sep;40(3):242-6. <https://doi.org/10.1111/j.1399-0004.1991.tb03085.x>
60. Bittencourt PL, Couto CA, Farias AQ, Marchiori P, Bosco Massarollo PC, Mies S. Results of liver transplantation for familial amyloid polyneuropathy type I in Brazil. *Liver Transpl.* 2002 Jan;8(1):34-9. <https://doi.org/10.1053/jlts.2002.29764>
61. Holmgren G, Ericzon BG, Groth CG, Steen L, Suhr O, Andersen O et al. Clinical improvement and amyloid regression after liver transplantation in hereditary transthyretin amyloidosis. *Lancet.* 1993 May;341(8853):1113-6. [https://doi.org/10.1016/0140-6736\(93\)93127-M](https://doi.org/10.1016/0140-6736(93)93127-M)
62. Suhr OB, Holmgren G, Steen L, Wikström L, Norden G, Friman S et al. Liver transplantation in familial amyloidotic polyneuropathy. Follow-up of the first 20 Swedish patients. *Transplantation.* 1995 Nov;60(9):933-8. <https://doi.org/10.1097/00007890-199511150-00009>
63. Dubrey SW, Davidoff R, Skinner M, Bergethon P, Lewis D, Falk RH. Progression of ventricular wall thickening after liver transplantation for familial amyloidosis. *Transplantation.* 1997 Jul;64(1):74-80. <https://doi.org/10.1097/00007890-199707150-00014>
64. Stangou AJ, Hawkins PN, Heaton ND, Rela M, Monaghan M, Nihoyannopoulos , et al. Progressive cardiac amyloidosis following liver transplantation for familial amyloid polyneuropathy: implications for amyloid fibrillogenesis. *Transplantation.* 1998 Jul;66(2):229-33. <https://doi.org/10.1097/00007890-199807270-00016>
65. Ericzon BG, Wilczek HE, Larsson M, Wijayatunga P, Stangou A, Pena JR et al. Liver transplantation for hereditary transthyretin amyloidosis: after 20 years still the best therapeutic alternative? *Transplantation.* 2015 Sep;99(9):1847-54. <https://doi.org/10.1097/TP.0000000000000574>
66. Beirão JM, Malheiro J, Lemos C, Matos E, Beirão I, Pinho-Costa P et al. Impact of liver transplantation on the natural history of oculopathy in Portuguese patients with transthyretin (V30M) amyloidosis. *Amyloid.* 2015 Mar;22(1):31-5. <https://doi.org/10.3109/13506129.2014.989318>
67. Coelho T, Merlini G, Bulawa CE, Fleming JA, Judge DP, Kelly JW et al. Mechanism of action and clinical application of Tafamidis in hereditary transthyretin amyloidosis. *Neurol Ther.* 2016 Jun;5(1):1-25. <https://doi.org/10.1007/s40120-016-0040-x>
68. Coelho T, Maia LF, Silva AM, Cruz MW, Planté-Bordeneuve V, Suhr OB et al. Long-term effects of tafamidis for the treatment of transthyretin familial amyloid polyneuropathy. *J Neurol.* 2013 Nov;260(11):2802-14. <https://doi.org/10.1007/s00415-013-7051-7>
69. Barroso FA, Judge DP, Ebede B, Li, H, Stewart M, Amass L et al. Long-term safety and efficacy of tafamidis for the treatment of hereditary transthyretin amyloid polyneuropathy: results up to 6 years. *Amyloid.* 2017;24(3):194-204. <https://doi.org/10.1080/13506129.2017.1357545>
70. Waddington Cruz M, Amass L, Keohane D, Schwartz J, Li H, Gundapaneni B. Early intervention with tafamidis provides long-term (5.5-year) delay of neurologic progression in transthyretin hereditary amyloid polyneuropathy. *Amyloid.* 2016 Sep;23(3):178-83. <https://doi.org/10.1080/13506129.2016.1207163>
71. Merlini G, Planté-Bordeneuve V, Judge DP, Schmidt H, Obici L, Perlino S et al. Effects of tafamidis on transthyretin stabilization and clinical outcomes in patients with non-Val30Met transthyretin amyloidosis. *J Cardiovasc Transl Res.* 2013 Dec;6(6):1011-20. <https://doi.org/10.1007/s12265-013-9512-x>
72. Lozeron P, Théaudin M, Mincheva Z, Ducot B, Lacroix C, Adams D. Effect on disability and safety of Tafamidis in late onset of Met30 transthyretin familial amyloid polyneuropathy. *Eur J Neurol.* 2013 Dec;20(12):1539-45. <https://doi.org/10.1111/ene.12225>
73. Keohane D, Schwartz J, Gundapaneni B, Stewart M, Amass L. Tafamidis delays disease progression in patients with early stage transthyretin familial amyloid polyneuropathy: additional supportive analyses from the pivotal trial. *Amyloid.* 2017;24(1):30-6. <https://doi.org/10.1080/13506129.2017.1301419>
74. Adams D, Cauquil C, Labeyrie C, Beaudonnet G, Algalarrondo V, Théaudin M. TTR kinetic stabilizers and TTR gene silencing: a new era in therapy for familial amyloidotic polyneuropathies. *Expert Opin Pharmacother.* 2016;17(6):791-802. <https://doi.org/10.1517/14656566.2016.1145664>

75. Whelan CJ, Dungu J, Pinney J, Gibbs S, Banypersad S, Venner C et al. GJDaHPN. Tolerability of diflunisal therapy in patients with transthyretin amyloidosis. In: XIII International Symposium on Amyloidosis, 6–10 May 2012, Groningen, Netherlands. Abstract OP 56.
76. Ackermann EJ, Guo S, Booten S, Alvarado L, Benson M, Hughes S et al. Clinical development of an antisense therapy for the treatment of transthyretin-associated polyneuropathy. *Amyloid*. 2012 Jun;19(suppl 1):43-4. <https://doi.org/10.3109/13506129.2012.673140>
77. Ackermann EJ, Guo S, Benson MD, Booten S, Freier S, Hughes SG et al. Suppressing transthyretin production in mice, monkeys and humans using 2nd-Generation antisense oligonucleotides. *Amyloid*. 2016;23(3):148-57. <https://doi.org/10.1080/13506129.2016.1191458>
78. Coelho T, Adams D, Silva A, Lozeron P, Hawkins PN, Mant T et al. Safety and efficacy of RNAi therapy for transthyretin amyloidosis. *N Engl J Med*. 2013 Aug;369(9):819-29. <https://doi.org/10.1056/NEJMoa1208760>
79. Suhr OB, Coelho T, Buades J, Pouget J, Conceicao I, Berk J et al. Efficacy and safety of patisiran for familial amyloidotic polyneuropathy: a phase II multi-dose study. *Orphanet J Rare Dis*. 2015 Sep;10(1):109. <https://doi.org/10.1186/s13023-015-0326-6>
80. Adams D, Coelho T, Conceição I, Cruz MW, Schmidt H, Buades J et al. Phase 2 Open-Label Extension (OLE) Study of Patisiran, an Investigational RNA interference (RNAi) Therapeutic for the Treatment of Hereditary ATTR Amyloidosis with Polyneuropathy (S27.004). *Neurology*. 2017 Apr;88(16 Suppl).
81. Cardoso I, Martins D, Ribeiro T, Merlini G, Saraiva MJ. Synergy of combined doxycycline/TUDCA treatment in lowering Transthyretin deposition and associated biomarkers: studies in FAP mouse models. *J Transl Med*. 2010 Jul;8(1):74. <https://doi.org/10.1186/1479-5876-8-74>
82. Brigham and Women's Hospital. Tolerability and efficacy of a combination of doxycycline and TUDCA in patients with Transthyretin Amyloid Cardiomyopathy. *Clinical Trials gov* NCT01855360. 2013 [access 2017 May 10]. Available from: <https://clinicaltrials.gov/ct2/archive/NCT01855360>
83. IRCCS Policlinico S. Matteo. Safety, efficacy and pharmacokinetics of doxycycline plus tauroursodeoxycholic acid in transthyretin amyloidosis. *Clinical-Trials gov* NCT01171859. 2010 [access 2017 May 10]. Available from: <https://clinicaltrials.gov/ct2/show/NCT01171859>
84. Therapeutics P. Phase 1/2, open label, dose escalation study of NEOD001 in subjects with light chain (AL) amyloidosis. *Clinical-Trials gov* NCT01707264. 2012 [access 2017 May 10]. Available from: <https://clinicaltrials.gov/ct2/show/NCT01707264>
85. GlaxoSmithKline. A study to evaluate the safety of GSK2398852 when co-administered with GSK2315698 in patients with systemic amyloidosis. *ClinicalTrials gov* NCT01777243. 2013 [Accessed 87. 1 [access 2017 May 10]. Available from: <https://www.clinicaltrials.gov/ct2/show/NCT01777243>