

New Magnetic Resonance Imaging (MRI) findings in a patient with hypochondroplasia caused by the *FGFR3* N540K variant

Novos achados de ressonância magnética (RM) em um paciente com hipocondroplasia causada pela variante *FGFR3* N540K

Paula Maria Preto MIMURA¹, José Thiago de Souza de CASTRO², Vinicius de Menezes JARRY², Marcondes Cavalcanti FRANÇA JÚNIOR³, Fabiano REIS²

A 7-year-old boy with hypochondroplasia had neurodevelopmental delay, mild cognitive impairment, subtle motor deficits and without epilepsy. There was no obstetric problem or perinatal impairment. Genetic revealed the p.N540K *FGFR3* variant. MRI findings are depicted (Figure 1).

FGFR3 regulates chondrocyte proliferation and differentiation and is instrumental in cortical patterning and neurogenesis¹. Temporal lobe dysgenesis is common in *FGFR3*-related hypochondroplasia^{2,3}. Squared and enlarged lateral ventricles, with reduced peritrigonal white matter (WM) have

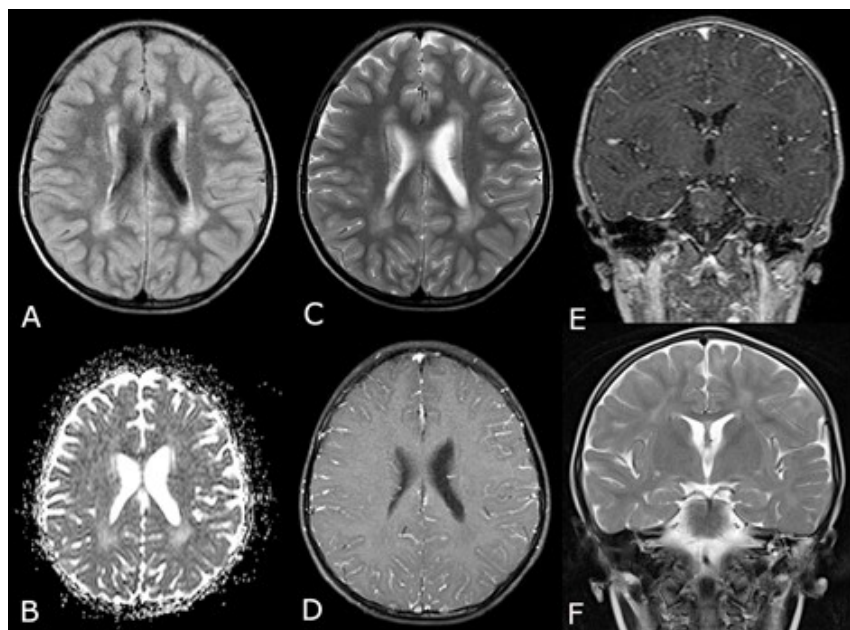





Figure 1. (A) Axial FLAIR-weighted image shows posterior periventricular white-matter hyperintensities. (B) Axial Apparent diffusion coefficient (ADC) map showing hyperintensities in the periventricular white-matter (reflecting absence of restricted diffusion). (C) Axial T2-weighted image shows posterior periventricular white-matter hyperintensities. (D) Axial and (E) Coronal T1-weighted image after gadolinium contrast, demonstrating absence of enhancement. (F) Coronal T2-weighted image without evidence of hippocampal abnormalities.

¹Pontifícia Universidade Católica de São Paulo, Faculdade de Medicina, Departamento de Reprodução Humana e Infância, Sorocaba, SP, Brazil.

²Universidade Estadual de Campinas, Faculdade de Ciências Médicas, Departamento de Radiologia, Campinas, SP, Brazil.

³Universidade Estadual de Campinas, Faculdade de Ciências Médicas, Departamento de Neurologia, Campinas, SP, Brazil.

Paula Maria Preto Mimura  <https://orcid.org/0000-0001-9041-5047>; José Thiago de Souza de Castro  <https://orcid.org/0000-0002-6009-8607>; Vinicius de Menezes Jarry  <https://orcid.org/0000-0002-7391-1193>; Marcondes Cavalcanti França Júnior  <https://orcid.org/0000-0003-0898-2419>; Fabiano Reis  <https://orcid.org/0000-0003-2256-4379>

Correspondence: Fabiano Reis; Email: fabianoreis2@gmail.com.

Conflict of interest: There is no conflict of interest to declare.

Authors' contribution: VMJ, PMPM and JTSC: acquisition of data and writing the initial drafts of the manuscript; MCFJ: acquisition of data and critical revision; FR: concept, acquisition of data and critical revision of the manuscript for intellectual content.

Received on September 09, 2020; Received in its final form on September 27, 2020; Accepted on October 07, 2020.

been described², but periventricular WM hyperintensities on T2/FLAIR weighted images, as demonstrated here, were not reported previously.

Such WM lesions expand the neuroimaging signature in FGFR3-related hypochondroplasia.

REFERENCES

1. Hevner RF. The cerebral cortex malformation in thanatophoric dysplasia: neuropathology and pathogenesis. *Acta Neuropathol.* 2005 Sep;110(3):208-21.
2. Linnankivi T, Mäkitie O, Valanne L, Toiviainen-Salo S. Neuroimaging and neurological findings in patients with hypochondroplasia and FGFR3 N540K mutation. *Am J Med Genet A.* 2012;158A(12):3119-25. <https://doi.org/10.1002/ajmg.a.35642>
3. Philpott CM, Widjaja E, Raybaud C, Branson HM, Kannu P, Blaser S. Temporal and occipital lobe features in children with hypochondroplasia/FGFR3 gene mutation. *Pediatr Radiol.* 2013 Sep;43(9):1190-5. <https://doi.org/10.1007/s00247-013-2684-3>