

Dysgenesis of the posterior segment of the corpus callosum: don't miss SPG45!

Disgenesia do segmento posterior do corpo caloso: lembre-se da SPG45!

Daniel de Faria Guimarães^{1,2} Ana Luiza Viegas de Almeida³ Felipe Alba Scortegagna^{1,2}
Renato Hoffmann Nunes^{1,2} Simone Consuelo Amorim³ Felipe Torres Pacheco^{1,2}
Fernando Kok^{4,5} Antonio José da Rocha^{1,2}

¹ Santa Casa de Misericórdia de São Paulo, Faculdade de Ciências Médicas, Departamento de Radiologia, São Paulo SP, Brazil.

² Grupo DASA São Paulo, Departamento de Radiologia, São Paulo SP, Brazil.

³ Clínica Vita, Departamento de Neurologia Pediátrica, São Paulo SP, Brazil.

⁴ Universidade de São Paulo, Faculdade de Medicina, Departamento de Neurologia, São Paulo SP, Brazil.

⁵ Mendelics Análise Genômica, São Paulo SP, Brazil.

Address for correspondence Felipe Torres Pacheco (email: felipetorrespacheco@hotmail.com).

Arq. Neuropsiquiatr. 2023;81(3):322–323.

In hereditary spastic paraplegias (HSPs), magnetic resonance imaging (MRI) scans of the brain typically show the involvement of the anterior part of the corpus callosum with abnormalities in the white matter fibers of the fornice minor (“ears of the lynx sign”). However, these

imaging findings are particularly associated with spastic paraplegia type 11 (SPG11) or spastic paraplegia type 15 (SPG15).¹

A child with spastic gait achieved independent walking at the age of 2 years, and 3 years later was referred to our service

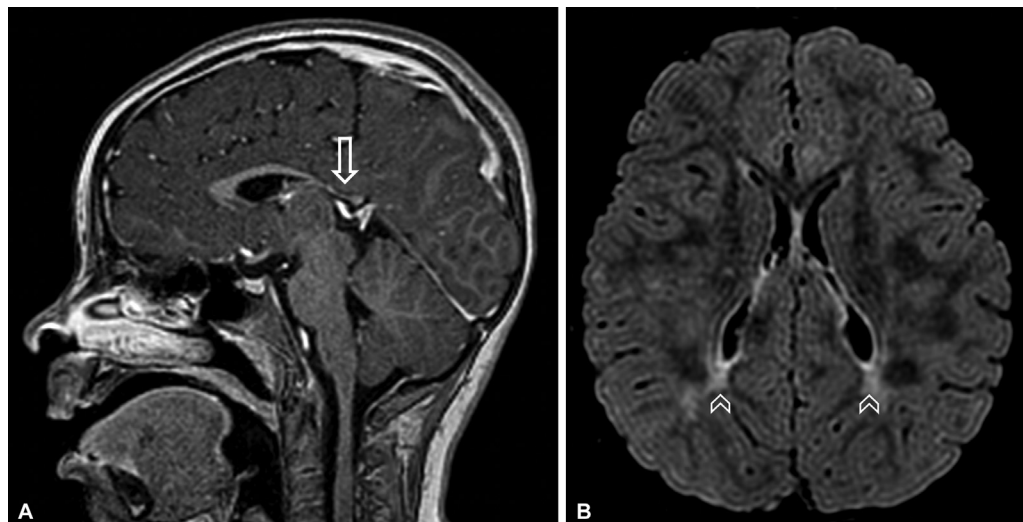


Figure 1 Brain MRI. (A) Sagittal T1 postcontrast shows hypoplastic corpus callosum with marked reduction of the splenium and posterior segment of its body (arrows), characteristic, even though not specific, of this disease. (B) Axial fluid-attenuated inversion recovery (FLAIR) demonstrates symmetric and bilateral peritrigonal white matter changes (arrowheads). The ears of the lynx sign is not usually observed in these cases.

received
August 19, 2022
received in its final form
October 13, 2022
accepted
October 21, 2022

DOI <https://doi.org/10.1055/s-0043-1763299>.
ISSN 0004-282X.

© 2023. Academia Brasileira de Neurologia. All rights reserved.
This is an open access article published by Thieme under the terms of the Creative Commons Attribution 4.0 International License, permitting copying and reproduction so long as the original work is given appropriate credit (<https://creativecommons.org/licenses/by/4.0/>).
Thieme Revinter Publicações Ltda., Rua do Matoso 170, Rio de Janeiro, RJ, CEP 20270-135, Brazil

for investigation. A brain MRI demonstrated corpus callosum dysgenesis and peritrigonal white matter abnormality (► **Figure 1**). Whole exome sequencing revealed compound heterozygosity for two novel likely pathogenic variants in *NT5C2* (p.[Leu468Pro] and p.[Gln542Argfs*71]), consistent with SPG45, of the SPG subtypes with thin corpus callosum.²

Authors' Contributions

DFG: selection of imaging scans and writing of the manuscript; ALVA: writing of the manuscript; FAS, RHN, SCA, FTP, FK, AJR: study concept, interpretation of data, and critical revision of the manuscript.

Conflict of Interest

The authors have no conflict of interests to declare.

References

- 1 Pascual B, de Bot ST, Daniels MR, et al. "Ears of the Lynx" MRI Sign Is Associated with SPG11 and SPG15 Hereditary Spastic Paraplegia. *AJNR Am J Neuroradiol* 2019;40(01):199–203
- 2 Elsaid MF, Ibrahim K, Chalhoub N, Elsotouhy A, El Mudehki N, Abdel Aleem A. *NT5C2* novel splicing variant expands the phenotypic spectrum of Spastic Paraplegia (SPG45): case report of a new member of thin corpus callosum SPG-Subgroup. *BMC Med Genet* 2017;18(01):33